

Cryptococcosis in a Bottlenose Dolphin (*Tursiops truncatus*) Caused by *Cryptococcus neoformans* var. *gattii*

W. George Miller,¹ Arvind A. Padhye,^{2*} William van Bonn,¹ Eric Jensen,¹
Mary E. Brandt,² and Sam H. Ridgway¹

Space and Naval Warfare Systems Center, San Diego, California 92152,¹ and Mycotic Diseases Branch,
Division of Bacterial and Mycotic Diseases, National Center for Infectious Diseases,
Centers for Disease Control and Prevention, Atlanta, Georgia 30333²

Received 3 August 2001/Accepted 11 October 2001

We describe the first case of cryptococcosis caused by *Cryptococcus neoformans* var. *gattii* in a male Atlantic bottlenose dolphin (*Tursiops truncatus*). The dolphin showed clinical signs of tachypnea, transient dyspnea, and mild tachycardia and developed multiple hyperechoic nodules, parenchymal consolidation, and thickening of pleura. A diagnosis of bronchopneumonia with pleuritis was made. Itraconazole therapy was implemented for 120 days, and trough levels in serum were within or above the suggested therapeutic range. Titers of cryptococcal antigen in serum increased eightfold during therapy, and the case had a fatal outcome. Necropsy examination findings included enlarged pulmonary lymph nodes and extensive coalescing granulomatous lesions throughout both lungs. Histologic examination revealed numerous, spherical to ellipsoidal, mucicarmine-positive, 3- to 14- μ m, encapsulated, budding cells consistent with *C. neoformans*. Culture of the lung tissue yielded colonies of *C. neoformans*. The isolate was urease positive and nitrate negative and exhibited phenoloxidase activity. It was positive on canavanine-glycine-bromothymol blue agar. When tested by the Iatron serodiagnostic reagent kit (Iatron Laboratories, Inc.), it was shown to belong to serotype B.

CASE REPORT

A 19-year-old adult male dolphin became acutely ill in April 1999, manifesting clinical signs of tachypnea, transient dyspnea, and mild tachycardia. Diagnostic ultrasonography of the thorax revealed diffusely distributed hyperechoic foci, focal parenchymal consolidation, thickening of the pleura, and a moderate increase in pleural fluid. A tentative diagnosis of bronchopneumonia with pleuritis was made. The animal was treated with broad-spectrum antibiotics for approximately 3 weeks and was further treated with itraconazole (Sporanox; Janssen Pharmaceutical, Titusville, N.J.) at an initial dosage of 9.2 mg/kg of body weight for 41 days followed by 4.6 mg/kg for 79 days (from April to August 1999).

Clinical laboratory values from April 1999 showed a moderate inflammatory hemogram with a marked absolute eosinophilia and elevated erythrocyte sedimentation rate. Peripheral blood circulating eosinophil numbers were intermittently elevated from May through September 1999. Elevated absolute eosinophil numbers were again noted in January 2000 and persisted until the animal's death in late February 2000. The elevation in erythrocyte sedimentation rate was first observed in March 1999 and also persisted until the animal's death. Serum chemistry values were within the established clinically normal range until mid-February 2000.

A marked elevation in respiratory rate was first observed in April 1999. The rate gradually returned to normal by September 1999. In January 2000, the respiratory rate was again elevated and remained so until the animal's death. Radiographs

of the thorax taken in January 2000 showed a severe extensive bronchointerstitial pattern.

Necropsy revealed enlarged pulmonary lymph nodes and extensive coalescing granulomatous lesions throughout both lungs. Sections of the lung tissue were stained by hematoxylin and eosin, periodic acid-Schiff stain, and Mayer's mucicarmine stain procedures. Microscopy revealed numerous, spherical to broadly ellipsoidal, encapsulated, budding yeast cells of *Cryptococcus neoformans*. The elongated ellipsoidal cells measured 3 to 14 μ m in the longest dimension (Fig. 1 and 2).

Mycological examination. Lung tissue was cultured on Sabouraud dextrose agar containing chloramphenicol (Difco Laboratories, Detroit, Mich.) and incubated at 25 and 37°C. Mucoid, white yeast-like colonies became evident after 78 to 96 h of incubation. A single colony isolate was used for further studies. The API 20C AUX system (bioMerieux, Hazelwood, Mo.), a commercial kit for the evaluation of the assimilation of 19 carbon sources, was used according to the manufacturer's instructions. The isolate was identified as *C. neoformans*. It was urease positive and nitrate negative and exhibited phenoloxidase activity by producing brown-pigmented colonies on L-dopa medium. Single brown-pigmented colonies from the L-dopa medium were isolated and grown on canavanine-glycine-bromothymol blue agar (16) at 28°C. The isolate was positive on canavanine-glycine-bromothymol blue agar after 48 h of incubation at 28°C and was identified as *C. neoformans* var. *gattii*. The serotype was determined using the Iatron serodiagnostic reagent kit (Iatron Laboratories, Inc., Tokyo, Japan) by slide agglutination using factor sera provided in the kit (12, 14). The isolate belonged to serotype B. The isolate has been deposited in the American Type Culture Collection

* Corresponding author. Mailing address: Mycotic Diseases Branch, Mail Stop G-11, Centers for Disease Control and Prevention, Atlanta, GA 30333. Phone: (404) 639-3749. Fax: (404) 639-3546. E-mail: aap1@cdc.gov.

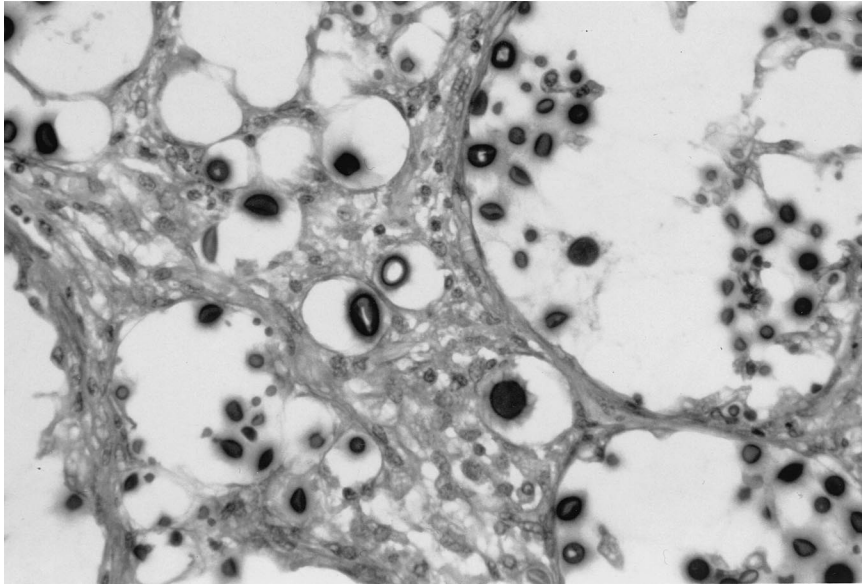


FIG. 1. Tissue section of lung of Atlantic bottlenose dolphin showing *C. neoformans* var. *gattii* encapsulated cells visualized with periodic acid-Schiff stain. Magnification, $\times 220$

(ATCC MYA 867) and the University of Alberta Microfungus Collection and Herbarium (UAMH 9837).

Serologic studies. Retrospective serum samples were submitted to Quest Diagnostics, San Diego, Calif., for cryptococcus antigen level determination by latex agglutination assay. A sample from 25 February 2000 was also tested by enzyme immunoassay (EIA). The results are shown in Table 1.

Discussion. *C. neoformans* is known to cause infection in a wide variety of mammalian hosts including marine dolphins. Pulmonary cryptococcosis in dolphins manifests as cryptococcal pneumonia most likely acquired through inhalation of cryptococcal aerosols (4). Fatal pulmonary cryptococcosis has previously been described for two species of dolphins, the Atlantic

bottlenose dolphin (*Tursiops truncatus*) and the striped dolphin (*Stenella coeruleoalba*) (10, 19). In both cases, the diagnosis was based on histopathologic examination of the necropsy tissues and the presence of cryptococcal cells in the lungs, mediastinal lymph nodes, and other organs. The causal agent was not isolated and/or grown in culture in either case.

The present case represents the first culture-proven case of cryptococcosis in an Atlantic bottlenose dolphin caused by *C. neoformans* var. *gattii* (serotype B). The only known environmental source of *C. neoformans* var. *gattii* (serotype B) is *Eucalyptus camaldulensis* and *E. tereticornis* (7, 8, 22). Three additional eucalypts, namely, *E. blakelyi*, *E. gomphocephala*, and *E. rudis*, also serve as natural hosts for *C. neoformans* var. *gattii*

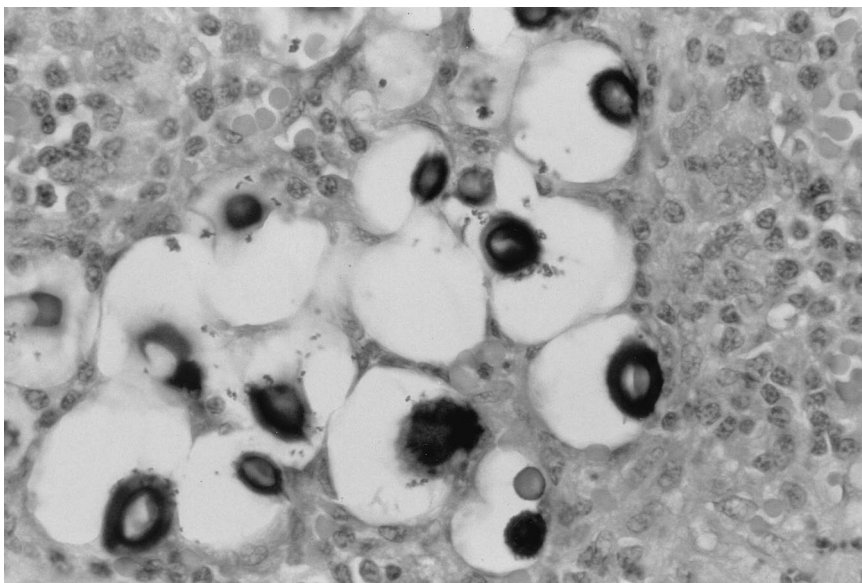


FIG. 2. Ellipsoid, encapsulated cells of *C. neoformans* var. *gattii*, visualized with Mayer's mucicarmine. Magnification, $\times 750$.

TABLE 1. Retrospective titers of cryptococcal antigen in serum determined by latex agglutination and EIA compared with clinical signs and itraconazole therapy

Date of sample or event (mo/day/yr)	Event ^a	Titer by latex agglutination test
6/11/1997		1:8
2/18/1998		1:8 (12 mo before signs)
7/6/1998		1:8
11/24/1998		1:32, 768
1/28/1999		1:16, 384
4/1/1999	Initial observation of respiratory signs	
4/9/1999	Start of itraconazole therapy at 800 mg BID	
4/16/1999		1:32,768
5/20/1999	Continuation of itraconazole therapy at 800 mg SID for 79 days	
6/10/1999		1:131,072
8/11/1999	Itraconazole serum levels measured at 2.4 µg/ml	
8/16/1999	Normal respiratory signs	
8/13/1999		1:262,144
2/25/2000		1:262,144 ^b

^a Abbreviations: BID, twice a day; SID, once a day.

^b Titer determined by EIA was 1:79,313.

(serotype B) (T. J. Pfeiffer and D. Ellis, Abstr. 13th Congr. Int. Soc. Hum. Anim. Mycol. [ISHAM] 1997, abstr. P111, p. 106, 1997). *C. neoformans* var. *gattii* appears to have been exported from Australia to other countries on contaminated seeds of *E. camaldulensis* and other species of eucalypts bearing fungal propagules. The first isolation of *C. neoformans* var. *gattii* from *E. camaldulensis* in the United States was made in 1991 by Pfeiffer and Ellis (21) from eucalypts growing near Fort Point, San Francisco, Calif. In the present case, the dolphin was maintained at the U.S. Navy Marine Mammal facilities in San Diego, Calif., where there are several eucalyptus trees growing on the campus. Whether the present isolate originated from any of the eucalyptus trees needs to be investigated.

A variety of systemic mycoses including aspergillosis (25), blastomycosis (5), candidiasis (2, 6), coccidioidomycosis (24), cryptococcosis (10, 19), histoplasmosis (13), lobomycosis (3, 17, 23), sporotrichosis (18), and zygomycosis (26, 27) have been reported elsewhere to cause fatal disease in cetaceans. Reidarson et al. (25) found itraconazole to be the most efficacious antifungal drug for treating marine mammals with *Aspergillus* infections. Because the drug was lipophilic, levels in tissue were generally higher than those in blood, and due to slow release of itraconazole from tissue, significant levels in blood could persist for weeks in marine mammals after discontinuation of therapy (25).

Confirmation of cryptococcal infection can be made by culture of the affected tissue and/or showing a positive cryptococcal antigen titer from serum (11, 15, 20). The cryptococcus latex agglutination test (Immuno-Mycologic Inc., Norman, Okla.) or the cryptococcus EIA (Meridian Diagnostic Inc., Cincinnati, Ohio) can be used to monitor response to antifungal therapeutics (11, 15, 20). Antemortem diagnosis of cryptococcal pneumonia in marine animals has not been documented. However, we confirmed cryptococcal pneumonia in a subsequent case via cytology of a thoracic parenchymal aspirate. Use of the cryptococcus latex agglutination test or the

EIA for diagnosis of cryptococcosis or determination of response to antifungal therapy in dolphins or other marine animals has not been documented.

Diagnosis of cryptococcal pneumonia in this case was initially made from postmortem specimens. Retrospective analysis of serum samples from this dolphin showed that the use of cryptococcal serology could be useful in antemortem diagnosis of this disease.

In vitro antifungal susceptibility testing of the present strain of *C. neoformans* var. *gattii* was performed at the Microbiology Reference Laboratory, Cypress, Calif., according to the NCCLS approved standard M27-A [19a]). The MIC and primary fungicidal action (minimal fungicidal concentration) of itraconazole for this isolate were 0.03 and 0.5 µg/ml, respectively. The level of itraconazole in serum measured on 30 July 1999 was 2.4 µg/ml (Table 1), which was five times the minimal fungicidal concentration. Itraconazole in serum was maintained at this level or higher for 120 days, and we believed that the drug at this level would have been efficacious against the present strain. However, retrospective titers of cryptococcal antigen in serum increased eightfold during the antifungal therapy (from 1:32,768 on 14 April 1999 to 1:262,144 on 13 August 1999). MICs can be potential predictors of poor clinical response to antifungal therapy when in vitro resistance is shown (1, 9), but our isolate did not show an elevated in vitro resistance.

In this case, the progressive increase in cryptococcal antigen titer and the eventual fatal outcome showed a failure of the itraconazole therapy. Suggested therapeutic levels of antifungals, as they apply for humans or other animals, were not appropriate for this bottlenose dolphin and may not apply to marine mammals. Further studies of dolphins are needed to determine an appropriate pharmaceutical therapy and the appropriate application of cryptococcal antigen serology as it relates to cryptococcosis in marine animals.

REFERENCES

- Aller, A. I., E. Martin-Mazuelos, F. Lozano, J. Gomez-Mateos, L. Steele-Moore, W. J. Holloway, M. J. Gutierrez, F. J. Recio, and A. Espinel-Ingroff. 2000. Correlation of fluconazole MICs with clinical outcome in cryptococcal infection. *Antimicrob. Agents Chemother.* **44**:1544-1548.
- Bossart, G. D., and C. Bossart. 1982. A treatment regimen for candidiasis in an Atlantic bottlenose dolphin. *J. Am. Vet. Med. Assoc.* **181**:1399-1400.
- Caldwell, D. K., M. C. Caldwell, J. C. Woodard, L. Ajello, W. Kaplan, and H. M. McClure. 1975. Lobomycosis as a disease of the Atlantic bottle-nosed dolphin (*Tursiops truncatus* Montagu, 1821). *Am. J. Trop. Med. Hyg.* **24**:105-114.
- Casadevall, A., and J. R. Perfect. 1998. *Cryptococcus neoformans*, p. 325-350. ASM Press, Washington, D.C.
- Cates, M. B., L. Kaufman, J. H. Grabau, J. M. Pletcher, and J. P. Schroeder. 1986. Blastomycosis in an Atlantic bottlenose dolphin. *J. Am. Vet. Med. Assoc.* **189**:1148-1150.
- Dunn, J. L., J. D. Buck, and S. Spotte. 1982. Candidiasis in captive cetaceans. *J. Am. Vet. Med. Assoc.* **181**:1316-1321.
- Ellis, D. H., and T. J. Pfeiffer. 1990. Natural habitat of *Cryptococcus neoformans* var. *gattii*. *J. Clin. Microbiol.* **28**:1642-1644.
- Ellis, D. H., and T. J. Pfeiffer. 1990. Ecology, life cycle, and infectious propagule of *Cryptococcus neoformans*. *Lancet* **336**:923-925.
- Espinel-Ingroff, A. 2000. Clinical utility of in vitro antifungal susceptibility testing. *Rev. Esp. Quimioter.* **13**:161-166.
- Gales, N., G. Wallace, and J. Dickson. 1985. Pulmonary cryptococcosis in a striped dolphin (*Stenella coeruleoalba*). *J. Wildl. Dis.* **21**:443-446.
- Gordon, M., and D. Vedder. 1966. Serologic tests in the diagnosis and prognosis of cryptococcosis. *JAMA* **197**:961-967.
- Ikeda, R., T. Shinoda, Y. Fukuzawa, and L. Kaufman. 1982. Antigenic characterization of *Cryptococcus neoformans* serotypes and its application to serotyping of clinical isolates. *J. Clin. Microbiol.* **16**:22-29.
- Jensen, E. D., T. Lipscomb, B. van Bonn, G. Miller, J. M. Fradkin, and S. H.

- Ridgway. 1998. Disseminated histoplasmosis in an Atlantic bottlenose dolphin (*Tursiops truncatus*). *J. Zoo Wildl. Med.* **29**:456–460.
14. Kabasawa, K., H. Itagaki, R. Ikeda, T. Shinoda, K. Kagaya, and Y. Fukazawa. 1991. Evaluation of a new method for identification of *Cryptococcus neoformans* which uses serologic tests aided by selected biological tests. *J. Clin. Microbiol.* **29**:2873–2876.
15. Knight, F. 1992. New enzyme immunoassay for detecting cryptococcal antigen. *J. Clin. Pathol.* **45**:836–837.
16. Kwon-Chung, K. J., I. Polacheck, and J. E. Bennett. 1982. Improved diagnostic medium for separation of *Cryptococcus neoformans* var. *neoformans* (serotypes A and D) and *Cryptococcus neoformans* var. *gattii* (serotypes B and C). *J. Clin. Microbiol.* **15**:535–537.
17. Migaki, G., M. G. Valerio, B. Irvine, and F. M. Garner. 1971. Lobo's disease in an Atlantic bottlenose dolphin. *J. Am. Vet. Med. Assoc.* **159**:578–582.
18. Migaki, G., R. L. Font, W. Kaplan, and E. D. Asper. 1978. Sporotrichosis in a Pacific white-sided dolphin (*Lagenorhynchus obliquidens*). *Am. J. Vet. Res.* **39**:1916–1919.
19. Migaki, G., R. D. Gunnels, and H. W. Casey. 1978. Pulmonary cryptococcosis in an Atlantic bottlenose dolphin (*Tursiops truncatus*). *Lab. Anim. Sci.* **28**:603–606.
- 19a. National Committee for Clinical Laboratory Standards. 1997. Reference method for broth dilution antifungal susceptibility testing of yeasts. Approved standard M27-A. National Committee for Clinical Laboratory Standards, Wayne, Pa.
20. Palmer, D., L. Kaufman, W. Kaplan, and J. J. Cavallaro. 1977. Slide latex agglutination test for cryptococcal antigen, p. 94–106. *In* Serodiagnosis of mycotic diseases. Charles C Thomas, Springfield, Ill.
21. Pfeiffer, T. J., and D. H. Ellis. 1991. Environmental isolation of *Cryptococcus neoformans gattii* from California. *J. Infect. Dis.* **163**:929–930.
22. Pfeiffer, T. J., and D. H. Ellis. 1992. Environmental isolation of *Cryptococcus neoformans* var. *gattii* from *Eucalyptus tereticornis*. *J. Med. Vet. Mycol.* **30**:407–408.
23. Pradinaud, R. 1998. *Lobo lobo*, p. 585–594. *In* L. Collier, A. Balows, and M. Sussman (ed.), Topley and Wilson's microbiology and microbial infections, vol. 4. Oxford University Press, New York, N.Y.
24. Reidarson, T. H., L. A. Griner, D. Pappagianis, and J. McBain. 1998. Coccidioidomycosis in a bottlenose dolphin. *J. Wildl. Dis.* **34**:629–631.
25. Reidarson, T. H., J. H. Harrell, M. G. Rinaldi, and J. McBain. 1998. Bronchoscopic and serologic diagnosis of *Aspergillus fumigatus* pulmonary infection in a bottlenose dolphin (*Tursiops truncatus*). *J. Zoo Wildl. Med.* **29**:451–455.
26. Sweeney, J. C., G. Migaki, P. M. Vainik, and R. H. Conklin. 1976. Systemic mycosis in marine mammals. *J. Am. Vet. Med. Assoc.* **169**:946–948.
27. Wunschmann, A., V. Siebert, and R. Weiss. 1999. Rhizopus mycosis in a harbor porpoise from Baltic sea. *J. Wildl. Dis.* **35**:569–573.