

Detection of endogenous cytokines in sera or in lymph nodes obtained from patients with sarcoidosis

M. ASANO, T. MINAGAWA, M. OHMACHI* & Y. HIRAGA* *Department of Microbiology, Hokkaido University School of Medicine, and *Department of Chest Medicine, JR Sapporo Hospital, Sapporo 060, Japan*

(Accepted for publication 17 October 1990)

SUMMARY

To investigate the possible role of endogenous cytokines in the immunopathogenesis of sarcoidosis, a study of cytokines in lymph nodes obtained from patients with active pulmonary sarcoidosis was carried out using immunoperoxidase staining and radioimmunoassays (RIA). Cells stained for interferon- γ (IFN- γ) and tumour necrosis factor- α (TNF- α), which appeared to be CD3⁺ cells and CD14⁺ cells, respectively, were seen scattered around granulomas. In contrast, cells positive for interleukin-1 β (IL-1 β) were located in CD11c⁺ cells within granulomas. Lymph nodes of patients with sarcoidosis contained significantly higher amounts of IFN- γ , TNF- α and IL-1 β than control lymph nodes. The levels of IFN- γ and TNF- α in extracts of lymph nodes were correlated with the histological status of the granulomas. IFN- γ was detected in all stages, while the highest level of TNF- α was obtained from lymph nodes containing many active granulomas. The level of serum IFN- γ was always lower than in lymph node extract and correlated significantly with either serum angiotensin-converting enzyme or serum lysozyme. Patients with positive gallium-67 uptake or bilateral hilar lymphadenopathy had high levels of either serum IFN- γ or lysozyme. These results suggest that quantitative analyses of IFN- γ and TNF- α in sera and lymph nodes may serve to elucidate the pathophysiology of sarcoidosis.

Keywords sarcoidosis interferon-gamma tumour necrosis factor-alpha interleukin-1 β

INTRODUCTION

Sarcoidosis is a chronic systemic disorder of unknown aetiology characterized by non-caseating epithelioid cell granulomata in the affected organs (Mitchell & Scadding, 1974). Macrophages and T lymphocytes around granulomas have been thought to play an important role in granuloma formation. These cells produce cytokines, including monokines and lymphokines. Macrophage chemotactic factor (MCF), interleukin-1 (IL-1), IL-2, and interferon- γ (IFN- γ), tumour necrosis factor- α (TNF- α) and macrophage colony-stimulating factor (M-CSF) have been detected in cultures of bronchoalveolar lavage fluid (BALF) cells or granulomatous lymph nodes of patients with sarcoidosis (Pinkston, Bitterman & Crystal, 1983; Hunninghake *et al.*, 1986; Robinson, McLemore & Crystal, 1985; Hancock *et al.*, 1986; Wewers *et al.*, 1987; Chilosi *et al.*, 1988; Ruco *et al.*, 1989; Kreipe *et al.*, 1990).

The titres of IFN- γ in sera of patients with sarcoidosis are higher than those of healthy persons and correlate with clinical activity (Minagawa *et al.*, 1988). But peripheral blood mono-

nuclear cells (PBMC) of patients produce relatively small amounts of IFN- γ when stimulated with various mitogens as compared with PBMC of healthy persons (Rohatgi & Goldstein, 1984), suggesting that IFN- γ detected in sera may be produced at specific disease sites and released into the bloodstream. Therefore, we studied endogenous cytokines in sera and lymph node extracts of patients with sarcoidosis detected by immunoperoxidase staining and radioimmunoassay (RIA), to discover whether the levels of endogenous cytokines correlated with either histological or clinical markers of sarcoidosis activity.

MATERIALS AND METHODS

Patients

Tissue samples of enlarged anterior scalene lymph nodes of 29 patients with sarcoidosis were resected for histology. The sera from these patients plus seven others were simultaneously sampled at operation. Twelve normal lymph nodes obtained from patients with non-immunological diseases were available as controls.

Immunohistochemical staining

Fresh lymph node tissues (from eight cases) were embedded in OCT compound (Miles, Elkhart, IN), snap-frozen in dry ice and

Correspondence: M. Asano, Department of Microbiology, Hokkaido University School of Medicine, North 15, West 7, Sapporo 060, Japan.

ethanol, and stored at -85°C until use. Four-micron cryostat sections were mounted on to poly-L-lysine (Sigma Chemical Co., St Louis, MO) coated glass slides and were fixed in cold acetone after sectioning. Immunohistochemical staining was carried out by the avidin-biotin-peroxidase complex (ABC) (Vector Laboratories, Burlingame, CA) method (Hsu, Raine & Fanger, 1981). The sections were stained with H_2O_2 and 3,3'-diaminobenzidine and by methyl green nuclear counter staining. Monoclonal antibodies (MoAbs) specific for IFN- γ (Centocor, Malvern, PA), TNF- α (Suntory), CD3, CD11c and CD14 (Becton-Dickinson, Mountain View, CA), which had been purified to IgG fractions, and a rabbit antiserum specific for IL-1 β (Cistron) were used in this study. Normal mouse IgG and normal rabbit serum were used as the control. The antigenic specificity of each anti-cytokine antibody was confirmed by the immunoabsorption method. Before application on to the tissue sections, each antibody was incubated at 4°C overnight in a 96-well electroimmunoassay (EIA) plate (Costar, Cambridge, MA) which was first coated with each cytokine and then washed with 0.05% Tween 20 in phosphate-buffered saline (PBS) and coated with 1% bovine serum albumin in PBS to block non-specific binding. The binding of each antibody to the well was ascertained by staining with *o*-phenylenediamine after treatment with anti-mouse IgG-conjugated peroxidase. The absorbed antibody failed to neutralize biological activity and there was no cross-reactivity with other cytokines.

Histological findings

Formalin-fixed paraffin-embedded sections of lymph nodes of patients with sarcoidosis were stained with haematoxylin and eosin. The histological findings of lymph nodes were classified into three groups as follows: lymph nodes of the early stage (I) consisted of sinus histiocytosis or ≤ 10 granulomas at low magnitude ($\times 100$). Lymph nodes of the active stage (II) contained ≥ 11 mature granulomas, occasionally with giant cells. Lymph nodes of the healing stage (III) showed fibrosis or hyalinosis in abundant granulomas.

Assays for cytokines

Assays for IFN- γ , TNF- α and IL-1 β in sera or in cell-free lymph node extracts were carried out using RIA kits purchased from Centocor (Malvern, PA), Medgenic (Fleurus, Belgium) and Cistron (Pine Brook, NJ), respectively. Lymph nodes were immediately frozen at -85°C after surgery and sliced in frozen condition. They were suspended in heat-treated human serum and frozen and thawed three times, and then centrifuged at 5000 g for 30 min. The supernatants were stored at -85°C until assayed. The minimum doses of IFN- γ , TNF- α and IL-1 β reproducibly detectable from the zero level were 0.1 IU/ml, 10 pg/ml and 0.25 ng/ml, respectively, as determined by Student's *t*-test. Raw data on the extracts were calculated as titres of cytokines per weight (g) of the original lymph nodes.

Enzyme assays

Angiotensin-converting enzyme (ACE) activity was measured using a method based on colorimetry of the quinoneimine dye produced from the substrate, hippuryl-L-histidyl-L-leucine (Kasahara & Ashihara, 1981). Lysozyme activity was measured using the turbidimetric method described by Ensink & Haering (1977). In this assay, serum samples were incubated with a

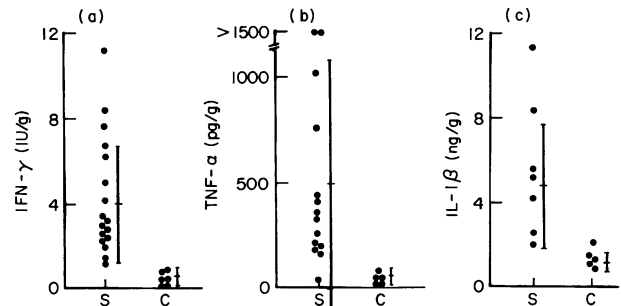


Fig. 1. Cytokine levels in lymph node extracts from patients with sarcoidosis (S) and controls (C). (a), IFN- γ (U/g); (b), TNF- α (pg/g); (c), IL-1 β (ng/g).

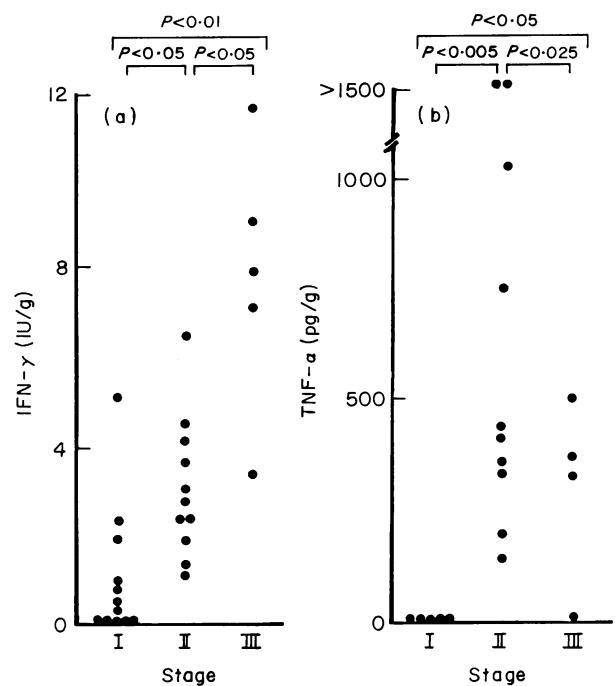


Fig. 2. Cytokine levels in the various histological stages of lymph nodes: (I) the early stage, (II) the active stage, (III) the healing stage. Both IFN- γ (U/g) (a) and TNF- α (pg/g) (b) were determined in the lymph node extracts. Levels of significance are for the Wilcoxon rank sum test.

suspension of *Micrococcus lysodeikticus* (Sigma). Lysis of bacteria by lysozyme was measured in a spectrophotometer.

Statistical analysis

All data were evaluated statistically by analysis of variance, and the least significant difference was determined. Paired values were compared using the Wilcoxon matched pairs signed ranks test.

RESULTS

The detection of cytokines in lymph node extracts

The quantitative detection of IFN- γ (lymph node IFN- γ), TNF- α (lymph node TNF- α) and IL-1 β (lymph node IL-1 β) in the extracts of lymph nodes of patients with sarcoidosis and

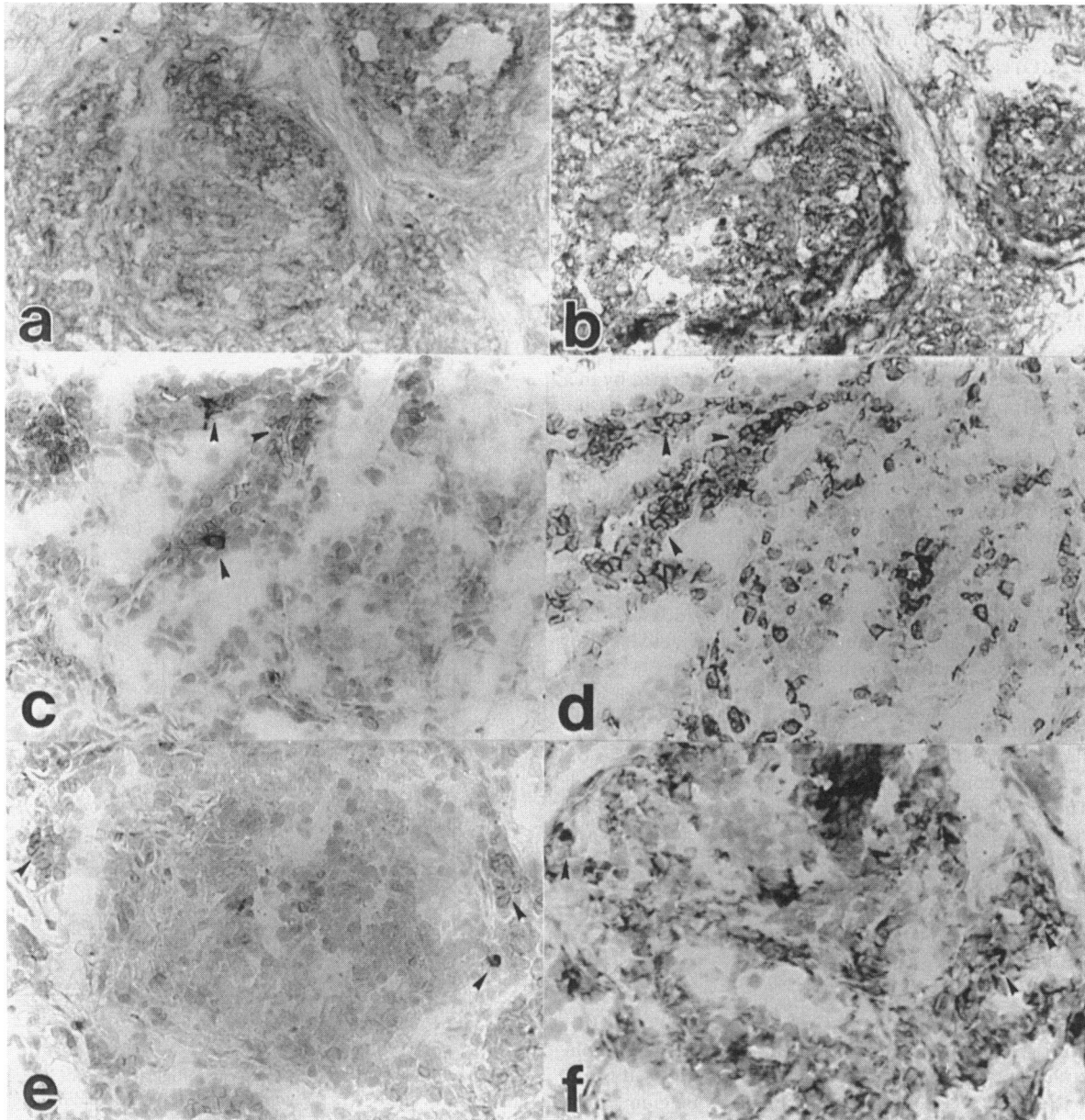


Fig. 3. Identification of surface markers of cells positive for cytokines (ABC immunoperoxidase technique: methyl green counterstain $\times 400$). IL-1 β + cells (a) were present among CD11c+ cells (b). IFN- γ + cells (c) were present among CD3+ cells (d). TNF- α + cells (e) were present among CD14+ cells (f) around granulomas.

controls was carried out using RIA. The levels of these three cytokines in sarcoidosis were significantly elevated as compared with control levels, being 4.19 ± 2.89 IU/g for IFN- γ , 483 ± 583 pg/g for TNF- α , and 4.99 ± 3.17 ng/g for IL-1 β . The control levels were 0.38 ± 0.27 IU/g, < 10 pg/g, and 1.06 ± 0.36 ng/g, respectively (Fig. 1).

The relationship between the levels of cytokines in lymph node extracts and histological findings on lymph nodes

Enlarged granulomatous lymph nodes of patients with sarcoidosis were divided into three stages according to the histological findings. Lymph node IFN- γ was detected in all stages and increased gradually according to the development of granulo-

mas, while the level of lymph node TNF- α was highest in the active stage (II) (Fig. 2).

Immunohistochemical demonstration of cytokines in lymph nodes

To evaluate the localization and characterization of cytokine-expressing cells within granulomatous lymph nodes, the qualitative detection of each cytokine was carried out on cryostat-frozen sections using immunohistochemical staining. A pair of mirror-image sections was mounted on the same glass slide so that the staining pattern for one cytokine could be compared with that for one surface marker. The cells positively stained for IL-1 β (Fig. 3a) belonged to the CD11c+ resting macrophage population, which was epithelioid cells within granulomas (Fig. 3b). The cells positive for IFN- γ (Fig. 3c) and TNF- α (Fig.

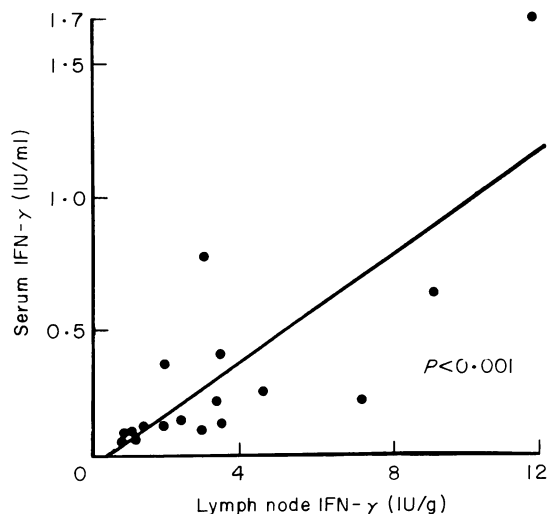


Fig. 4. Relationship between the level of serum IFN- γ and lymph node IFN- γ of each patient. The correlation coefficient (r) was 0.903 ($P < 0.01$).

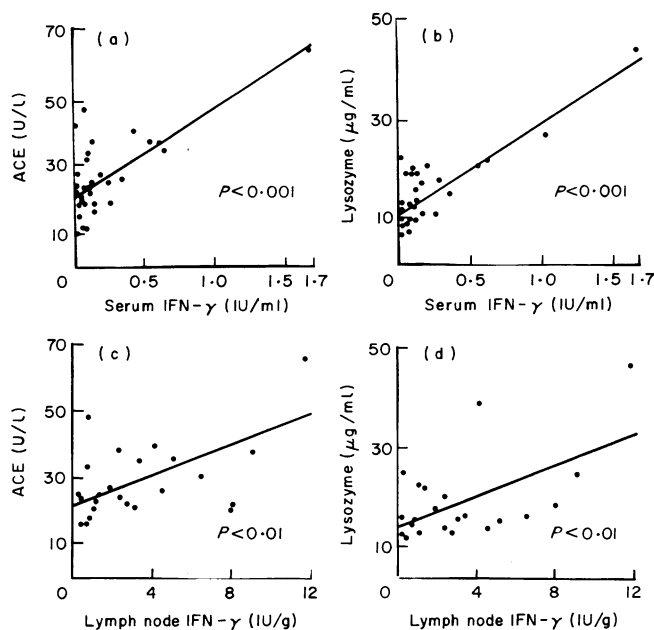


Fig. 5. Relationship between the level of serum IFN- γ and either serum ACE (a) or serum lysozyme (b), or the level of lymph node IFN- γ and either serum ACE (c) or serum lysozyme (d). Correlation coefficients (r) were as follows: (a) 0.764, (b) 0.887, (c) 0.612, (d) 0.627.

3d), which were located within mantle lymphocytes surrounding granulomas, were found among CD3⁺ T lymphocytes (Fig. 3e) and CD14⁺ macrophage/monocyte populations (Fig. 3f), respectively. Preabsorption of antibodies against cytokines abolished specific staining. Sections treated with control mouse IgG and normal rabbit serum were unstained (data not shown). Staining for all anticytokine antibodies in control lymph nodes was negative (data not shown).

Table 1. The level of IFN- γ , serum ACE or serum lysozyme according to ⁶⁷Ga uptake or BHL finding

	⁶⁷ Ga uptake		BHL	
	+	-	+	-
	(n=28)	(n=7)	(n=24)	(n=12)
Serum IFN- γ (IU/ml)	0.23 ± 0.39**	0.05 ± 0.03	0.24 ± 0.40**	0.05 ± 0.03
Lymph node IFN- γ (IU/g)	3.11 ± 3.30	1.32 ± 1.96	3.30 ± 3.39	1.62 ± 1.82
Serum ACE (U/l)	28.1 ± 10.5	21.8 ± 7.9	29.3 ± 10.6	22.5 ± 7.1
Serum lysozyme (μg/ml)	15.1 ± 8.3*	8.9 ± 2.0	16.2 ± 8.5*	9.6 ± 2.1

Values represent mean ± s.d. activity in units. Level of significance for the Wilcoxon rank sum test. P value as compared with negative.

* $P < 0.005$; ** $P < 0.025$.

BHL, bilateral hilar lymphadenopathy.

n , number of patients.

The detection of cytokines in sera

The mean level of serum IFN- γ in 36 patients with sarcoidosis (0.23 ± 0.16 IU/ml) was higher than that in 77 healthy persons (< 0.1 IU/ml). On the other hand, the serum levels of TNF- α and IL-1 β in sarcoidosis patients stayed as low as those in controls (TNF- α : < 10 pg/ml; IL-1 β : < 0.25 ng/ml). The level of lymph node IFN- γ was always higher than that of serum IFN- γ in each patient and correlated with that of serum IFN- γ (Fig. 4). When the standard solutions of these cytokines and the sera containing high amounts of cytokines were treated at 56°C for 30 min, they became undetectable by RIA. Neither IFN- γ nor TNF- α in sera and lymph node extracts could be detected by bioassay.

Relationship between cytokine levels and clinical markers

The level of either serum IFN- γ or lymph node IFN- γ correlated significantly with either serum ACE or serum lysozyme (Fig. 5), though lymph node TNF- α did not, and a positive relationship between the level of serum ACE and serum lysozyme was observed ($P < 0.01$) (data not shown).

Twenty-eight patients with positive gallium-67 (⁶⁷Ga) uptake showed high levels of serum IFN- γ and lysozyme, while the levels in seven patients with negative ⁶⁷Ga were low (Table 1). Similarly, the levels of serum IFN- γ and lysozyme in 24 patients with positive bilateral hilar lymphadenopathy (BHL) were higher than those of the 12 patients with negative BHL (Table 1). However, a significant difference was not observed between the levels of either lymph node TNF- α or serum ACE and either ⁶⁷Ga uptake or BHL (Table 1).

DISCUSSION

The present study describes the quantitative and qualitative detection of endogenous cytokines in sera and in lymph nodes obtained from patients with sarcoidosis and their relationship to the clinical markers of the disease. Granulomas in lung, regional lymph nodes and other organs where T lymphocytes and macrophages are activated locally by cytokines in an autocrine and/or paracrine manner develop during the active stage of sarcoidosis (Mosley *et al.*, 1986; Semenzato, Agostini & Zam-

bello, 1986; Gerli *et al.*, 1988; Spiteri, Poulter & James, 1989). Localization of IFN- γ , TNF- α and IL-1 β in granulomatous lymph nodes of sarcoidosis patients has been reported (Chilosi *et al.*, 1988; Hancock *et al.*, 1986; Ruco *et al.*, 1989). We show that the cells expressing IFN- γ , TNF- α and IL-1 β are present among CD3⁺, CD14⁺ and CD11c⁺ cells, respectively. In addition, these cytokines were extracted from lymph nodes and determined by RIA. The levels of IFN- γ and TNF- α were related to the histological status of granulomatous lymph nodes. The level of lymph node IFN- γ was always higher than that of serum IFN- γ , suggesting that IFN- γ might be produced in the inflamed lesions of sarcoidosis and released into the bloodstream. Thus, it is important to determine the minimum detectable doses of IFN- γ , TNF- α , and IL-1 β by RIA. We confirmed that there was a significant difference between the lowest standard dose and the zero standard, supporting the detection of low levels of cytokines in lymph nodes and in sera.

Serum ACE and serum lysozyme have been known to localize within epithelioid granuloma and be released into the bloodstream (Silverstein, Pertsch & Friedland, 1979). The serum levels of ACE, lysozyme, and also IFN- γ appear to reflect the disease activity in systemic granulomatous lesions. The levels of four markers, serum IFN- γ , lymph node IFN- γ , serum ACE, and serum lysozyme, were mutually correlated. A positive relationship between these four markers was also observed in additional experiments (data not shown). Moreover, the levels of serum IFN- γ and serum lysozyme, rather than serum ACE, correlated significantly with ⁶⁷Ga uptake and BHL, suggesting that determining serum IFN- γ is helpful for the evaluation of the local immunological state and for the prediction and treatment of the disease.

REFERENCES

- CHILOSI, M., MENESTRINA, F., CAPELLI, P., MONTAGNA, L., LESTANI, M., PIZZOLLO, G., CIPRIANI, A., AGOSTINI, C., TRENTIN, L., ZAMBELLO, R. & SEMENZATO, G. (1988) Immunohistochemical analysis of sarcoid granulomas: evaluation of Ki 67⁺ and interleukin-1⁺ cells. *Am. J. Pathol.* **131**, 191.
- ENSINK, F.T.E. & HAERINGEN, N.J. (1977) Pitfalls in the assay of lysozyme in human tear fluid. *Ophthalm. Res.* **9**, 366.
- GERLI, B.R., DARWISH, S., BROCCUCCI, L., MINOTTI, V., SPINOZZI, F., CERNETTI, C., BERTOTTO, A. & RAMBOTTI, P. (1988) Analysis of CD4-positive T cell subpopulation in sarcoidosis. *Clin. exp. Immunol.* **73**, 226.
- HANCOCK, W.W., KOBZIK, L., COLBY, A.J., O'HARA, C.J., COOPER, A.G. & GODLESKI, J.J. (1986) Detection of lymphokines and lymphokine receptors in pulmonary sarcoidosis: immunohistologic evidence that inflammatory macrophages express IL-2 receptors. *Am. J. Pathol.* **123**, 1.
- Hsu, S.M., RAINE, L. & FANGER, H. (1981) A comparative study of the peroxidase-antiperoxidase method and an avidin-biotin complex method for studying polypeptide hormones with radioimmunoassay antibodies. *Am. Soc. Clin. Pathol.* **75**, 734.
- HUNNINGHAKE, G.W., HEMKEN, C., BRADY, M. & MONICK, M. (1986) Interferon is a growth factor for human lung fibroblasts. *Am. Rev. Respir. Dis.* **134**, 1025.
- KASAHARA, Y. & ASHIHARA, Y. (1981) Colorimetry of angiotensin converting enzyme activity in serum. *Clin. Chem.* **27**, 1922.
- KREIPE, H., RADZUN, J.R., HEIDORN, K., BARTH, J., KALLEE, J.K., PETERMANN, W., GERDES, J. & PARWARESCH, M.R. (1990) Proliferation, macrophage colony-stimulating factor, and macrophage colony-stimulating factor-receptor expression of alveolar macrophages in active sarcoidosis. *Lab. Invest.* **62**, 697.
- MINAGAWA, T., KANEKO, F., HIRAGA, Y., SAGAWA, A., NAKANE, A., KATO, K. & OHKAWARA, A. (1988) The level of gamma interferon detected in sera and exudates or extracts of local lesions of chronic inflammation. *Proc. Jpn Soc. Invest. Dermatol.* **12**, 28.
- MITCHELL, D.N. & SCADDING, J.G. (1974) Sarcoidosis. *Am. Rev. Respir. Dis.* **110**, 774.
- MOSLEY, P.L., HEMKEN, C., MONICK, M., NUGENT, K. & HUNNINGHAKE, G.W. (1986) Interferon and growth factor activity for human lung fibroblasts. Release from bronchoalveolar cells from patients with active sarcoidosis. *Chest*, **89**, 657.
- PINKSTON, P., BITTERMAN, P.B. & CRYSTAL, R.B. (1983) Spontaneous release of interleukin-2 by lung T-lymphocytes in active pulmonary sarcoidosis. *N. Engl. J. Med.* **308**, 793.
- ROBINSON, B.W.S., McLEMORE, T.L. & CRYSTAL, R.G. (1985) Gamma interferon is spontaneously released by alveolar macrophages and lung T lymphocytes in patients with pulmonary sarcoidosis. *J. Clin. Invest.* **75**, 1488.
- ROHATGI, P.K. & GOLDSTEIN, R.A. (1984) Immunopathogenesis, Immunology and assessment of activity of sarcoidosis. *Ann. Allergy*, **52**, 316.
- RUCO, L.P., STOPPACCIARO, A., POMPONI, D., BORASCHI, D., SANTONI, A., TAGLIABUE, A., UCCINI, S. & BARONI, C.D. (1989) Immunoreactivity for IL-1 beta and TNF alpha human lymphoid and nonlymphoid tissues. *Am. J. Pathol.* **135**, 889.
- SEMENZATO, G., AGOSTINI, C. & ZAMBELLO, R. (1986) Activated T cells with immunoregulatory functions at different sites of involvement in sarcoidosis. Phenotypic and functional evaluations. *Ann. NY Acad. Sci.* **465**, 56.
- SILVERSTEIN, E., PERTSCHK, L.P. & FRIEDLAND, J. (1979) Immunofluorescent localization of angiotensin converting enzyme in epithelioid and giant cells of sarcoidosis granulomas. *Proc. Natl Acad. Sci. USA*, **76**, 6646.
- SPITERI, M.A., POULTER, L.W. & JAMES, D.G. (1989) The macrophage in sarcoid granuloma formation. *Sarcoidosis*, **6** (Suppl. 1), 12.
- WEWERS, M.D., SAITINI, C., SELLERS, S., TOCCI, M.J., BAYNE, E.K., SCHMIDT, J.A. & CRYSTAL, R.G. (1987) Evaluation of alveolar macrophages in normals and individuals with active pulmonary sarcoidosis for the spontaneous expression of the interleukin-1 β gene. *Cell. Immunol.* **107**, 479.