

HNK-1 monoclonal antibody (Leu-7) in the identification of abnormal expansions of large granular lymphocytes

F. PANDOLFI, G. SEMENZATO, G. DE ROSSI, ISABELLA QUINTI, C. GUGLIELMI, A. PEZZUTTO, MANUELA LOPEZ, G. TONIETTI, L. FONTANA, T. ABO & F. AIUTI *Department of Allergology and Clinical Immunology, Institute of Clinical Medicine III, La Sapienza, University of Rome; Immunopathology Division, Department of Clinical Medicine, University of Padua; Department of Hematology, Institutes of Clinical Medicine II and VI, La Sapienza, University of Rome and Cellular Immunology Unit of the Tumour Institute, Department of Surgery and Microbiology, University of Alabama, Birmingham, USA*

(Accepted for publication 7 December 1982)

SUMMARY

Among 12 cases of chronic T lymphoproliferative disorders we observed, six patients showed an expansion of mononuclear cells with azurophilic granules usually referred to as large granular lymphocytes or LGL. Cells obtained from five patients with these abnormal LGL proliferations were studied with several surface markers including their reactivity with the HNK-1 monoclonal antibody reported to be specific for LGL. Cells in four out of five cases were HNK-1 positive. Whereas normal LGL have been reported to be unreactive with several T cell markers, three cases showed the co-existence of HNK-1 and surface markers expressed by T cells. Two cases were characterized by the proliferation of OKT8 cells. Cells from one patient were HNK-1 positive but did not express T or monocytic antigens. These cells were apparently not completely mature since α -naphthyl acetate acid esterase activity was negative. Cells from the remaining case were HNK-1 negative and positive for T and monocytic antigens. An increase of OKT-10 cells was observed in only one patient. Our data indicate that proliferations of LGL represent a remarkable proportion of the rare cases of sheep erythrocyte rosetting chronic lymphocytic leukaemias or lymphomas. Besides the morphology of LGL, the rosetting ability and the negativity for peroxidase, cells from these cases showed a vast heterogeneity of other structural and functional markers, possibly reflecting different stages in the maturation of these cells. The HNK-1 monoclonal antibody proved to be an important marker in the identification of these cases.

INTRODUCTION

Human peripheral blood mononuclear cells (PBMC) with intracytoplasmic azurophilic granules (usually referred to as large granular lymphocytes, or LGL) have long been observed in blood smears of normal subjects. Over the past few years, there has been increasing interest in the study of surface markers and functional activities of these cells. Most LGL have been found to bear receptors for the Fc portion of IgG (Fc γ R) and are included among both sheep rosette forming cells (SRFC) (Grossi *et al.*, 1978) and non-T, non-B cells (Ferrari *et al.*, 1980). The heterogeneity of this population is also confirmed by its reactivity with monoclonal antibodies. Normal peripheral blood

Correspondence: Professor F. Aiuti, Cattedra di Allergologia e Immunologia Clinica, Viale dell'Università 37, 00161 Rome, Italy.

LGL are unreactive with some anti-T reagents (OKT3, OKT4, OKT5), while displaying small amounts of positivity with other anti-T monoclonals (OKT8, 3A1) (Ortaldo *et al.*, 1981; Abo & Balch, 1981). Several LGL are OKM1 positive, and the majority of LGL cells have been reported to react with OKT10 (Ortaldo *et al.*, 1981). More recently, a monoclonal antibody (HNK-1) has been reported to bind specifically to LGL (Abo & Balch, 1981). In addition, evidence has recently been provided that NK activity in humans is confined to LGL enriched fractions (Timonen, Ortaldo & Herberman, 1981; Strong *et al.*, 1982). Taken together, these findings suggest that we are dealing with a discrete subset of mononuclear cells with specialized functions.

Non-Hodgkin lymphomas and chronic lymphocytic leukaemias (CLL) of T cell origin are rare diseases, accounting for only 2% of all CLL cases (Pandolfi *et al.*, 1982c). In the past, these disorders were identified by the ability of the cells to form sheep erythrocyte rosettes. Additional studies have demonstrated that these lymphoproliferative diseases include proliferations of different subpopulations of mature SRFC, showing specialized functions, such as helper (Haynes *et al.*, 1981) or cytotoxic suppressor (Pandolfi *et al.*, 1980) activities. Despite the heterogeneous morphology of these cells (Pandolfi *et al.*, 1982a), some cases clearly appear to be sustained by the proliferation of LGL. These rare cases, further support the evidence that LGL are a discrete subset of PBMC. In the present report, the evaluation of surface markers, morphology, cytochemistry and functional activities were performed on PBMC from five cases of LGL lymphoproliferative disorders.

MATERIALS AND METHODS

Patients. Out of 12 patients with T-CLL or T lymphomas observed by us, high proportions of circulating LGL were found in the PBMC of six cases. One patient, however, died of a traumatical cranial injury before the study was completed and consequently he is not included in this paper. Of the five remaining cases with lymphoproliferative disorders of LGL, three patients had the clinical features of CLL: proliferating cells from these three patients have already been extensively characterized (Pandolfi *et al.*, 1982a, 1982b, 1982c). Physical examination was essentially negative and a diagnosis of CLL was formulated, according to Rai's criteria (Rai *et al.*, 1975), on the basis of a significant and persistent lymphocytosis in the peripheral blood and marrow. These patients have been under observation with no therapy for 14–22 months. Proliferating cells from case 2 (EM) were characterized as small lymphocytes (Pandolfi *et al.*, 1982a). However, after 1 year of observation, while the OKT8⁺ cellular phenotype remained unchanged, LGL started to increase slowly and 1 year later, they were about half of the PBMC; ANAE positive cells also increased from 46% to 78%.

Two additional cases of lymphoproliferative disorders were studied. Details are reported separately (Pandolfi *et al.*, 1983). These patients were characterized by neoplastic infiltration of parenchymatous organs and later they developed peripheral LGL lymphocytosis. The disease was more aggressive and chemotherapy was required (Case Nos 3 & 5).

Surface markers and cytochemistry. PBMC were isolated from venous blood through a Ficoll-Hypaque gradient (Aiuti *et al.*, 1975). SRFC and cells positive for Fc γ R were determined as described (Pandolfi *et al.*, 1982b). Nine monoclonals, which have been previously described, were used in an indirect immunofluorescence test (Pandolfi *et al.*, 1982c). In brief, OKT3 reacts with mature T cells (Reinherz & Schlossman, 1980); OKT4 with a subpopulation of T cells including the helper subset (Reinherz & Schlossman, 1980); OKT5, OKT8 (Reinherz & Schlossman, 1980) and Leu 2a (Evans *et al.*, 1981) with subpopulations including the T suppressor/cytotoxic cells; anti-Tac, recognizes activated cytotoxic killer T cells, suppressor cells and a subset of helper T cells (Uchiyama, Broder & Waldmann, 1981); OKM1 or M2 recognize monocytes (Breard *et al.*, 1980); OKT10 reacts with the majority of thymocytes and about 15% of bone marrow cells and it has been reported to recognize the majority of LGL (Ortaldo *et al.*, 1981). HNK-1 (Leu-7) identifies human LGL (Abo & Balch, 1981).

Cytocentrifuged preparations of PBMC were stained for peroxidase, acid phosphatase (AcP) and α -naphthyl acetate acid esterase (ANAE) as already reported (Semenzato *et al.*, 1979).

Identification of the LGL. This was performed by light and by transmission electron microscopy (TEM). For light microscopy (Strong *et al.*, 1982), air dried cytocentrifuged preparations were fixed

for 10 min in methanol and stained for 10 min with 10% Giemsa. LGL were identified as slightly larger than small lymphocytes. They had a relatively high cytoplasmic/nuclear ratio and weak basophilic cytoplasm with azurophilic granules. TEM was performed on 1% osmium tetroxide fixed PBMC, as described (Pandolfi *et al.*, 1982a).

Functional studies. Cytotoxic and suppressor activities on monocyte depleted PBMC isolated from the patients were studied as previously reported in detail: in brief, antibody-dependent cellular cytotoxicity (ADCC) (Pandolfi *et al.*, 1982a) against ⁵¹Cr-labelled chicken erythrocytes coated with anti-chicken erythrocyte IgG, was measured by counting the ⁵¹Cr release after 20 h incubation of erythrocytes and PBMC. Percentage of release obtained at 20:1 (effector:target) ratio, is reported. Natural killer (NK) activity was performed against the K-562 cell line as previously described (Pandolfi *et al.*, 1980).

In brief, effector PBMC were depleted of monocytes with carbonyl iron at 37°C, and then incubated with target cells at different effector:target ratios. Plates were incubated for 18 h at 37°C in a 5% CO₂ incubator and supernatant counted in a gamma spectrophotometer. Percentage of specific lysis at 100:1 effector:target cells ratio are reported according to the following formula:

$$\% \text{ of lysis} = \frac{A - B}{C - B} \times 100$$

where A = mean ct/min experimental release; B = mean ct/min of spontaneous release; C = mean ct/min experimental release.

Suppressor activity on pokeweed mitogen (PWM)-induced B cell differentiation was studied, as reported (Pandolfi *et al.*, 1982c) by adding several ratios of PBMC isolated from the patients, to a helper combination of B and T cells from a normal donor. PWM was added, the cultures incubated for 7 days, and the number of plasma cells determined on cytocentrifuged slides stained with the anti-human fluorescent Ig antibodies. Suppression was calculated as the percentage of variation between cultures containing cells from the patients in comparison to control cultures.

RESULTS

Table 1 reports the phenotypes as determined by rosette formation, FcγR and reactivity with monoclonal antibodies of PBMC from the five reported cases. All of them had high proportions of SRFC, PBMC from case 1 were characterized by high levels of FcγR, whereas monoclonal antibodies for T cells and monocytes were negative. Cases 2 and 3 had high levels of FcγR, OKT3 cells and cells bearing antigens expressed on cytotoxic suppressor cells (OKT8, OKT5, Leu 2a). Case 4 had low levels of FcγR, high proportions of OKT3 cells and significant percentages of both

Table 1. Clinical and immunological data of five patients with lymphoproliferative disorders of LGL

Sex	Age	Diagnosis	% Lymphocytes		Lymph/ cumm × 10 ³	% Positive on PBMC							
			PB	BM		SRFC	FcγR	OKT3	OKT4	OKT8	OKT5	Leu2a	
VL	M	33	CLL	75	35	17.0	80	53	16	<5	16	9	ND
EM	F	70	CLL	96	70	18.0	98	85	96	<5	93	ND	ND
MM	M	52	lymphoma	83	70	12.0	83	70	84	10	85	80	83
EDF	M	70	CLL	70	65	18.5	80	17	79	42	32	23	38
GB	F	50	lymphoma	75	28	25.0	82	80	72	<5	18	20	23
Normal donors (15)							69.0	12.2	63.3	44.8	26.6	21.2	25.3
							± 7.3	± 2.0	± 6.0	± 4.1	± 4.3	± 4.1	± 4.5

PB = peripheral blood; BM = bone marrow; ND = not done.

Table 2. Percentage of circulating LGL, surface markers, ANAE⁺ cells and summary of the functional activities of PBMC isolated from five patients with lymphoproliferative disorders

	% LGL	% Positive cells				% ANAE	% ADCC	% NK	% Suppression*
		HNK-1	OKT10	OKM2	OKM2				
VL	86	72	9	13	15	90	58	37%	
EM	58	70	36	<5	78	76	<15	84%	
MM	90	63	19	7	45	46	30	47%	
EDF	87	55	<5	9	80	17	40	no suppression	
GB	78	<5	10	75	30	79	20	62%†	
Normal donors (12)	15.0 ±2.0	16.1 ±5.6	7.2 ±2.0	13.4 ±4.0		65.5 ±3.7	50.1 ±4.8	±20%	

* On pokeweed mitogen induced B cell differentiation. Results showed represent % of suppression by adding 25% of PBMC isolated from the patients.

† Lack of spontaneous suppressor activity, but presence of 62% suppression upon activation with immune complexes (binding with ox erythrocytes coated with anti-ox erythrocytes IgG).

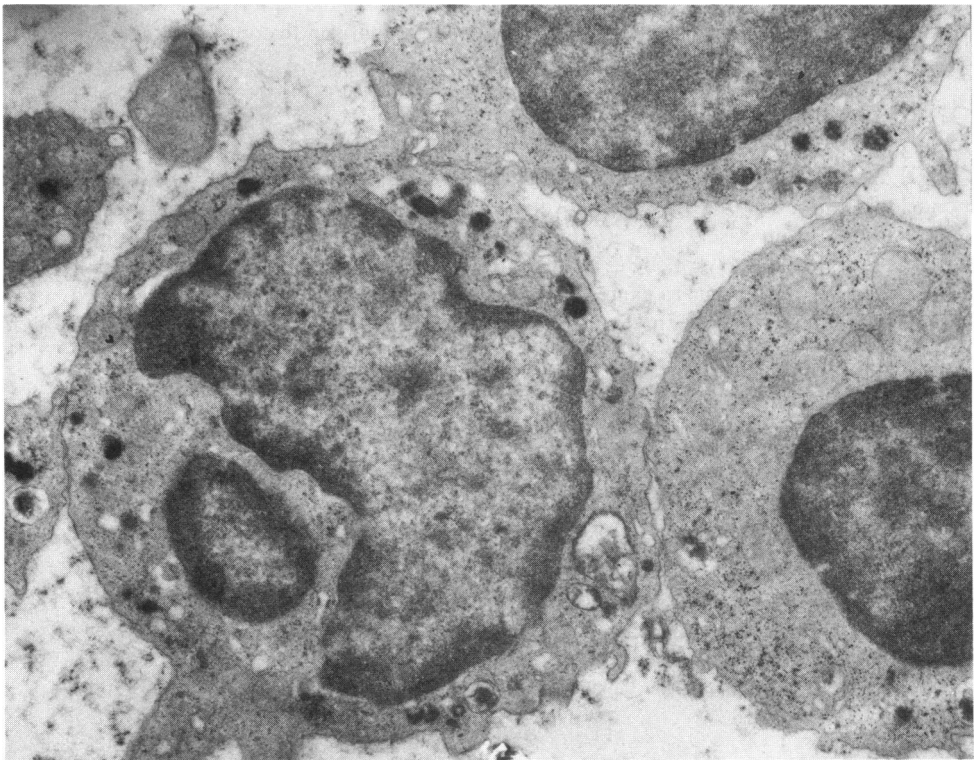


Fig. 1. TEM of PBMC isolated from case 1 (V.L.) ($\times 11,300$). The nucleus is irregularly round with heterochromatin. In the cytoplasm mitochondria and several scattered membrane bound granules containing an electron dense matrix are observed.

helper related (OKT4) and suppressor related (OKT8, OKT5, Leu 2a) markers. In case 5 high levels of Fc γ R and OKT3 positive cells were present, but only low numbers of OKT4, OKT8, OKT5 and Leu 2a cells. Anti-Tac monoclonal antibody was virtually unreactive with PBMC from all the cases (data not shown).

The percentages of LGL in the patient's PBMC as assessed by light microscopy, are reported in Table 2. These proliferating LGL were also studied by TEM. Representative features of case 1 and case 4 are reported in Figs 1 & 2. Essentially identical pictures were obtained by TEM in the majority of PBMC from the remaining cases. Table 2 shows the percentage of positive cells with monoclonal antibodies reported to be specific (HNK-1) or to bind to the majority of LGL. Cells positive with HNK-1 were highly increased in cases 1, 2, 3 and 4, but absent in case 5. OKT10 cells were slightly increased in cases 2 and 3 and OKM2 cells were increased in case 5.

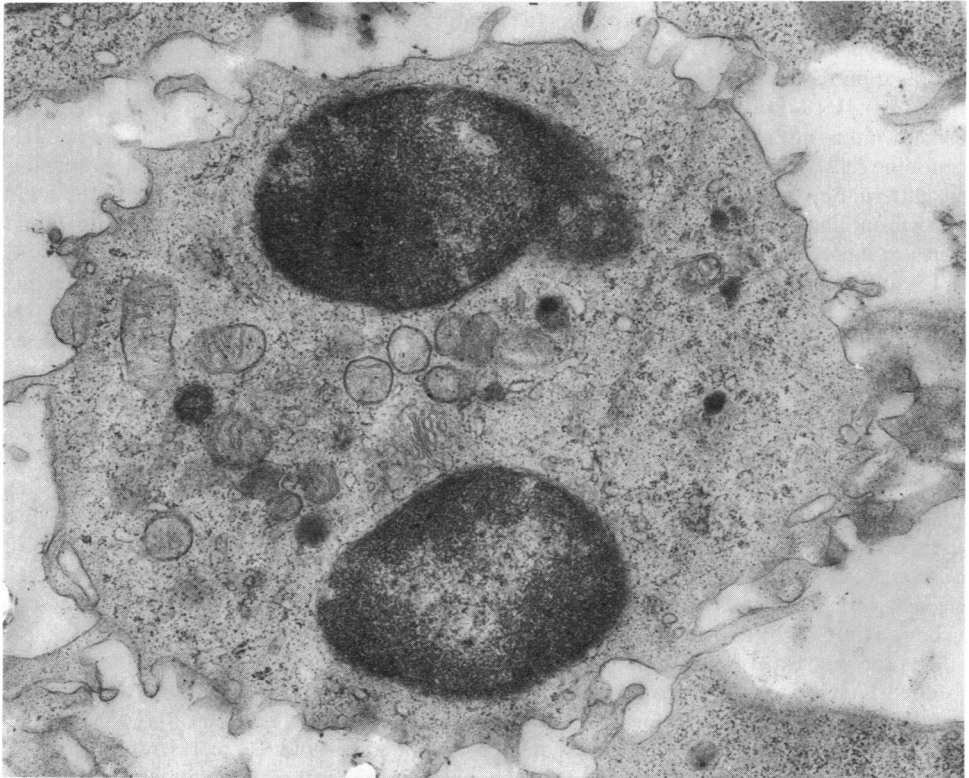


Fig. 2. TEM of PBMC isolated from case 4 (EDF) ($\times 15,600$) showing an abundant cytoplasm with mitochondria, a well developed Golgi apparatus, and electron dense granules.

Cytochemical studies showed low percentages ($< 15\%$) of peroxidase positive cells and high percentages ($> 75\%$) among PBMC isolated from all tested cases; ANAE positive cells were high in cases 2 and 4; 45% and 30% in cases 3 and 5 respectively, and only 15% of PBMC from case 1 were ANAE positive (Table 2).

In Table 2 the functional activities of these cells are also reported. Strong ADCC against chicken erythrocytes was observed in cases 1, 2 and 5. Natural killer (NK) activity was present, but not increased in three cases and reduced in cases 2 and 5. PBMC from cases 1, 2, 3 and 5 were able to suppress pokeweed-induced B cell differentiation, and in case 5, only upon activation of the patient's cells with immune complexes.

DISCUSSION

In the present report we demonstrate that half of the rare cases of sheep erythrocyte rosetting CLLs and/or non-Hodgkin lymphomas, consist of proliferation of LGL, as assessed by the morphology of PBMC isolated from these patients. Besides the features of LGL morphology, rosetting ability and the cytochemical patterns AcP⁺ and peroxidase⁻, which were present in PBMC from all cases, the other markers studied revealed large phenotype heterogeneity, possibly reflecting the heterogeneity of LGL at different levels of maturation. PBMC from four cases reacted with the monoclonal antibody HNK-1, reported to be specific for LGL (Abo & Balch, 1981). Emphasis must be placed on the fact that this reagent was unreactive on PBMC from three cases of OKT4 T-CLL cells (data not shown). Another monoclonal antibody (OKT 10) which has been shown to bind to the majority of normal LGL (Ortaldo *et al.*, 1981), was essentially unreactive with cells from four cases, and slightly positive in cells from case 2. In contrast to what is reported for normal LGL (non-reactivity with several T specific monoclonal antibodies) (Ortaldo *et al.*, 1981), three cases had a T phenotype, two of them (cases 2 and 3) appearing to be a highly purified subset of the T cell subpopulation that includes the cytotoxic/suppressor cells (demonstrated by the strong positivity with OKT8). HNK-1 positive, T-antigens bearing PBMC from case 4 were negative for Fc γ R; it has been shown that not all LGL possess Fc γ R (Abo & Balch, 1981) and normal Fc γ R negative, NK functioning cells are devoid of ADCC activity (Bolhuis *et al.*, 1978). PBMC from case 4 showed this same pattern: Fc γ R⁻, NK⁺, ADCC⁻. Cells from one case (case 1) showed low levels of both T and monocyte specific antigens, while they were HNK-1 positive and capable of *in vitro* cytotoxic and suppressor functions. These cells possibly represent the abnormal proliferation of a subset of SRFC (OKT3 and OKM negative) with NK activity which is present in normal donors (Zarling *et al.*, 1981). Finally, in one case (case 5) both OKT3 and OKM2 cells were present; while HNK-1 was undetectable. Further studies are in progress to clarify if T3 antigen is co-expressed with M2 antigen on the same cells. At present it is not possible to clarify if these patterns are related to small subsets of normal LGL or to the presence of abnormal co-expression of several molecules reacting with monoclonals on the surface of lymphoid cells in malignancies.

Different stages of cellular maturation are probably represented by these LGL. PBMC from all the patients did not express the thymocytic T6 antigen (data not shown) and therefore are probably not immature T cells. A different expression of ANAE activity, which becomes increasingly positive with maturation of normal lymphocytes (Basso *et al.*, 1980) and is present on normal mature LGL (Grossi *et al.*, 1982) was observed. Our results indicate that patients with LGL also expressing T cell antigens have higher levels of ANAE positive cells, whereas ANAE negative SRFC from case 1, which are HNK-1 positive do not express other T cell markers.

Thus far, our experience is limited to sheep erythrocyte rosetting LGL lymphoproliferative disorders, but it is conceivable that disorders of non-rosetting LGL will also be detected, since more than 50% of normal LGL do not form rosettes with sheep erythrocytes (Timonen *et al.*, 1981; Strong *et al.*, 1982). In conclusion, diseases which consist of a proliferation of LGL represent a remarkable proportion of the rare sheep rosetting CLL or lymphomas. Only further observations will elucidate possible peculiarities in the clinical pattern of these rare patients. Our data suggest an apparently favourable and extremely chronic course for patients with peripheral and bone marrow LGL lymphocytosis. Patients with LGL involvement of parenchymatous organs, (such as cases 3 & 5 in the present series) may have a more aggressive disease. Personal data also show that cells from these patients are capable of retaining some *in vitro* functions, and express different levels of maturation, according to their phenotype and enzymatic content. These LGL also show a vast heterogeneity of surface phenotypes and some of them clearly have T cell markers. The HNK-1 monoclonal antibody represents an important reagent for the identification of these cases, even if our data suggest that LGL from rare cases may be HNK-1 negative.

This work was supported by grants: 80.01461.96 and 81.01475.96 from the Consiglio Nazionale delle Ricerche, Italy; by the Istituto Pasteur-Fondazione Cenci-Bolognetti; and by grant 100.405 from the University of Padua.

We wish to thank Drs C.E. Grossi, M. Ferrarini, R.B. Herberman, M.D. Cooper and J. Ortaldo for their

encouragement and excellent discussion and Dr G. Basso for performing some of the cytochemical reactions. Monoclonal antibodies were kindly provided by Drs G. Goldstein and T.A. Waldmann. We also thank Mrs A.H. Constantine for expert editorial assistance.

REFERENCES

- ABO, T. & BALCH, C.M. (1981) A differentiation antigen of human NK and K cells identified by a monoclonal antibody (HNK-1). *J. Immunol.* **127**, 1024.
- AIUTI, F., CEROTTINI, J.C., COOMBS, R.A., COOPER, M.D., DICKER, H.B., FRÖLAND, S.S., FUDENBERG, H.H., GREAVES, M.F., GREY, H.M., KUNKEL, H.G., NATWIG, J.B., PREUD'HOMME, J.L., RABELLINO, E., RITTS, R.E., ROWE, D.S., SELIGMANN, M., SIEGAL, F.P., STJERNSWARD, J., TERRY, D. & WYBRAN, J. (1974) Identification, enumeration and isolation of B and T lymphocytes from human peripheral blood. *Scand. J. Immunol.* **3**, 521.
- BASSO, G., COCITO, M.G., SEMENZATO, G., PEZZUTTO, A. & ZANESCO, L. (1980) Cytochemical study of thymocytes and T lymphocytes. *Br. J. Haematol.* **44**, 577.
- BOLHUIS, R.L.H., SCHUIT, H.R.E., NOOYEN, A.M. & RONTETAP, C.P.M. (1978) Characterization of natural killer (NK) cells and killer (K) cells in human blood: discrimination between NK and K cell activities. *Eur. J. Immunol.* **8**, 731.
- BREARD, J., REINHERZ, E.L., KUNG, P.C., GOLDSTEIN, G. & SCHLOSSMAN, S.F. (1980) A monoclonal antibody reactive with human peripheral blood monocytes. *J. Immunol.* **124**, 1943.
- EVANS, R.L., WALL, D.W., PLATSOUCAS, C.D., SIEGAL, F.P., FIKRING, S.M., TESTA, C.M. & GOOD, R.A. (1981) Thymus dependent membrane antigens in man: inhibition of cell-mediated lympholysis by monoclonal antibodies to the TH₂ antigen. *Proc. Natl. Acad. Sci. USA.* **78**, 544.
- FERRARINI, M., CADONI, A., FRANZI, A.T., GHIGLIOTTI, G., LEPRINI, A., ZICCA, A. & GROSSI, C.E. (1980) Ultrastructure and cytochemistry of human peripheral blood lymphocytes. Similarities between the cells of the third population and T_H cells. *Eur. J. Immunol.* **10**, 562.
- GROSSI, C.E., WEBB, S.R., ZICCA, A., LYDYARD, P.M., MORETTA, L., MINGARI, M.C. & COOPER, M.D. (1978) Morphological and histochemical analysis of two human T-cell subpopulations bearing receptors for IgM and IgG. *J. exp. Med.* **147**, 1405.
- GROSSI, C.E., CADONI, A., ZICCA, A., LEPRINI, A. & FERRARINI, M. (1982) Large granular lymphocytes in human peripheral blood. *Blood*, **59**, 277.
- HAYNES, B.F., METZGAR, R.S., MINNA, J.D. & BUNN, P.A. (1981) Phenotypic characterization of cutaneous T-cell lymphoma. *N. Engl. J. Med.* **304**, 1319.
- ORTALDO, J.R., SHARROW, S.O., TIMONEN, T. & HERBERMAN, R.B. (1981) Determination of surface antigens of highly purified human NK cells by flow cytometry with monoclonal antibodies. *J. Immunol.* **127**, 2401.
- PANDOLFI, F., STRONG, D.M., SLEASE, R.B., SMITH, M.L., ORTALDO, J.R. & HERBERMAN, R.B. (1980) Characterization of a suppressor T-cell chronic lymphocytic leukemia with ADCC but not NK activity. *Blood*, **56**, 653.
- PANDOLFI, F., DE ROSSI, G., SEMENZATO, G., QUINTI, I., RANUCCI, A., DE SANCTIS, G., LOPEZ, M., GASPAROTO, G. & AIUTI, F. (1982a) Immunological evaluation of T-chronic lymphocyte leukemia cells. Correlations among phenotype, functional activities and morphology. *Blood*, **59**, 688.
- PANDOLFI, F., PEZZUTTO, A., DE ROSSI, G., PASQUALETTI, D., SEMENZATO, G., QUINTI, I., RANUCCI, A., RAIMONDI, R., BASSO, G., STRONG, D., FONTANA, L. & AIUTI, F. (1983) Characterization of two patients with lymphomas of large granular lymphocytes. *Cancer*, (In press.)
- PANDOLFI, F., QUINTI, I., DE ROSSI, G., FRIELINGS-DORF, A., TONIETTI, G., PASQUALETTI, D. & AIUTI, F. (1982b) A population of sheep rosetting cells lacking T- and monocytic-specific antigens, as detected by monoclonal antibodies. *Clin. Immunol. Immunopathol.* **22**, 331.
- PANDOLFI, F., SEMENZATO, G., DE ROSSI, G., STRONG, D.M., QUINTI, I., PEZZUTTO, A., MANDELLI, F., & AIUTI, F. (1982c) Heterogeneity of T-CLL defined by monoclonal antibodies in nine patients. *Clin. Immunol. Immunopathol.* **24**, 330.
- RAI, K.R., SAWITSKY, A., CRONKITE, E.P., CHANANA, A.D., LEVY, R.N., & PASTERNAK, B.S. (1975) Clinical staging of chronic lymphocytic leukemia. *Blood*, **46**, 219.
- REINHERZ, E.L. & SCHLOSSMAN, S.F. (1980) The differentiation and function of human T lymphocytes. *Cell*, **19**, 821.
- SEMENZATO, G., AMADORI, G., BASSO, G., COCITO, M.G., COLOMBATTI, M. & ANGLIANI, F., GASPAROTTO, G. (1979) Immunological features in chronic lymphocytic leukemia (CLL) of T cell origin. *J. clin. lab. Immunol.* **2**, 45.
- STRONG, D.M., ORTALDO, J.R., PANDOLFI, F., MALUISH, A. & HERBERMAN, R.B. (1982) Cryopreservation of human mononuclear cells for quality control in clinical immunology. I. Correlations in recovery of K and NK functions surface markers and morphology. *J. clin. Immunol.* **2**, 214.
- TIMONEN, T., ORTALDO, J.R. & HERBERMAN, R.B. (1981) Characteristics of human large granular lymphocytes and relationship to natural killer and K cells. *J. exp. Med.* **153**, 569.
- UCHIYAMA, T., BRODER, S. & WALDMANN, T.A. (1981) A monoclonal antibody (anti-Tac) reactive with activated and functionally mature human T cells. *J. Immunol.* **126**, 1393.
- ZARLING, J.M., CLOUSE, K.A., BIDDISON, W.E. & KUNG, P.C. (1981) Phenotypes of human natural killer cell populations detected with monoclonal antibodies. *J. Immunol.* **127**, 2575.