

BRIEF COMMUNICATION

**Reactivity of presumed anti-natural killer cell antibody
Leu 7 with intrafollicular T lymphocytes**

S. POPPEMA, LYDIA VISSER & L. DE LEIJ *Departments of Pathology and Immunology,
University of Groningen, Groningen, The Netherlands*

(Accepted for publication 4 July 1983)

SUMMARY

This report describes the presence of a T lymphocyte subpopulation in germinal centres of lymph follicles. This subpopulation is defined by reactivity with Leu 7 antibody, in addition to OKT11, OKT1, OKT3 and OKT4 positivity. The functional activity of this T lymphocyte subpopulation is a matter of discussion and has to be clarified by functional studies of purified populations of these cells.

Keywords germinal centre T lymphocytes natural killer cells

INTRODUCTION

Immunohistological staining techniques revealed the presence of T lymphocytes in germinal centres of follicles in lymphoid tissue of mouse (Gutman & Weissman, 1972) and man (Poppema *et al.*, 1981). It has been shown that in man these T lymphocytes express the helper cell phenotype (OKT11⁺, OKT3⁺, OKT4⁺) and not the suppressor–cytotoxic phenotype (OKT5⁻, OKT8⁻) (Poppema *et al.*, 1981). This finding seems to be in agreement with the apparent dependence of the germinal centre reaction on the presence of thymus processed lymphocytes (Jacobson, Caporale & Thorbecke, 1974).

Recently a monoclonal antibody reactive with a lymphocyte subset with azurophilic granules, comprising about 15% of peripheral blood lymphocytes and containing natural killer cell reactivity, was described (Abo & Balch).

Here we will describe reactivity of this monoclonal antibody with T lymphocytes in germinal centres of reactive lymphoid tissue and in nodules of follicular cell lymphoma.

MATERIALS AND METHODS

Frozen blocks of lymph nodes from five patients with non-specific lymphadenitis and two spleens, removed because of traumatic rupture, were studied. In addition frozen tissue of five cases of follicular centre cell lymphoma were studied. For immunohistological staining 5 µm thick cryostat sections were fixed in acetone for 10 min and incubated with 25 µl of mouse hybridoma antibody dilution (OKT11, OKT1, OKT3, OKT4, OKT5, OKT6, OKT8 or Leu 7), for 30 min. After a 5 min wash, the sections were incubated with 25 µl of a 1/20 dilution of horseradish peroxidase conjugated rabbit anti-mouse Ig antibody, supplemented with 1% human AB serum, for 15 min. After another wash the peroxidase activity was demonstrated by the aminoethylcarbazole method (Graham, Lundholm & Karnovsky, 1965). Sections were counterstained with Mayers hemalum and mounted

Correspondence: Dr S. Poppema, Department of Pathology, University of Groningen, Oostersingel 63, 9713 EZ Groningen, The Netherlands.

with Aquamount. In addition, sections were incubated with mixtures of OKT11 and Leu 7, OKT3 and Leu 7, OKT4 and Leu 7, or OKT8 and Leu 7, for 30 min.

Subsequently, sections were incubated with a mixture of fluorescein conjugated goat anti-mouse IgG (detecting OKT11, OKT3, OKT4 or OKT8, all being of the IgG subclasses) and rhodamin conjugated goat anti-mouse IgM, detecting Leu 7, which is of the IgM class. This procedure enables double labelling of the Leu 7 positive cells.

RESULTS

Germinal centres of lymph follicles in lymph nodes and spleens contained several T lymphocytes, as demonstrated by positive staining with OKT11, OKT1, and OKT3. No positive reaction was found with OKT6, an antibody reactive with cortical thymocytes. The vast majority of these intrafollicular lymphocytes appeared to be OKT4 positive and OKT5 and OKT8 negative. In addition, the germinal centres contained a population of Leu 7 positive lymphocytes, whereas only very few such cells were present in the paracortical, thymus-dependent areas (Fig 1). In the spleen, a moderate number of Leu 7 positive cells was found in the red pulp, none in the periarteriolar thymus-dependent periarteriolar lymphocyte sheaths and several in germinal centres.

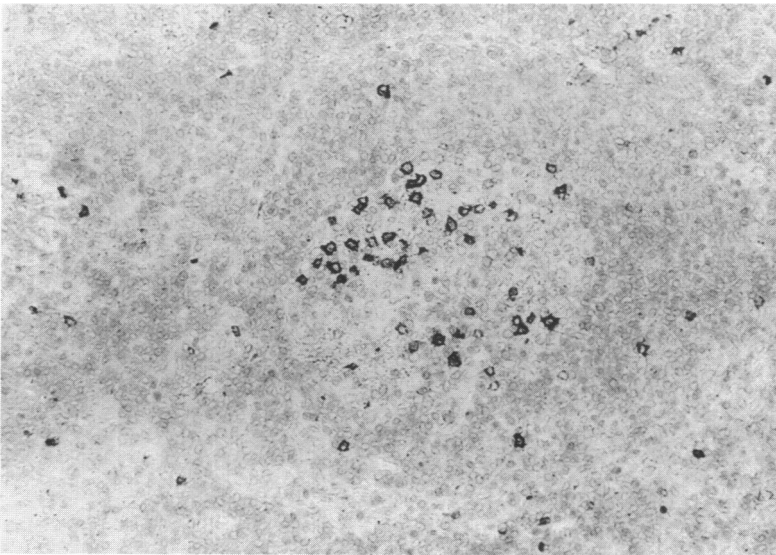


Fig. 1. Secondary follicle in lymph node with follicular hyperplasia, demonstrating the presence of several Leu 7 positive lymphocytes in the germinal centre (immunoperoxidase, $\times 140$).

Counting of the number of positive cells in serial sections, stained with OKT11 or Leu 7, or OKT11 and Leu 7 together, revealed that apparently all Leu 7 positive cells were contained in the OKT11 positive population, but that not all OKT11 positive cells were reactive with Leu 7 (Table 1). The numbers of OKT11, OKT1, OKT3 and OKT4 positive cells were about equal in the germinal centres in lymph nodes as well as in spleen. The double staining findings were in agreement with these results. Leu 7 positive cells in germinal centres were also reactive with OKT11, OKT3 and OKT4 (Fig. 2) but not with OKT8. Leu 7 positive cells outside follicles in the paracortex of lymph nodes and also in the red pulp of spleen were either negative with anti-T cell antibodies, or were reactive with OKT11, OKT3 and/or OKT8, but not with OKT4.

Nodules of follicular centre cell lymphomas contained several OKT11 positive, and also Leu 7 positive lymphocytes and therefore did not seem to be different from reactive germinal centres in this respect (Fig. 3).

Table 1. Quantitative analysis of cells reactive with Leu 7, OKT11 or Leu 7 and OKT11 in germinal centres of a reactive lymph node

Germinal centre*	Leu 7 ⁺	OKT11 ⁺	Leu 7 ⁺ + OKT11 ⁺
No. 1	15	21	23
No. 2	12	17	16
No. 4	35	44	47
No. 5	72	80	78
No. 8	36	47	50
No. 9	25	30	32
No. 12	49	56	53
No. 13	16	18	21
No. 14	91	100	96
No. 16	32	43	45
No. 18	56	62	67

* Only germinal centres which could be evaluated in three serial sections are represented.

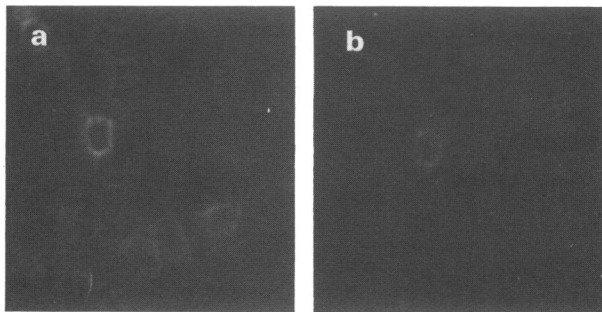


Fig. 2. Secondary follicle in lymph node stained for the presence of OKT4 positive lymphocytes with fluorescein labelled antibodies (a) showing several positive cells, and for the presence of Leu 7 positive lymphocytes with rhodamin labelled antibodies (b), showing that some of these OKT4 positive cells are also reactive with Leu 7 antibody ($\times 450$).

DISCUSSION

We have demonstrated the presence of a special T lymphocyte subset in germinal centres of reactive lymphoid tissue and in nodules of follicular centre cell lymphomas. This subset is characterized by reactivity with OKT11, OKT1, OKT3, OKT4 and Leu 7, and represents a large proportion of the intrafollicular T lymphocytes. The main difference with other peripheral T lymphocytes is the Leu 7 reactivity, which is absent from the T lymphocytes in paracortex and periarteriolar lymphocyte sheath of the spleen. So far, Leu 7 was thought to be specific for lymphocytes containing azurophilic granules, exhibiting natural killer activity (Abo & Balch, 1981). Only a slight overlap with OKT3 and OKT8 positive lymphocyte populations was recorded. The unexpected activity with OKT1, OKT3, OKT4 positive lymphocytes practically restricted to germinal centres, cannot be explained by present knowledge. One possible explanation may be that the antigenic determinant recognized by Leu 7 is an expression of lymphocyte activation, since it has been reported that activated T lymphocytes may have natural killer cell activity (Seeley & Karre, 1980). This would implicate that germinal centre T lymphocytes are in an activated state, and thereby differ from the T lymphocytes in non-follicular areas. The demonstration of reactivity of anti-Ia antibodies with T lymphocytes in

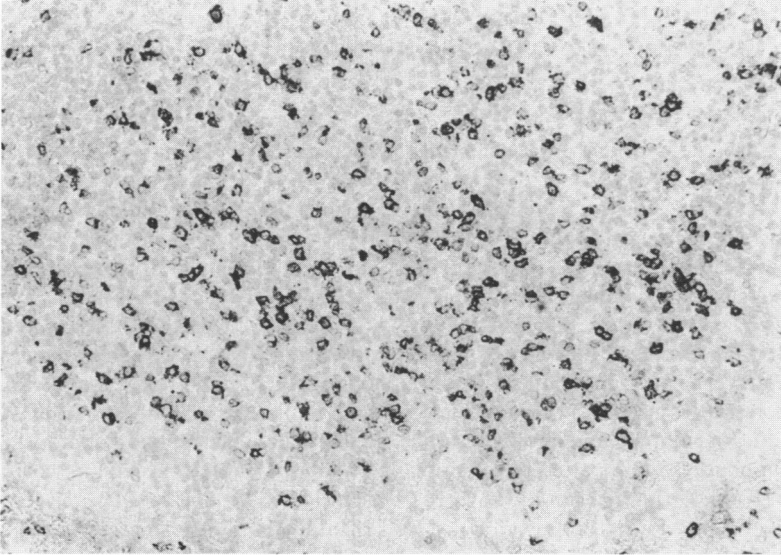


Fig. 3. Nodule of follicular cell lymphoma, demonstrating a similar population of Leu 7 positive cells as in a reactive germinal centre (immunoperoxidase, $\times 140$).

follicles could be in agreement with this idea (Stein, Bonk & Tolksdorf, 1980). It has been suggested that some natural killer cells may act as regulators of differentiation of haematopoietic cells (Cudkowicz & Hochman, 1979). Nabel, Allard & Cantor (1982) recently described a cloned cell line mediating natural killer cell function, that inhibits immunoglobulin secretion and suggested that this mechanism plays a role in the regulation of antibody response. Whatever the explanation may be, the presence of a recognizable subpopulation of Leu 7 positive T lymphocytes in germinal centres is a finding of potential importance. By means of fluorescence activated cell sorting it should be possible to isolate these cells and to define their morphological and functional characteristics.

REFERENCES

- ABO, T & BALCH, C.M. (1981) A differentiation antigen of human NK and K cells identified by a monoclonal antibody (HNK-1). *J. Immunol.* **127**, 1024.
- CUDKOWICZ, G. & HOCHMAN, P.S. (1979) Do natural killer cells engage in regulated reactions against self to ensure homeostasis? *Immunol. Rev.* **44**, 13.
- GRAHAM, R.C., LUNDHOLM, U. & KARNOVSKY, M.J. (1965) Cytochemical demonstration of peroxidase activity with 3-amino-9-ethylcarbazole. *J. Histochem. Cytochem.* **13**, 150.
- GUTMAN, G.A. & WEISSMAN, I.L. (1972) Lymphoid tissue architecture. Experimental analysis of the origin and distribution of T-cells and B-cells. *Immunology*, **23**, 465.
- JACOBSON, E.B., CAPORALE, C.H. & THORBECKE, G.J. (1974) Effect of thymus cell injections on germinal center formation in lymphoid tissues of nude (thymusless) mice. *Cell. Immunol.* **13**, 416.
- NABEL, G., ALLARD, W.J. & CANTOR, H. (1982) A cloned cell line mediating natural killer cell function inhibits immunoglobulin secretion. *J. exp. Med.* **156**, 658.
- POPPEMA, S., BHAM, A.K., REINHERZ, E.L., MCCLUSKEY, R.T. & SCHLOSSMAN, S.F. (1981) Distribution of T-cell subsets in human lymph nodes. *J. exp. Med.* **153**, 30.
- SEELEY, J.K. & KARRE, K. (1980) MLC-induced cytotoxicity against NK-sensitive targets. In *Natural cell-mediated immunity against tumors* (ed. by R. B. Herberman) p. 477. Academic Press, New York.
- STEIN, H., BONK, A. & TOLKSDORF, G. (1980) Immunohistologic analysis of the organization of normal lymphoid tissue and non-Hodgkin lymphomas. *J. Histochem. Cytochem.* **28**, 746.