

## The fine structure of normal lymphocyte subpopulations—a study with monoclonal antibodies and the immunogold technique

E. MATUTES & D. CATOVSKY *MRC Leukaemia Unit, Royal Postgraduate Medical School, Ducane Road, London, UK*

(Accepted for publication 18 June 1982)

### SUMMARY

The ultrastructural characteristics of normal lymphocyte subpopulations, identified by monoclonal antibodies and visualized by a colloidal gold labelled anti-mouse IgG were analysed. Our study demonstrates: (1) the major T lymphocyte subsets (OKT4<sup>+</sup> and OKT8<sup>+</sup>) have distinct ultrastructural morphology. The majority of OKT4<sup>+</sup> cells have a high nuclear/cytoplasmic ratio (N/C) and few cytoplasmic organelles whilst most OKT8<sup>+</sup> cells have a low N/C ratio and numerous organelles, namely a well developed Golgi apparatus, lysosomal granules and parallel tubular arrays (PTA); (2) a unique subtype with irregular nuclear outline that resembles Sézary cells was seen in 5–10% of OKT4<sup>+</sup> lymphocytes; (3) OKM1, a reagent that reacts with monocytes and granulocytes, is positive in a small lymphocyte subset which appears to be negative with the OKT reagents and is morphologically identical to OKT8<sup>+</sup> cells; (4) 'hand-mirror' cells were only seen labelled with OKT8 and OKM1; (5) B lymphocytes labelled with FMC4 (anti-IA) could be distinguished from OKT3<sup>+</sup> lymphocytes by having numerous profiles of endoplasmic reticulum (ER) and ribosomes; these were particularly prominent in lymphoplasmacytoid cells. Morphological similarities between normal T lymphocyte subsets and T neoplasias of the same membrane phenotype suggest that these disorders arise from specific T cell types present in normal peripheral blood or from common precursors.

### INTRODUCTION

Functional and morphological differences in normal human blood lymphocytes according to their membrane receptors have been reported (Moretta *et al.*, 1977; Grossi *et al.*, 1978; Ferrarini *et al.*, 1980). Two major cell types within normal T (E<sup>+</sup>) lymphocytes can be distinguished: cells that have receptors for the Fc portion of IgM (T $\mu$ ) and those with receptors for the Fc portion of IgG (T $\gamma$ ). T $\mu$  lymphocytes are characterized morphologically by their high N/C ratio and few cytoplasmic organelles whereas T $\gamma$  cells, with suppressor and cytotoxic functions, have lower N/C ratio with numerous granules and cytoplasmic structures (Grossi *et al.*, 1978; Ferrarini *et al.*, 1980). More recently, Van der Loo, Cnossen & Meijer (1981) have characterized T $\delta$  lymphocytes (E<sup>+</sup> cells without receptors for the Fc portion of IgG or IgM) as an heterogeneous population. Some cells resembling T $\mu$ , T $\gamma$  lymphocytes and a special cell type called 'cerebriform mononuclear cell' can be found within the T $\delta$  population.

Since human blood lymphocytes have been immunologically characterized by a series of monoclonal antibodies (Reinherz *et al.*, 1979, 1980a), no studies have been reported on morphological differences between these cell populations. We have analysed the ultrastructural

Correspondence: Dr D. Catovsky, MRC Leukaemia Unit, Royal Postgraduate Medical School, Ducane Road, London W12 0HS, UK.

features of the normal blood T lymphocytes defined by the OKT monoclonal antibodies OKT3<sup>+</sup>, OKT4 (helper/inducer cell subset) and OKT3<sup>+</sup>, OKT8<sup>+</sup> (suppressor/cytotoxic cell subset) and visualized by a colloidal gold labelled anti-mouse IgG (De Mey *et al.*, 1982). We have also studied OKM1 (Breard *et al.*, 1980), a reagent whose reactivity in lymphocytes has not been established by ultrastructural studies and FMC4 (anti-Ia like) to identify B lymphocytes (Beckman *et al.*, 1980).

The aim of the present work has been to see if the normal lymphocyte subpopulations have in addition to their different membrane antigens and immunological functions, different morphological characteristics when viewed under the electron microscope and to define the ultrastructural characteristics of OKM1 reactive lymphocytes, which have been identified at light microscopy as a 'large granular lymphocyte' (LGL) (Timonen, Ortaldo & Herberman, 1981).

## MATERIALS AND METHODS

*Lymphocyte cell suspensions.* Mononuclear cells from five normal donors were isolated on a Lymphoprep (Nyegaard) gradient. Cells were washed three times in medium Tc199 (Wellcome) and fixed for 5 min in 1% glutaraldehyde in 0.1 M cacodylate buffer (pH 7.4). Following two washes in 0.1 M cacodylate buffer (pH 7.4), cells were resuspended in medium Tc199 ( $5 \times 10^6$  cells/ml).

*Monoclonal antibody studies.* The monoclonal antibodies used were: OKT3, OKT8, OKT4 (Orthoclone) to identify T cell subsets (Reinherz *et al.*, 1979, 1980a, 1980b); OKM1 (Orthoclone), for labelling monocytes, neutrophils and a proportion of T $\gamma$  lymphocytes (Abo & Balch, 1981, Kay & Horowitz, 1980) in four experiments; FMC4 (gift from Dr H. Zola), an anti-Ia like reagent (Beckman *et al.*, 1980), to study B cells in three experiments.

Mononuclear cells were incubated, after fixation, with the monoclonal antibody (5  $\mu$ l for  $1 \times 10^6$  cells) for 30 min at 4°C and washed three times in medium Tc199. Cells were resuspended in a goat anti-mouse IgG coupled to 40 nm colloidal gold particles (gift from Dr J. De Mey) for 60 min at 4°C and washed twice in 0.05 M Tris-saline buffer containing 0.2% bovine serum albumin (BSA) (Sigma) and 0.02 M sodium azide (pH 8.2). The specificity of the labelling was checked in controls where the first antibody layer was omitted. The immunogold method was based on De Mey *et al.*, (1982).

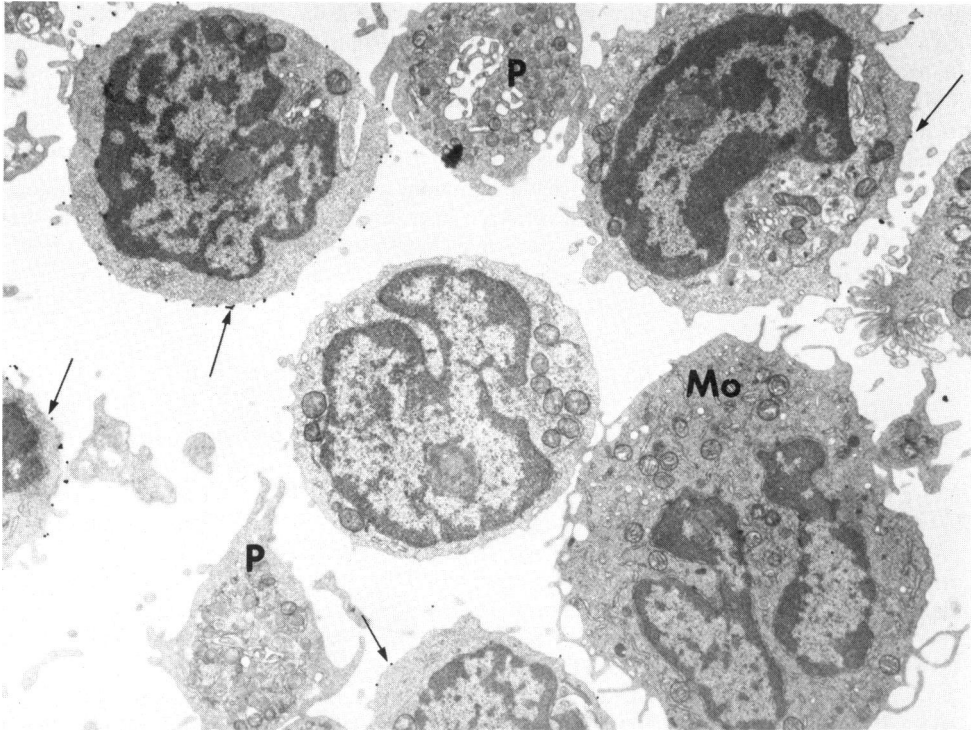
*Ultrastructural studies.* Following the antibody incubations, cell suspensions were fixed in 1% glutaraldehyde in 0.1 M cacodylate buffer (pH 7.4). Cells were post-fixed in 1% buffered osmium tetroxide in Millonigs medium, dehydrated in a graded series of alcohols and embedded in Araldyte. Ultrathin sections of approximately 60 nm (silver) were stained with 5% uranyl acetate and lead citrate and examined with a AE1 or Zeiss 10 electron microscope.

Observations were made in serial sections on 300–500 cells from each donor and for each reagent. A cell was said to be labelled (positive) if it had several gold particles (at least three) attached to the surface. In previously unfixed cells the gold particles are distributed in patches on the surface (De Mey *et al.*, 1982). In the procedure used here, with a short fixation prior to incubation with the monoclonal antibodies, the disposition of the gold is more uniform over the whole cell surface. There was no background staining and the distinction between positive and negative cells could be easily seen (Fig. 1). Cells in the control experiments did not shown gold labelling.

## RESULTS

The main distinguishing features between the lymphocytes positive with the various reagents are summarized in Table 1.

The majority of OKT8 reacting lymphocytes (c 60%) had an eccentric nucleus with abundant heterochromatin and regular nuclear outline. A small nucleolus was infrequently seen (< 10% of OKT8<sup>+</sup>). The cytoplasm, relatively abundant, had numerous and large mitochondria and a prominent Golgi apparatus. Several lysosome-like granules (1–12 per section) of different size and density were identified in 60–80% of OKT8<sup>+</sup> cells. The granules were localized in the Golgi zone or were scattered through the cytoplasm (Fig. 2). A minority of these OKT8 reactive cells (10–15%) in



**Fig. 1.** Low power view of the immunogold staining using 40 nm gold particles. This sample was stained with 3A1 (Haynes *et al.*, 1981) that reacts with most blood T lymphocytes. Four lymphocytes are seen labelled (arrows) and one is negative (centre). A monocyte (Mo) and two platelets (P) are also negative (uranyl acetate and lead citrate stain,  $\times 6,200$ ).

four out of five cases contained parallel tubular arrays (PTA) (Fig. 3) and less frequently vesicles, vacuoles, Gall bodies and multivesicular bodies. Profiles of endoplasmic reticulum (ER), when observed ( $< 30\%$  of cells), were few and short. A proportion of OKT8<sup>+</sup> lymphocytes presented a 'hand-mirror' configuration, showing in the uropod or tail numerous pinocytotic vesicles and vacuoles, but were, in all other respects similar to the other OKT8<sup>+</sup> cells. 'Hand-mirror' lymphocytes were never seen labelled with OKT4.

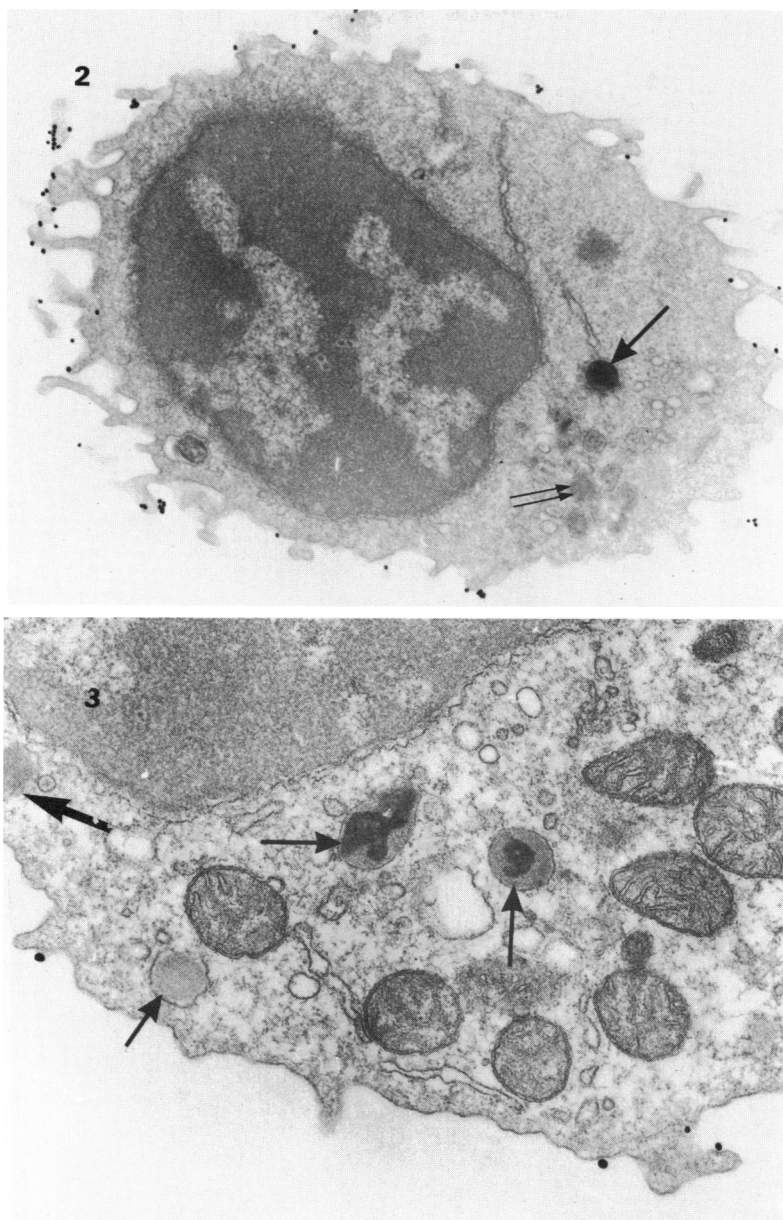
Lymphocytes reactive with OKT4 had less abundant cytoplasm and as a result a higher N/C ratio than OKT8<sup>+</sup> cells (a low N/C ratio was only seen in 10% of the OKT4<sup>+</sup> lymphocytes). The nucleus had a regular or slightly indented outline ( $> 70\%$ ) but in the remaining OKT4<sup>+</sup> cells, several

**Table 1.** Summary of findings in OKT4, OKT8, OKM1 and FMC4 reacting lymphocytes

Membrane phenotype	Low N/C ratio	Irregular nuclear outline	Chromatin condensation	Nucleolus	Granules	Golgi apparatus	PTA	ER	Special cell subtype
OKT3 <sup>+</sup> ,OKT4 <sup>+</sup>	+/-	++	+	++	++	+/-	-	+	'Cerebriform'
OKT3 <sup>+</sup> ,OKT8 <sup>+</sup>	+++	+	+++	+/-	+++	++	+	+	'Hand-mirror'
(OKT3 <sup>-</sup> ),OKM1 <sup>+</sup>	+++	-	+++	+/-	+++	++	+	+	'Hand-mirror'
(OKT3 <sup>-</sup> ),FMC4 <sup>+</sup>	+	-	++	+	++	+	-	+++*	'Lymphoplasmacytoid'

% of lymphocytes: +/- = 10, + =  $< 25$ , ++ = 25-50, +++ = 50-75.

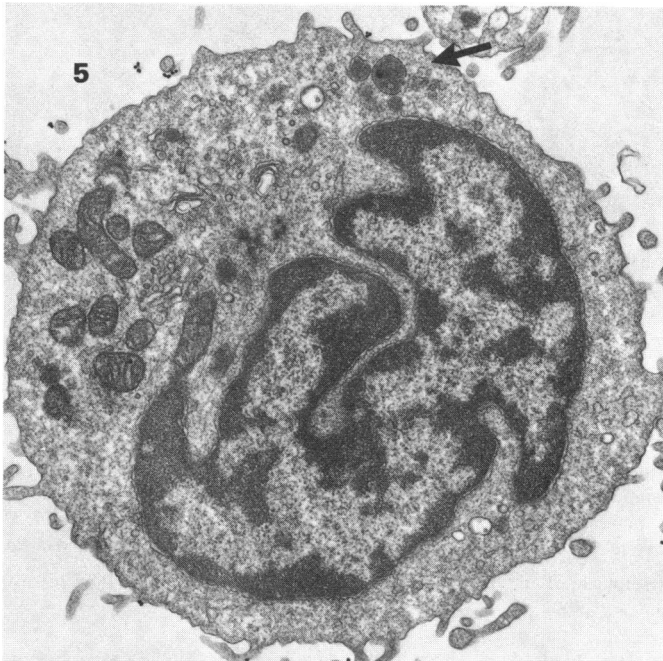
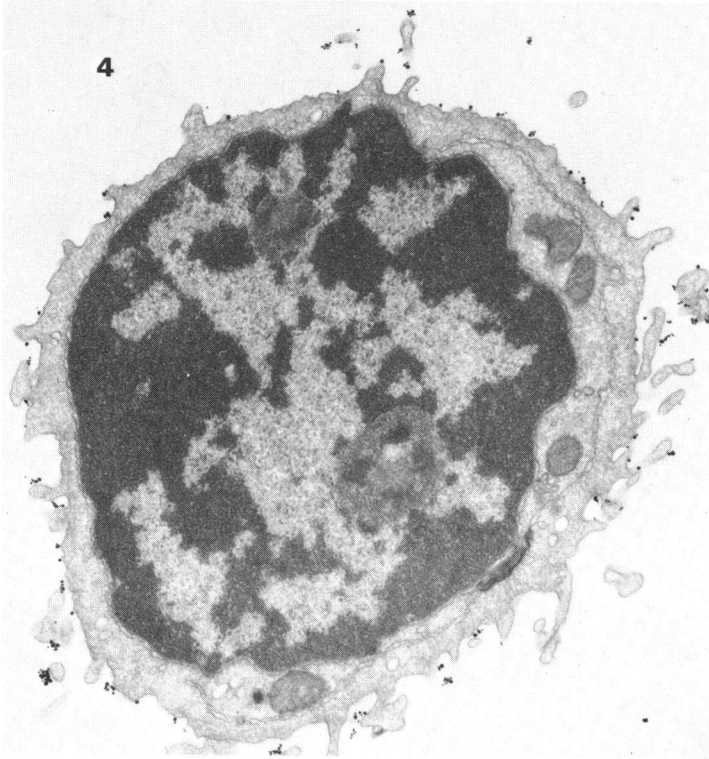
\* long and numerous



**Fig. 2.** T lymphocyte reacting with the OKT8 monoclonal antibody and labelled with a goat anti-mouse IgG coupled to 40 nm colloidal gold particles. The cell shows condensed nuclear chromatin and abundant cytoplasm containing various membrane bound parallel tubular arrays (PTA, two arrows), an electron dense granule (arrow) and several vesicles. PTA are seen more clearly in Fig. 3 (Uranyl acetate and lead citrate stain,  $\times 11,700$ ).

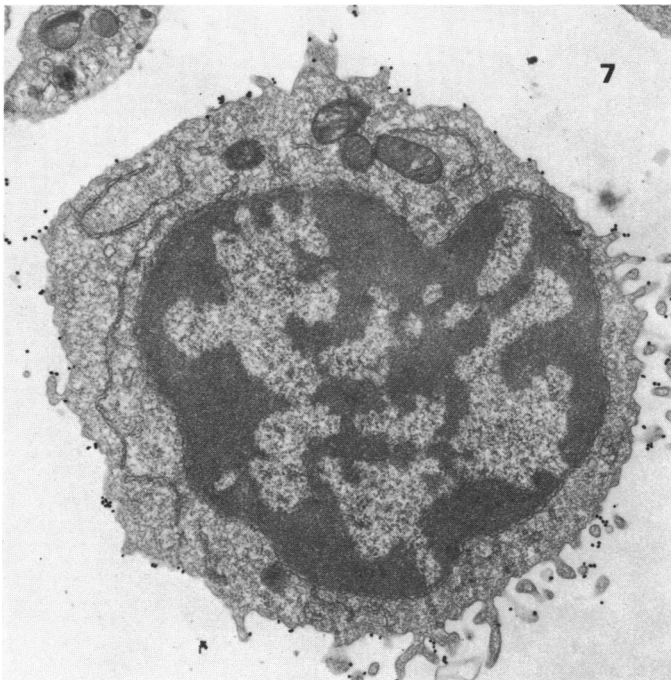
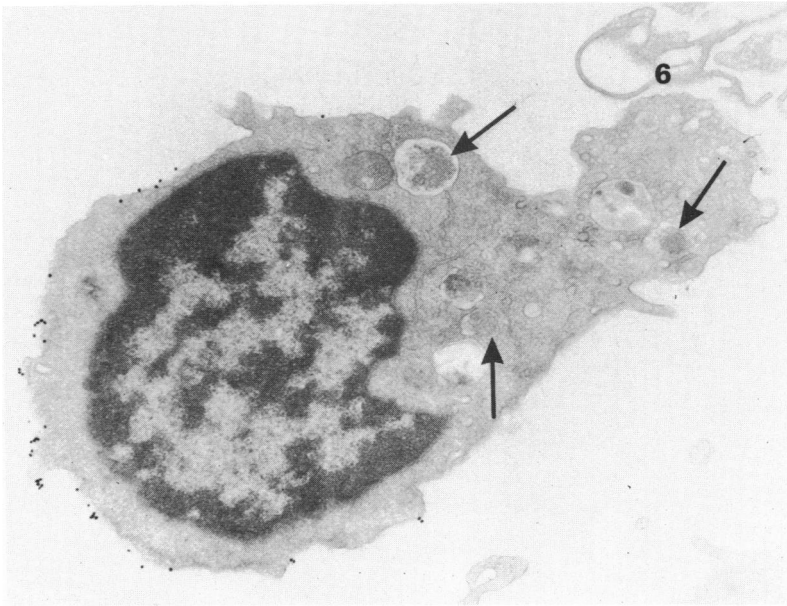
**Fig. 3.** Part of the cytoplasm of an OKT8 positive lymphocyte showing several PTA (arrows) (Uranyl acetate and lead citrate stain  $\times 27,000$ ).

degrees of nuclear irregularity were observed. The majority of OKT4<sup>+</sup> lymphocytes (60–80%) had less chromatin condensation than OKT8<sup>+</sup> cells and in >25% of them, a small ring shaped nucleolus was seen (Fig. 4). Few large or medium size granules (1–5 per section), often localized in one area, were observed in 40% of OKT4<sup>+</sup> cells. Occasional Gall bodies, multivesicular bodies, strands of ER and few mitochondria were identified in their cytoplasm. In contrast to OKT8<sup>+</sup> lymphocytes, the



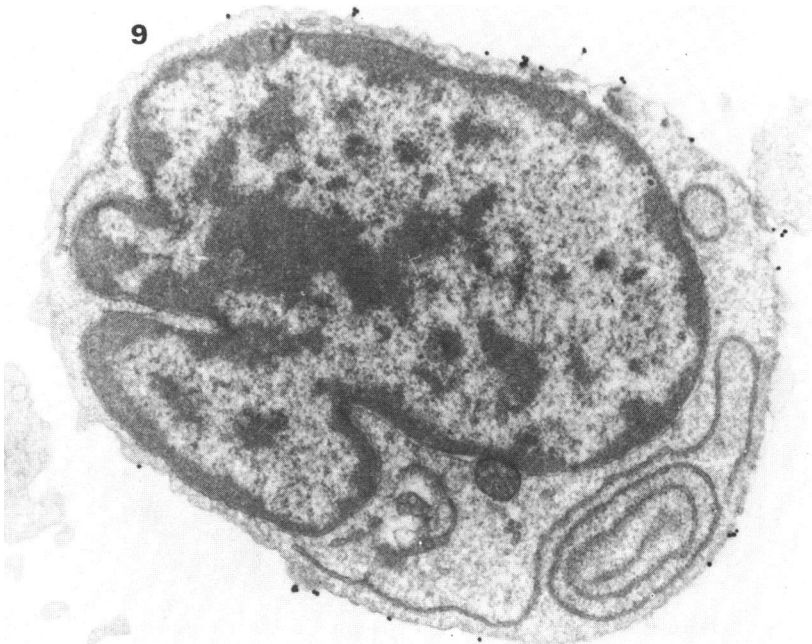
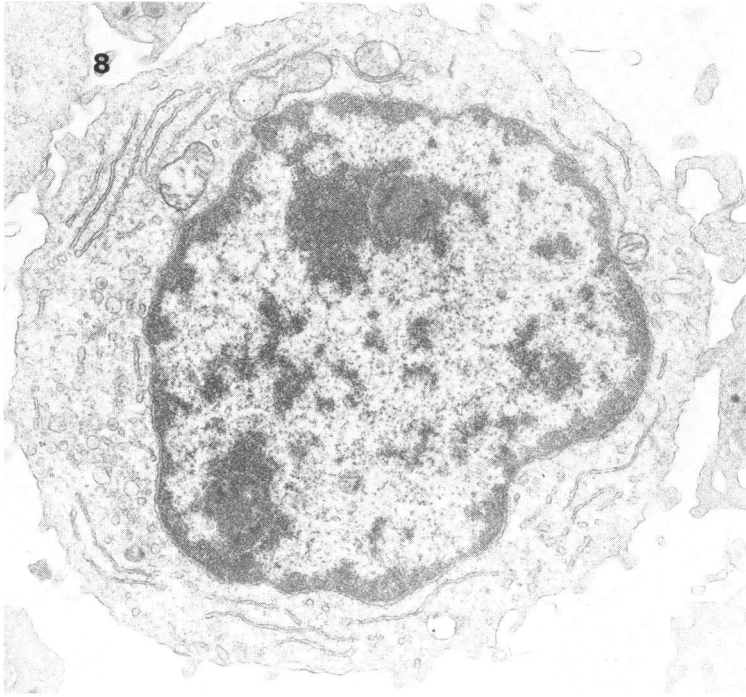
**Fig. 4.** Lymphocyte reactive with OKT4 showing a high nuclear-cytoplasmic ratio, two small nucleoli and few cytoplasmic organelles. (Uranyl acetate and lead citrate stain,  $\times 11,700$ ).

**Fig. 5.** OKT4 positive lymphocyte showing a characteristic 'cerebriform' nucleus, a prominent Golgi area and few localized lysosomal granules in the cytoplasm (arrows). As in most cells reactive with OKT4, few gold particles are seen on the cell membrane. (Uranyl acetate and lead citrate stain,  $\times 11,700$ ).



**Fig. 6.** Lymphocyte reactive with OKM1 showing 'hand-mirror' configuration. Several PTA (arrows) and multiple vesicles can be identified, mainly in the uropod. OKM1 positive lymphocytes are morphologically identical to OKT8 positive cells. (Uranyl acetate and lead citrate stain,  $\times 11,700$ ).

**Fig. 7.** OKT3 reacting lymphocyte with numerous gold particles on the cell membrane. Profiles of endoplasmic reticulum and mitochondria can be seen in the cytoplasm. The morphology of this cell corresponds to those with a 'helper' phenotype (OKT3<sup>+</sup>, OKT4<sup>+</sup>) (Uranyl acetate and lead citrate stain,  $\times 11,700$ ).



**Fig. 8.** Lymphocyte unreactive with OKT3 showing little chromatin condensation and two small nucleoli. Multiple vesicles and perinuclear distribution of endoplasmic reticulum are seen in the cytoplasm. The morphology of this cell corresponds to B lymphocytes described as 'lymphoplasmacytoid'. (Uranyl acetate and lead citrate stain,  $\times 11,700$ ).

**Fig. 9.** B lymphocyte reactive with FMC4 (anti-Ia) showing a slightly indented nuclear outline and long strands of endoplasmic reticulum. (Uranyl acetate and lead citrate stain,  $\times 11,700$ ).

Golgi area was inconspicuous (> 50%) and PTA were never observed in OKT4<sup>+</sup> cells. Five to ten percent of OKT4 labelled lymphocytes in every case had a deeply invaginated or 'cerebriform' nucleus. The cytoplasm contained medium or large granules, as other OKT4<sup>+</sup> cells but also microfibrils (Fig. 5). These cells, closely resembling Sézary cells (Van der Loo *et al.*, 1981) were never seen labelled with OKT8.

A small proportion (5–10%) of normal blood lymphocytes were reactive with OKM1. These cells showed morphological features indistinguishable from those seen in OKT8<sup>+</sup> cells including cells with the 'hand-mirror' configuration (seen in three out of four normals) (Fig. 6). A minority (c. 10%) had a high nucleo-cytoplasmic ratio with few or no cytoplasmic organelles.

The majority of monocytes and granulocytes were also reactive with OKM1 but they showed a higher number of gold particles attached to the membrane than lymphocytes. Monocytes were easy to recognise because of their characteristic lysosomal granules and fine villi.

Lymphocytes reacting with OKT3 showed both the morphological features observed in OKT4<sup>+</sup> and OKT8<sup>+</sup> cells but with more numerous colloidal gold particles attached to the membrane (Fig. 7); cells not reacting with any of the three antibodies OKT8, OKT4 and OKT3 were: (1) a minority of lymphocytes characterized by a mature nucleus, a cytoplasm with numerous vesicles, mitochondria and PTA as well as the other features seen in OKT8<sup>+</sup> cells; these cells probably correspond to the OKM1<sup>+</sup> lymphocytes; (2) cells with well developed endoplasmic reticulum, as well as those described as 'lympho-plasmacytoid' (Müller-Hermelink & Lennert, 1978) (Fig. 8), with features consistent with B cells; (3) monocytes (Fig. 1) which were positive with OKM1 and (4) occasional normal plasma cells.

The majority of FMC4 reactive (Ia-like) lymphocytes (> 60%) showed as OKT4<sup>+</sup> cells, a high N/C ratio and a nucleus with regular or indented outline. A small nucleolus was identified in 15% of the cells. The most characteristic features of FMC4<sup>+</sup> lymphocytes were the presence of numerous and long ER profiles and/or clusters of ribosomes in over 50% of cells (Fig. 9) and localized non-electron dense granules, some of them vesicle-like (c. 40%). Occasional multivesicular bodies, vacuoles and mitochondria were also seen. Lymphocytes described as 'lymphoplasmacytoid' showing little chromatin condensation, the presence of one or two nucleoli and perinuclear formation of endoplasmic reticulum were seen always as FMC4 reactive (5–10% of the FMC4<sup>+</sup> cells). Cells in the control experiments did not show gold labelling.

## DISCUSSION

Several workers have suggested morphological differences in human blood lymphocytes according to their membrane receptors (Grossi *et al.*, 1978; Ferrarini *et al.*, 1980; Poore *et al.*, 1981) but this is the first report in which the ultrastructural features of cells corresponding to normal lymphocyte subpopulations and defined by monoclonal antibodies are described. Our observations indicate that normal T and B lymphocytes have different morphological features and that within the T cells, each of the two major T cell subsets has, in addition to different immunological functions, membrane antigens (Reinherz *et al.*, 1979, 1980a, 1980b) and patterns of tissue distribution (Janossy *et al.*, 1980), a distinct morphology when viewed under the electron microscope.

The most characteristic findings in B lymphocytes (FMC4<sup>+</sup>) were the presence of numerous and long strands of ER and/or ribosomes, previously observed in isolated normal B lymphocytes (cells with surface immunoglobulins) (Ferrarini *et al.*, 1980). Such cells were not observed within OKT reactive lymphocytes. A minority of FMC4<sup>+</sup> cells are known as 'lymphoplasmacytoid' cells (Müller-Hermelink & Lennert, 1978) because of the abundant perinuclear profiles of rough endoplasmic reticulum; these cells probably represent an intermediate state between B cells and plasma cells.

Ultrastructural features in T lymphocytes with the 'suppressor-cytotoxic' phenotype (OKT3<sup>+</sup>, OKT8<sup>+</sup>) and in those with 'natural killer' (NK) activity (OKM1<sup>+</sup>, OKT3<sup>-</sup>) (Kay & Horowitz, 1980; Reinherz *et al.*, 1980b) were the presence of numerous organelles and PTA in the cytoplasm. PTA have been previously described in lymphocytes bearing receptors for the Fc portion of IgG (Ty



cells) (Costello *et al.*, 1980; Halie *et al.*, 1979; Huhn *et al.*, 1978; McKenna *et al.*, 1977; Payne & Glasser, 1981). Other morphological features of T $\gamma$  cells Grossi *et al.*, 1978; Ferrarini *et al.*, 1980) are also similar to those seen here in OKT8<sup>+</sup> and in OKM1<sup>+</sup> lymphocytes. This is not surprising since a portion of T $\gamma$  cells (60%) react with OKM1 (Abo & Balch, 1981; Kay & Horwitz, 1980) and another fraction is reactive with OKT8 (Callard *et al.*, 1981). Thus, OKM1<sup>+</sup> lymphocytes, which were identified at light microscopy as a 'large granular lymphocyte' (LGL) (Timonen *et al.*, 1981) show ultrastructural features that clearly support their lymphoid lineage.

Our findings also confirm that lymphocytes with Fc $\gamma$  receptors, which are known to be heterogeneous with respect to membrane antigens and function (Callard *et al.*, 1981; Reinherz *et al.*, 1980b; Timonen *et al.*, 1981) appear nevertheless to have uniform morphology (Grossi *et al.*, 1978; Ferrarini *et al.*, 1980). This raises the issue of the role of some organelles (e.g. PTA) in specialized cell functions such as cytotoxicity (e.g. NK and K cell activity). Findings in normal and neoplastic proliferations of T $\gamma$  lymphocytes confirm this morphological identity. For example both in six patients with T cell chronic lymphocytic leukaemia (T-CLL) with the membrane phenotype T $\gamma$ <sup>+</sup>, OKT3<sup>+</sup>, OKT8<sup>+</sup> (Crockard *et al.*, 1982), and in one case of T-CLL with the phenotype T $\gamma$ <sup>+</sup>, OKT3<sup>-</sup>, OKM1<sup>+</sup> (Dr Melief, personal communication), we have shown that the morphology of the leukaemia was identical to that of the OKT8<sup>+</sup>, OKM1<sup>-</sup> and the OKT8<sup>-</sup>, OKM1<sup>+</sup> subsets of normal blood, including the presence of numerous PTA. These cells also closely resemble the 'atypical' lymphocyte of infectious mononucleosis which has also been shown to be T $\gamma$  and OKT8<sup>+</sup> (De Waele, Thielemans & Van Camp, 1981) and to have abundant PTA at ultrastructural level (McKenna *et al.*, 1977).

A small proportion of OKT4 reacting lymphocytes have ultrastructural features resembling those of the characteristic Sézary cell. This may be significant because the origin of the Sézary cell is unknown and its normal counterpart has not hitherto been recognized. In another ultrastructural study, but without monoclonal antibodies, a small percentage of 'cerebriform' cells were described in the peripheral blood of normal individuals (Van der Loo *et al.*, 1981). We have confirmed this finding and have shown in addition that this cell type is OKT3<sup>+</sup> and OKT4<sup>+</sup>, which corresponds to the membrane phenotype found in Sézary cells (Haynes *et al.*, 1981). Thus, it is possible that the neoplastic cell population of Sézary syndrome as well as those of the T cell lymphoma/leukaemia (Catovsky *et al.*, 1982) may arise by expansion of this normal OKT4 cell subset.

Further studies combining morphological and immunological techniques in normal and pathological lymphoid tissues may help identify normal counterparts of cells characteristic of other lymphoproliferative disorders and help to study further the relationship between certain cell organelles and the versatile immunological function of the lymphocyte.

We are grateful to Dr J. De Mey of Janssen Pharmaceutica for the supply of colloidal gold labelled goat anti-mouse reagent (GAM G40) and Dr Hedy Zola of Flinders Medical Centre for the gift of the monoclonal antibody FMC4.

## REFERENCES

- ABO, T. & BALCH, C.H. (1981) A differentiation antigen of human NK and K cells identified by a monoclonal antibody (HNC-1). *J. Immunol.* **127**, 1024.
- BECKMAN, I.G.R., BRADLEY, J., BROOKS, D.A., KUPA, A., MCNAMARA, P.J., THOMAS, M.E. & ZOLA, H. (1980) Human lymphocyte markers defined by antibodies derived from somatic cell hybrids. II. A hybridoma secreting antibody against an antigen expressed by human B and null lymphocytes. *Clin. exp. Immunol.* **40**, 593.
- BREARD, J., REINHERZ, E.L., KUNG, P.C., GOLDSTEIN, G. & SCHLOSSMAN, S.F. (1980) A monoclonal antibody reactive with human peripheral blood monocytes. *J. Immunol.* **124**, 1943.
- CALLARD, R.E., SMITH, C.M., WORMAN, C., LINCH, D., CAWLEY, J.C. & BEVERLEY, P.C.L. (1981) Unusual phenotype and function of an expanded subpopulation of T cells in patients with haemopoietic disorders. *Clin. exp. Immunol.* **43**, 497.
- CATOVSKY, D., GREAVES, M.F., ROSE, M., GOOLDEN, A.W.G., WHITE, J.M., BOURIKAS, G., BROWNELL, A.I., GALTON, D.A.G., MCCLUSKEY, D.R., LAMPERT, I., IRELAND, R., BRIDGES, J.M., BLATTNER, W.A. & GALLO, R.C. (1982) Adult T-cell lymphoma leukaemia in Blacks from the West Indies. *Lancet*, **i**, 639.
- COSTELLO, C., CATOVSKY, D., O'BRIEN, M., MORILLA, R. & VARADI, S. (1980) Chronic T-cell leukaemias. I. Morphology, cytochemistry and ultrastructure. *Leuk. Res.* **4**, 463.
- CROCKARD, A., CHALMERS, D., MATUTES, E. &

- CATOVSKY, D. (1982) Cytochemistry of acid hydrolases in chronic B and T leukaemias. *Am. J. clin. Pathol.* (In press.)
- DE MEY, J., MOEREMANS, M., DE WAELE, M., GEUENS, G. & DE BRAVANDER, M. (1982) The ISG (immuno gold staining) method used with monoclonal antibodies. *Protides Biol. Fluids*, **29**, 943.
- DE WAELE, M., THIELEMANS, C. & VAN CAMP, B. (1981) Characterization of immunoregulatory T cells in EBV-induced infections mononucleosis by monoclonal antibodies. *N. Engl. J. Med.* **304**, 460.
- FERRARINI, M., CADONI, A., FRANZI, A.T., GHIGLIOTTI, C., LEPRINI, A., ZICCA, A. & GROSSI, C.E. (1980) Ultrastructure and cytochemistry of human peripheral blood lymphocytes. Similarities between the cells of the third population and Tg lymphocytes. *Eur. J. Immunol.* **10**, 562.
- GROSSI, C.E., WEBB, S.R., ZICCA, A., LYDYARD, P.M., MORETTA, L., MINGARI, M.C. & COOPER, M.D. (1978) Morphological and histochemical analysis of two human T-cell populations bearing receptors for IgM or IgG. *J. exp. Med.* **147**, 1405.
- HALIE, M.R., BLOM, N., KLOOSTERMAN, T. & SMIT, J.W. (1979) Lymphocyte subpopulations in lymphoproliferative diseases. Parallel tubular structures in Fc receptor bearing lymphocytes. *Acta Haemat.* **62**, 25.
- HAYNES, B.F., METZGAR, R.S., MINNA, J.D. & BUNN, P.A. (1981) Phenotypic characterization of cutaneous T-cell lymphoma. *N. Engl. J. Med.* **304**, 1319.
- HUHN, D., ANDREWEA, P., RODT, H., THIEL, E. & EVLITZ, M. (1978) Demonstration of the Fc receptor of blood cells by soluble peroxidase-antiperoxidase (PAP) complexes. *Blut*, **36**, 263.
- JANOSSY, G., TIDMAN, N., SELBY, W.S., THOMAS, J.A., GRANGER, S., KUNG, P.C. & GOLDSTEIN, G. (1980) Human T lymphocytes of inducer and suppressor type occupy different microenvironments. *Nature*, **288**, 81.
- KAY, D. & HORWITZ, D.A. (1980) Evidence of reactivity with hybridoma antibodies from probable myeloid origin of peripheral blood cells active in natural cytotoxicity and antibody dependent cell-mediated cytotoxicity. *J. clin. Invest.* **66**, 847.
- McKENNA, R.W., PARKIN, J., GAJL-ECZALSKA, K.J., KERSEY, J.H. & BRUNNING, R.D. (1977) Ultrastructural, cytochemical and membrane surface marker characteristics of the atypical lymphocytes in infectious mononucleosis. *Blood*, **50**, 505.
- MORETTA, L., WEBB, S.R., GROSSI, C.E., LYDYARD, P.M. & COOPER, M.D. (1977) Functional analysis of two human T cell-subpopulations: help and suppression B cell responses. *J. exp. Med.* **146**, 184.
- MÜLLER-HERMELINK, H.-K. & LENNERT, K. (1978) In *Malignant Lymphomas other than Hodgkin's Disease* (ed. by K. Lennert) pp 27-29. Springer-Verlag, Berlin.
- PAYNE, C.M. & GLASSER, L. (1981) Evaluation of surface markers on normal human lymphocytes containing parallel tubular arrays: a quantitative study. *Blood*, **57**, 567.
- POORE, T.E., BARRET, S.G., KADIN, M.E. & BAINTON, D.F. (1981) Ultrastructural localization of acid phosphatase in rosetted T and B lymphocytes of normal blood. *Am. J. Path.* **102**, 72.
- REINHERZ, E.L., KUNG, P.C., GOLDSTEIN, G. & SCHLOSSMAN, S.F. (1979) Separation of functional subsets of human T cells by a monoclonal antibody. *Proc. Natl. Acad. Sci. USA*, **76**, 4061.
- REINHERZ, E.L., KUNG, P.C., GOLDSTEIN, G., LEVEY, R.H. & SCHLOSSMAN, S.F. (1980a) Discrete stages of human intrathymic differentiation. Analysis of normal thymocytes and leukaemic lymphoblasts of T cell lineage. *Proc. Natl. Acad. Sci. USA*, **77**, 1588.
- REINHERZ, E.L., MORETTA, L., ROPER, M., BREARD, J.M., MINGARI, M.C., COOPER, M.D. & SCHLOSSMAN, S.F. (1980b) Human T lymphocyte subpopulations defined by Fc receptors and monoclonal antibodies. A comparison. *J. exp. Med.* **151**, 969.
- TIMONEN, T., ORTALDO, J.R. & HERBERMAN, R.B. (1981) Characteristics of human large granular lymphocytes and relationship to natural killer and K cells. *J. exp. Med.* **153**, 569.
- VAN DER LOO, E.M., CNOSSEN, J. & MEIJER, C.J.L.M. (1981) Morphological aspects of T cell subpopulations in human blood: characterization of the cerebriform mononuclear cells in healthy individuals. *Clin. exp. Immunol.* **43**, 506.