

A novel eosinophil chemotactic factor derived from a histiocytic lymphoma of the central nervous system

E. J. GOETZL, J. ROTHENBERG, E. L. WEBER, C. M. SINN & K. F. AUSTEN *The Howard Hughes Medical Institute Laboratory at Harvard Medical School, the Departments of Medicine, Harvard Medical School and the Robert B. Brigham Hospital Division of the Affiliated Hospitals Center Inc., Boston, Massachusetts; and the Deaconess Hospital, Evansville, Indiana, USA*

(Accepted for publication 19 November 1979)

SUMMARY

An eosinophil chemotactic activity was identified in extracts of tumour tissue and cerebrospinal fluid from a patient with a histiocytic lymphoma of the brain and spinal cord that was infiltrated extensively with eosinophils and associated with peripheral blood eosinophilia. The histiocytic lymphoma-derived eosinophil chemotactic factor, termed ECF-HL, exhibited a mol. wt of 13,000–14,000 by filtration on Sephadex G-50, was highly acidic based on its elution from a high pressure anion exchange column at pH 2.3–2.1, and was susceptible to inactivation by proteolytic digestion. ECF-HL was absent from extracts of control human brain tissue, glioblastomas, other lymphomas and a variety of carcinomas that lacked an accumulation of eosinophils. Partially purified ECF-HL had no chemokinetic activity, but rendered eosinophils unresponsive to other chemotactic factors. Thus ECF-HL is structurally and functionally distinct from other recognized peptides that are preferentially chemotactic for eosinophils.

INTRODUCTION

The occasional occurrence of peripheral blood eosinophilia in association with a malignant tumour usually heralds the development of metastatic lesions (Isaacson & Rapoport, 1946; Viola, Chun & Mukhopadhyay, 1972) or represents a response to irradiation of the tumour (Muggia, Chossein & Wohl, 1973). In several such cases, the resolution of the eosinophilia following the removal of the tumour suggested the possibility that the tumour cells were elaborating a principle that preferentially stimulated the production of eosinophils (Weiss, 1926; Isaacson & Rapoport, 1946). The intense eosinophil infiltration of anaplastic squamous cell lung carcinomas in three patients with striking blood eosinophilia and the finding of clusters of eosinophils around tumour cells in the pleural fluid of one of the patients led to the recognition of distinct tumour-derived low molecular weight eosinophil chemotactic activity (Wasserman *et al.*, 1974; Goetzl *et al.*, 1978). The eosinophil chemotactic factor of lung squamous cell carcinoma, termed ECF-LSC, is a peptide of mol. wt 200–400 that was recovered from tumour extracts, media of dispersed tumour cell cultures and the urine of two of the patients late in the course of their disease (Goetzl *et al.*, 1978).

The presentation of a patient with peripheral blood eosinophilia and marked eosinophil infiltration of a histiocytic lymphoma of the brain prompted an analysis of the tumour tissue and cerebrospinal fluid for the presence of an ECF. A protein of approximate mol. wt 13,000–14,000 was isolated from both sources and the partially purified factor was selectively chemotactic for

Correspondence: Edward J. Goetzl, MD, Seeley Mudd Building, 250 Longwood Avenue, Boston, MA 02115, USA.

eosinophils, as compared to neutrophils and monocytes. Although blood and tissue eosinophilia have been described in association with widespread lymphomas (Henderson & Mejia, 1969) and with malignant histiocytosis (Barth *et al.*, 1972; Liao, Rosai & Danesbod, 1972), the ECF that was identified in the present patient has not been recognized previously in tumours or in normal tissues.

CASE REPORT

R.E. was a 39-year-old white male who presented initially in July 1976 with a 3-week history of headache, irritability, light-headedness and occasional nausea. Physical examination revealed papilloedema and left facial weakness. Computerized tomography and angiography showed a mass in the right temporal area. At craniotomy, a red-gray tumour mass was discovered a few mm below the surface of the right temporal lobe and this mass was easily separated from the surrounding brain tissue and removed. Cranial radiation to a total dose of 4,000 rads, corticosteroids, vincristine and cyclophosphamide were administered with symptomatic relief. In August 1977 the patient developed weakness and decreased sensation of the legs, an unstable gait, and neurogenic abnormalities of the bladder and bowel. Computerized tomography disclosed a recurrence of the cranial mass and myelography revealed multiple masses in the cervical and thoracic spinal cord. Tumour cells were found in Papanicolaou-stained smears of cerebrospinal fluid. An additional course of 2,000 rads of radiation to the brain and 4,000 rads to the brainstem and spinal cord, as well as corticosteroid and intravenous BCNU therapy, failed to prevent the development of quadriplegia. The patient became stuporous, developed bronchopneumonia and died in January, 1978. At autopsy, the tumour was found to have infiltrated the right temporal and frontal lobes of the brain, the subarachnoid space of the spinal cord and many of the spinal nerve roots. No tumour was detected outside of the central nervous system. The bone marrow was markedly hypocellular.

Histological examination of the tumour tissue obtained at surgery and at autopsy (Fig. 1a) revealed the presence of irregular collections of large basophilic cells with pale nuclei that contained prominent nucleoli. There were occasional foci of necrosis despite prominent proliferation and dilatation of the regional blood vessels. Increased numbers of eosinophils were present both in dense clusters (Fig. 1b) and in a diffuse distribution in the tumour tissue with a predilection for the margin that separated the tumour from normal brain tissue. The initial diagnosis of a malignant histiocytic lymphoma of the central nervous system was supported by identical findings in the autopsy specimens. Drs F. Stephen Vogel and Peter C. Burger of Duke University Medical Center and Drs G. Pinkus and W. Schoene of the Department of Pathology of the Peter Bent Brigham Hospital reviewed the relevant tissue sections and concurred with the diagnosis.

When initially evaluated in July 1976, the peripheral blood total eosinophil count ranged from 4,995–8,028/mm³. Within 24 hr after the initial cranial surgery, the total eosinophil count dropped to a normal level. Of the more than twelve total eosinophil counts that were obtained during the ensuing 18 months, only one was elevated to 604/mm³ at the time of recurrence of the tumour. The bone marrow aspirate at the peak of the peripheral blood eosinophilia demonstrated increased eosinophils with normal maturation and no malignant cells. Bone marrow cultures for fungi and *M. tuberculosis*, the erythrocyte sedimentation rate, serum protein electrophoresis, stool examinations for ova and parasites, and routine blood chemistry analyses were all negative or within normal limits.

EXPERIMENTAL MATERIALS AND METHODS

Blind-end acrylic chemotactic chambers with a 0.2-ml stimulus compartment and a 0.5-ml leucocyte well (Neuroprobe Inc., Bethesda, Maryland), 3- μ m pore Sartorius filters (Beckman Instruments Inc., Wakefield, Massachusetts), Hanks' balanced salt solution (Microbiological Associates, Bethesda, Maryland), ovalbumin recrystallized five times (Miles Laboratories Inc., Elkhart, Indiana), and Sephadex G-50 (Pharmacia Fine Chemicals Inc., Piscataway, New Jersey) were obtained as noted.

Two samples of 2.68 g and 3.15 g of the brain tumour, that were obtained at autopsy, were extracted by homogenization in 1 ml of Hanks' solution per g of tissue and sonication at 100 W for 3 min at 4°C (Model 350, Branson Sonic Power Co., Danbury, Connecticut). Portions of 2–5 g each of tumour-free brain tissue from three patients who succumbed to carcinoma of the colon, breast and lung, respectively, of glioblastomas from two patients, and of lymphomas from four patients, all of whom lacked eosinophilia, similarly were homogenized and sonicated. Each sonicate was centrifuged at 10,000 g for 15 min at 4°C and 2 ml of supernate was applied to separate 1.7 × 64-cm columns of Sephadex G-50 (bed volume = 145 ml). The columns were equilibrated and developed with 0.05 M ammonium acetate, pH 7.2, at a flow rate of 6 ml/hr. A 2-ml sample of cerebrospinal fluid from patient R.E. was filtered on an identical column. The adjacent fractions from each Sephadex G-50 column that contained eosinophil chemotactic activity were pooled, lyophilized, dissolved in 200 µl of 0.02 M Na/KHPO₄ (pH 6.3) and injected onto a Partisil-SAX column (Whatman Inc., Clifton, New Jersey) that was equilibrated in the same buffer. The Partisil-SAX column was developed with a linear gradient to 0.03 M H₃PO₄ (pH 2.0) over 150 min in a high pressure liquid chromatography system with two metered pumps (Model 322, Altex Scientific Inc., Berkeley, California) that maintained a flow rate of 1 ml/min.

Mixed leucocytes from eosinophilic donors were washed and resuspended at a concentration of $3.0 \pm 0.2 \times 10^6$ eosinophils/ml in Hanks' solution containing 0.005 M Tris-HCl, pH 7.4, and 0.4 g/100 ml of ovalbumin (HBSS-OA). The incubation of migration chambers, the processing of filters, and the enumeration of eosinophils in stained filters were carried out as described (Goetzl & Austen, 1976; Goetzl *et al.*, 1978). Human neutrophil chemotaxis was measured in the same type of chambers (Goetzl & Gorman, 1978; Goetzl & Hoe, 1979). Eosinophils and neutrophils were counted at between 90–110 µm from the cell source, since background counts of 3–6 eosinophils/high power field (hpf) and 4–8 neutrophils/hpf were observed at this level in filters from chambers lacking a stimulus. Chemotaxis was expressed as net leucocytes/hpf responding to a stimulus, after subtraction of the background level of migration. Some samples of tumour-derived eosinophil chemotactic activity were incubated in 0.1 M Tris-HCl (pH 8) with 2 µg of chymotrypsin (Calbiochem-Behring Corporation, La Jolla, California) for 6 hr or in 0.1 M ammonium acetate (pH 7.4) with 1 µg of subtilisin (Miles-Yeda Ltd, Rehoveth, Israel) for 4 hr at 37°C prior to the assessment of the residual chemotactic activity.

RESULTS

An extract of 2.68 g of tumour tissue obtained at autopsy was filtered on a column of Sephadex G-50 and 100-µl portions of each fraction were assayed for eosinophil and neutrophil chemotactic activity (Fig. 2, bottom frame). The chemotactic activity was expressed preferentially for eosinophils and eluted at 54–58% bed volume in the same position as the ribonuclease A marker, which indicated that the mol. wt was approximately 13,000–14,000. Filtration on Sephadex G-50 of a sonicate of 3.15 g of the tumour gave identical results. The chemotactic activity in the cerebrospinal fluid, that had been collected at the time of recurrence of the tumour, also filtered in the 13,000–14,000 dalton region on Sephadex G-50 and exhibited a similar preference for eosinophils as compared to neutrophils (Fig. 2, top frame). Both the extract and the cerebrospinal fluid contained a small quantity of low mol. wt eosinophil chemotactic activity, eluting at 86–94% bed volume, which was not characterized further. The fractions from the Sephadex G-50 chromatograms of three samples of control brain tissue, two samples of glioblastomas and four samples of other lymphomas, gave maximal responses of 3 net eosinophils/hpf or less. Two hundred-microlitre portions of the pooled Sephadex G-50 peaks of the histiocytic lymphoma-derived eosinophil chemotactic factor, which attracted 28 net eosinophils/hpf, were incubated in duplicate with 1 µg of subtilisin or 2 µg of chymotrypsin. Subtilisin inactivated the tumour-derived principle by 87% and the cerebrospinal fluid-derived principle by 95%, while chymotrypsin inactivated the principle from the two sources by 43 and 59% respectively.

One-half of the pooled peak of eosinophil chemotactic activity from the Sephadex G-50 filtration of the extract of tumour tissue was subjected to anion-exchange high-performance liquid

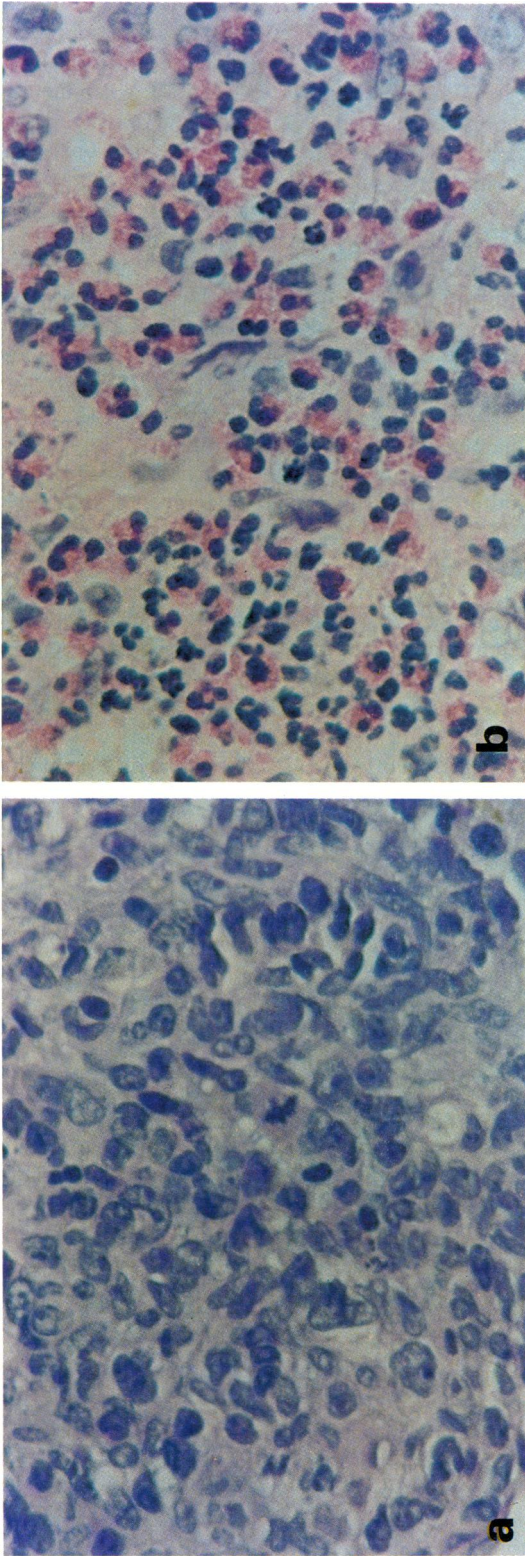


Fig. 1. Eosinophil infiltration of the histiocytic lymphoma in the brain. (a) Tumour tissue. (H&E \times 350.) (b) Focus of intense eosinophil infiltration at the margin of the tumour. (H&E \times 350.)

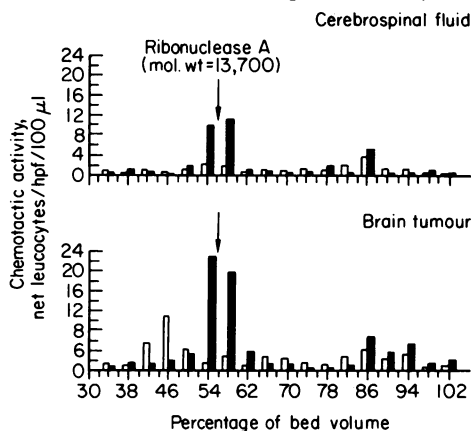


Fig. 2. Filtration on Sephadex G-50 of cerebrospinal fluid and of the extract of brain tumour tissue. Fractions of 2% bed volume were collected and 100- μ l portions were assayed in duplicate utilizing neutrophils (\square) from a normal subject and eosinophils (\blacksquare) from a patient with chronic active hepatitis and 82% peripheral blood eosinophilia. The background migration was 6 neutrophils/hpf and 5 eosinophils/hpf in the absence of a stimulus.

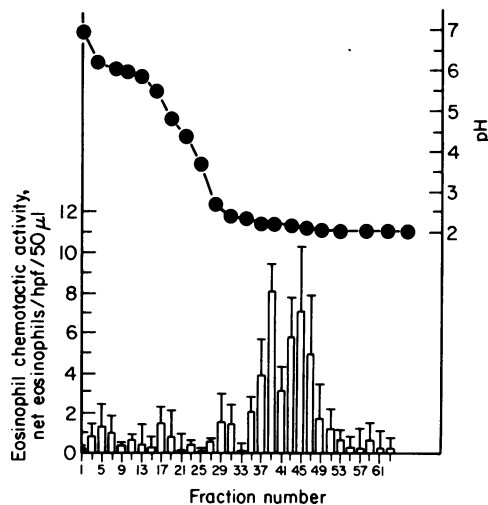


Fig. 3. High pressure anion-exchange chromatography of the eosinophil chemotactic activity derived from Sephadex G-50 filtration of the extract of brain tumour tissue. Each bar and bracket represent the mean and 0.5 the range of the results of assaying the activity in 50 μ l of the 1-ml fractions with eosinophils from two donors. One donor had a hyper eosinophilic syndrome and 85% eosinophilia and the other had an allergic reaction to nitrofurantoin and 41% eosinophilia. The background levels of eosinophil migration were 2 and 5 eosinophils/hpf respectively. (●-●) pH values.

chromatography (Fig. 3). The bulk of the eosinophil chemotactic activity eluted at pH 2.3–2.1. The pooled peak of activity was concentrated to 2 ml and was analysed in dose–response fashion utilizing eosinophils of 85% purity from a donor with a hyper eosinophilic syndrome. The mean response to 25 μ l, 50 μ l, 100 μ l and 200 μ l was 6, 12, 17, and 23 net eosinophils/hpf above a mean background of 5 eosinophils/hpf. The addition of 50 μ l to the eosinophil compartment as well as to the stimulus compartment reduced the response to 4 net eosinophils/hpf, indicating that the activity was predominantly chemotactic. Portions of 1.2×10^7 eosinophils were preincubated for 30 min at 37°C with 25 μ l and 50 μ l of the pooled eosinophil chemotactic activity, washed and employed in four chemotactic chambers to assess the effects of the activity on random migration and chemotaxis

to 50 μ l of the purified factor. The chemotactic response of 24 net eosinophils/hpf was suppressed by 31% at 25 μ l and 74% at 50 μ l, while random migration was unaffected.

DISCUSSION

The presence of peripheral blood eosinophilia at the time of diagnosis of a histiocytic lymphoma of the brain in a patient with localizing neurological signs, the disappearance of eosinophilia with initial treatment, and the reappearance of eosinophilia with the recurrence of the tumour in the brain and spinal cord suggest the possibility of a causal relationship. Further, the intense focal infiltration of the tumour tissue by eosinophils (Fig. 1) in the absence of tissue eosinophilia in other organs is compatible with the production of an eosinophilotactic factor by the tumour. The clinical and pathological features of the tumour in this patient do not support a diagnosis of familial or acquired malignant histiocytosis with eosinophilia. In familial instances of malignant histiocytosis with peripheral blood eosinophilia, the affected infants develop a maculo-papular erythematous skin eruption, hepatosplenomegaly, and hypogammaglobulinaemia in association with the accumulation of eosinophils and atypical histiocytes in the bone marrow, skin, liver, lymph nodes, heart and salivary glands (Barth *et al.*, 1972). In the rare acquired cases in adults, there is a comparable systemic invasion by eosinophils and atypical histiocytes that may involve the brain as well (Liao *et al.*, 1972). The infiltrates described in both forms of the disease are diffuse and no tumour masses have been recognized. The current patient is the first to be described with peripheral blood and tumour tissue eosinophilia in relation to discrete masses and nodules of histiocytic lymphoma in the central nervous system.

The predominant eosinophil chemotactic activity detected in extracts of the brain tumour tissue and in the cerebrospinal fluid exhibited a mol. wt of 13,000–14,000 on Sephadex G-50 gel filtration (Fig. 2), was highly acidic as assessed by its elution from a Partisil-SAX column at pH 2.3–2.1 (Fig. 3) and was susceptible to inactivation by digestion with proteolytic enzymes. This presumed highly acidic polypeptide thus is a novel factor which is structurally distinct from other eosinophil chemotactic peptides. The peptides extracted from normal human lung tissue that are preferentially chemotactic for eosinophils filter on Sephadex G-25 in two peaks containing principles of mol. wt 300–1,000 and 1,500–2,500 respectively (Goetzl & Austen, 1975; Goetzl & Austen, 1977). The low mol. wt eosinophil chemotactic peptides of human lung are highly acidic, eluting from Dowex-1 at pH 3.2–2.2, and two of the active constituents have been identified as Ala-Gly-Ser-Glu and Val-Gly-Ser-Glu (Goetzl & Austen, 1975). The peptides of both sizes are presumed to be of mast cell origin as they are released from fragments of human lung tissue by IgE-dependent challenge (Goetzl & Austen, 1977). Eosinophil chemotactic peptides of similar sizes have been recovered from isolated rat mast cells as well (Wasserman, Goetzl & Austen, 1974; Boswell, Austen & Goetzl, 1978). The rat mast cell-derived peptides of mol. wt 1,500–2,500 elute from Dowex-1 in two peaks at pH 5.4–4.4 and 3.1–2.1, and the less acidic principles can be resolved further by reverse-phase high performance liquid chromatography (Boswell *et al.*, 1978). ECF-LSC, the eosinophilotactic peptide purified from human bronchogenic carcinomas, has a mol. wt comparable to that of the smaller peptides isolated from human lung tissue and rat mast cells, but is less acidic and elutes from Dowex-1 at pH 5.0–3.5 (Goetzl & Austen, 1977). A range of eosinophil chemotactic factors were detected in the culture medium of lymph node cells obtained from patients with Hodgkin's disease (Kay *et al.*, 1975), but the exact size and the net charge of these activities have not been determined.

The apparent specificity of the eosinophil chemotactic factor of histiocytic lymphoma (ECF-HL) for this tumour was established by its absence from extracts of specimens of control human brain tissue, glioblastomas, other lymphomas, renal cell carcinomas, colonic carcinomas, a variety of human bronchogenic carcinomas and normal human lung tissue or fibroblasts (Goetzl *et al.*, 1978). ECF-HL has no detectable chemokinetic activity and chemotactic deactivation of eosinophils is achieved at a concentration of ECF-HL that is 1/10–1/5 of that required for a maximal chemotactic response. The ability of ECF-HL to influence other functions of the eosinophil or to evoke peripheral blood eosinophilia must await further studies.

REFERENCES

- BARTH, R.F., VERGARA, G.G., KHURANA, S.K., LOWMAN, J.T. & BECKWITH, J.B. (1972) Rapidly fatal familial histiocytosis associated with eosinophilia and primary immunological deficiency. *Lancet*, **ii**, 503.
- BOSWELL, R.N., AUSTEN, K.F., & GOETZL, E.J. (1978) Intermediate molecular weight eosinophil chemotactic factors in rat peritoneal mast cells: immunologic release, granule association, and demonstration of structural heterogeneity. *J. Immunol.* **120**, 15.
- GOETZL, E.J. & AUSTEN, K.F. (1975) Purification and synthesis of eosinophilotactic tetrapeptides of human lung tissue: identification as eosinophil chemotactic factor of anaphylaxis. *Proc. Natl. Acad. Sci. USA*, **72**, 4123.
- GOETZL, E.J. & AUSTEN, K.F. (1976) Structural determinants of the eosinophil chemotactic activity of the acidic tetrapeptides of eosinophil chemotactic factor of anaphylaxis. *J. exp. Med.* **144**, 1424.
- GOETZL, E.J. & AUSTEN, K.F. (1977) Factors regulating eosinophil migration in immediate hypersensitivity reactions. *Progress in Immunology III* (ed. by T. E. Mandel), p. 439. Australian Academy of Science, Canberra City.
- GOETZL, E.J. & GORMAN, R.R. (1978) Chemotactic and chemokinetic stimulation of human eosinophil and neutrophil polymorphonuclear leukocytes by 12-L-hydroxy-5,8,10-heptadecatrienoic acid (HHT). *J. Immunol.* **120**, 526.
- GOETZL, E.J. & HOE, K.Y. (1979) Chemotactic factor receptors of human PMN leucocytes. I. Effects on migration of labelling plasma membrane determinants with impermeant covalent reagents and inhibition of labelling by chemotactic factors. *Immunology*, **37**, 407.
- GOETZL, E.J., TASHJIAN, A.H., JR, RUBIN, R.H. & AUSTEN, K.F. (1978) Production of a low molecular weight eosinophil polymorphonuclear leukocyte chemotactic factor by anaplastic squamous cell carcinomas of human lung. *J. clin. Invest.* **61**, 770.
- HENDERSON, A.H. & MEJIA, G. (1969) Malignant lymphoma presenting with a high eosinophilia, eosinophilic pleurisy, and pericarditis. *Thorax*, **24**, 124.
- ISAACSON, N.H. & RAPOPORT, P. (1946) Eosinophilia in malignant tumours: its significance. *Ann. intern. Med.* **25**, 893.
- KAY, A.B., MCVIE, J.G., STUART, A.E., KRAJEWSKI, A. & TURNBULL, L.W. (1975) Eosinophil chemotaxis of supernatants from cultured Hodgkin's lymph nodes. *J. clin. Pathol.* **28**, 502.
- LIAO, K.T., ROSAI, J. & DANESBOD, K. (1972) Malignant histiocytosis with cutaneous involvement and eosinophilia. *Am. J. clin. Pathol.* **57**, 438.
- MUGGIA, E.M., CHOSSEIN, N.A. & WOHL, H. (1973) Eosinophilia following radiation therapy. *Oncology*, **27**, 118.
- VIOLA, M.V., CHUN, E.D.B. & MUKHOPADHYAY, M.C. (1972) Eosinophilia and metastatic carcinoma. *Med. Ann. DC*, **41**, 1.
- WASSERMAN, S.I., GOETZL, E.J. & AUSTEN, K.F. (1974) Preformed eosinophil chemotactic factor of anaphylaxis (ECF-A). *J. Immunol.* **112**, 351.
- WASSERMAN, S.I., GOETZL, E.J., ELLMAN, L. & AUSTEN, K.F. (1974) Tumor-associated eosinophilotactic factor. *N. Engl. J. Med.* **290**, 420.
- WEISS, E. (1926) Carcinoma of the stomach with high blood eosinophilia. *J. Lab. clin. Med.* **11**, 733.