

Clinical significance of a new autoantibody against a human eye muscle soluble antigen, detected by immunofluorescence

M. MENGISTU, E. LARYEA, A. MILLER, & J. R. WALL *The Thyroid Research Unit, The Montreal General Hospital Research Institute, Montreal, Quebec, Canada*

(Accepted for publication 14 February 1986)

SUMMARY

The clinical significance of a circulating autoantibody against a recently identified soluble human eye muscle-derived antigen was studied in patients with Graves' ophthalmopathy and autoimmune thyroid disorders. Tests were positive in 73% of patients with Graves' ophthalmopathy, including six of seven with no associated thyroid disease (euthyroid Graves' disease). Tests were also positive in 27% of patients with hyperthyroidism but no clinically apparent eye disease, in 13% of patients with Hashimoto's thyroiditis without eye disease, in two of 12 patients with subacute thyroiditis, in one of 20 patients with non-immunological thyroid disorders but in none of 39 normal subjects. There were significant positive correlations between serum levels of the antibody (expressed as a titre) and the severity of the eye muscle component quantified as an index as well as the duration of the eye disease. Antibodies were detected in three of five patients with only lid lag and state who subsequently developed active ophthalmopathy, in six of nine patients who developed eye disease after treatment of their hyperthyroidism and in one of eight first degree relatives of patients with Graves' ophthalmopathy. In addition three of the 12 patients with autoimmune thyroid disease without apparent eye involvement, but positive antibody tests, have developed ophthalmopathy since the time of testing. These findings suggest that tests for antibodies against a soluble human eye muscle antigen may be useful clinically as a diagnostic test and to predict the onset of eye disease in predisposed patients and subjects.

Keywords Graves' ophthalmopathy eye muscle antibodies immunofluorescence-Graves' disease

INTRODUCTION

Although Graves' ophthalmopathy is almost certainly an autoimmune disorder, if only because of its almost invariable association with autoimmune thyroid disorders (Volpé, 1977; Doniach, 1982; Wall, 1984; 1985), the underlying immunological abnormalities and the mechanism for its association with thyroid disorders are unclear (Wall, 1984; Wall & Kuroki 1985). Recently, antibodies reactive with orbital antigens have been described from three laboratories. Firstly, Kodama *et al.* (1982) described antibodies against a partially purified human eye-muscle-derived soluble antigen in 74% of patients with active ophthalmopathy. Secondly, Kendall-Taylor and colleagues (Atkinson *et al.*, 1984; Kendall-Taylor, Atkinson & Holcombe 1984) described an antibody reactive with a pig eye-muscle membrane-antigen in patients with ophthalmopathy. Both

Correspondence: J. R. Wall, The Thyroid Research Unit, The Montreal General Hospital Research Institute, Montreal, Quebec, Canada.

of these groups used the enzyme-linked immunosorbent assay (ELISA). Recently, Faryna, Nauman and Gordas (1985) demonstrated antibodies against a human eye-muscle-membrane-antigen using a staphylococcal protein A binding procedure. The soluble antigen has been characterized and partially purified from human eye muscle cytosol using a monoclonal antibody (Kodama *et al.*, 1982). Using the ELISA and unpurified tissue preparations as antigen we have been unable to demonstrate convincingly differences between patients with Graves' ophthalmopathy and normal subjects because of high background reactivity. This was shown to be due to non-specific binding of serum proteins and enzyme-second antibody conjugates to the plastic surface and tissue proteins, and contamination, in human tissue, with blood-derived immunoglobulin (Wall & Kuroki, 1985). For these reasons we have assessed the immunofluorescence test for the measurement of antibodies against human eye-muscle-antigens. In this paper we report our findings of the prevalence and significance of antibodies against an eye-muscle soluble-antigen in patients with Graves' ophthalmopathy and autoimmune thyroid disorders.

MATERIALS AND METHODS

We studied 55 patients, 10 males and 45 females aged 14–82 (mean age 48 years) with Graves' ophthalmopathy, of whom 41 had 'active' disease (i.e. with periorbital congestion, chemosis and conjunctival injection of less than 6 months duration) and 14 severe but 'inactive' ('burnt-out') disease. Forty-four had associated hyperthyroidism, at the time of study in 14 cases and in the past in 30 cases. Four had associated Hashimoto's thyroiditis of whom all were euthyroid, while seven had no associated thyroid disorder ('euthyroid ophthalmic Graves, disease') as determined by thyroid function tests including ^{131}I uptake and scan, but not thyrotrophin releasing hormone (TRH) or T3 suppression tests, and thyroid (including thyroid stimulating hormone (TSH) receptor), autoantibody tests. All patients had class three or worse disease (Werner, 1969; 1977). Only one patient had corneal inflammation while none had loss of vision due to optic papillitis. Hyperthyroid patients had been treated with antithyroid drugs only (four cases), with radioactive iodine (38 cases), and by thyroidectomy (two cases). The clinical severity of the eye disease was quantified using a clinical index based on the classification recommended by the American thyroid association (Werner, 1969; 1977) as modified by Kriss *et al.* (1967) a score of 0–3 (where 0 = absent, 1 = mild, 2 = moderate and 3 = severe) being assigned for each of proptosis > 18 mm in one or both eyes, conjunctival injection, epiphora, chemosis, periorbital swelling, and eye-muscle dysfunction. The severity of the eye-muscle component was quantified 0–5, (0 = no eye muscle involvement, 1 = mild restriction of upward gaze, 2 = moderate restriction of upward gaze, 3 = severe restriction of upward gaze, 4 = restriction of gaze in two or more directions and 5 = complete ophthalmoplegia). Also studied were (a) 30 patients, all females aged 14–60 (mean age 36 years) with Hashimoto's thyroiditis without clinically apparent eye disease in whom the diagnosis was made on the basis of a firm, indurated, goitre, significant titres ($\geq 1/256$) of thyroid antibodies and biopsy evidence of lymphocytic infiltration and/or Hürtle cells; (b) 30 patients, four males and 26 females aged 16–70 (mean age 40 years) with Graves' hyperthyroidism without evident eye disease of whom 10 were hyperthyroid, 16 euthyroid following treatment and four hypothyroid following treatment; (c) four patients, two males and two females aged 30–72 and two females aged 30–72 (mean age 60 years) with primary myxoedema without eye disease; (d) 12 patients, three males and 9 females aged 28–60 (mean age 48 years) with subacute thyroiditis in whom the diagnosis was made from local inflammation of the thyroid gland associated with hyperthyroidism (in 10 cases), very low ^{131}I uptake and an elevated ESR; (e) 20 euthyroid patients, four males and 16 females aged 28–62 (mean age 52 years) with simple (colloid) goitre which was multinodular in 16 cases and apparently uninodular in four cases; (f) 10 patients, three males and seven females aged 8–50 (mean age 24 years) with type I diabetes mellitus of whom eight had significant titres ($\geq 1/256$) of antithyroid microsomal antibody, two of antithyroglobulin antibody, but none of non-organ specific antibodies (g) eight euthyroid first degree relatives of patients with Graves' ophthalmopathy, three males and five females aged 16–24 (mean age 20 years). Thirty-nine subjects, 10 males and 29 females aged 18–62 (mean age 40 years), were tested as controls.

Human eye-muscle-derived soluble-antigen. Human eye-muscle-derived soluble-antigen was prepared as described previously (Kodama *et al.*, 1982) from crude human eye-muscle-cytosol. Briefly, the cytosol fraction of autopsy-derived normal human eye-muscle was chromatographed on Sephadex G-200, 4.2 ml aliquots being tested for reactivity with monoclonal antibody no. 50-24. Positive aliquots were pooled, freeze dried, and reconstituted to 1 mg/ml.

Immunofluorescence. The method used was based on standard tests (Wall & Wright 1974) with minor modifications for eye-muscle. Tissue substrates used were human eye-muscle, abdominal-wall-muscle, thyroid, liver and eye-muscle obtained from pig, dog and rat. In preliminary studies the following conditions were found to be optimal; fresh, snap frozen, eye-muscle obtained from normal subjects undergoing strabismus repair was sectioned at 6 μm , air dried for 20 min, and fixed in 100% acetone for 15 min. Sections comprised both transverse and longitudinal cuts of eye muscle bundles. Preabsorption of sera with red blood cells, liver powder, or skeletal muscle was not found to reduce the background fluorescence or to enhance the difference between patients and normal subjects. Similarly, absorption of the FITC-antiserum conjugate was not helpful. Incubation with serum (dilution 1/6) was for 15 min at 20°C and with FITC-antihuman γ -globulin (1/10; Kellstad no. 78701, Austin, TX, USA) for 20 min at 20°C. Fluorescence was assessed by two observers, neither knowing the origin of the sera, as negative, +, ++ or +++. Positive sera ($\geq +$) were retested at dilutions of 1/12, 1/24 and 1/48, the final results being expressed as a titre (the greater dilution with $\geq +$ fluorescence). Antibodies against human thyroglobulin and the thyroid microsomal antigen were determined using ELISAs. TSH receptor antibodies were measured using the radioceptor assay described by Smith and Hall (1974) as modified slightly by Strakosch *et al.* (1978). Results were expressed as TSH binding inhibition indices (TBII). An index of < 0.75 (mean $- 2$ s.d. for normals) was taken as a positive test for TSH receptor antibody. Serum thyroxine was measured using a standard radioimmunoassay.

Statistical analysis. Relationship between antibody levels and the severity and duration of the ophthalmopathy and serum thyroid hormone levels were assessed as Spearman's rank correlation coefficient (r_s). Relationship between eye-muscle titres and thyroid antibody levels were assessed as correlation coefficients (r). The prevalences of antibodies in patient groups and normals were compared using χ^2 tests.

RESULTS

In preliminary studies it was found that eye-muscle antibodies against eye-muscle soluble-antigen in the serum of patients with Graves' ophthalmopathy could be detected by immunofluorescence. The fluorescence pattern was diffusely cytoplasmic and did not appear to include the cell surface (Fig. 1). The test was reproducible, readings of the two observers being the same on repeated testing of the same sera in over 95% of cases. Antibodies were of the IgG class and fixed complement and were species non-specific, reacting with eye-muscle of all other species tested. Fluorescence was completely absorbed by preincubation, overnight at 37°C, of three positive sera with the soluble, but not membrane, fraction of human eye muscle, but not liver or thyroid fractions, or bovine serum albumin (BSA). As determined by immunofluorescence antibodies against the eye-muscle-derived soluble-antigen were detected in 40 of the 55 patients with ophthalmopathy tested. Of these, tests were positive in 33 of 44 patients with associated hyperthyroidism (in 22 of 31 with active disease and in 11 of 13 with inactive, 'burnt-out', disease), in one of four patients with associated Hashimoto's thyroiditis and in six of seven with no associated thyroid disorder. Tests were also positive in eight of 30 patients with Graves' hyperthyroidism but no associated eye disease, in four of 30 patients with Hashimoto's thyroiditis and no associated eye disease, in two of 12 patients with subacute thyroiditis and in one of 20 patients with non-autoimmune thyroid disorders. Tests were negative in all 39 normal subjects tested (Table 1). In addition, tests were positive in one of 10 patients with type I diabetes mellitus tested and in one of eight euthyroid first degrees relatives of patients with ophthalmopathy (results not shown). Finally, tests were negative in all four patients with primary myxoedema tested.

The titre of immunofluorescent antibodies was determined for all positive sera. In patients with

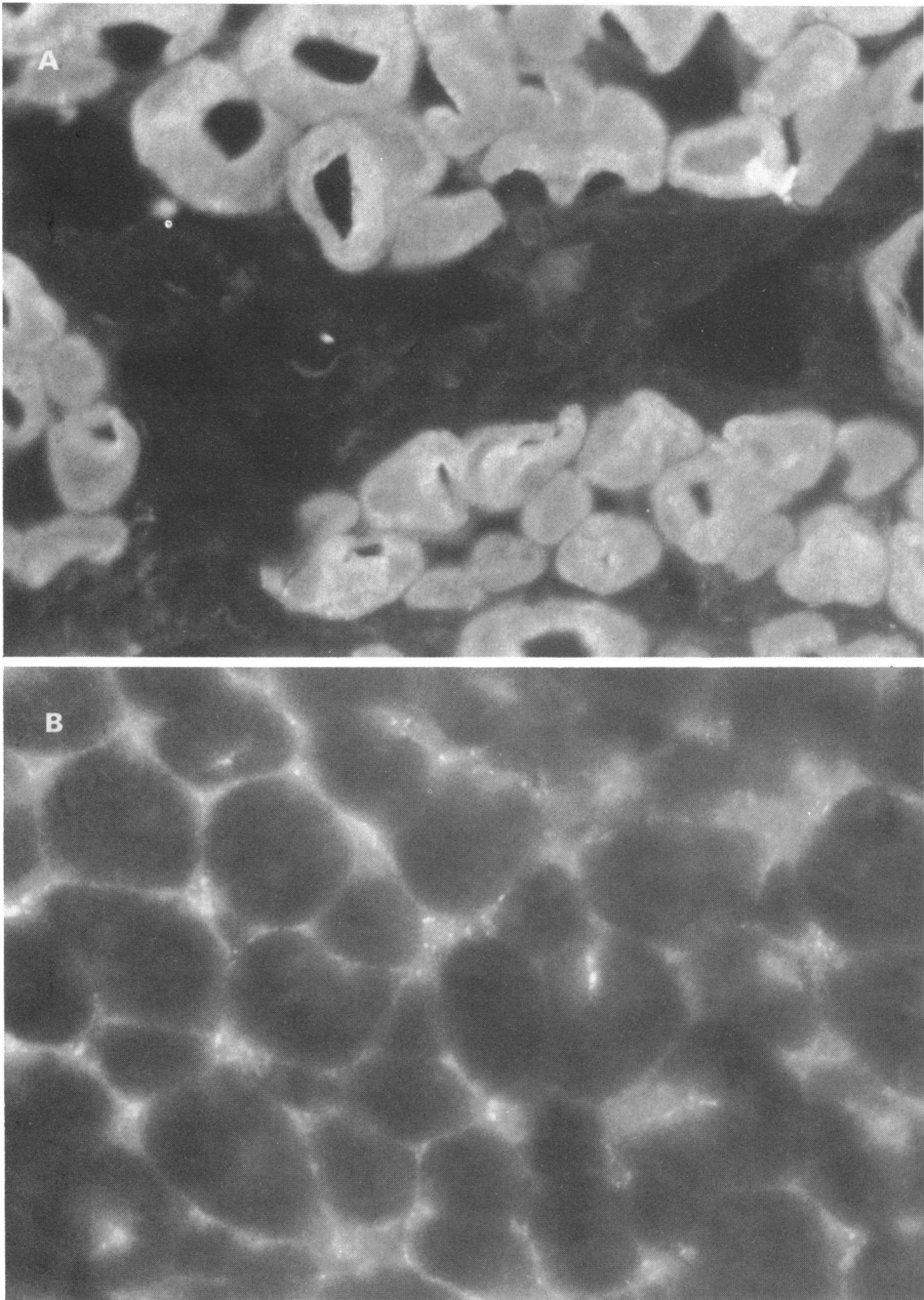


Fig. 1. Typical fluorescence pattern given by serum from a patient with Graves' ophthalmopathy when incubated with normal human eye muscle (a). A diffuse cytoplasmic fluorescence is seen. Serum dilution was 1/6. For comparison a negative test, with normal serum at a dilution of 1/6, is shown in (b).

Table 1. Prevalence of antibodies against a human eye-muscle soluble-antigen, determined by immunofluorescence, in patients with ophthalmopathy, autoimmune thyroid disorders and other thyroid disorders without eye involvement, and normal subjects

Group	Number with positive tests*	χ^2 tests (<i>P</i> compared to normal subjects)
Ophthalmopathy (<i>n</i> = 55)	40 (73%)	< 0.001
Graves' hyperthyroidism	33 (75%)	< 0.001
Active (<i>n</i> = 31)	22 (71%)	< 0.001
'burnt-out' (<i>n</i> = 13)	11 (85%)	< 0.001
Hashimoto's thyroiditis (<i>n</i> = 4)	1	—
Euthyroid Graves' disease (<i>n</i> = 7)	6	< 0.001
Graves' hyperthyroidism (<i>n</i> = 30)	8 (27%)	< 0.05
Hashimoto's thyroiditis (<i>n</i> = 30)	4 (13%)	ns
Subacute thyroiditis (<i>n</i> = 12)	2 (16%)	ns
Other thyroid disorders (<i>n</i> = 20)	1 (5%)	ns
Normal subjects (<i>n</i> = 39)	0 (0%)	

* Positive test taken as significant ($\geq +$) fluorescence at a serum dilution of 1/6.

Statistical analyses refer to χ^2 tests comparing prevalence of positive tests in patients groups with that in the normal subjects.
ns not significant.

thyroid disorders and no associated eye disease, but positive tests, the titres were, in all cases, low ($\leq 1/2$) (Fig. 2). Titres of eye-muscle antibodies were correlated with thyroid antibody levels and with the severity and duration of the eye disease. There were no close correlations between titres of eye-muscle antibody and titres of antithyroglobulin or antimicrosomal antibodies, or levels of TSH receptor antibodies, in the few patients in whom all of these tests were performed. Although more severe eye disease, assessed as a clinical index, was associated with greater prevalences of positive eye muscle antibody tests, and higher titres, overall the correlation was not significant ($r_s = 0.251$, $P = ns$) (Fig. 3).

The relationship between eye muscle antibodies and the severity of the eye muscle dysfunction was also examined. Patients with severe eye muscle disease had a higher prevalence of positive tests, and higher titres, compared to those with mild or no eye disease and the correlation between the degree of eye muscle involvement, expressed as a clinical index, and the titre of eye muscle antibodies was significant ($r_s = 0.60$, $P < 0.001$) (Fig. 4). Of four patients with Graves' ophthalmopathy and enlarged eye muscles as determined by computerised tomography (CT) scanning of their orbits all had a positive antibody test, while tests were positive in only one of the four patients with normal CT scans tested.

Antibody levels were correlated with the duration of the eye diseases in the 49 cases in whom this was accurately known. There was a close correlation between duration of disease and antibody titres. Thus tests were more often positive in patients with disease of ≤ 3 years duration (13 out of 14), all of whom had inactive but severe disease, than in those of disease of less than 1 years duration (χ^2 tests, $P < 0.001$) and the correlation between duration of the eye-muscle disease (years) and antibody titres was as significant ($r_s = 0.35$, $P < 0.05$) (Fig. 5).

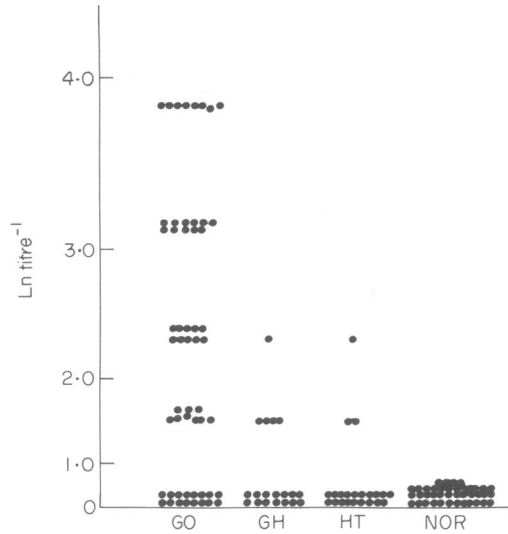


Fig. 2. Titres of antibodies against an eye muscle soluble antigen, in patients with Graves' ophthalmopathy (GO), Graves' hyperthyroidism without eye-muscle disease (GH), Hashimoto's thyroiditis without evident eye disease (HT) and normal subjects, as measured by immunofluorescence. Results expressed as natural log (Ln) titre⁻¹.

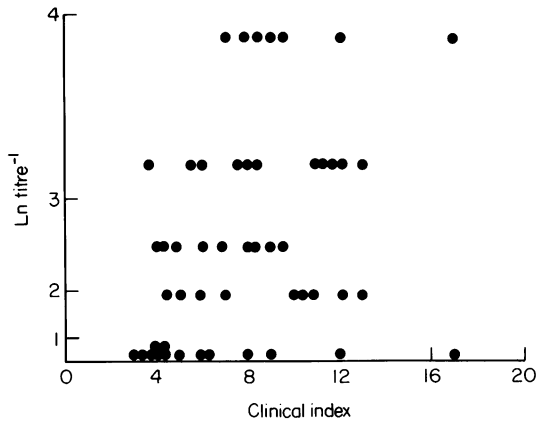


Fig. 3. Correlation between serum titres of antibodies against an eye-muscle soluble antigen (expressed as Ln titre⁻¹), as measured by immunofluorescence and severity of the eye disease, expressed as a clinical index (see Materials and Methods).

Of the seven patients with ophthalmopathy in whom immunofluorescence testing was repeated on serum taken from 2–8 months later, tests converted from positive to negative in three and from negative to positive in four. In these patients there was no close correlation between changes in antibody levels and change in the clinical status of either the overall degree of inflammation or the severity of the eye-muscle component. In retrospect tests had been positive in six of nine hyperthyroid patients (66%) with no evidence of eye disease from 3–21 months before they developed overt eye disease (after treatment of their hyperthyroidism by radioiodine in all cases). Antibody levels had increased in three of these patients just before the onset of clinical ophthalmopathy. Tests were also positive in three of five patients with only lid lag and stare who subsequently developed severe, progressive, ophthalmopathy. Of the 12 patients with hyperthy-

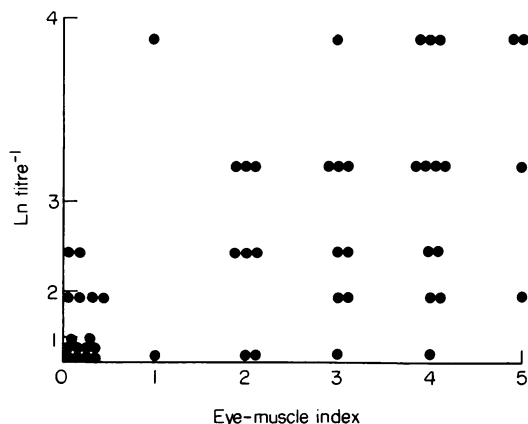


Fig. 4. Correlation between serum titres of antibodies against an eye-muscle soluble-antigen (expressed as Ln titre^{-1}), as measured by immunofluorescence and severity of the eye disease, expressed as a clinical index (see Materials and Methods).

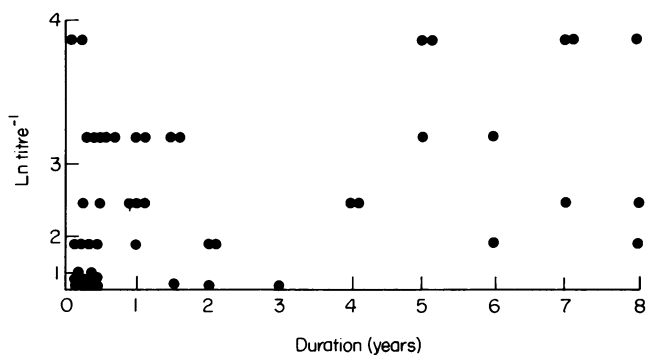


Fig. 5. Correlation between serum titres of antibodies against an eye-muscle soluble-antigen (expressed as Ln titre^{-1}) as measured by immunofluorescence and the duration of the eye disease.

oidism or Hashimoto's thyroiditis without evidence for eye disease but positive tests, three have developed eye disease since the time of initial testing which was from 3–12 months earlier. Finally, there was no close correlation between titres of eye muscle antibody and serum thyroxine levels in patients with Graves' ophthalmopathy ($r_s=0.23$, $P=\text{ns}$), tests being positive in nine of 14 hyperthyroid patients and in 31 of 41 euthyroid patients with ophthalmopathy (χ^2 test, $P=\text{ns}$).

DISCUSSION

We have shown that the ELISA and immunofluorescence tests detect the same antibody against a human eye-muscle-derived soluble-antigen. Preliminary results suggest that immunofluorescence may be more specific and sensitive than the ELISA. As determined by immunofluorescence the antibody was eye-muscle-specific but not species-specific and associated with the presence of ophthalmopathy, particularly the eye-muscle component. The detection of antibodies in some hyperthyroid patients before they developed eye disease, as well as in the occasional patient with Type I diabetes and in an apparently normal first degree relative of a patient with ophthalmopathy, suggests that the antibodies may be detected in patients or subjects predisposed to ophthalmopathy before the onset of eye disease. This raises the possibility that Graves' ophthalmopathy could be

prevented by prophylactic treatment of patients with autoimmune thyroid disorders and positive tests. The observed relationship between antibody levels and the severity of the eye muscle component suggests that measurement of the eye-muscle antibodies may also be useful as an aid to monitor treatment with, for example, immunosuppressive drugs or plasmaphoresis. The finding of positive tests in a large proportion of patients with no evidence of thyroid disease (euthyroid Graves' disease) is strong evidence that the antibodies are closely associated with the eye disease, rather than thyroid autoimmunity, and suggests that the test may be useful to confirm the diagnosis of autoimmune ophthalmitis in patients without apparent thyroid disease, or in those with associated thyroid disease and only mild eye signs. In order to further elucidate the relationship between this antibody and the clinical features of Graves' ophthalmopathy, quantitative eye muscle function tests such as intraocular pressure on upward gaze, CT scan, and orthoptics need to be performed in a prospective study and correlated with changes in antibody titres.

It is well recognized that while antibodies may be good markers of the autoimmune process tissue damage is more likely to be mediated by killer (K) cells in association with cell surface-directed antibodies (Bogner, Schleusener & Wall, 1984) or by cytotoxic T cells. The antibodies against a soluble antigen detected by immunofluorescence are thus unlikely to be the primary cause of tissue damage in Graves' ophthalmopathy even though, in this study, there was a modest association between their presence, and levels, and the eye muscle component of Graves' ophthalmopathy. Indeed there is preliminary evidence that the eye muscle damage in Graves' ophthalmopathy is mediated by K cells in association with antibodies against a cell surface antigen (Chuang, Whelan & Wall, 1985). Although the eye muscle appears to be the primary target in this disorder (Rundle, Finlay-Jones & Noad, 1953; Riley, 1972), it is possible that antigens in the orbital connective tissue or the lacrimal gland (Wall *et al.*, 1978; Wall, Walters & Grant, 1979) may also be involved in the inflammatory reaction. In addition, we have recently identified an antigen in the orbital connective tissue membranes which shares a reactive site with human thyroglobulin against which autoantibodies from patients with ophthalmopathy and autoimmune thyroid disorders react (Kuroki *et al.*, 1985; Wall & Kuroki, 1985). Reactivity against orbital tissue-thyroid shared antigens would certainly be a plausible explanation for the frequent association of ophthalmopathy with Graves' hyperthyroidism and Hashimoto's thyroiditis although in the above study, there was no close correlation between the levels of antibodies against the shared antigen and the presence or severity of the eye disease (Kuroki *et al.*, 1985; Wall & Kuroki, 1985). Prospective studies of eye-muscle antibodies in patients with Graves' disease and Hashimoto's thyroiditis should also help resolve the controversy regarding the prevalence of ophthalmopathy in these disorders (Gamblin *et al.*, 1983a, b) and whether, or not ophthalmopathy ever occurs in the complete absence of thyroid disease (Gorman 1983). Finally, the prevalence in other inflammatory muscle disorders and other organ specific and multi system autoimmune disorders, of eye muscle antibodies as detected by immunofluorescence, as well as the muscle specificity, need to be assessed.

This work was supported by the MRC Canada (Grant No. MA 698) and by the national Eye Institute of the NIH (Grant No. EY05062-01A1). The authors are grateful to Drs J. Wise, R. Polomino, J.L. Jacobs and M. Flanders for providing human eye-muscle.

REFERENCES

- ATKINSON, S., HOLCOMBE, M., TAYLOR, J. & KENDALL-TAYLOR, P. (1984) The relationship of ophthalmopathic IgG to TBII and other thyroid autoantibodies. Proc. 14th Annual meeting of the European Thyroid Association Rotterdam, Sept 3-7 1984. *Annales d'endocrinologie*, **45**, 12 (abstract).
- BOGNER, U., SCHLEUSENER, H. & WALL, J.R. (1984) Antibody-dependent cell-mediated cytotoxicity against human thyroid cells in hashimoto's thyroiditis but not Graves' disease. *J. clin. Endocrinol. Metab.* **59**, 734.
- CHUANG, P.W., WHELAN, L. & WALL, J.R. (1985) Immunologically-mediated cytotoxicity against eye muscle cells by serum and lymphocytes from patients with Graves' ophthalmopathy. *Proc. 67th Annual Meeting of the Endocrine Society Baltimore June 1985* (abstract).
- DONIACH, D. (1982) Autoimmune endocrine exophthalmos. *Lancet*, **11**, 2878.
- FARYNA, M., NAUMAN, T. & GORDAS, A. (1985) Measurement of autoantibodies against human eye muscle plasma membranes in Graves' ophthalmopathy. *Br. Med. J.* **29**, 191.
- GAMBLIN, G.T., GALENTINE, P., HARPER, D.G., CHER-

- NOW, B. & EIL, C. (1983a) Screening for elevated intraocular pressure (IOP) on upward gaze in thyroid disease. In *proc. 59th Meeting of the American Thyroid Association. New Orleans October 1983* (Abstract).
- GAMBLIN, G.T., HARPER, D.G., GALENTINE, P., BUCK, D.R., CHERNOW, B. & EIL, C. (1983b) Prevalence of increased intraocular pressure in Graves' disease—evidence of frequent subclinical ophthalmopathy. *New Engl. J. Med.* **308**, 420.
- GORMAN, C. (1983) Ophthalmopathy of Graves' disease. *New Engl. J. Med.* **308**, 453. (editorial).
- KENDALL-TAYLOR, P., ATKINSON, S., & HOLCOMBE, M. (1984) A specific IgG in Graves' ophthalmopathy and its reaction in retroorbital and thyroid autoimmunity. *Br. Med. J.* **288**, 1183.
- KODAMA, K., SIKORSKA, H., BANDY-DANFOE, P., BAYLY, R. & WALL, J.R. (1982) Demonstration of a circulating autoantibody against a soluble eye muscle antigen in Graves' ophthalmopathy. *Lancet*, **ii**, 1353.
- KUROKI, T., RUF, J., WHELAN, L., MILLER, A. & WALL, J.R. (1985) Antithyroglobulin monoclonal and autoantibodies cross-react with an orbital connective tissue membrane antigen: a possible mechanism for the association of ophthalmopathy with autoimmune thyroid disorders. *Clin. exp. Immunol.* **62**, 361.
- KUROKI, T., KODOMA, K., CARAYON, P., RUF, J., MILLER, A. & WALL, J.R. (1986) Use of mouse and human monoclonal antibodies to investigate the immunological basis of Graves' Ophthalmopathy. *Mt. Sinai J. Med.* **53**, 60.
- KRISS, J.P., PLESHAKOV, V., ROSENBLUM, A., HODERNES, M., SHARP, G. & UTIGER, R. (1967) Studies of the pathogenesis of the ophthalmopathy of Graves' disease. *J. Clin. Endocrinol. Metab.* **27**, 582.
- RILEY, F.C. (1972) Orbital pathology in Graves' disease. *Mayo. Clin. Proc.* **47**, 975.
- RUNDLE, F.F., FINLAY-JONES, L.R. & NOAD, K.B. (1953) Malignant exophthalmos; a quantitative analysis of the orbital tissues. *Australas. Ann. Med.* **2**, 128.
- SISSON, J.C., KOTHARY, P. & KIRCHICK, H. (1973) The effects of lymphocytes, sera, and long acting thyroid stimulator from patients with Graves' disease on retrobulbar fibroblasts. *J. Clin. Endocrinol. Metab.* **37**, 17.
- SMITH, B.R. & HALL, R. (1974) Thyroid stimulating immunoglobulin in Graves' disease. *Lancet*, **ii**, 427.
- STRAKOSCH, C.R., JOYNER, D. & WALL, J.R. (1978) Thyroid stimulating antibodies in patients with subacute thyroiditis. *J. Clin. Endocrinol. Metab.* **46**, 345.
- VOLPÉ, R. (1977) This role of autoimmunity in hypoendocrine and hyperendocrine function with special emphasis on autoimmune thyroid disease. *Ann. Int. Med.* **87**, 86.
- WALL, J.R. (1984) Immunological aspects of Graves' ophthalmopathy. In: *The Eye and Orbit in Thyroid Disease* (ed. by C. Gorman, R. Waller & J. Dyer) p. 103, Raven Press, New York.
- WALL, J.R. & KUROKI, T. (1985) Immunological factors in thyroid disease. In: *Symposium on Thyroid Disease*. Med. Clinics. (ed. by M. Caplan & P. Larsen) N. America WB Saunders Co. Vol. **69**, 913.
- WALL, J.R. & WRIGHT, D.J.M. (1974) Antibodies against testicular germinal cells in lepromatous leprosy. *Clin. exp. Immunol.* **17**, 51.
- WALL, J.R., TREWIN, A., FANG, S.L., INGBAR, S.H. & BRAVERMAN, L.E. (1978) Studies on immunoreactivity to human lacrimal gland fractions in patients with ophthalmic Graves' disease. *J. Endocrinol. Invest.* **1**, 253.
- WALL, J.R., WALTERS, B.A.J. & GRANT, C. (1979) Leukocyte adherence inhibition in response to human orbital and lacrimal extracts in patients with Graves' ophthalmopathy. *J. Endocrinol. Invest.* **2**, 375.
- WERNER, S. (1969) Classification of the eye changes in Graves' disease. *J. Clin. Endocrinol. Metab.* **29**, 982.
- WERNER, S. (1977) Modification of the classification of the eye changes in disease: recommendations of the ad hoc committee of the American Thyroid Association. *J. Clin. Endocrinol. Metab.* **44**, 203.