

## Section of Otology

President J C Ballantyne FRCS

Meeting 4 February 1977

### Congenital Conductive Deafness

#### Professor Ruth E M Bowden

(Royal Free Hospital School of Medicine,  
8 Hunter Street, London WC1N 1BP)

#### Development of the Middle and External Ear in Man

The development of the external ear, temporal bone and middle ear cleft involves interactions between ectoderm, mesoderm and endoderm. The special sensory receptors derived from the neuroectodermal otic vesicle (Friedmann 1968) are surrounded by mesenchyme in which the cartilaginous otic capsule develops (Baxter 1953, Hamilton *et al.* 1972, Warwick & Williams 1973). This capsule lies medial to the endodermal pharyngotympanic recess. Recent work by Kanagasuntheram (1967) indicates that the lining of the tympanum and its extensions is derived only from the first pharyngeal pouch. The distal ends of the cartilages of the first

and branchial arches are related to, but are outside this endodermal tube (Fig 1). The precise contribution of the cartilages to the formation of the ossicles is still controversial. The classical view is that the malleus and incus differentiate from the first arch cartilage and the stapes from the second (Keith 1948, Baxter 1953, Hamilton *et al.* 1972, Warwick & Williams 1973). On the basis of meticulous reconstructions, Anson & Bast (1949) consider that the footplate of the stapes is either derived exclusively from the lateral wall of the otic capsule or, in some cases, it may have a dual origin from the second arch cartilage and the otic capsule.

According to Hough (1963) certain congenital abnormalities could only be explained if the upper and lower elements of the articular chain were developed from the first and second arch cartilages respectively. (Reconstructions do not support this view, and the possibility of abnormal resorption of cartilage and bone by invading endoderm or by the endodermal/mesodermal junctional tissues should be studied.)

The internal carotid artery runs between the pharyngotympanic tube and the otic capsule (Fig 1) and is later incorporated into bone as ossification extends from the otic capsule to form the carotid canal and bony part of the eustachian tube (Frazer 1946, Warwick & Williams 1973). Occasionally, ossification is incomplete and the artery lies within the tympanum (Glasgold & Horrigan 1972). The nerves of the first, second and third branchial arches (mandibular V, VII and IX) and the stapedial artery, a branch of the hyoid artery, are related to this tube (Fig 2). The artery may persist (Hough 1963, Davies 1967, Bergstrom & Hemenway 1972) but usually disappears in man.

Fig 3 illustrates a later stage of development of the temporal bone and includes the squamous and tympanic parts which are ossified in membrane, and the tympanic membrane which includes ectoderm, mesoderm and endoderm (Lim 1970).

The two membrane bones ossify before the otic

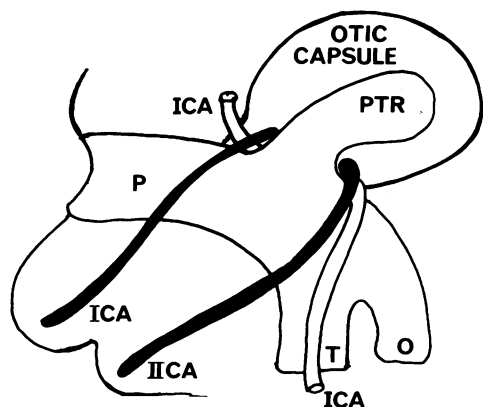


Fig. 1 Lateral view of developing left temporal bone (after Frazer 1946). ICA, IICA, cartilages of first and second branchial arches respectively. P, pharynx. PTR, pharyngotympanic recess. T, trachea. O, oesophagus. ICA, internal carotid artery

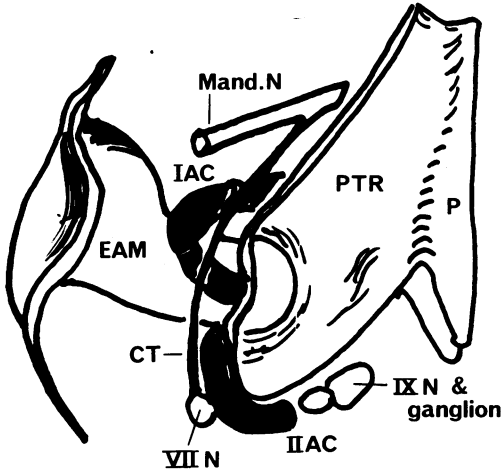


Fig 2 Diagram of reconstructed middle ear of 27 mm embryo (after Hamilton et al. 1972). IAC, IIAC, cartilages of first and second branchial arches respectively. P, pharynx. PTR, pharyngotympanic recess. Mand. N, mandibular branch of fifth cranial nerve. VII N, seventh (facial) cranial nerve. CT, chorda tympani. IX N, ninth (glossopharyngeal) cranial nerve and ganglion. EAM, external auditory meatus

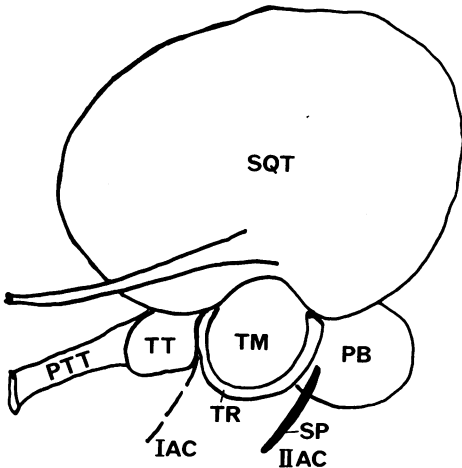


Fig 3 Lateral view of developing left temporal bone (after Frazer 1946). IAC, position of first branchial arch cartilage. IIAC, upper end of second branchial arch cartilage forming the styloid process (SP). PTT, pharyngotympanic tube (eustachian) derived from the pharyngotympanic recess. PB, petrous bone with its process. TT, derived from the cartilaginous otic capsule. SP, styloid process. SQT, squamous temporal bone. TT, tegmen tympani. TR, tympanic ring. TM, tympanic membrane

capsule. A single centre appears during the 7th to 8th week and spreads from the root of the zygomatic process (Frazer 1946, Anson & Bast 1949, Warwick & Williams 1973). The tympanic ring is relatively large, and ossifies from three or four centres which coalesce by the eleventh week (Anson et al. 1955). Ossification of the ossicles begins in the fourth month (Anson et al. 1948), three centres appear in the stapes and are fused by twenty weeks (Dass & Makhni 1966). By eight months the ring and the ossicles are of adult proportions (Fig 5). The ring which holds the triple layered tympanic membrane (Anson et al. 1955) is grooved anteriorly and inferiorly, but not posterosuperiorly (Fig. 6). Congenital cholesteatomata with an intact tympanic membrane are said to be commonest in the petrous attic (Cawthorne 1963). Although suggestive, it cannot be proved that absence of grooving of the tympanic ring predisposes to invasion by aberrant ectodermal tissues.

Ossification of the otic capsule begins in the fifth month from fourteen to sixteen different centres (Anson & Bast 1949, Dass & Makhni 1966). For some time cartilage persists between the cochlea and vestibular areas (Streeter 1906, Anson & Bast 1949). Normally, but not invariably, the cartilage of the otic capsule breaks down around the footplate of the stapes to form the joint and the oval window (Anson & Bast 1949, Nakamura & Sando 1966, Bergstrom & Hemenway 1972).

At 36 to 37 weeks the temporal bone is in three separate parts (Fig 7) which do not fuse until after birth. The tympanic cavity and mastoid antrum, formed by encroachment of the endoderm of the pharyngotympanic tube during the sixth to seven month (Proctor 1969), are adult in size and the VII and VIII nerves and the internal carotid artery

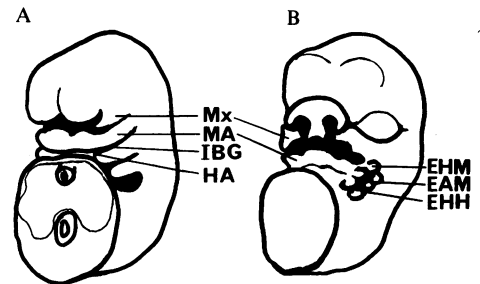


Fig 4 Oblique frontal views of developing face and pharyngeal arches of human embryos (after Streeter 1948). Not to scale. A, 6 mm CR length. B, 14 mm CR length. Mx, maxillary process of first branchial arch. MA, mandibular arch. IBG, first branchial groove. HA, hyoid arch (second branchial arch). EAM, external auditory meatus derived from dorsal end of first branchial groove. EHM, ear hillocks on dorsal extremity of mandibular arch. EHH, ear hillocks on dorsal extremity of hyoid (second) branchial arch

have normally been surrounded by bone (Hough 1963, Rhotan *et al.* 1968, Pou 1971). At birth the tympanic membrane is still markedly oblique in inclination (Fig 8), allowing for accommodation of the adult size structure in the late fetal and infant face (Davies 1967). Subsequent changes in position must lead to alterations in the orientation of the ossicular chain. Not only growth but also development, in the proper sense of the term, continues until puberty with the formation of the mastoid process and varying degrees of pneumatization associated with invasion of the bone by the mucosa of the middle ear cleft (Fig 9).

Study of histological sections clarifies some of the significant points of development. The otic placode appears at 21–24 days (Fig 10), and sinks below the surface as a vesicle which lies in undifferentiated mesenchyme. By the fifth week the mesenchyme condenses round the vesicle which has undergone changes in shape (Fig 11A), but in this embryo of 7.5 mm crown-rump (CR) length there is no sign of the external auditory meatus (Fig 11B). A relatively huge acousticofacial ganglion is seen in an 8.5 mm CR length embryo in Fig 12. The otic vesicle undergoes rapid modification to form the membranous labyrinth between four and six and a half weeks, i.e. late somite to approximately 30 mm CR length (O'Rahilly 1963, Hamilton *et al.* 1972). These stages in development are shown in models based on Streeter's reconstructions (Streeter 1906). However, they do not show the change in orientation from vertical to horizontal during the last stage (Anson & Bast 1949), a change which is correlated with alterations in the flexion of the neck and therefore in the posture of the head (Fig 13).

The endodermal tubotympanic recesses are shown in horizontal section in a 12 mm CR embryo in Fig 14. They are anterolateral to the otocyst and have not yet reached the surface of the head.

A parasagittal section of the left side of the head of a 13 mm CR length embryo shows the acute flexion of the neck and low position of the developing ear (Fig 15). The trigeminal ganglion and the three main divisions of the nerve are seen passing to their distribution to parts derived from the frontonasal, maxillary and mandibular processes respectively. The acousticofacial ganglion is intimately related to the membranous otocyst.

The external appearance of the face at 6 and 12 mm CR lengths (i.e. 5 and 6 weeks respectively) is illustrated in Fig 4. The secondary auditory pit, the future external auditory meatus, lies at the dorsal end of the first branchial groove between the hyoid and mandibular arches. In Fig 4B the ear hillocks from which the pinna is derived have developed, three on each side of the external auditory meatus (Jones & I-Chuan Wen 1934, Keith 1948, Baxter 1953, Wilson 1959, Hamilton *et*

*al.* 1972, Warwick & Williams 1973). By the fourth month the pinna reaches the normal position and is morphologically complete provided no toxic or adverse gene effects are operative (Livingstone & Delahunty 1962, Scheer 1967, Morgon *et al.* 1970, Bergstrom & Hemenway 1972, Bergstrom *et al.* 1974). The external auditory meatus extends medially and at its inner extremity there is a plug of epithelium around which the mesenchyme differentiates into elastic cartilage (Figs 16 and 17). At seven weeks (Fig 16) there is a considerable amount of tissue between the ectodermal lining of the meatus and the endoderm of the middle ear cleft. As the ectodermal meatus extends medially (Dayal *et al.* 1973), the endodermal tube is invading the intervening mesoderm surrounding the distal ends of the first and second branchial cartilages and the facial nerve as it pursues its angulated course towards the face (Keith 1948, Baxter 1953, Proctor 1969). The behaviour of mesenchyme in relation to endodermal and ectodermal structures appears to differ in very early chick embryos (M England 1977, personal communication). Although extrapolation to human embryos and fetuses at a much later date is not permissible, it is clear that cytochemical and electron microscopical studies of this phenomenon of benign invasion of endoderm and programmed death of mesenchyme in the mammal would be of interest and might explain certain anomalies (cf. Hough 1963). Figs 17 and 18 are of the same 25 mm CR embryo (7th week) but are taken at different levels. The lower section (Fig 17) shows a single middle ear cavity and the higher one (Fig 18) shows two pockets of the encroaching endodermal sac (Anson *et al.* 1948, Glasgold & Horrigan 1972, Bollabás & Hajdu 1975).

In Fig 20 the facial nerve and the chorda tympani can be seen lying in close relation to the cartilaginous otic capsule and surrounded by mesenchyme which still occupies the greater part of the future tympanic cavity. Although the arch cartilages show signs of differentiating joints they are completely embedded in mesenchyme. Spaces have appeared around the membranous labyrinth and these and the formation of the round and oval windows are attributed to the action of histiocytes (Andersen & Matthiessen 1966, Andersen *et al.* 1969). The perilymphatic spaces are more clearly seen in Fig 19. In this 49 mm CR fetus a joint cavity has developed between the malleus and incus (Andersen 1964, Andersen *et al.* 1969). The squamous temporal bone has ossified and this section passes through the epitympanic recess. (Since all three ossicles including an abnormal 'banana' stapes are seen, this probably reflects the alignment of chain imposed by the extreme obliquity of the tympanic membrane.)

Figs 21–24 are from a 4½-month fetus. They

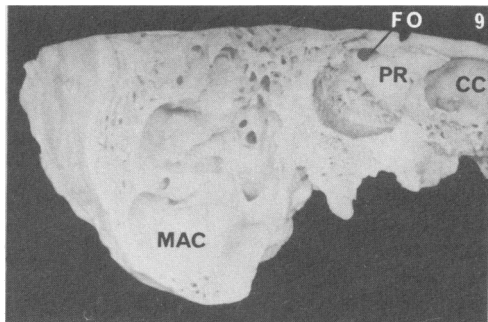
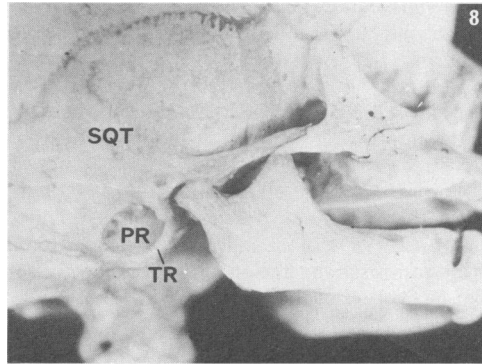
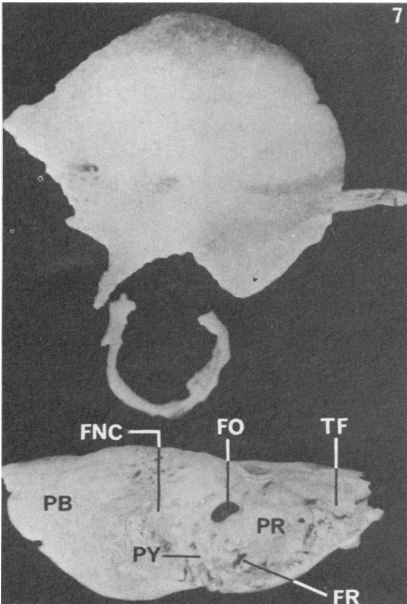
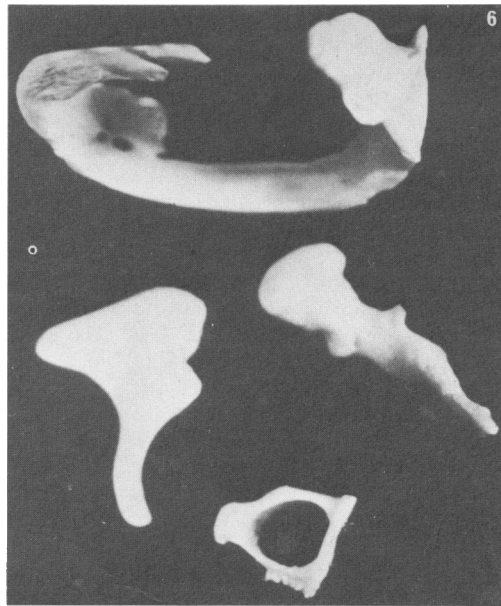
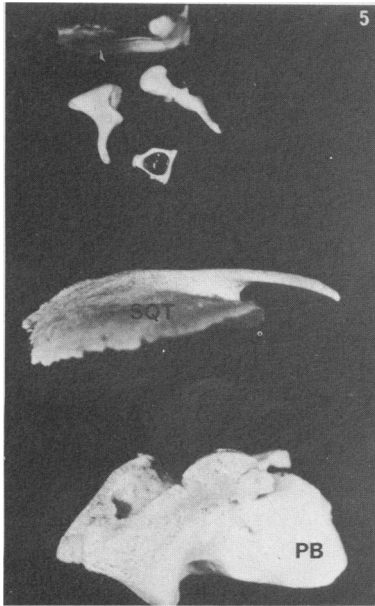


Fig 5 Left temporal bone and ossicles of 8-month human fetus. PB, petrous bone. SQT, squamous temporal. Note relatively large size of ossicles and tympanic ring.  $\times 1.8$   
 Fig 6 Enlargement of tympanic ring and ossicles of Fig 5. Note the absence of groove posteriorly and the small openings in the ring.  $\times 7$   
 Fig 7 Right temporal bone of 36-37-week human fetus. The petrous bone (PB), tympanic ring and squamous parts are unfused. FNC, ridge overlying canal for the facial nerve. FO, fenestra ovalis. FR, fenestra rotunda. PR, promontory. PY, pyramid. TF, tegmen tympani.  $\times 1.5$   
 Fig 8 Skull of 32-36-week fetus showing the obliquity of the large tympanic ring (TR) even when the skeleton has been tilted (note lower borders of right and left sides of the mandible). PR, promontory. SQT, squamous temporal bone  
 Fig 9 Part of adult right temporal bone showing numerous large mastoid air cells (MAC), which develop postnatally by encroachment and extension of the middle ear cleft. FO, fenestra ovalis. PR, promontory. CC, carotid canal

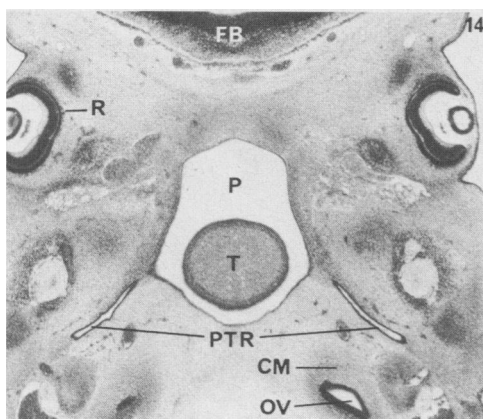
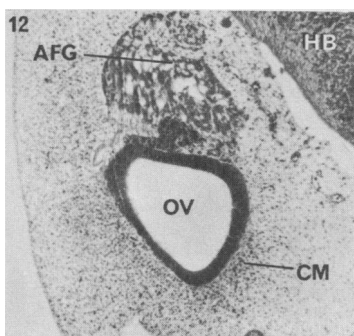
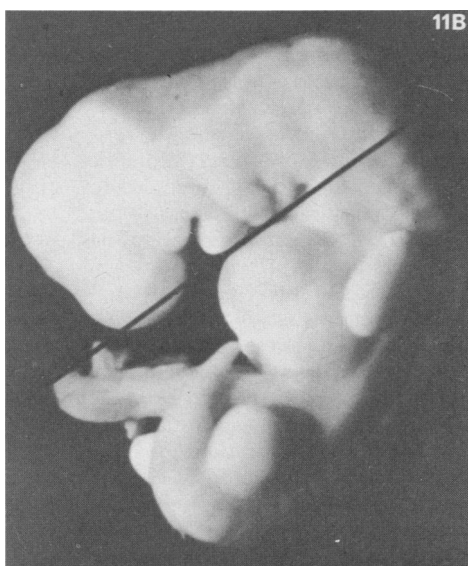
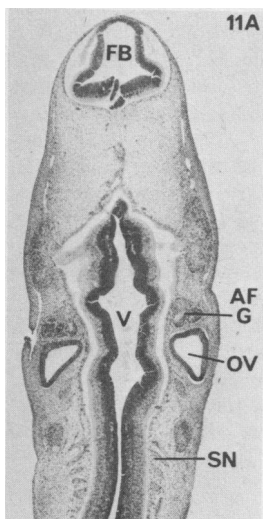
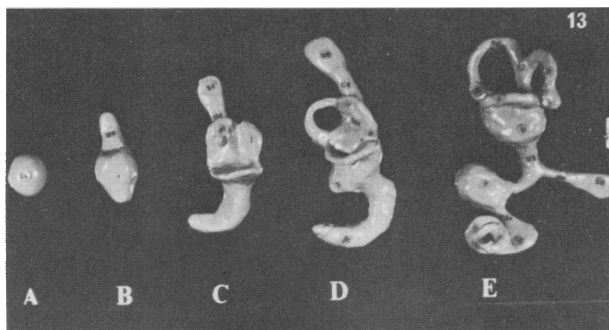
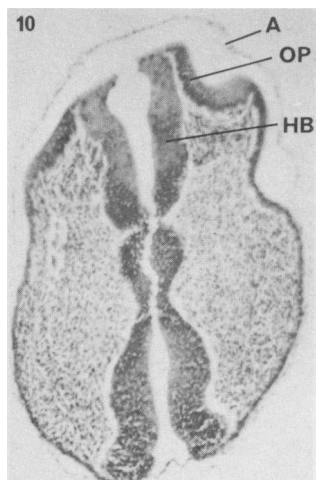


Fig 10 Transverse section through cephalic end of 2 mm human embryo. A, amnion. HB, hindbrain. OP, otic placode. *Hæmatoxylin and Biebrich Scarlet.*  $\times 32$  original with  $\times 2$  photographic enlargement  
 Fig 11A 7.5 mm human embryo (see Fig 11B for plane of sectioning). AFG, acousticofacial ganglion. FB, forebrain vesicle. OV, otic vesicle. SN, segmental spinal nerve. V, fourth ventricle. H & E. (CCHMSC B/26/5 R3-3.)  $\times 21$   
 Fig 11B Left lateral view of Barnes 7.5 mm embryo. The line marks plane of sectioning of embryo. (CCHMSC.)  $\times 9.3$   
 Fig 12 8.5 mm human embryo. OV, left otic vesicle. AFG, acousticofacial ganglion. HB, hindbrain. CM, condensation of mesenchyme around otic vesicle. (CCHMSC Purdie Sl.4 R1-7.)  $\times 70$   
 Fig 13 Models of developing membranous labyrinth based on reconstructions of Streeter (1906). Not to scale. A, late somite stage (c. 4 weeks). B, 6 mm CR length. C, 12 mm CR length. D, 20 mm CR length. E, 30 mm CR length (6½ weeks)  
 Fig 14 12 mm human fetus. Horizontal section of head through eye and developing ear. FB, forebrain. P, pharynx. PTR, pharyngotympanic recess. R, pigmented and nervous layers of retina. T, tongue. CM, condensation of mesenchyme around the otic vesicle (OV). (CCHMSC Doyle 23R 1-4.) H & E.  $\times 29$   
 (CCHMSC = Charing Cross Hospital Medical School collection)

show evidence of multiple centres of ossification in the otic capsule, early signs of ossification in the ossicles, the well-defined orientation of the mesenchyme (Guggenheim 1971) and a cavity forming in relation to the tympanic ring in the region of the membrane.

By 230 mm CR length ossification of the cartilaginous otic capsule is advanced but not complete and may remain defective (Harrington & Herbert 1967). The modiolus ossifies in membrane (Anson & Bast 1949). The walls of the eustachian tube are approximated.

By 30 weeks the tympanum is completed although the epitympanic recess is not pneumatized until about a week before birth (Dayal *et al.* 1973). The mucosa has been described as œdematous and thick and according to some authorities the middle ear cavity is fluid-filled at birth, whether due to mucosal secretions or aspiration of fluids is not clear (Dayal *et al.* 1973). (Recent investigations on neonates casts doubts on the presence of fluid in the cavity (A W Morrison 1977, personal communication).) However, it is of interest that encephalographic recording from neonates has demonstrated that for two days there is conductive impairment which clears rapidly (Engel 1975). The eustachian tube is said to open in association with the efforts of establishing respiration; possibly swallowing is a more important factor.

Although surfactant is said to be present and to play a part in maintaining patency of the eustachian tube, no references have been found in the literature. The presence of surfactant seems unlikely in the light of Pattle's classical work (1958)

on respiratory passages, for it was never found in association with ciliated epithelium, and the lining of the tube, tympanum and tympanic membrane is known to be ciliated, at least in patches (Kawabata & Paparella 1969, Lim 1970). (Dr Pattle (1977, personal communication) has conducted preliminary experiments on the rat and failed to find surfactant in the middle ear.)

The precocious development of special sensory endings and the slower development of the external and middle ears raise interesting questions in relation to functional completion. Early attempts to assess hearing in utero suggested that reliable results could not be obtained before 26 weeks (Wilson 1967). However, the mode of stimulation and use of an increased pulse rate as evidence of auditory function are open to other interpretations. More reliable information can be obtained by electroencephalography of premature and full-term neonates. Each conceptual age has characteristic EEG patterns of activity (Curzi 1976; Pampiglione 1977, personal communication). Between 23 and 45 weeks of conceptual age progressive changes are found in potentials evoked by ordinary stimuli (Regan 1972). Engel (1975) reported hearing 'levels' very close to adult norms through the frequency range 250–8000 Hz in 75 randomly selected neonates. The evidence of an impairment of conduction has already been noted above. Engel stressed that the fact that an evoked potential can be recorded, signals the arrival of an impulse on the cortex, but is not necessarily the equivalent of the psychological event of hearing.

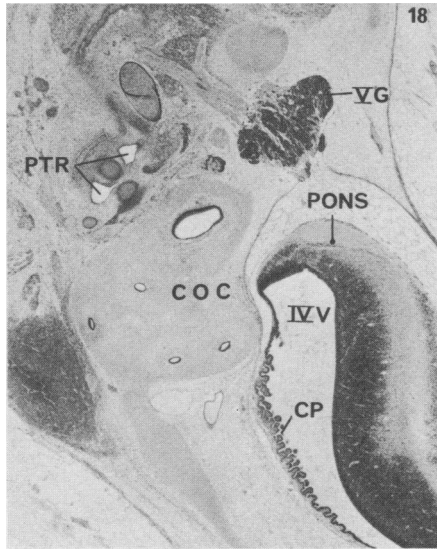
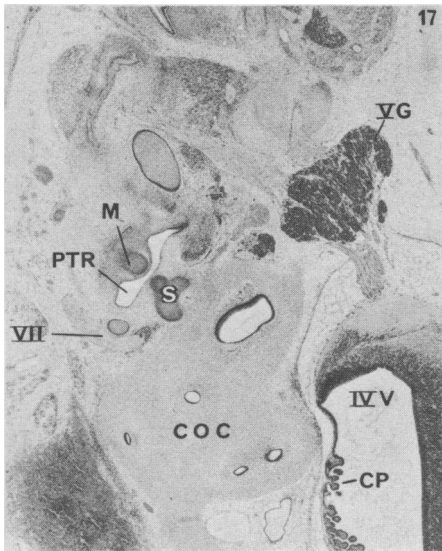
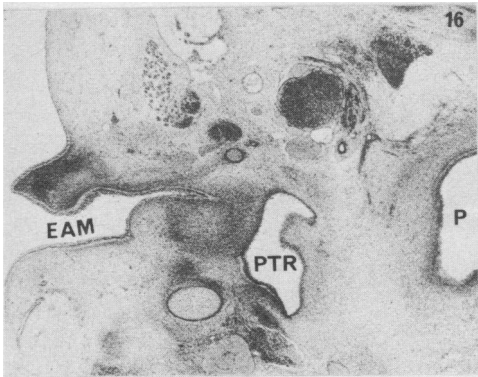
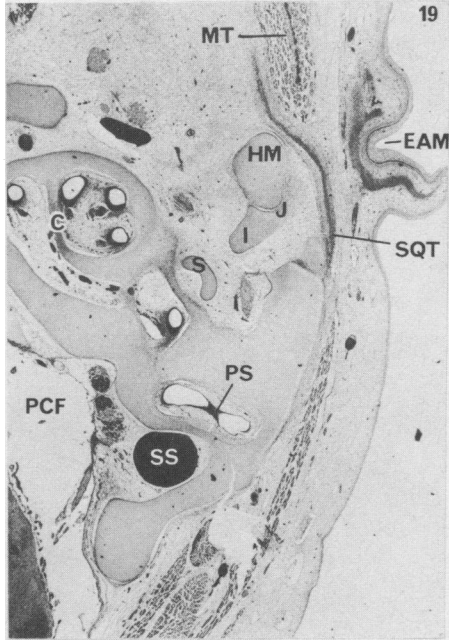
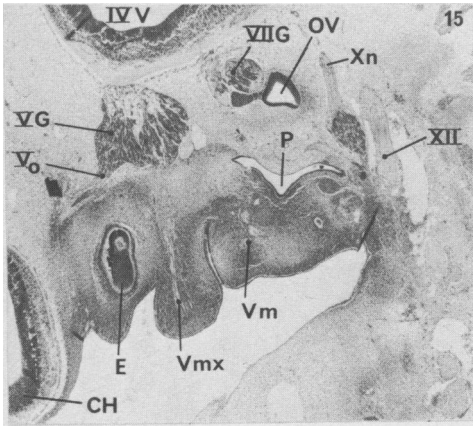
Fig 15 *Sagittal section 13 mm CR human embryo. Note the persistence of flexion of the neck (cf. Fig 11B) and the low position of the otic vesicle. CH, left cerebral vesicle. E, developing eye. V G, trigeminal ganglion. V o, ophthalmic division of fifth nerve. V mx, maxillary division of fifth nerve. V m, mandibular division of fifth nerve. VII G, facial nerve ganglion. OV, developing membranous labyrinth. P, pharynx. X n, vagus and ganglion. XII, hypoglossal nerve. IV V, fourth ventricle. (Hall, Sl.7 R1-3.) × 25*

Fig 16 *20 mm CR length human embryo. Horizontal section through left external auditory meatus (EAM). Note: the epithelial plug and the condensation of mesenchyme around the meatus from which the cartilage will develop; the distance between the ectodermal epithelium and the endodermal lining of the pharyngotympanic recess (PTR). P, pharynx. (CNS 16 Sl.361 R2-2.) × 27*

Fig 17 *Horizontal section of 22 mm CR human embryo showing the extension of the left pharyngotympanic tube between the malleus (M) and incus and stapes (S). V G, trigeminal ganglion. VII G, seventh (facial) cranial nerve. COC, cartilaginous otic capsule surrounding the various parts of the membranous labyrinth with no perilymphatic space. IV V, fourth ventricle. CP, choroid plexus of fourth ventricle. (Peglar Sl.302 R1-2.) × 20*

Fig 18 *Same embryo as Fig 17 but sectioned more cranially. Note the extending recess (PTR) now in two sections and not a single cavity. Key as for Fig 17. (Peglar Sl.306 R1-2.) × 17.5*

Fig 19 *Horizontal section 49 mm CR length embryo. EAM, right external auditory meatus with developing elastic cartilage of pinna. SQT, ossifying squamous temporal bone. MT, temporalis muscle. HM, head of malleus. J, joint cavity between malleus and incus. I, incus. S, stapes crura only; no footplate was found, this is a 'banana stapes'. PS, perilymphatic space forming around membranous labyrinth by destruction of cartilaginous otic capsule. C, developing cochlea. PCF, posterior cranial fossa. SS, sigmoid sinus.*



Figs 15-19 (All sections are from Charing Cross Hospital Medical School collection and are stained with H & E)

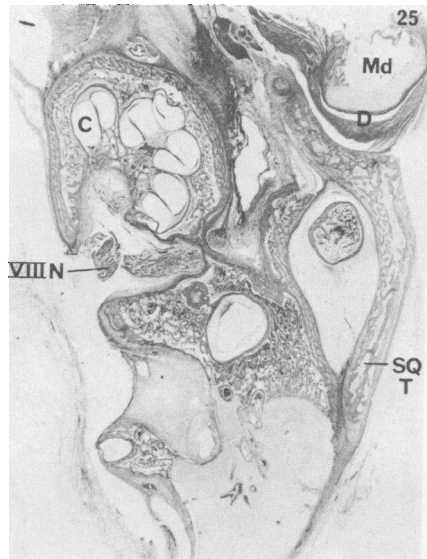
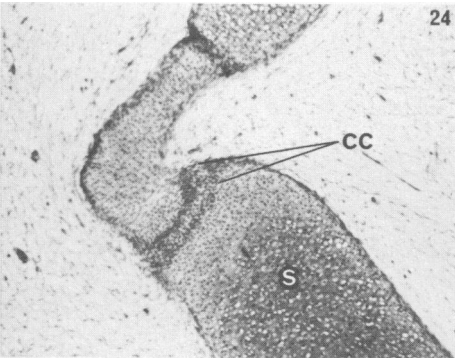
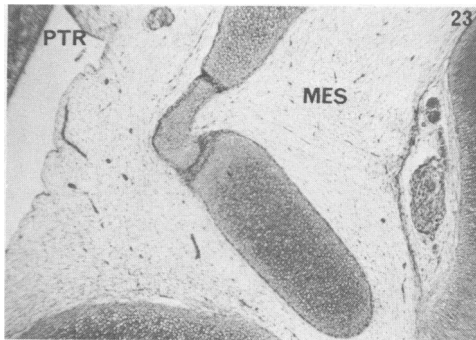
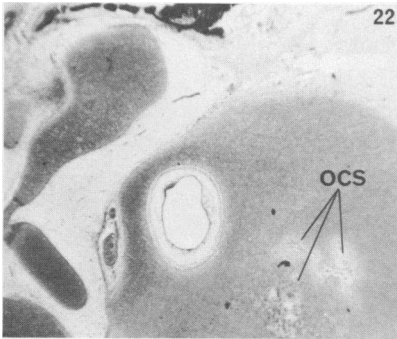
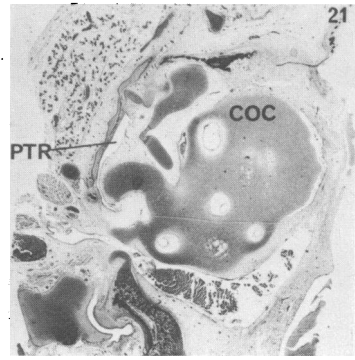
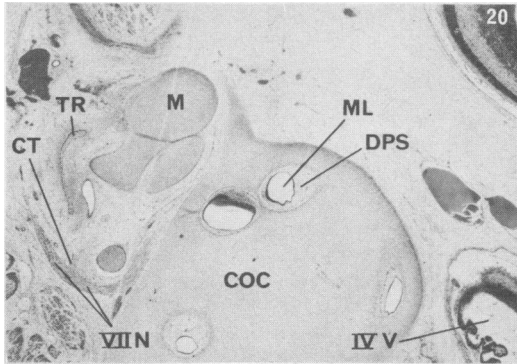


Fig 20 40 mm CR length human embryo. Left side. M, malleus. ML, membranous labyrinth. DPS, developing perilymphatic space. COC, cartilaginous otic capsule. VII N, facial nerve. CT, chorda tympani branching off the main facial nerve trunk. IV V, fourth ventricle. (CCHMSC Leach Sl. 131 R1-2.)  $\times 17.6$

Fig 21 Human embryo c. 4½ months. General arrangement of ossicles, cartilaginous otic capsule (COC) and encroaching pharyngotympanic recess (PTR). Hæmatoxylin and Biebruch Scarlet.  $\times 4$

Fig 22 Same embryo as Fig 21,  $\times 10$ . Note several centres of ossification (OCS) in the cartilaginous otic capsule

Fig 23 Same embryo as Figs 21 and 22,  $\times 20$ . Note the arrangement of mesenchyme (MES) surrounding the cartilaginous ossicles and the encroaching pharyngotympanic recess (PTR)

Fig 24 Same embryo as Figs 21-23,  $\times 40$ . Note the condensation of cartilage (CC) in the region of the developing incudostapedial joint, also orientation of the mesenchyme. S, stapes

Fig 25 Horizontal section 230 mm CR length human embryo, showing ossification of petrous is incomplete. C, cochlea. VIII N, eighth nerve. Md, head of mandible. D, intra-articular disc of temporomandibular joint. SQT, squamous temporal. (CCHMSC RB Sl.7.) H & E

(CCHMSC = Charing Cross Hospital Medical School collection)



**Acknowledgments:** Grateful thanks are due to Professor A T Glenister for generously allowing complete freedom of access to the late Professor W J Hamilton's selection of embryos and fetuses at Charing Cross Hospital Medical School; to Mr Reginald Watts who prepared these serial sections; to Miss Hudson for colour transparencies and black-and-white photographs illustrating these preparations; to the late William Matthews for sections in the Royal Free Hospital School of Medicine collection; and to the Photographic Department of the RFHSM.

## REFERENCES

- Andersen H**  
(1964) *Acta anatomica* **58**, 90
- Andersen H & Matthiessen M E**  
(1966) *Zeitschrift für Zellforschung und mikroskopische Anatomie* **72**, 193
- Andersen H, Matthiessen M E & Jørgensen B**  
(1969) *Acta otolaryngologica (Stockholm)* **68**, 243
- Anson B J & Bast T H**  
(1949) *The Temporal Bone and the Ear*. Thomas, Springfield, Illinois; pp 163–257, 306–315, 337–374
- Anson B J, Bast T H & Cauldwell E W**  
(1948) *Annals of Otolology, Rhinology and Laryngology* **57**, 603
- Anson B J, Bast T H & Richany S F**  
(1955) *Annals of Otolology, Rhinology and Laryngology* **64**, 802
- Baxter J S (ed)**  
(1953) *Frazer's Manual of Embryology*. 3rd edn. Baillière, Tindall & Cox, London; pp 202–205, 235–243
- Bergstrom La V & Hemenway W G**  
(1972) *Laryngoscope* **82**, 1777
- Bergstrom La V, Stewart J M & Kenyon B**  
(1974) *Laryngoscope*, **84**, 1905
- Bollabás B & Hajdu I**  
(1975) *Journal for Otolaryngology and its Borderlands* **37**, 97
- Cawthorne T**  
(1963) *Archives of Otolaryngology* **78**, 248
- Curzi L**  
(1976) Thesis, Université de Paris, Sud Centre d'Orsay, Orsay No. d'ordre 1685
- Dass R & Makhni S S**  
(1966) *Archives of Otolaryngology* **84**, 306
- Davies D G**  
(1967) *Journal of Laryngology and Otolology* **81**, 649
- Dayal V S, Farkashidy J & Kokshanian A**  
(1973) *Canadian Journal of Otolaryngology* **2**, 136
- Engel R C H**  
(1975) *Auditory Evoked Potentials from Abnormal Electroencephalograms in the Neonatal Period*. Thomas, Springfield, Illinois; pp 17, 21, 73–74, 82–83, 110–116, 118
- Frazer J E**  
(1946) *The Anatomy of the Human Skeleton*. 4th edn. J & A Churchill Ltd, London; p 173
- Friedmann I**  
(1968) *Journal of Laryngology and Otolology* **82**, 185
- Glasgold A I & Horrigan W D**  
(1972) *Laryngoscope* **82**, 2217
- Guggenheim P**  
(1971) *Laryngoscope* **81**, 1665
- Hamilton W J, Boyd J D & Mossman H W**  
(1972) *Human Embryology*. 4th edn. Heffer, Cambridge; Williams & Wilkins, Baltimore; pp 509–516, 532–539
- Harrington J W & Herbert G B**  
(1967) *Archives of Otolaryngology* **85**, 572
- Hentzer E**  
(1969) *Acta Otolaryngologica (Stockholm)* **68**, 376
- Hough J V D**  
(1963) *Archives of Otolaryngology* **78**, 335
- Jones F W & I-Chuan Wen**  
(1934) *Journal of Anatomy (London)* **68**, 525
- Kanagasuntheram R**  
(1967) *Journal of Anatomy (London)* **101**, 731
- Kawabata I & Paparella M M**  
(1969) *Annals of Otolology, Rhinology and Laryngology* **78**, 125
- Keith A**  
(1948) *Human Embryology and Morphology*. Edward Arnold, London
- Lim D J**  
(1970) *Acta Otolaryngologica (Stockholm)* **70**, 176
- Livingstone G & Delahunty J E**  
(1962) *Journal of Laryngology and Otolology* **82**, 495
- Morgon A, Charachon D & Bringuier N**  
(1970) *Minerva Otolaryngologica* **20**, 166
- Nakamura S & Sando I**  
(1966) *Archives of Otolaryngology* **84**, 131
- O'Rahilly R**  
(1963) *Journal of Embryology and Experimental Morphology* **11**, 741
- Pattie R E**  
(1958) *Proceedings of the Royal Society, Series B* **148**, 217
- Pou J W**  
(1971) *Laryngoscope* **81**, 831
- Proctor B**  
(1969) *Annals of Otolology, Rhinology and Laryngology* **78**, 1026
- Regan D**  
(1972) *Evoked Potentials in Psychology, Sensory Psychology and Clinical Medicine*. Chapman & Hall, London; pp 187–188
- Rhotan A L, Pulec J L, Hall G M & Boyd A S**  
(1968) *Journal of Neurosurgery* **28**, 48
- Scheer A A**  
(1967) *Archives of Otolaryngology* **85**, 55
- Streeter G L**  
(1906) *American Journal of Anatomy* **6**, 139
- Streeter G L**  
(1948) *Contributions to Embryology* **32**, 133
- Warwick R & Williams P L (eds)**  
(1973) *Gray's Anatomy*. 3rd edn. Longman, London &c; pp 147–149
- Wilson C P**  
(1959) *Acta Otolaryngologica (Stockholm)* **50**, 225
- Wilson T C**  
(1967) *Proceedings of the Royal Society of Medicine* **60**, 407.