

## Section of Medicine, Experimental Medicine & Therapeutics

President R D Cohen FRCP

Meeting 8 March 1977

### Immunological Disturbance in Diseases of Liver and Thyroid

**Professor Sheila Sherlock**

(Department of Medicine,  
Royal Free Hospital, Pond Street,  
London NW3 2QG)

#### Immunological Changes in Liver Disease

Immunological changes in liver disease may be divided into two groups. The first is the immunological effect induced by liver damage irrespective of the cause, and the second is the specific changes seen in any particular liver disease and their relationship to aetiology and diagnosis.

#### Hyperglobulinæmia

Elevation of total serum globulin levels is a well-known phenomenon accompanying most forms of liver disease. It was the basis of positivity of many of the seroflocculation tests now no longer used. Recognition of the different fractions of the total serum globulin concentration has been fruitful and has led to the first indications of an abnormal immune response in patients with chronic liver disease. Since gammaglobulin levels to a great extent reflect antibody-like protein levels, the hypergammaglobulinæmia, which is associated with an increased turnover rate, is likely to be part of an immunological response.

Electrophoresis of the serum proteins shows a polyclonal response in patients with chronic hepatocellular disease. The increase in gammaglobulin also involves fast gammaglobulin and leads to a characteristic filling in of the gap normally present between the beta- and gammaglobulins (Fig 1). Rarely, a monoclonal picture may be seen. Of 27 patients 18 were found with liver disease and cryoglobulinæmia and 6 of these with monoclonal immunoglobulins were found to have antibody activity, directed to human gammaglobulin, alpha

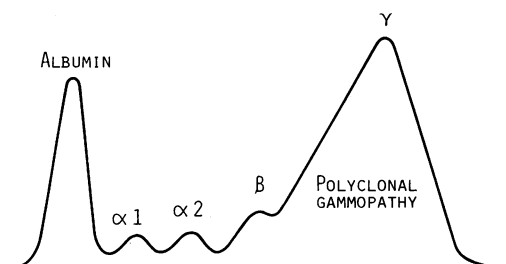


Fig 1 *Electrophoresis of plasma proteins in cirrhosis. Note reduced albumin and high wide  $\gamma$  peak. The gap between  $\beta$  and  $\gamma$  is filled in*

fetoprotein, smooth muscle and mitochondria (Roux *et al.* 1974).

The mechanism for the increased serum antibody levels has only recently been investigated. In part it may be related to increased tissue autoantibodies, such as smooth muscle antibody, which will be discussed later. However, the major component seems related to failure of the damaged liver to clear antigen. Havens *et al.* (1951) reported that patients with alcoholic cirrhosis produced excessive amounts of antibody in response to tetanus toxoid injections, but this could not be confirmed (Cherrick *et al.* 1959). Interest in the topic was revived when it was reported that patients with chronic liver disease showed increased antibody to gastrointestinal tract antigens particularly *E. coli* (Bjorneboe *et al.* 1972, Triger *et al.* 1972). Antibodies to these and similar dietary or bacterial antigens of gastrointestinal origin may be responsible for the hyperglobulinæmia of chronic liver disease (Fig 2). The portal venous blood normally contains a heavy load of antigens of micro-organisms and their products, and dietary protein components but this is probably not increased in patients with chronic liver disease. The

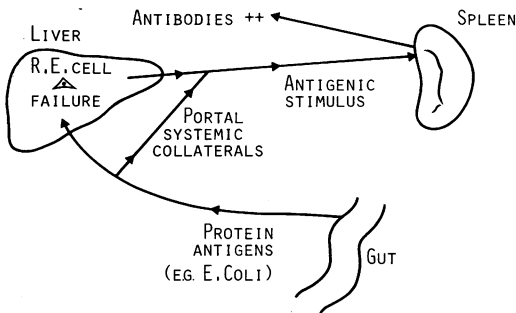


Fig 2 Mechanism of increased serum antibody levels in cirrhosis. Protein antigens from the gut bypass reticulo-endothelial (RE) (Kupffer) cells in the liver and produce an antigenic stimulus to other organs, particularly the spleen, so increasing serum antibodies

problem is in portal-systemic bypassing, which may be through the liver as in cirrhosis, or extra-hepatic through portal-systemic collateral channels such as oesophageal varices. The Kupffer cells, macrophages lining the hepatic sinusoids, have an enormous capacity to sequester antigenic material, possibly for months after exposure. Injections of antigen into the rat portal vein induce a much lower antibody response than if similar material is injected into the inferior vena cava (Triger *et al.* 1973). If the phagocytic function of the liver is reduced by previous injections of such particulate matter as carbon or dextran sulphate, the antigen is disposed elsewhere in the reticulo-endothelial system and is diverted to other organs such as the spleen. The antibody response is increased (Thomas *et al.* 1973, Souhami 1972). This phagocytic function is reduced in animals with experimental cirrhosis or with porta-caval anastomosis.

Patients with cirrhosis also show impairment of physiological elimination of antigens by the liver (Eckhardt *et al.* 1976). In patients with cirrhosis, there is little evidence that the hepatic macrophages function poorly. There is however plenty of opportunity for these phagocytic cells to be bypassed by portal venous blood either within the liver itself in cirrhosis or through portal-systemic collaterals (Sherlock 1975). Once in the systemic circulation, these intestinal antigens are distributed and provoke an increased antibody response from such organs as the spleen. The depressed cell-mediated (T-cell) immunity associated with chronic liver disease may also be important. This would release inhibition of B lymphocytes (antibody formers) as a consequence of lack of suppressive T cells. This concept has been confirmed by observations on rats rendered cirrhotic by carbon tetrachloride (Thomas *et al.* 1976). These animals showed reduced susceptibility to the induction of tolerance by the oral administration of a protein antigen and this is dependent on depressed T-cell function.

### Immunologically-related Liver Disease

The regular demonstration, in high titre, of serum antibody tests such as antinuclear fluorescence (ANF), smooth muscle antibody (SMA) and antimitochondrial antibody (MA) are virtually confined to three liver diseases; chronic active hepatitis, primary biliary cirrhosis and cryptogenic cirrhosis, particularly in women (Doniach & Walker 1969). Results are negative in such conditions as alcoholic liver disease, Wilson's disease and sclerosing cholangitis, even though the extent of hepatocellular or biliary damage may be as great. This suggests that the increases do not simply result in antibodies developing as a response to injury of liver cells or bile ducts. Moreover, there is a considerable overlap between the hepatic histology of chronic active hepatitis and primary biliary cirrhosis. Serum immunoglobulin patterns of chronic active and cryptogenic cirrhosis are very similar. This may represent a response to the same or similar antigenic stimuli. Cirrhosis ultimately develops in many patients with chronic active hepatitis. It is possible that cryptogenic cirrhosis may be the late stage of a subclinical chronic active hepatitis.

The immunological changes in chronic active hepatitis and primary biliary cirrhosis will now be discussed with particular reference to mechanisms of tissue injury and to the presence of antibodies in the serum which may be of diagnostic importance.

### Chronic Active Hepatitis

Chronic active hepatitis presents as variable, fluctuant hepatocellular jaundice. Symptomatic portal hypertension (ascites, bleeding oesophageal varices) is late.

**Biochemistry:** Serum bilirubin is raised, serum transaminase values are usually increased five times and the gammaglobulin concentration is at least elevated to twice its normal amount.

**Hepatic histology** shows a portal zone inflammatory infiltrate of lymphocyte and plasma cells with extension into the liver lobule causing erosion of the limiting plate and piecemeal necrosis. Portal zone fibrosis is usually present and active septa extend into the hepatic parenchyma. The condition should have lasted for at least six months.

**Ætiology:** This common clinical, biochemical and hepatic histological picture has been associated with more than one ætiological agent. There are two varieties where immunological changes are particularly marked. One is associated with a persistence of hepatitis B surface antigen (HB<sub>s</sub>Ag) in the serum. The other is associated with a negative HB<sub>s</sub>Ag test and is sometimes termed

'lupoid' because of the association with a positive lupus erythematosus (LE) cell phenomena in some 15% of patients. Others such as Wilson's disease and drug-related chronic active hepatitis, do not have such close immunological associations.

*Immunological mechanisms of liver injury:* The HB<sub>s</sub>Ag positive type has been most intensively investigated because an antigen can be identified. In the HB<sub>s</sub>Ag negative patient, no such antigen has been constantly identified. However, a liver specific membrane antigen has been recently identified in this condition and delayed hypersensitivity against it reported (Hopf *et al.* 1976). Fixed antibodies are demonstrable on the hepatocellular membrane. Liver membrane autoantibodies have been shown in the serum (Tage-Jensen *et al.* 1977).

The possible immunological mechanisms mediating hepatocyte injury have been well reviewed recently (Edgington & Chisari 1975, Paronetto & Popper 1976) (Fig 3). The first possibility is a direct action on an altered liver cell membrane by a complement fixing antibody. There is little evidence of this in HB<sub>s</sub>Ag positive liver disease. In the HB<sub>s</sub>Ag negative group, however, this could be so, the antigen being the liver specific membrane protein (Hopf *et al.* 1976).

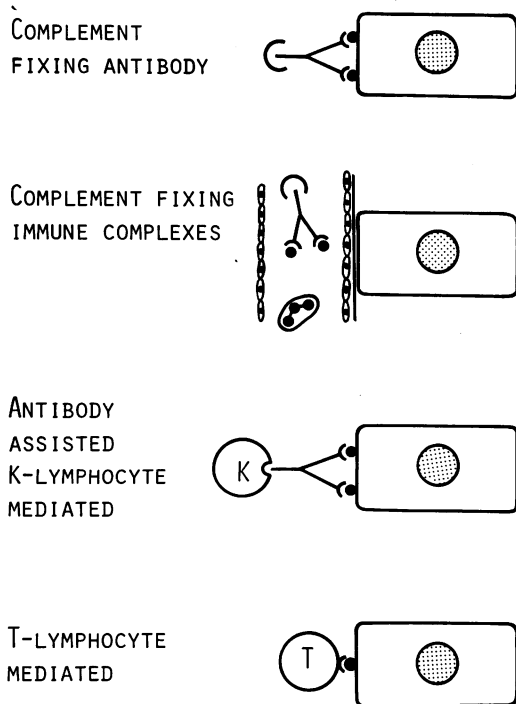


Fig 3 Possible cytotoxic mechanisms of liver cell injury

Local immune complex formations are unlikely as a cause of direct liver injury in man. HB<sub>s</sub>Ag can form complexes with HB<sub>s</sub>Ab and complement. These have been associated with the polyarteritis which rarely complicate chronic HB<sub>s</sub>Ag infection. However, such complexes have not been demonstrated in liver and their presence in the blood correlates poorly with the degree of liver damage.

The cytotoxicity might be T cell mediated (Dudley *et al.* 1972a). This immune response is particularly important in determining the clinical manifestations and course of viral infections. HB<sub>s</sub>Ag positive chronic hepatitis develops in those with a defective cellular immune response to HB<sub>s</sub>Ag and progressive liver damage is the result of continuing immunological reaction against hepatocytes bearing these antigens. There might be defective recognition of viral antigens on the hepatocyte surface by T lymphocytes (Dudley *et al.* 1972a). Cellular immunity to HB<sub>s</sub>Ag has been demonstrated by leukocyte migration studies and shown to be defective in those with chronic hepatitis (Dudley *et al.* 1972b). In HB<sub>s</sub>Ag negative patients the agent inducing the abnormality in the hepatocyte is unknown. Cellular immunity to the liver specific protein of Meyer zum Buschenfelde has however been shown to be defective in these patients (Meyer zum Buschenfelde & Miescher 1972, Miller *et al.* 1972). Lymphocytotoxins have been demonstrated in acute and chronic hepatitis and might contribute to a depressed lymphocyte function (Dehoratius *et al.* 1976).

Finally, and this seems the most important mechanism, the necrosis might be related to antibody directed cellular cytotoxicity. Peripheral blood lymphocytes from patients with chronic active hepatitis are directly cytotoxic towards hepatocytes when tested in an *in vitro* micro-cytotoxicity assay (Cochrane *et al.* 1976). This cytotoxicity may be mediated not by T lymphocytes but by another lymphocyte, termed K (killer). This process may be particularly marked in lymphocytes from HB<sub>s</sub>Ag negative patients and less so in HB<sub>s</sub>Ag positive ones (Jacques *et al.* 1976). Immunosuppressant therapy with prednisolone with or without azathioprine has been shown of greater benefit in HB<sub>s</sub>Ag negative than in HB<sub>s</sub>Ag positive patients with chronic active hepatitis (Schalm *et al.* 1976). It is of interest that prednisolone reduces cytotoxicity of lymphocytes against cultured lymphocytes much more in HB<sub>s</sub>Ag negative than in HB<sub>s</sub>Ag positive patients.

*Primary Biliary Cirrhosis*

This is a granulomatous destruction of small intrahepatic bile ducts, largely affecting middle-aged women. The main bile ducts are patent. The clinical picture is of progressive cholestasis (obstructive jaundice).

**Mechanisms of bile duct destruction:** These are unclear. Research is restricted because, unlike chronic active hepatitis, no antigen has been identified. The disturbance in cell-based immunity is shown by granuloma formation not only related to injured bile ducts, but in nonportal areas of the liver, in lymph nodes and in lungs (Fox *et al.* 1969). Skin test responses using such materials as tuberculin or dinitrochlorobenzene (DNCB) are depressed. Abnormal cell-mediated responses may be seen by the leukocyte migration test in 64%. The bile duct injury could be caused in similar fashion to the hepatocellular destruction in chronic active hepatitis. In this case, cellular cytotoxicity mediated by K cells would be directed against bile ducts, but this theory is unproven.

#### *Serum Autoantibodies*

Chronic active hepatitis, cryptogenic cirrhosis and primary biliary cirrhosis show an increased incidence of high titres of serum autoantibodies. The most interesting are the smooth muscle antibody, the mitochondrial antibody and the liver cell membrane autoantibody.

**Smooth muscle antibody:** This is detected in high titre in about two-thirds of patients with HB<sub>s</sub>Ag negative chronic active hepatitis. It is much less frequent and in low titre in those with HB<sub>s</sub>Ag positive chronic active hepatitis. It is also found in about a third of patients with primary biliary cirrhosis. Titres exceeding 1:40 are rarely seen except in chronic active hepatitis. Smooth muscle antibody can be found in low titre in 80% of patients with type A or type B hepatitis and these antibodies are stimulated by other agents such as cytomegala and Epstein-Barr (EB) virus. The antibody is of IgM type. The antigen is related to the F actin of smooth and skeletal muscle which is also present in cell membrane. Virtually all cells possess contractile elements immunologically related to the various antigens associated with the contractile elements of smooth muscle. Smooth muscle antibody can therefore be regarded as a sequel of liver cell injury, especially viral (Anderson *et al.* 1976). Its presence in both viral infections and in non-HB<sub>s</sub>Ag positive chronic active hepatitis does suggest that the latter condition might be related to autoantigenicity due to a hitherto unrecognized virus. The wide spectrum of diseases associated with a positive smooth muscle antibody titre reduces its diagnostic usefulness.

**Mitochondrial antibodies:** These non-organ specific serum antibodies are demonstrated by immunofluorescence on renal tubules. Human kidney is preferable but rat kidney is the most commonly used. They can also be shown by complement fixation. Two antibodies having preferential

affinity can be shown; M1 for proximal tubules and M2 for distal tubules (Berg *et al.* 1969). M2 is more abundant in liver. The antigen is a lipoprotein composed of mitochondrial inner membranes (Berg *et al.* 1969). It may also include antibodies to other cell components, particularly the membrane antigen of rough endoplasmic reticulum and outer nuclear membrane.

The cardiolipin antigen involved in the Wasserman reaction is also associated with the mitochondrial inner membranes but is quite distinct from that demonstrated in primary biliary cirrhosis.

Mitochondrial antibody is present in serum of over 90% of patients with primary biliary cirrhosis compared with 2-3% of those with obstruction to bile ducts of a mechanical nature (Fig 4). It is thus a very important diagnostic test. It is absent in the serum of patients with cholestasis associated with inflammatory bowel disease or with viral hepatitis, or in a normal population. It is present in 30% of patients with chronic active hepatitis and in 3% of those with so-called 'connective tissue' disease.

**Family studies:** Relatives of patients with either HB<sub>s</sub>Ag negative chronic active hepatitis or primary biliary cirrhosis show an increased incidence of antinuclear antibody (ANA), smooth muscle antibody and mitochondrial antibodies in the serum compared with normal people (Galbraith *et al.* 1974).

An increased frequency of the histocompatibility antigens HLA1 HLA8 have been found in chronic active hepatitis (Mackay & Morris 1972). This applies only to cryptogenic cirrhosis and active chronic hepatitis and not to viral or drug-related types or primary biliary cirrhosis (Lindberg *et al.* 1975). This suggests that chronic active hepatitis may be an immunological disorder arising in a genetically susceptible individual after exposure to a particular environmental factor.

**Liver cell membrane antibody:** Using isolated rabbit hepatocytes, an autoantibody against liver cell membranes has been demonstrated in HB<sub>s</sub>Ag

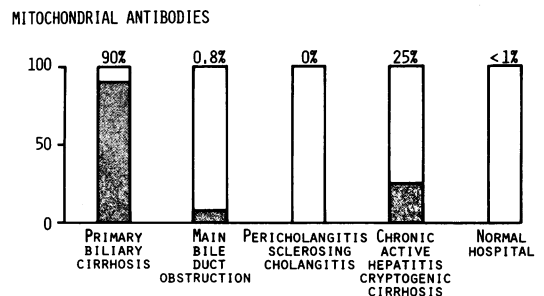


Fig 4 Percentage increase of serum mitochondrial antibodies in various disease states

negative chronic active hepatitis and in cryptogenic cirrhosis (Tage-Jensen *et al.* 1977). This may be useful diagnostically, particularly in identifying one type of HB<sub>s</sub>Ag negative chronic active liver disease. The reagents are not currently available.

## REFERENCES

- Anderson P, Small J V & Sobieszek A (1976) *Clinical and Experimental Immunology* 26, 57
- Berg P A, Roitt I M, Doniach D & Horne R W (1969) *Clinical and Experimental Immunology* 4, 511
- Bjorneboe M, Prytz H & Orskov F (1972) *Lancet* i, 58
- Cherrick G R, Pothier L, Dufour J-J & Sherlock S (1959) *New England Journal of Medicine* 261, 340
- Cochrane A M G, Thomson A D, Moussouros A, Eddleston A L W F & Williams R (1976) *Lancet* i, 441
- Dehoratius R J, Henderson C & Strickland R G (1976) *Clinical and Experimental Immunology* 26, 21
- Doniach D & Walker J G (1969) *Lancet* i, 813
- Dudley F J, Fox R A & Sherlock S (1972a) *Lancet* i, 743
- Dudley F J, Giustino V & Sherlock S (1972b) *British Medical Journal* iv, 574
- Eckhardt R, Heinisch M & Meyer zum Buschenfelde K H (1976) *Scandinavian Journal of Gastroenterology* 11, 49
- Edgington T S & Chisari F V (1975) *American Journal of Medical Sciences* 270, 213
- Fox R A, Scheuer P J, James D G, Sharma O & Sherlock S (1969) *Lancet* i, 959
- Galbraith R M, Smith R M, Mackenzie D E, Tee D E, Doniach D & Williams R (1974) *New England Journal of Medicine* 290, 63
- Havens W P, Shaffer J M & Hopke C J (1951) *Journal of Immunology* 67, 347
- Hopf U, Meyer zum Buschenfelde K H & Arnold W (1976) *New England Journal of Medicine* 294, 578
- Jacques E A, de Villiers D, Crimmins F, Thomas H C & Sherlock S (1976) *Gastroenterology* 71, 913
- Lindberg J, Lindholm A, Lundin P & Iwarson S (1975) *British Medical Journal* ii, 77
- Mackay I R & Morris J J (1972) *Lancet* ii, 793
- Meyer zum Buschenfelde K H & Miescher P A (1972) *Clinical and Experimental Immunology* 10, 89
- Miller J, Smith M G M, Mitchell C G, Reed W D, Eddleston A L W F & Williams R (1972) *Lancet* ii, 296
- Paronetto F & Popper H (1976) *New England Journal of Medicine* 294, 606
- Roux M E B, Florin-Christensen A, Arana R M & Doniach D (1974) *Gut* 15, 396
- Schalm S W, Summerskill W H J, Gitnick G L & Elveback L R (1976) *Gut* 16, 781
- Sherlock S (1975) *Diseases of the Liver and Biliary System* 5th edn. Blackwells Scientific, Oxford; p 390
- Souhami R L (1972) *Immunology* 22, 685
- Tage-Jensen U, Arnold W, Dietrichson O, Hardt F, Hopf U, Meyer zum Buschenfelde K H & Nielson J O (1977) *British Medical Journal* i, 206
- Thomas H C, MacSween R N M & White R G (1973) *Lancet* i, 1288
- Thomas H C, Ryan C J, Benjamin I S (1976) *Gastroenterology* 71, 114
- Triger D R, Alp M H & Wright R (1972) *Lancet* i, 60
- Triger D R, Cynamon M H & Wright R (1973) *Immunology* 25, 941

## Professor D S Munro

(Temporary Clinical Sciences Centre,  
Northern General Hospital,  
Sheffield, S5 7AU)

## Autoimmunity and the Thyroid Gland

Disturbances of autoimmunity are now identified in many common thyroid diseases. Hashimoto (1912) originally observed extensive lymphocytic infiltration of the thyroid in goitrous hypothyroid patients but it was not until 1957 that Doniach & Roitt (1957) described a circulating antibody to thyroglobulin in patients with Hashimoto's disease. Since then, other thyroid autoantibodies have been characterized and it has been noted that a variable degree of lymphocytic infiltration of the thyroid is found in many patients, who do not necessarily have disturbed thyroid function. This group of euthyroid patients are classified as 'lymphocytic thyroiditis' or 'lymphadenoid goitre'. Lymphocytic infiltration is also a common histological feature in the thyroid gland in Graves' disease. It has been proposed that disorders of thyroid function could be placed in a spectrum ranging from myxoedema at one end of the scale, through 'lymphadenoid goitre', to florid thyrotoxicosis at the other end.

In the pathogenesis of thyroid disease it has long been recognized that genetic influences are important (Martin 1945). It has also been demonstrated that thyroid autoantibodies are found with increased frequency in the relatives of patients with thyroid disturbances (Hall & Stanbury 1967, Howell-Evans *et al.* 1967). So far, information obtained from studies of histocompatibility antigens have not been easy to interpret and advances in the identification of other antigens may be needed before any pattern of linkage emerges.

It is also uncertain, at this stage, whether disturbances of T-, B- and K-cell function play an important role in autoimmune thyroiditis. It has been postulated that a deficiency in T cells may be the key factor in initiating the whole process but, ultimately, all three categories of lymphocyte may be involved (Urbaniak *et al.* 1973, Irvine 1974).

## Humoral Thyroid Autoantibodies

The first thyroid autoantibody to be clearly identified was the antibody to thyroglobulin, originally detected by a relatively insensitive precipitation technique. It is now usual to use the much more sensitive 'tanned red cell' test. Similarly, microsomal antibodies were originally detected by complement fixation but this was displaced in turn by immunofluorescence studies and now by another tanned red cell technique in which the microsomal antigen is used to coat the red cell membrane (Bird & Stephenson 1973). The clinical significance of