

THE OPERATIVE REPAIR OF MASSIVE RECTAL PROLAPSE*

ROSCOE R. GRAHAM, M.D.

TORONTO, CANADA

PROLAPSE of the rectum varies in degree from the minor cases in which only the mucous membrane of the anal canal or lower rectum is prolapsed, to the instance of massive prolapse in which the prolapse assumes enormous proportions and includes all the coats of the rectal wall. In the three cases we are reporting, the prolapse started in childhood and had gradually increased in size until it occurred not only during defecation, but also when the patient walked about. In two patients the prolapse assumed such magnitude as to constitute a major disability at age 26. The third case was able to carry on until age 42. It is noteworthy that these patients suffered a progressive increase in the size of the prolapse over many years. In none of the three patients was the prolapse less than six inches in length (Fig. 1).

On examining these patients, the most outstanding observation was that the lumen of the rectum presented on the posterior quadrant of the prolapsed mass. The long axis of the lumen was at right angles to the long axis of the body (Fig. 2). In Figure 2 the cork in the lumen indicates the site and direction of the canal. This led to the conclusion that the prolapse was more at the expense of the anterior than the posterior rectal wall. The prolapsed mass was resonant on percussion, and, on occasions, gurgling was heard during attempts at reduction. After reduction of the prolapse, the anal sphincter was so stretched that it very poorly closed the anal canal, but in two instances one could see the patient was able voluntarily to contract it. In Case 3 there was no visible evidence of the patient's ability to do so. In two cases there was a definite sulcus about three-quarters of an inch long between the anal canal and the prolapse. In Case 1 no such sulcus was present, the prolapse being so complete that the anal canal was everted. Moschowitz¹ made an important observation: "If, after reducing the prolapse, the patient strained while the examining finger is pressed anteriorly in the lower rectum, the prolapse would not recur, whereas if pressure were made posteriorly the prolapse recurred immediately."

The disability which these young individuals suffered was very great, not only economically but socially. The problem which they presented to the surgeon demanded careful consideration. Moschowitz¹ article published in 1912, 30 years ago, advanced the suggestion that a massive rectal prolapse resulted from a sliding hernia of the anterior wall of the rectum at the level of the cul-de-sac of Douglas or rectovesical pouch. Our interest in sliding hernia of the sigmoid² led us to consider seriously this hypothesis. Yet if this be the correct etiology, the treatment suggested by Moschowitz of

* Read before the American Surgical Association, Cleveland, Ohio, April 6-8, 1942.

plicating the peritoneum of the cul-de-sac of Douglas or rectovesical pouch is inefficient. It would be comparable to plicating the sac of an inguinal hernia without removing it and without any attempt at repairing the defect in the wall.

The injection treatment suggested by Gabriel is comparable to the injection treatment of an inguinal hernia, were one to dispense with the pressure of a truss during the course of treatment. If our observation be sound, that

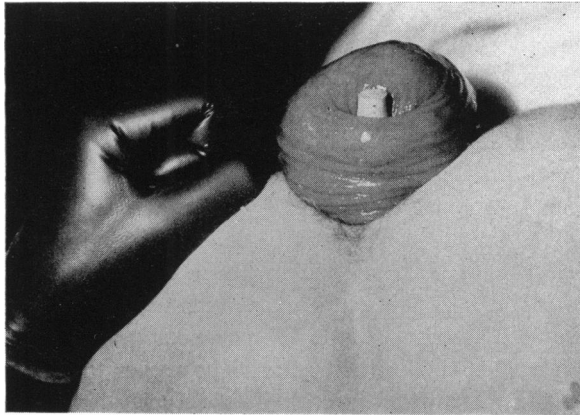


FIG. 1.—The size of the prolapse can be compared to the size of an adult fist.

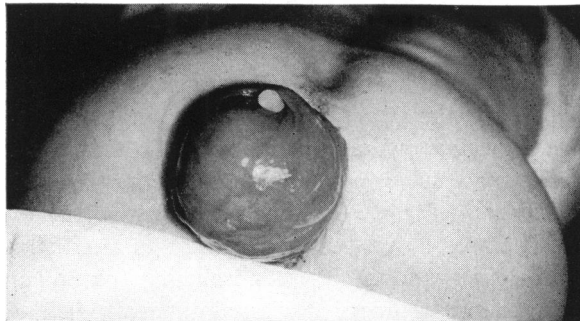


FIG. 2.—With the patient in the knee-chest position the prolapse is seen from behind. The position and direction of the lumen of the rectum is indicated by the cork placed in the lumen.

the prolapse occurs at the expense of the anterior rather than the posterior rectal wall, which is very little disturbed, then the procedure of Lockhart-Mummery and Pemberton is unsound. Their technic is aimed at the fixation of the posterior rectal wall, which is little altered from its normal relationship to the sacrum.

The fact that after reduction of the prolapse, pressure anteriorly by the examining finger in the rectum prevented its recurrence even with straining, was the most important single observation confirming the hypothesis that the lesion was essentially a sliding hernia of the anterior wall of the rectum (Fig. 3).

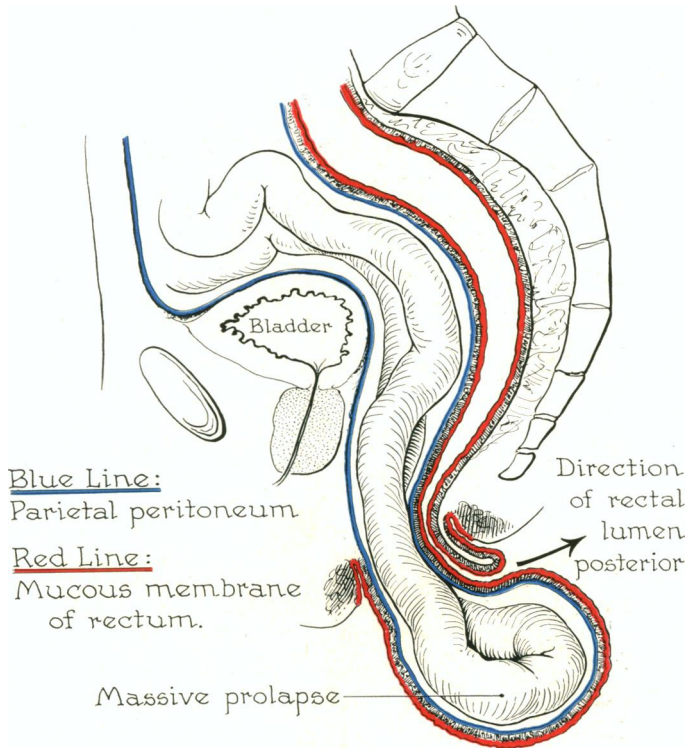


FIG. 3.—The invagination of the anterior rectal wall into itself and through the anal canal separates the fascial and muscular supports of the rectum and by overstretching results in incompetence of the anal sphincter. The lengthening of the mesentery of the small bowel occurs over the years to such a degree that small bowel lies within the hernial sac of a massive prolapse.

In this mechanism the natural defect in the pelvic fascia which permits the passage of the rectum through the pelvic diaphragm is enlarged by the contents of the cul-de-sac of Douglas or rectovesical pouch pressing downward into the anterior rectal wall. This increased bulk of rectum further separates the levator ani by stretching the pelvic fascia, which normally unites them medially. This likewise decreases the normal fixation of the rectum at this level. The separation of the levators permits sufficient anterior wall of the rectum to be invaginated into the lumen of the rectum that the latter pro-

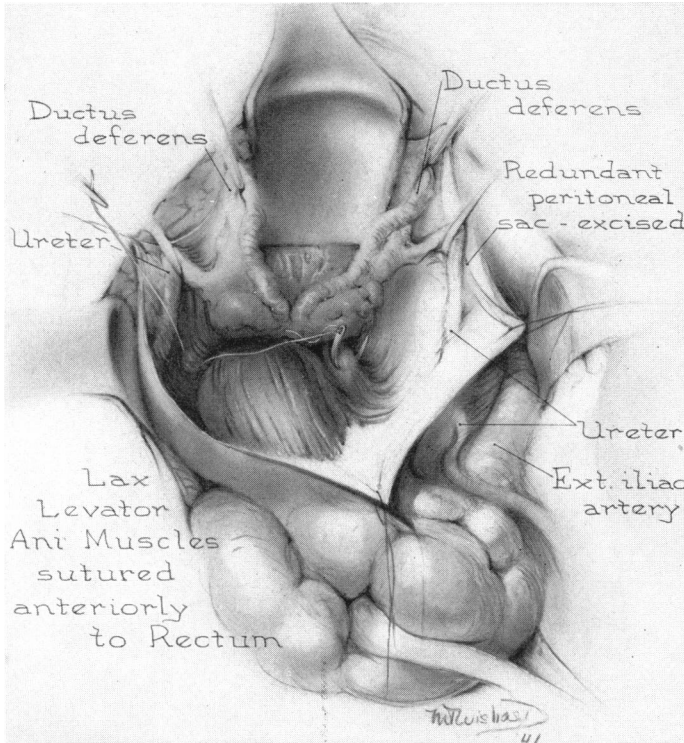


FIG. 4.—The dissection completed identifies the ureters, the seminal vesicles and the separated levator ani muscles identified by the sutures. They, with the overlying fascia, are approximated with locked mattress sutures of silk. This closure in one case was reinforced by a strip of fascia lata suture.

trudes through the anal canal. As this occurs, the course of the rectum is straightened and the normal angulation of the rectum at the level of the pelvic floor is eliminated. The posterior wall of the rectum is carried forward from the hollow of the sacrum, making the rectum now almost a straight tube, with the fascial supports most inefficient, due to the overstretching. Over the years there has also occurred elongation of the mesentery of the small bowel, permitting the latter to lie in the hernial sac, and this accounts for the tympanic note on percussing the prolapse, as well as explaining the gurgling which was elicited on attempts at reduction.

This conception of the mechanism of production of massive rectal prolapse is not new; nor was it new with Moschowitz, as it was first propounded

by Jeannell, in 1890. This conception, however, appealed to us so strongly that we felt it pointed a way to safe and adequate treatment, using the same principles as are applied in the operative repair of all herniae, particularly sliding herniae.²

If this conclusion be correct, then the adequate treatment should be removal of the sac and repair of the anatomic defect in the wall. The anatomic defect is in the pelvic fascia, just as in a direct inguinal hernia the defect is in the transversalis fascia. Hence, we must restore the normal relationship of the pelvic fascia to the rectal wall, as well as obliterate the peritoneal sac.

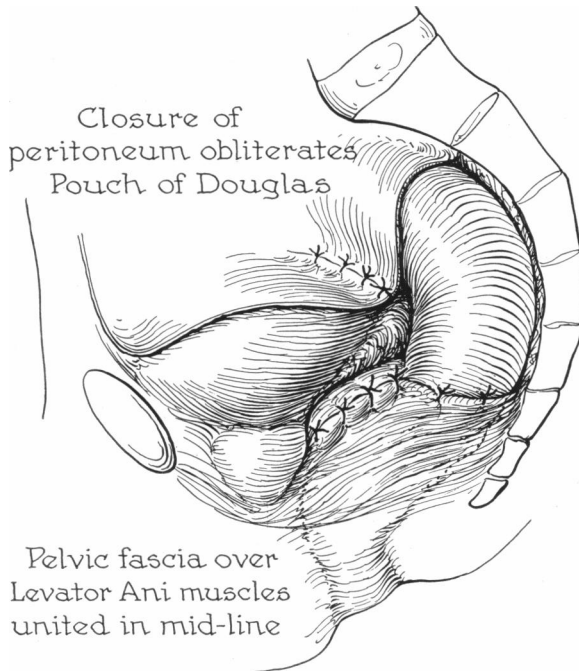


FIG. 5.—The levator ani muscles are approximated and their fascial covering united to the rectum by interrupted silk sutures. This may be reinforced by sutures of fascia lata. This approximation of the levators replaces the rectum in its normal relation to the hollow of the sacrum and prevents the prolapse. The redundant peritoneum of the pouch of Douglas is excised, and on closing the posterior parietal peritoneum the pouch of Douglas is obliterated.

To achieve this, it becomes imperative that we open the peritoneal cavity. The following are the details of the operative procedure (Fig. 4): With the patient in the Trendelenberg position, under spinal anesthesia, the abdomen is opened by a large incision displacing the lower left rectus laterally. The small bowel is packed off with hot sponges. Two points were noted: First, there was an unusually deep cul-de-sac of Douglas or rectovesical pouch; second, an unduly mobile rectosigmoid, due to the fact that the rectum was pulled forward, had a mesentery throughout the greater part of its length, and did not lie as is usual in close contact with the sacrum. Gauze on the

end of a sponge forcep placed on the bottom of the cul-de-sac of Douglas or rectovesical pouch, with downward pressure readily invaginated the anterior rectal wall into the rectal lumen. The defect in the muscular pelvic floor could readily be palpated. This invagination was easily carried through the anal canal, and reproduced the massive rectal prolapse, and convinced us that it really was due to a sliding hernia of the anterior wall of the rectum. Furthermore, this prolapse was readily reduced by upward traction on the rectosigmoid junction. Having convinced ourselves of these facts, the peritoneum of the cul-de-sac of Douglas or rectovesical pouch was opened and dissected free from the extraperitoneal fat and areolar tissue. The ureters were then identified and surrounded with tape, in order to retract them laterally. A further dissection of the perirectal fat made possible the visualization of the seminal vesicles and the widely separated fascial-covered medial borders of the levator ani muscles. With the rectum pulled well up into the abdomen, and starting just behind the prostate, interrupted locked mattress sutures of silk were placed in the fascia covering the levator ani muscles. These sutures united the levators until their resultant approximation forced the rectum back into the hollow of the sacrum (Fig. 5). In Case 3 this repair was reenforced by a single suture of fascia lata. This maneuver restored the normal angulation of the rectum. It was then no longer possible to invaginate the anterior wall of the rectum through the anal canal. Pressure exerted at the level of the rectum and new pelvic floor forced the rectum into the hollow of the sacrum, not toward the anal canal. Interrupted silk stitches then united the lateral rectal wall to the fascia over the right and left levators (Fig. 5). This appeared to give a very adequate support to the rectum, particularly to its anterior wall, which is so important in preventing a recurrence of the massive prolapse. Excision of the redundant hernial sac and suture of the pelvic peritoneum obliterates the cul-de-sac of Douglas or rectovesical pouch entirely. The abdomen is then closed without drainage.

On return to the ward, the patient remains recumbent, with the foot of the bed elevated ten inches, for one week. A low-residue diet is given. Every effort is made to prevent a stool for a week to ten days, at the end of which time oil enemata are usually effective in producing a stool. The patient is encouraged to practice contraction of the overstretched anal sphincter many times a day, in order that it will regain its tonicity. The following are the details of the three cases:

CASE REPORTS

Case 1.—Hospital No. A64821: W. J. P., male, age 26. Admitted April 12, 1939. Mass first present at age six, gradually increased in size, and recently appeared with slight straining when patient was erect. The mass had to be replaced by manipulation. There was marked urgency of defecation.

Examination.—The mass was as large as a man's fist, and could be prolapsed voluntarily. In the knee-chest position it could be replaced by violent movements of the abdominal muscles. No ulceration was present. There was no sulcus at the anal sphincter, as the anal canal was also prolapsed. The mass was tympanitic on percussion,

and the lumen of the rectum pointed backward. With a finger in the rectum, pressure anteriorly controlled the prolapse.

Operation.—April 24, 1939: Primary healing. Discharged May 16, 1939. Has had no further trouble, and is doing hard physical work in a tannery at the present time.

Case 2.—Hospital No. A82662: W. B., male, age 42. Admitted April 4, 1940. Prolapse first noticed at age eight. Now comes down with stool and has to be replaced. The size has increased markedly in the previous five weeks. Now has a mass 6x8 inches protruding from anus, and reduction becoming difficult (Fig. 1).

Examination.—Well nourished; sphincter contraction visible and surprisingly good tone. The mass is difficult to replace. There is no ulceration and no hemorrhage. The lumen points posteriorly. The mass is resonant on percussion (Fig. 2). With a finger in the rectum, pressure anteriorly controlled the prolapse.

Operation.—April 12, 1940: Had slight superficial wound separation due to coughing from a respiratory infection. Good recovery. Complete relief, with a very slight prolapse of one area of anal mucous membrane on straining. At present is working in munitions plant as a laborer.

Case 3.—Hospital No. A99554: G. T., age 26. Admitted April 1, 1941 to the Neurologic Service, with headaches, fainting attacks, and a multiplicity of complaints. Only organic finding was rectal prolapse present since childhood. Had to be replaced after each stool. Marked increase in size of prolapse during past five years, becoming difficult to replace, and on admission prolapse occurs on walking or any exertion.

Examination.—Sphincter lax. No evidence of contraction could be demonstrated by the patient. On straining, the rectum prolapsed at least six inches; a sulcus is present between the anal canal and prolapse about one-half inch deep. By introducing two fingers into the rectum and pressing anteriorly, the prolapse could be prevented as the patient strained. Pressing posteriorly into the hollow of the sacrum while the patient strained, permitted recurrence of the prolapse.

Operation.—May 10, 1941: Bowels moved on tenth day. Primary union. Discharged.

Progress.—No further prolapse of the bowel. Slight prolapse of mucous membrane treated by injections of 2 cc. phenol and almond oil. Some difficulty in controlling stool for four months. At present has perfect control of bowel movements. On examination, the tone of the sphincter ani is remarkable, but not as strong as normal. Her neurologic symptoms have nearly all disappeared. She is working in our hospital as a ward aid at the present time. We are indebted to Dr. Keith Welsh for the privilege of seeing and reporting this third case.

CONCLUSIONS

- (1) Massive rectal prolapse is a sliding hernia of the anterior rectal wall through the anal canal.
- (2) The lumen of the rectal canal points posteriorly as the prolapsed mass is formed largely at the expense of the anterior rectal wall.
- (3) This results in an overstretching of the pelvic fascial supports of the rectum.
- (4) With the examining finger in the rectum, the prolapse can be controlled as the patient strains if pressure be exerted anteriorly, whereas if pressure be exerted posteriorly, the prolapse will recur.
- (5) The treatment of this condition should be planned to apply the basic principles underlying the treatment of all herniae—first, remove the sac; second, restore the defect in the wall.
- (6) A procedure is presented which fulfills these requirements.

(7) It has been successfully carried out on three patients. Two have returned to hard labor; the third is working as ward aid in our hospital.

(8) The return of tone in the anal sphincter is most remarkable.

REFERENCES

- ¹ Moschcowitz, Alexis V.: The Rational Treatment of Sliding Hernia. Surg., Gynec., and Obstet., **81**, 330, January, 1925.
- ² Graham, R. R.: The Operative Repair of Sliding Hernia of the Sigmoid. ANNALS OF SURGERY, **102**, No. 4, 784, October, 1935.

DISCUSSION.—DR. VERNON C. DAVID (Chicago): Doctor Graham has limited his discussion to the type of prolapse of the rectum in which the anus, including the patulous sphincter muscles, prolapses with the four to six inch tube of bowel carrying with it the cul-de-sac of Douglas. In principle, the treatment he advocates requires an abdominal approach, opening of the cul-de-sac, and the approximation of the levator muscles by suture in front of the rectum. He is to be congratulated on the results in the three cases he reports.

To present a slightly different viewpoint, I should like to point out that the levator muscles, which have a very delicate fascial covering, completely encircle the rectum and their highest or superior surface is at about the level of the sacrococcygeal junction. To tighten these muscles by suture *via* the abdominal approach in the depth of the pelvis is a difficult procedure, and I should like to ask Doctor Graham if he finds it necessary to cut the triangular ligaments of the rectum, which lie below the culdesac, before he reaches the levator muscles. When the levator muscles are divided, as in removal of the rectum posteriorly, the rectum is still firmly anchored in place by the fascia propria, which is a dense fascia about one millimeter thick, firmly attached to the sacrococcygeal junction posteriorly and anteriorly to the prostate which it completely envelops. Before the rectum can be mobilized this fascia must be cut.

It is my belief that it is not only the atrophy and weakness of the levator muscles and depth of the cul-de-sac which favor this type of prolapse but more particularly a weakness and stretching of the fascia which allows the rectum to completely prolapse carrying the cul-de-sac with it. In repair of this type of prolapse we, therefore, believe that the structures in most need of support are in the prolapsed segment of bowel and on its outer surface, namely, the fascia propria and levator muscles. We also believe that the atonic sphincter muscles, which have been greatly dilated by the prolapse of the bowel and levator muscles through them, are a factor which favors early recurrence of the prolapse.

With these anatomic facts in mind, I should like to call your attention to the operation for the repair of this type of prolapse originally proposed by Delorme, in 1890, and first carried out by Rehn, in 1896. This operation is easily carried out under novocain anesthesia and consists in the removal of the mucosa of the prolapsed segment from the mucocutaneous line to the apex of the prolapse. The muscularis of the bowel, levator muscles, and fascia propria in the outer layer of the prolapse are collapsed like a closed accordion by longitudinal puckering-stitches, which reduces the prolapse and makes tighter the supporting levator muscles and fascia propria and places the puckered mass of muscle and fascia above the sphincter muscles, which are narrowed below it by angulating stitches. The excess of freed mucosa is then cut off and the cut surface sutured to the skin. This operation accomplishes everything but obliteration of the cul-de-sac. I first saw Doctor Bevan perform this operation, and I have carried it out in 12 cases, with good results, and no massive recurrences. In women, where the perineal body is gone and the levator muscles are widely separated, it is advisable to perform a later perineorrhaphy.

This type of prolapse demands, essentially, strengthening of the pelvic fascia and levator muscles. In my opinion this may be best accomplished by the abdominal operation described by Bardenheuer, Moschcowitz, and Graham, or by the Rehn-Delorme operation from below.

DR. CHARLES G. MIXTER (Boston): Massive rectal prolapse, particularly of the recurrent variety, is frequently a discouraging lesion from the surgeon's viewpoint. Doctor Graham has presented to us a well-conceived operation that has been successful in the

three patients he has subjected to this procedure, and in skilled hands it should yield good results. It is, however, a procedure of considerable magnitude. The lesion occurs many times in the aged and, perhaps, enfeebled group. It might not be amiss to bring before this Association briefly a simple procedure that has yielded satisfactory results in the two cases upon whom I have had the opportunity to try it.

The abdomen is opened through a low left rectus muscle-splitting incision. A small opening is made in the pelvic floor on either side of the rectosigmoid. The rectum is mobilized by blunt dissection and cigarette wicks are inserted to stimulate fixation of this bowel segment by resultant fibrosis. The wicks are brought out through stab wounds above the inguinal ligament on either side. Further experience may prove this step to be unnecessary. The sigmoid which is usually redundant is brought out of the abdominal wound in a manner similar to a subcutaneous loop-colostomy or precolostomy. The distal limb of sigmoid should run tautly downward from the lower angle of the wound to the rectosigmoid. The proximal sigmoid reenters the abdomen at the upper end of the incision. All layers of the abdominal wall except the skin and superficial fascia are closed in a routine manner beneath the exteriorized sigmoid through an opening established in the mesentery. The fat is separated from the anterior rectus sheath and allowed to gape to accommodate the loop and the skin is closed over the bowel. Care must be taken not to constrict the lumen where the bowel enters and leaves the abdomen.

Two cases, both having had three previous procedures, have been treated by operation based on the principle of fixation of the sigmoid in the abdominal wound. In the first case, a woman of about 40, a double-barrel colostomy was done, the bowel later opened, the spur crushed and the colostomy closed. This patient has remained free of recurrence and with satisfactory bowel function for two and one-half years. The second case was a rather feeble woman in the late sixties, who was operated upon by the method outlined above. She had no difficulty in moving her bowel postoperatively. It is now about nine months since operation, and I understand she has had no recurrence, though I have not had an opportunity to examine her personally.

The results in two cases are insufficient to draw conclusions from, but suggest that this simple procedure may be worthy of further trial, particularly where relief must be given in the poor-risk group.

DR. JOHN PEMBERTON (Rochester, Minn.): Since Doctor Graham mentioned the operation that I described four years ago, I would like to run over, very briefly, the principles of it, which are similar to what Doctor Mixer has described.

I think the fundamental principles of rectal prolapse are about the same that you see in the colostomy. If the distal segment or the segment just distal or just proximal to the colostomy is fixed, you will not get a prolapse of the colostomy, if you get up close to the descending colon, but if you take it in the middle of the sigmoid, then you are very likely to get a prolapse.

You cannot make a complete fixation of the rectum unless you divide the pelvic peritoneum, so this is done either on one side or both sides. Then the rectum is freed up from the segment going down there. This permits fibrosis to take place here, which you can readily determine by examining the rectum digitally after incision. This is freed up, and we get a space between the rectal wall and the sigmoid, until it heals. The problem is, of course, to suspend the sigmoid afterward. The suspension will not hold, but if it holds temporarily, for a couple of weeks, I believe the fixation will hold up.

Four years ago I reported six cases that we had operated upon. I think the longest case was two or three years. Since then we have done others, but of those six cases I know that one has had some recurrence of the prolapse.

DR. ROSCOE R. GRAHAM (closing): I have just one thought, and that is to state our amazement at what happened at the anal sphincter. In the patient whom you saw in the moving picture there was no visible evidence, whatsoever, that the patient could make the slightest contraction of the anal sphincter. That was a year ago. At the present time, by encouraging her to voluntarily attempt contraction, she has an anal sphincter which is not as good as normal but is amazingly good in its grip of the examining finger. The other two men had visible evidence at the time of operation, and they have come back with exercise in a way that is remarkable. While one is conscious of the fact that this is a major procedure, it also is undertaken to correct a very major disability.