

# Hereditary coproporphyria and epilepsy

A. B. HOUSTON, M. J. BRODIE, M. R. MOORE, G. G. THOMPSON, AND J. B. P. STEPHENSON

From the Royal Hospital for Sick Children, Glasgow, and University of Glasgow, Department of Materia Medica, Stobhill General Hospital

**SUMMARY** A 9-year-old boy with mental deterioration and epilepsy suffered an acute attack of hereditary coproporphyria associated with worsening of seizure control. Leucocyte coproporphyrinogen oxidase activity was undetectable in the patient during this attack, and was reduced in his mother, a latent case. The complex relationship between porphyria, epilepsy, and anticonvulsant drugs is discussed.

The porphyrias, a group of disorders characterized by abnormalities in the biosynthesis of haem, are classified in Table 1 (Goldberg *et al.*, 1977). They are errors of metabolism, mainly inborn, which involve specific enzymes in the haem biosynthetic

The acute porphyrias (Table 1) are the most important in terms of morbidity and mortality. They are all transmitted as autosomal dominant genes. All patients during an attack excrete the porphyrin precursors  $\delta$ -aminolaevulinic acid (ALA)

Table 1 Classification of the porphyrias according to the major site of abnormal porphyrin production

<i>Hepatic porphyrias</i>	
(1) Acute intermittent porphyria	} Acute porphyrias
(2) Variegate porphyria	
(3) Hereditary coproporphyria	
(4) Cutaneous hepatic porphyria	
(a) Genetically predisposed	
(b) Toxic	
(c) Neoplastic	
<i>Erythropoietic porphyrias</i>	
(1) Congenital porphyria	
(2) Erythropoietic protoporphyria	

pathway (Fig.). The enzymes deficient in acute intermittent porphyria and erythropoietic protoporphyria have been identified as porphobilinogen deaminase (Meyer *et al.*, 1972) and ferrochelatase (Bottomley *et al.*, 1975) respectively. Brodie *et al.* (1976) have shown a reduction in coproporphyrinogen oxidase activity in hereditary coproporphyria. The defects in the other types of porphyria await delineation. The major sites of abnormal porphyrin production are liver and bone marrow, though haem biosynthesis is a function of every somatic cell. Control of the pathway is via feedback repression and inhibition by haem of  $\delta$ -aminolaevulinic acid synthase, the first and rate-limiting enzyme in haem biosynthesis. Thus, common to all porphyrias is the finding of increased activity of this enzyme.

Received 13 January 1977

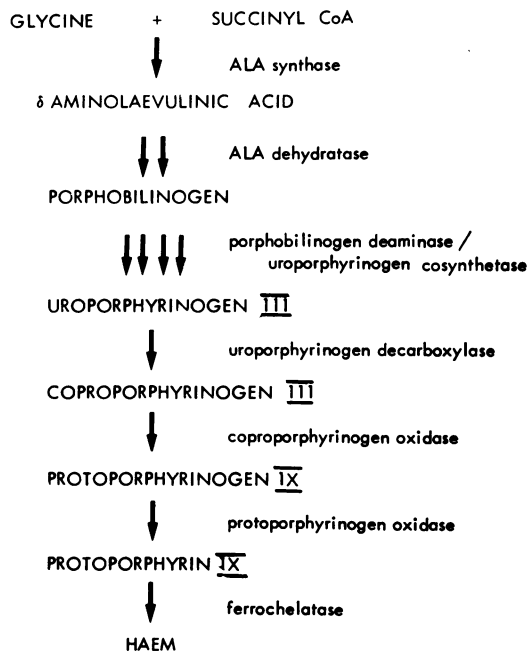


Fig. Haem biosynthetic pathway. In hereditary coproporphyria depressed activity of coproporphyrinogen oxidase leads to excessive excretion of coproporphyrin in faeces and often in urine. In addition reduction in haem production results in increased activity of  $\delta$ -aminolaevulinic acid synthase.

and porphobilinogen (PBG) in excess in the urine. All can display similar abdominal and neuropsychiatric disturbances. All can be precipitated by sex hormones, alcohol, and certain drugs, often hepatic microsomal enzyme inducers (Goldberg *et al.*, 1977). These diseases rarely present before puberty, and porphyria in childhood has been reviewed by Chisolm (1964).

Hereditary coproporphyria is the least common of the acute porphyrias and is distinguished by excess faecal and often urinary excretion of coproporphyrin in remission and in the latent case. In the acute attack there is also increased urinary excretion of ALA and PBG. Hereditary coproporphyria was first described in a 10-year-old boy (Berger and Goldberg, 1955) and was for a time considered an asymptomatic biochemical abnormality. This is now known to be incorrect and cases have been reported associated with gastrointestinal symptoms (Goldberg *et al.*, 1967; Haeger-Aronsen *et al.*, 1968), skin photosensitivity (Hunter *et al.*, 1971; Jaeger *et al.*, 1975), psychiatric symptoms (Goldberg *et al.*, 1967; McIntyre *et al.*, 1971), seizures (Birchfield and Cowger, 1966; Haeger-Aronsen *et al.*, 1968), and peripheral neuropathy (Dean *et al.*, 1969; McIntyre *et al.*, 1971). Death from respiratory paralysis has occurred in 2 patients (Dean *et al.*, 1969; Jaeger *et al.*, 1975). 8 children have been reported with biochemical findings of hereditary coproporphyria (Berger and Goldberg, 1955; Birchfield and Cowger, 1966; Goldberg *et al.*, 1967; Haeger-Aronsen *et al.*, 1968; Lomholt and With, 1969; Hunter *et al.*, 1971; Jaeger *et al.*, 1975), but only 2 of them have had symptoms (Birchfield and Cowger, 1966; Haeger-Aronsen *et al.*, 1968). We report a further case of an epileptic boy with hereditary coproporphyria in whom an acute attack presented as uncontrollable seizures.

### Case report

This boy, the second of 3 children of a Scottish mother and English father, was born on 23 January 1966, by normal delivery after an uneventful pregnancy. There is a strong family history of epilepsy and psychiatric illness. His father has had seizures from the age of 16 years, as has his 12-year-old sister from the age of 6 years. His mother has suffered from an anxiety neurosis for 20 years. His 8-year-old brother is well.

His medical history exhibits three distinct features: seizures, mental deterioration, and occasional episodes of vomiting. From the age of 2½ years he has had seizures, initially epileptic falls, myoclonic jerks, tonic seizures, and atypical absences; later clonic generalized and lateralized clonic and tonic

convulsions. These have recurred repeatedly and have been exceedingly difficult to control despite therapy with a total of 14 drugs, singly or in combination, a ketogenic diet, or no therapy at all. His drug regimen has included sulthiame, phenobarbitone, phenytoin, carbamazepine, meprobamate, primidone, prednisolone, clonazepam, diazepam, acetazolamide, sodium valproate, bromide, dexamphetamine, and methylphenidate. Electroencephalogram (EEG) showed spike and wave activity, often with accompanying myoclonic jerks or eyelid flicker, since the first recording in 1968, and later showed generalized slow 2 Hz spike and wave (Lennox-Gastaut syndrome). Tonic seizures occurring during the EEG were accompanied by fast activity and rapid spiking.

His initial development was said to be normal and at the age of 6 years he was reported, without formal testing, to be of normal intelligence. However, hyperactivity was first noticed at the age of 3½ years and mental deterioration was suspected at the age of 8 years when he was found to be severely retarded with an IQ of 47 on the Stanford-Binet scale. Investigations failed to show any apparent cause for this deterioration. When aged 10 years his IQ had fallen to 34, previously acquired skills having been lost.

He was admitted to hospital twice with persistent vomiting, first at 7 years of age no definite diagnosis was made, and then at 9 years, in February 1975, he was admitted to the Royal Hospital for Sick Children. There was a 4-day history of vomiting and mild abdominal discomfort which settled within 24 hours on intravenous fluid therapy alone. Urine was noted to be dark in colour. Screening tests suggested a trace of bile and urobilinogen but testing with Ehrlich's aldehyde reagent showed no colour change. There was no clinical evidence of liver disease though serum bilirubin was 22 µmol/l (1.29 mg/100 ml) (normal <17 µmol/l; <0.99 mg/100 ml), falling to normal within a week. Urine analysis suggested the presence of excessive amounts of porphyrins and on quantitation increased urinary and faecal coproporphyrin and faecal protoporphyrin were found (Table 2). This suggested a diagnosis of hereditary coproporphyria but normal urinary ALA and PBG excluded an acute porphyric attack as the cause of the vomiting episode. Hb, blood film, and blood lead were normal. As his seizures had been relatively well controlled in the preceding months, phenytoin and clonazepam therapy was continued. Seizure control deteriorated in July 1975. Urine contained normal amounts of PBG; phenytoin was replaced by sodium valproate with little improvement. A combination of primidone, diazepam, and acetazolamide controlled his

Table 2 Porphyrin and precursor excretion in the propositus and family

	Age (years)	Date	Urinary porphyrins and precursors				Faecal porphyrins (nmol/g dry weight)	
			( $\mu\text{mol/l}$ )		(nmol/l)		Copro	Proto
			ALA	PBG	URO	Copro		
Propositus	9	14 Feb 75	11	0.1	10	800	1245	429
		20 Feb 75	5	0.7	115	865	828	170
		9 July 75	40	22	225	1815	2730	276
		3 Dec 75	225	163	307	16990	—	—
		29 Dec 75	365	94	1068	13808	—	—
		8 Jan 76	237	55	1257	6725	—	—
		5 Apr 76	165	22	362	1365	—	—
Father	43	23 Apr 75	5	0	21	21	17	25
Mother	43	"	11	6	49	30	176	64
Sister	10	"	18	2	20	62	50	17
Brother	7	"	16	8	19	40	29	159
Normal values			<43	<25	<22	<227	<76	<200

ALA =  $\delta$ -aminolaevulinic acid; PBG = porphobilinogen; URO = uroporphyrin; Copro = Coproporphyrin; Proto = protoporphyrin.

seizures to some degree until late November 1975, when he worsened, taking numerous seizures daily. On readmission to hospital in minor epileptic status, urine for the first time contained excessive quantities of ALA and PBG (Table 2). Blood was taken for measurement of ALA synthase and coproporphyrinogen oxidase activities (Table 3). Therapy was

Table 3 Leucocyte enzyme activities in patients and controls

	ALA synthase (pmol ALA/mg protein per h)	Coproporphyrinogen oxidase (nmol protoporphyrin/g protein per h)
Propositus	426	None detectable
Mother	506	70
Normal	192 $\pm$ 58 (n=19)	179 $\pm$ 70 (n=9)

altered to sodium valproate and bromides but he was unable to tolerate the latter and is now receiving sodium valproate alone with adequate seizure control.

## Methods

**Porphyrins and precursors.** Urinary and faecal porphyrins were measured by the method of Rimington (1971) and urinary ALA and PBG by the method of Mauzerall and Granick (1956).

**Enzymes.** Enzyme activities were measured in leucocytes by the methods described by Brodie *et al.* (1976).

**Preparation of leucocytes.** Immediately after removal into a heparinized tube, 30 ml blood was placed in ice, the tubes centrifuged at 2500 *g* for 30 minutes, the plasma removed, and the white cell layer carefully separated from the red cells with a pasteur

pipette. These white cells were then washed 4 times in an ice cold saline solution (150  $\mu\text{mol/l}$ ). The washed cells were lysed in an ultrasonic homogenizer (Polytron) in an equal volume of saline and split into aliquots for assay of ALA synthase, coproporphyrinogen oxidase, and protein (Lowry *et al.*, 1951).

**ALA synthase (EC 2, 3, 1, 37).** Estimation of ALA synthase was carried out by a radiochemical modification of the method of Dowdle *et al.* (1969). The results were expressed as pmol ALA produced per mg protein per hour.

**Coproporphyrinogen oxidase (EC 1, 3, 3, 3).** Assay of coproporphyrinogen oxidase was according to the method of Batlle *et al.* (1965) modified for leucocytes. Results were expressed as nmol protoporphyrin produced per g protein per hour.

## Results

The values for porphyrin and porphyrin precursor excretion in the patient and his family are given in Table 2. The father and 2 sibs had normal porphyrin excretion, but the mother excreted increased amounts of faecal coproporphyrin. At the time of his acute attack porphyrin and porphyrin precursor levels were greatly increased in our patient and this was associated with increased activity of leucocyte ALA synthase, the mitochondrial rate-limiting enzyme of haem biosynthesis. In addition, no detectable activity of leucocyte coproporphyrinogen oxidase was observed. Similar increased ALA synthase activity and depression of coproporphyrinogen oxidase activity were found in the patient's mother, confirming that she is a latent case of the disease (Table 3).

## Discussion

The pathway of haem biosynthesis is outlined in the Fig. In hereditary coproporphyria increased activity of the initial mitochondrial rate-limiting enzyme of haem biosynthesis, ALA synthase, has previously been shown in the liver (Sasaki *et al.*, 1969; Kaufman and Marver, 1970; McIntyre *et al.*, 1971). In our study a similar increased activity has been found in the leucocytes. It has long been suspected and recently confirmed (Brodie *et al.*, 1976) that a defined depression of coproporphyrinogen oxidase, the penultimate enzyme in the pathway, led to the excess excretion of coproporphyrin in this disease. Such a depression has clearly been shown in the leucocytes of the 2 patients studied. The increased ALA synthase activity may therefore be due to depressed levels of circulating free haem brought about by reduced coproporphyrinogen oxidase activity.

This case is unusual in that the diagnosis of porphyria was suspected when the patient developed gastrointestinal symptoms similar to those of an acute porphyric attack but the biochemical findings excluded acute porphyria as the cause of the episode. Indeed, had the urine been tested only in the ward side room with Ehrlich's aldehyde reagent, the diagnosis would have been missed. This emphasizes the point made by Gatfield *et al.* (1972) that though it is common practice to test qualitatively for PBG in urine in the side room, it is also necessary to look for ALA and porphyrins if some cases of porphyria are not to be missed. Moreover, in hereditary coproporphyria raised faecal coproporphyrin may be the only abnormality, and complete quantitative analysis of urine and stool for porphyrins and precursors (Rimington, 1971) is therefore required to exclude porphyria.

It is difficult to ascertain the exact relationship of the seizures and anticonvulsant therapy to the porphyria. Seizures are not uncommonly associated with acute porphyria in attack and certain anticonvulsants are well known inducers of an acute

porphyric attack. The most commonly implicated drugs are the barbiturates, but phenytoin, primidone, chlordiazepoxide, meprobamate, phensuximide, and troxidone are also considered to be porphyrinogenic (Wetterberg, 1976). Our patient had received phenobarbitone, phenytoin, meprobamate, and most recently primidone. The 2 children previously reported as having symptomatic hereditary coproporphyria (Birchfield and Cowger, 1966; Haeger-Aronsen *et al.*, 1968) were also on anticonvulsants at the time of diagnosis. Birchfield's patient shows some similarity to ours (Table 4), with recurrent episodes of seizures of varying type which continued despite numerous anticonvulsants. At the age of 7 she showed no evidence of mental deterioration, being in the dull normal category of intellectual function. The third child (Haeger-Aronsen *et al.*, 1968) suffered intermittent episodes of headache and vomiting without abdominal pain from the age of 2 years. After a grand mal seizure at the age of 10 she received phenobarbitone therapy for 2 years until she developed abdominal pain and vomiting and was found to be having an acute attack of hereditary coproporphyria. At age 13 she was of normal intelligence.

When drugs were withdrawn seizure control improved in 2 cases and abdominal pain stopped in the third. It seems likely that the therapy played a part in inducing the acute attacks. Convulsions in children are common and are often treated with anticonvulsant drugs. In the porphyric child such treatment may well result in a further fit and further drugs perhaps causing EEG disruption and permanent brain damage. No anticonvulsant drug is totally safe for use in the acute porphyrias but clonazepam and sodium valproate have not been implicated as yet in the production of an acute porphyric attack. In our patient administration of sodium valproate did not increase urinary porphyrin or precursor excretion.

Porphyria in childhood is rare. Barclay (1974) recently reviewed the literature on acute intermittent porphyria in childhood and found only 37 cases,

Table 4 Seizure types and EEG pattern in the 3 children with symptomatic hereditary coproporphyria

Case	Age of onset (years)	Seizure types	EEG	No. of antiepileptic drugs used	Mental state
Present	2½	Falls, myoclonic, tonic, atypical absences, clonic, and hemiconvulsions	Slow spike wave, fast spiking in seizures	14	Hyperkinetic; severe mental handicap at age 10
Birchfield & Cowger (1966)	3½	Febrile grand mal, 'akinetic', myoclonic, 'minor motor', atypical absences	Spike and wave, repetitive spikes in seizure	14	Dull normal at age 7
Haeger-Aronsen <i>et al.</i> (1968)	10	Tonic/clonic with left clonic	'Partially paroxysmal'	1	Normal at age 13

though few clinical details are given. The incidence of fits complicating an acute attack of porphyria in adults is 15% (Goldberg and Rimington, 1962), but the association of chronic epilepsy with porphyria is not well documented. Magnussen *et al.* (1975) reported a case of acute intermittent porphyria with long-standing grand mal seizures and discussed a possible relationship. We are aware of a further case in an institutionalized patient with mental retardation who developed intractable idiopathic epilepsy at the age of 3 years and in whom the diagnosis of porphyria was made at the age of 29. As in the present case, acquired skills were lost. We wish to stress the importance of considering the diagnosis of acute porphyria in any child with unexplained refractory epilepsy, especially when there are multiple seizure types suggestive of organic brain disorder, 'epileptic encephalopathy' with slow spike-wave on EEG (Chevrie and Aicardi, 1972), or episodes of minor epileptic status (Brett, 1966).

Grateful acknowledgement is made to Dr. R. A. Shanks and Professor A. Goldberg for helpful criticism and advice.

#### References

- Barclay, N. (1974). Acute intermittent porphyria in childhood. A neglected diagnosis? *Archives of Disease in Childhood*, **49**, 404-406.
- Battle, A. M. del., Benson, A., and Rimington, C. (1965). Purification and properties of coproporphyrinogenase. *Biochemical Journal*, **97**, 731-740.
- Berger, H., and Goldberg, A. (1955). Hereditary coproporphyria. *British Medical Journal*, **2**, 85-88.
- Birchfield, R. I., and Cowger, M. L. (1966). Acute intermittent porphyria with seizures. Anticonvulsant medication-induced metabolic changes. *American Journal of Diseases of Children*, **112**, 561-565.
- Bottomley, S. S., Tanaka, M., and Everett, M. A. (1975). Diminished erythroid ferrochelatase activity in protoporphyria. *Journal of Laboratory and Clinical Medicine*, **86**, 126-131.
- Brett, E. M. (1966). Minor epileptic status. *Journal of the Neurological Sciences*, **3**, 52-75.
- Brodie, M. J., Thompson, G. G., Moore, M. R., Beattie, A. D., and Goldberg, A. (1976). Hereditary coproporphyria. *Quarterly Journal of Medicine*, **181**, 849-861.
- Chevrie, J. J., and Aicardi, J. (1972). Childhood epileptic encephalopathy with slow spike-wave. A statistical study of 80 cases. *Epilepsia*, **13**, 259-271.
- Chisolm, J. J. (1964). Symposium on porphyrins. II. Pediatric aspects of the porphyrias. *Journal of Pediatrics*, **64**, 159-172.
- Dean, G., Kramer, S., and Lamb, P. (1969). Coproporphyria. *South African Medical Journal*, **43**, 138-142.
- Dowdle, E., Mustard, P., and Eales, L. (1967).  $\delta$ -aminolaevulinic acid synthetase activity in normal and porphyric human livers. *South African Medical Journal*, **41**, 1093-1096.
- Garfield, P. D., Haust, H. L., and Durrant, D. (1972). Porphyria in childhood following transient neonatal quadriplegia. *Developmental Medicine and Child Neurology*, **14**, 495-501.
- Goldberg, A., and Rimington, C. (1962). *Diseases of Porphyrin Metabolism*. Thomas, Springfield, Illinois.
- Goldberg, A., Rimington, C., and Lochhead, A. C. (1967). Hereditary coproporphyria. *Lancet*, **1**, 632-636.
- Goldberg, A., Brodie, M. J., and Moore, M. R. (1977). Porphyrin metabolism and the porphyrias. *Price's Textbook of Medicine*, 12th ed. Oxford University Press, London (in press).
- Haeger-Aronsen, B., Stathers, G., and Swahn, G. (1968). Hereditary coproporphyria. Study of a Swedish family. *Annals of Internal Medicine*, **69**, 221-227.
- Hunter, J. A., Khan, S. A., Hope, E., Beattie, A. D., Beveridge, G. W., Smith, A. W. M., and Goldberg, A. (1971). Hereditary coproporphyria. Photo-sensitivity, jaundice and neuropsychiatric manifestations associated with pregnancy. *British Journal of Dermatology*, **84**, 301-310.
- Jaeger, A., Tempe, J. D., Geisler, F., Nordmann, Y., and Mantz, J. M. (1975). La coproporphyrémie héréditaire. *Nouvelle Presse Médicale*, **4**, 2783-2787.
- Kaufman, L., and Marver, H. S. (1970). Biochemical defects in two types of human hepatic porphyria. *New England Journal of Medicine*, **283**, 954-958.
- Lomholt, J. C., and With, T. K. (1969). Hereditary coproporphyria. A family with unusually few and mild symptoms. *Acta Medica Scandinavica*, **186**, 83-85.
- Lowry, O. H., Rosebrough, N. J., Farr, A. L., and Randall, R. J. (1951). Protein measurement with the folin phenol reagent. *Journal of Biological Chemistry*, **193**, 265-275.
- McIntyre, N., Pearson, A. J. G., Allan, D. J., Craske, S., West, G. M. L., Moore, M. R., Beattie, A. D., Paxton, J., and Goldberg, A. (1971). Hepatic delta-aminolaevulinic acid synthetase in an attack of hereditary coproporphyria and during remission. *Lancet*, **1**, 560-564.
- Magnussen, C. R., Doherty, J. M., Hess, R. A., and Tschudy, D. P. (1975). Grand mal seizures and acute intermittent porphyria. *Neurology*, **25**, 1121-1125.
- Mauzerall, D., and Granick, S. (1956). The occurrence and determination of  $\delta$ -aminolaevulinic acid and porphobilinogen in urine. *Journal of Biological Chemistry*, **219**, 435-448.
- Meyer, U. A., Strand, L. J., Doss, M., Rees, A. C., and Marver, H. S. (1972). Intermittent acute porphyria-demonstration of a genetic defect in porphobilinogen metabolism. *New England Journal of Medicine*, **286**, 1277-1282.
- Rimington, C. (1971). *Quantitative Determination of Porphobilinogen and Porphyrins in Urine and Porphyrins in Faeces and Erythrocytes*. Broadsheet No. 70. Association of Clinical Pathologists, London.
- Sasaki, H., Kaneko, K., and Tsuneyama, H. (1969). Activities of delta-aminolaevulinic acid synthetase in the liver and bone marrow of hepatic coproporphyria. *Acta Medica et Biologica*, **17**, 97-99.
- Wetterberg, L. (1976). Report on international survey of safe and unsafe drugs in acute intermittent porphyria. Supplement of *Proceedings of the 1st International Meeting on Porphyrins in Human Diseases*, pp. 191-202. Ed. by M. Doss and P. Nawrocki. Falk, Freiburg.

Correspondence to Dr. A. B. Houston, Royal Hospital for Sick Children, Yorkhill, Glasgow G3 8SJ.