

- Lenney, W., and Milner, A. D. (1978). At what age do bronchodilator drugs work? *Archives of Disease in Childhood*, **53**, 532-535.
- Milner, A. D., and Ingram, D. (1970). Peak expiratory flow rates in children under five years old. *Archives of Disease in Childhood*, **45**, 780-782.
- Molina, M. J., and Rowland, F. S. (1974). Stratospheric sink for chlorofluoromethanes: chlorine atom catalysed destruction of ozone. *Nature*, **249**, 810-812.

W. LENNEY, A. D. MILNER, AND E. J. HILLER
Department of Child Health, Nottingham City Hospital and Nottingham Children's Hospital

Correspondence to Dr A. D. Milner, Department of Child Health, The City Hospital, Hucknall Road, Nottingham.

Depigmented hair

The earliest sign of tuberous sclerosis

Tuberous sclerosis is an important cause of infantile spasms or other early epileptic seizures with developmental delay—that is, of seizures suggesting an underlying cerebral malformation. Diagnosis is necessary to allow appropriate management including precise genetic counselling. Until now the earliest useful external sign has been the ash-leaf shaped depigmented macule or 'white spot'. Unfortunately these depigmented macules are not always visible at birth or in early months of life, particularly in fair-skinned individuals or in the absence of sun-tan.

We recently observed 4 children with tuberous sclerosis each one of whom had had at least one tuft of white scalp hair present since birth. This sign is illustrated in an encyclopaedic textbook (Swaiman and Wright, 1975). Patches of grey (poliosis) or white (leukotrichia) hair are common in tuberous sclerosis and were present in 18% of cases in a survey from hospitals for mental deficient patients (Nickel and Reed, 1962). However this is not generally recognised by paediatricians and the sign received no mention in a review of 100 affected children (Pampiglione and Moynahan, 1976). No previous

paper has drawn attention to this distinctive feature as the earliest sign of the disorder.

Patients

The children reported all attended this hospital during 1977. They had originally presented with developmental delay and with either infantile spasms or other varieties of epileptic seizure, suggestive of an abnormally structured brain. The parents of each child had noticed one or more patches of white hair soon after birth (Figure) but had not observed other stigmata of the disease until much later (Table). Case 1 was the only infant to be seen by one of us at an age when depigmented hair was present but no characteristic depigmented macules were detectable even though these were sought; 13 months later depigmented macules had appeared where initial colour photographs confirmed their previous absence.

We could not recognise any depigmentation of the scalp underlying the white tufts, nor did we make any biopsies, but in Case 3 one tuft abutted the temporal hair line and clearly arose from the continuation of an ovate, depigmented macule on the adjacent hairless skin (Figure).

Discussion

Tuberous sclerosis is an important cause of early seizures with impaired development and on follow-up accounts for at least 25% of cases of infantile spasms (Pampiglione and Pugh, 1975). The early diagnosis of tuberous sclerosis has been much easier since it has been known that ash-leaf shaped, depigmented macules are characteristic of the disorder (Gold and Freeman 1965; Fois *et al.*, 1973) and are probably present at birth (Fitzpatrick *et al.*, 1968). However, these white macules may not be visible in fair-skinned infants, even under Wood's light, and may not become apparent until solar pigmentation is acquired (as may have been the case in Case 1).

Depigmented hair does not have this disadvantage, being readily recognised, if looked for, even in the

Table Four children with tuberous sclerosis, presenting with early seizure and developmental delay, in whom a tuft of white hair had been present since birth

Case	Age (months)		At which white macules noted	Other manifestations of tuberous sclerosis
	At presentation	At diagnosis		
1	5	18	18*	Epilepsy, mental retardation, shagreen patch
2	5	8	8	Epilepsy, retinal phakomata
3	2	84	24	Epilepsy, mental retardation, adenoma sebaceum
4	18	84	24	Epilepsy, mental retardation, adenoma sebaceum

*Not present at 5 months.

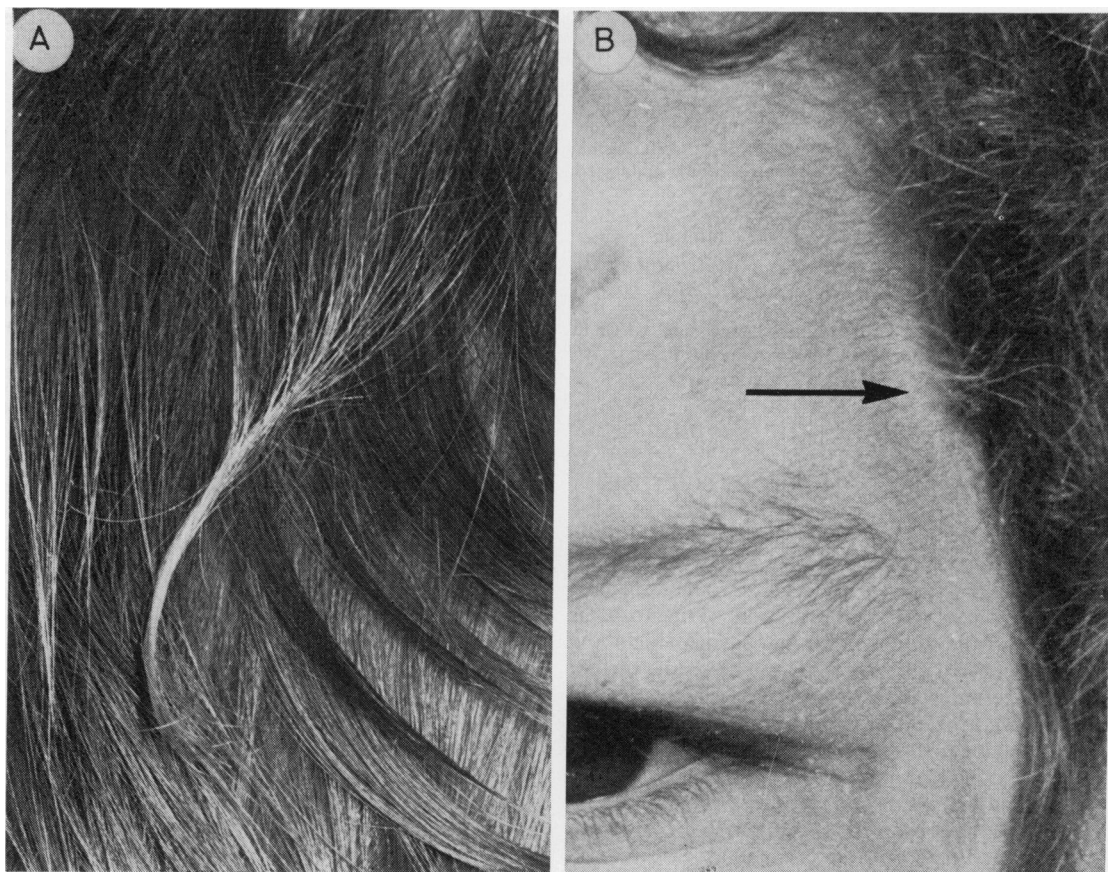


Figure (A) A tuft of white hair over the vertex in Case 2 aged 11 months. (B) Case 3. Note the depigmented macule on the temporal hair-line and the white hair growing from it.

neonatal period. Because the tufts of white hair appear to grow out from the equivalent of depigmented macules on the scalp, it is likely that they have the same pathognomonic significance. Poliosis may be found in several other disorders (Waardenburg's syndrome, pie-baldism, vitiligo, Vogt-Koyanagi syndrome, neurofibromatosis), but these are not readily confused with tuberous sclerosis. The finding of one or more tufts of white hair in an infant with seizures strongly suggests the diagnosis of tuberous sclerosis and, even in an otherwise normal baby, it should alert the physician to further surveillance.

Summary

We have studied 4 children with tuberous sclerosis with one or more patches of depigmented scalp hair and in each case these were noticed by the parents at birth. In one patient the finding of a tuft of white

hair preceded the appearance of white macules by many months. A tuft of white scalp hair is a useful new sign of tuberous sclerosis in the newborn and young child, and the hair should be examined as carefully as the skin when early 'organic' seizures are unexplained.

Addendum

We are grateful to Mrs Ann Hunt, Honorary Secretary of the Tuberous Sclerosis Association of Great Britain, for the results of a recent questionnaire sent to all members who have children with tuberous sclerosis. Of 74 replies, 15 (20%) had observed white hair patches. In 4 children the patches were noted at birth. In 5 the white hair patches were noticed before depigmented skin patches. Interestingly, the white hair patches later disappeared in 2 children.

We thank the Department of Medical Illustration for the photographs, and paediatricians who kindly referred the children.

This paper was presented on 18 November 1977 to the Scottish Paediatric Society in Edinburgh and also to the British Paediatric Neurology Association at Liverpool in January 1978.

References

- Fitzpatrick, T. B., Szabo, G., Hori, Y., Simone, A. A., Reed, W. B., and Greenberg, M. H. (1968). White, leaf-shaped macules (earliest visible sign of tuberous sclerosis). *Archives of Dermatology*, **98**, 1-6.
- Fois, A., Pindinelli, C. A., and Berardi, R. (1973). Early signs of tuberous sclerosis in infancy and childhood. *Helvetica paediatrica acta*, **28**, 313-321.
- Gold, A. D., and Freeman, J. M. (1965). Depigmented nevi: the earliest sign of tuberous sclerosis. *Pediatrics*, **35**, 1003-1005.
- Nickel, W. R., and Reed, W. B. (1962). Tuberous sclerosis. *Archives of Dermatology*, **85**, 209-226.
- Pampiglione, G., and Moynahan, E. J. (1976). The tuberous sclerosis syndrome: clinical and EEG studies in 100 children. *Journal of Neurology, Neurosurgery, and Psychiatry*, **39**, 666-673.
- Pampiglione, G., and Pugh, E. (1975). Letter: Infantile spasms and subsequent appearances of tuberous sclerosis syndrome. *Lancet*, **2**, 1046.
- Swaiman, K. F., and Wright, F. G. (1975). *The Practice of Pediatric Neurology*, volume 2, p. 741. Mosby: St Louis.
- R. C. McWILLIAM AND J. B. P. STEPHENSON
University Department of Child Health, and Fraser of Allander Unit, Royal Hospital for Sick Children, Yorkhill, Glasgow G3 8SJ

Correspondence to Dr J. B. P. Stephenson.

Bone growth in thalassaemic children

The recent interest in various aspects of growth of thalassaemic children resulted in studies of body growth (Kattamis *et al.*, 1970; Pantelakis *et al.*, 1978) and bone density (Johnston and Roseman, 1967; Lapatsanis *et al.*, 1976; Liakakos *et al.*, 1976). As the individual height is related to the length of the long bones, a reliable index of longitudinal bone growth is the increase in length of the metacarpal bones (Exton-Smith *et al.*, 1969; Ikkos *et al.*, 1972). We have therefore studied the metacarpal growth in thalassaemic children.

Materials and methods

Sixty-one children with homozygous β -thalassaemia and 35 controls were studied. The control group consisted of children admitted to the ENT department for tonsillectomy or adenoidectomy. The age

range in both groups was 5-13 years. Thalassaemic children had hepatosplenomegaly, anaemia, and bone lesions, and were transfused every 4-8 weeks. Pretransfusion blood Hb was 6-8 g/dl for at least one year before the study; 24 hours after transfusion it was 11 g/dl or more. The total and medullary widths of the 2nd, 3rd, and 4th metacarpal bones were measured using the method of Horsman and Simpson, 1975. The axial length of the 2nd, 3rd, and 4th metacarpal bones was also measured. All measurements were made by two of us (A.D. and H.G.). Denoting total bone width by TW, medullary width by MW, cortical width by CW, and bone length by L for each metacarpal, the following were evaluated (Horsman and Simpson, 1975).

$$TW = \frac{1}{2} (TW_1 + TW_2)$$

$$MW = \frac{1}{2} (MW_1 + MW_2)$$

$$CW = \frac{1}{2} (CW_1 + CW_2)$$

$$L = \frac{1}{2} (L_1 + L_2)$$

The averages for the 6 metacarpal bones of TW, MW, CW, and L denoted by \overline{TW} , \overline{MW} , \overline{CW} , and \overline{L} were evaluated.

Results

Table 1 shows the mean values and standard deviations (SDs) of the average length of the 6 metacarpal bones in the two groups of children. The length of the metacarpal bones was no different in the two groups between the ages of 5 and 11 years ($P > 0.1$). After age 11 years however, there was a difference ($P < 0.0025$).

Table 2 shows the mean values and SDs of the average total, medullary, and cortical widths of the 6 metacarpal bones (\overline{TW} , \overline{MW} , \overline{CW}), in the two groups. \overline{TW} was greater in the thalassaemic children aged 5-11 years but this difference was not observed after age 11 years ($P > 0.1$). \overline{MW} was greater in thalassaemic than in control children, and thalassaemic children had lower \overline{CW} between ages 5 and 13 years.

Table 3 shows the bone age retardation in thalassaemic children. For each age group the number of children with bone retardation and the range of retardation in months are shown. In the group 5-7 years half the children showed bone age retardation (> 6 months), whereas after this age bone retardation was found in almost two-thirds of the cases.

Discussion

Some authors (Johnston *et al.*, 1966; Johnston and Roseman, 1967; Lapatsanis *et al.*, 1976) have observed that the cortical width is smaller in thalassaemic children than in controls, but Liakakos