

Medulloblastoma—a changing prognosis?

NEIL McINTOSH

University College Hospital, London

SUMMARY 87 of 90 consecutive cases of medulloblastoma diagnosed at The Hospital for Sick Children, London, in the 10-year period 1965-74 were followed-up until death or until 1 January 1978. Only one patient survived in the 1st 5-year period and is a cure. In the 2nd 5-year period 17 (41%) of 41 patients presenting are alive and, of these, 11 are 5-year survivors (= 39% of possible 5-year survivors). Reasons for this improvement are discussed; it is thought likely that the main contribution is improved radiotherapeutic techniques.

Since Bailey and Cushing established medulloblastoma as an entity in 1925, it has been regarded as a predominantly paediatric cerebral tumour with a poor prognosis. Cushing (1930) showed that survival with radical surgery alone was impossible so that the current mainstays of treatment are a combination of surgery and radiotherapy. Surgery to the posterior fossa is as radical as is allowed at operation, and is followed by radiotherapy to the whole craniospinal axis as seeding occurs through cerebrospinal fluid paths. Until the 1950s very poor survival rates were uniformly reported (e.g. Lampe and MacIntyre, 1949; Chatty and Earle, 1971), but since then prognosis has improved, almost certainly because of better radiotherapeutic techniques (Smith *et al.*, 1961; Bloom *et al.*, 1969; Hope-Stone, 1970). Five-year survival rates as high as 75% have been quoted (Hope-Stone, 1970) but to the family doctor or neurosurgical unit counselling the newly diagnosed patient, the outlook is confusing as survival is generally quoted after successful completion of treatment. We report the follow-up on 87 of 90 consecutive cases diagnosed in the 10 years 1965-74. Histology in each case was confirmed by Professor T. Crawford at St George's Hospital. Divided into two consecutive 5-year periods there is more than a suggestion that the survival in the 2nd is better.

Cases and methods

Of 90 consecutive cases diagnosed with medulloblastoma in the 10-year period 1965-74, all except 3 cases have complete follow-up. These 3 (described below) are excluded from all the discussion.

Cases lost to follow-up.

Case 1

Girl, complete removal at diagnosis July 1967. Received no radiotherapy or other treatment. No details available since December 1973, when in Malta, alive and well; therefore 6 years after craniotomy, well.

Case 2

Boy, partial surgical removal in November 1969 followed by 5000 rads tumour dose to posterior fossa and 3000 rads to cranium and spinal cord. 14 months after treatment in Qatar in March 1971, said to be blind but otherwise well. No further details.

Case 3

Girl, diagnosed February 1970. Partial removal followed by suboptimal cranial irradiation (3000 rads) and no spinal irradiation. Two months after operation had the insertion of a ventriculo-atrial shunt and was then lost to follow-up in Iran in June 1970.

Cases 2 and 3 have possibly died, but Case 1 is a 'long-term' survivor.

Cases with complete data.

Sex

52 boys and 35 girls.

Age

Three months to 11 years, median 4 years.

Length of symptoms before diagnosis

One week to greater than one year, median < 3 months.

Symptoms

These were well described recently by Gjerris (1976). Symptoms of many of the cases in this series were discussed previously by Till (1975).

Surgery

Definitive surgery was carried out in 94% of cases at The Hospital for Sick Children in London. As a routine this consisted of posterior fossa decompression with removal of as much tumour as the surgeon considered possible at the time of operation. Macroscopic removal was thought complete in 9 (10%) cases and partial in 72 (83%). In all except one, surgery was at the time of initial diagnosis, the exception being a patient referred from Zambia who had received 4 months of chemotherapy (prednisolone, methotrexate, and vincristine) before transfer to England for surgery. Of the 5 cases not receiving definitive surgery, 3 were preoperative deaths and 2 presented with spinal secondaries for which they had laminectomies; one of these 11 months later had a frontal craniotomy for a frontal secondary.

Radiotherapy

11 of 87 patients died before radiotherapy could be initiated, and 2 other patients were not given radiotherapy. Five patients died during radiotherapy. Thus 66 (76%) patients survived the combined treatment of surgery and radiotherapy. Radiotherapy was carried out at 6 different centres—38 cases were treated at UCH, London, receiving treatment with 250 kV equipment until 1967 and subsequently with ⁶⁰Co equipment. 12 cases were treated at Guildford, before 1968, receiving radiation from 250 kV equipment. 13 cases received treatment at the Royal Marsden Hospital, 3 before 1968 using 250 kV equipment, and 9 after 1968 using 6 MeV equipment. One case was treated at Northampton, one at Nottingham, and one at Derby. Before 1968, radiotherapy was generally with 250 kV equipment and after this date with ⁶⁰Co or 6 MeV equipment.

Radiation dosage varied, particularly before 1970. The overall outcome of the 87 cases presenting is shown in the Figure.

Table 1 shows how the dosage of radiotherapy has on the whole increased at the various centres in the 2nd 5-year period. Other features of radiotherapy technique have changed. In addition to greater total radiation dosage, better care has evolved by firstly avoiding areas of underdosage of the neuraxis which might allow seeding of tumour cells, and secondly by ensuring no overlap of spinal and cranial fields which might lead to gliosis at the junction of these.

Immunotherapy (Bloom, 1975)

After 1970 immunotherapy was given to 14 patients

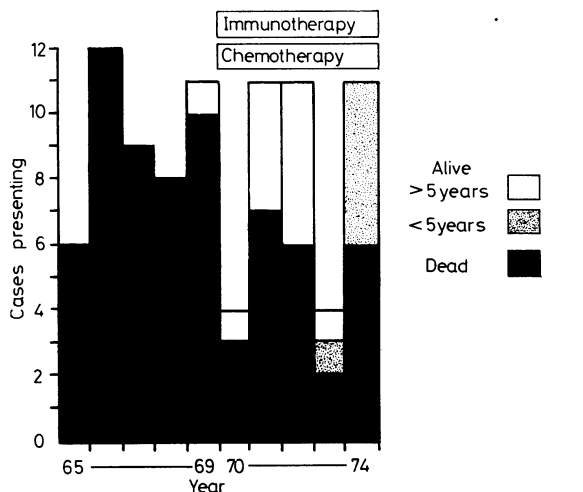


Figure Outcome on 1 January 1978 for all cases according to year of presentation.

Table 1 Dosage of radiotherapy given

Period	Total no.	Adequate treatment	
		Posterior fossa*	Spinal cord†
1965-69	33	10	13
1970-74	33	30	28
		P < 0.001	P < 0.001

*Adequate treatment posterior fossa = >4000 rads, †spinal cord = >3000 rads.

as part of a wider trial. Active immunisation was attempted, using autologous medulloblastoma tissue irradiated with 15000 rads and injected post-operatively subcutaneously. Six injections were normally given during the course of radiotherapy. Seven of these 14 patients are alive, and all are 5-year survivors.

Chemotherapy

12 patients received chemotherapy with their initial treatment and 2 received chemotherapy with recurrence. One case from Zambia had chemotherapy before surgery (see above). The type of chemotherapy varied from one injection of vincristine only to a combination of intrathecal methotrexate, oral CCNU, and IV vincristine in repeated courses. No cases included in the co-operative European trial of adjuvant chemotherapy run by the International Society of Paediatric Oncology (SIOP), which started in January 1975, are included in this series which is complete up to the time of the start of the trial.

Results

The overall outcome of the 87 cases presenting is shown in the Figure. The age range, sex ratio, and length of symptoms before diagnosis are all similar to other extensive series. All except one case diagnosed in the 1st 5-year period died within 4 years, the exception being alive and well 9 years after operation. In the 2nd 5-year period 11 cases are 5-year survivors (39% of those possible), and 6 others are alive and well, although they are not yet 5-year survivors.

All 18 of the current survivors received surgery followed by 5000 rads to the posterior fossa, and 3000–3500 rads to the spinal cord. Seven cases in addition had immunotherapy and 7 chemotherapy. Should complete surgical removal of macroscopic tumour be possible, prognosis is better, 55% are survivors compared with 18% of the partial removal group ($\chi^2 P < 0.01$).

Five survivors are completely well and asymptomatic. Four have features possibly referable to their surgery or radiotherapy, such as visual loss or short stature, and 6 have soft signs such as mild ataxia which could be due to initial tumour damage, surgery, or radiotherapy. Two survivors have severe clinical problems interfering with their everyday life, and both of these have evidence of tumour recurrence.

Two patients presented with secondaries at the time of diagnosis—both are dead. One patient without shunt finally died with extra-cerebrospinal secondaries in the lung. Secondaries outside the central nervous system are well recorded although rare with this tumour but have never before been recorded within the lung in the absence of a ventriculo-atrial shunt (Makeever and King, 1966).

Table 2 compares the outcome in the two 5-year periods 1965–69, 1970–74. It considers both the total cases presenting and the prognosis in those successfully completing surgery and radiotherapy. The 5-year survival of all cases presenting has improved from 2% in the first period to 39% of

those cases in the 2nd period where 5-year follow-up is so far possible. By the χ^2 test these differences are statistically highly significant.

Discussion

Cushing, having defined medulloblastoma as an entity, recognised two things about this tumour. Firstly, that there was a high operative mortality and secondly, that without additional radiation, death was invariable within 6 months of diagnosis. The high operative mortality has been confirmed more recently (Smith *et al.*, 1961; McFarland *et al.*, 1969). Elsberg and Gotten (1933) showed that a more conservative approach to surgery consisting of decompression of the posterior fossa with removal of the bulk of tumour tissue and reopening of cerebrospinal fluid paths, gave much better operative figures and did not appear adversely to influence the long-term outcome. This approach, probably associated with advances in anaesthesia and intensive postoperative care, has improved operative and immediate postoperative mortality in this series to 14% (20.5% of the 1st 5-year group and 10.0% of the 2nd group).

The improved survival in the 2nd 5-year period is shown in Table 2. In addition to surgical advances, this improvement could be due to other factors. Firstly, radiation therapy techniques improved in this period with the change from 250 kV to 2–10 MeV or ^{60}Co equipment (Bloom *et al.*, 1969). Secondly, a higher dosage of radiotherapy was applied to both posterior fossa and spinal cord (Table 1) and with awareness was probably applied more effectively. Thirdly, immunotherapy or chemotherapy may have improved the outlook. Because 4 of the survivors had only surgery and radiotherapy, it is likely that improved prognosis is due mainly to improved radiotherapy, not to chemotherapy. This is substantiated by data from the first 100 patients on the SIOP trial of adjuvant chemotherapy in medulloblastoma, where so far there is no difference between patients allocated chemotherapy in addition, compared with the group receiving surgery and radiotherapy alone (Bloom, 1977, personal communication). However, this trial has only been in effect 3 years, so it is too early to draw any conclusions.

The improved techniques of radiotherapy have been described (Smith *et al.*, 1961; Bloom *et al.*, 1969; Hope-Stone, 1970). Hope-Stone in a series of 35 cases, had a 58% 5-year survival but only in a group completing successfully surgery and radiotherapy. The mean age in this series was 9 years which is old compared with other series, and this may favourably have influenced his results.

Table 2 Comparison of survival in the two periods 1965–69 and 1970–74

Outcome	Period	No.	Survival	
			2 years	
			No.	(%)
Cases presenting	1965–69	46	6	(13)
	1970–74	41	22	(53)*
Cases completing radiotherapy	1965–69	33	6	(19)
	1970–74	33	22	(65)

* $\chi^2 P < 0.001$.

The reason for the poor survival in the first 5-year period has to be attributed to inadequate radiation, as overall only cases receiving 5000 rads to posterior fossa and 3500 rads to the spinal cord survived. Very few cases in this group received this amount of radiation (Table 1).

For the paediatrician or neurosurgeon counselling parents at the time of diagnosis, it is important to know that the prognosis is improving. At least 39% are now 5-year survivors and overall in this series, no patient has died more than 4 years after diagnosis, although late deaths have occurred in other series (Gjerris, 1976). It may be that 5-year survival will be as high as 46%. By the age + 9 months rule (Collins rule for embryonal tumours) we have overall in the 10-year period 7 (8%) cases cured of their condition (Bloom *et al.*, 1969).

My thanks for encouragement and information from Mr Kenneth Till and Mr Norman Grant, The Hospital for Sick Children, London, Dr Nicholas Godlee and Dr Robert Boyd, University College Hospital, London, Dr H. J. G. Bloom, Royal Marsden Hospital, London, and many other paediatricians.

References

- Bailey, P., and Cushing, H. (1925). Medulloblastoma cerebelli: a common type of midcerebellar glioma of childhood. *Archives of Neurology and Psychiatry*, **14**, 192–224.
- Bloom, H. J. G. (1975). Combined modality therapy for intracranial tumours. *Cancer*, **35**, 111–120.
- Bloom, H. J. G., Wallace, E. N. K., and Henk, J. M. (1969). The treatment and prognosis of medulloblastoma in children. *American Journal of Roentgenology*, **105**, 43–62.
- Chaty, E. M., and Earle, K. M. (1971). Medulloblastoma. A report of 201 cases with emphasis on the relationship of histological variants to survival. *Cancer*, **28**, 977–983.
- Cushing, H. (1930). Experiences with the cerebellar medulloblastomas: a critical review. *Acta pathologica et microbiologica Scandinavica*, **7**, 1–86.
- Elsberg, C. A., and Gotten, N. (1933). Result of conservative compared with radical operations in the cerebellar medulloblastomas. *Bulletin of the Neurological Institute of New York*, **3**, 33–52.
- Gjerris, F. (1976). Clinical aspects and long term prognosis of intracranial tumours in infancy and childhood. *Developmental Medicine and Child Neurology*, **18**, 145–159.
- Hope-Stone, H. F. (1970). Results of treatment of medulloblastomas. *Journal of Neurosurgery*, **32**, 83–88.
- Lampe, I., and MacIntyre, R. S. (1949). Medulloblastoma of the cerebellum. *Archives of Neurology and Psychiatry*, **62**, 322–329.
- McFarland, D. R., Horowitz, H., Saenger, E. L., and Bahr, G. K. (1969). Medulloblastoma—a review of prognosis and survival. *British Journal of Radiology*, **42**, 198–214.
- Makeever, L. C., and King, J. D. (1966). Medulloblastoma with extracranial metastasis through a ventriculovenous shunt. *American Journal of Clinical Pathology*, **46**, 245–249.
- Smith, R. A., Lampe, I., and Kahn, E. A. (1961). The prognosis of medulloblastoma in children. *Journal of Neurosurgery*, **18**, 91–97.
- Till, K. (1975). *Paediatric Neurosurgery*. Blackwell Scientific: Oxford.

Correspondence to Dr N. McIntosh, Department of Child Health, St George's Hospital, Blackshaw Road, London SW17 0QT.

Received 15 June 1978