

calcaemia to hypocalcaemia in pseudohypoparathyroidism is now well established (Mann, Alterman, and Hills, 1962) and was again shown in one of our cases. It seems that normocalcaemia alone is insufficient evidence to exclude the diagnosis of pseudohypoparathyroidism when appropriate clinical features are present.

The concept of the role of cyclic AMP as a 'messenger' for several hormones has now been accepted and there has been increasing interest in the clinical application of this concept (Murad and Pak, 1972; Murad, 1973). Defective excretion of cyclic AMP after infusion of PTH in adult patients with pseudohypoparathyroidism has been shown by various investigators (Chase *et al.*, 1969; Kaminsky *et al.*, 1970; Greenberg *et al.*, 1972). The 2 children studied here likewise failed to respond to the hormone. The usefulness of phosphaturic response to PTH in the diagnosis of pseudohypoparathyroidism has frequently been challenged (MacGregor and Whitehead, 1954). In our patients an increase in urinary phosphate was observed when an increased dose of PTH was infused. The failure of urinary cyclic AMP to rise in response to increasing dosage of PTH, in contrast to the sharp rise in normal subjects, may be pathognomonic of pseudohypoparathyroidism. Our results support the possibility that measurement of urinary cyclic AMP after PTH infusion may be superior to measurement of urinary phosphate as a diagnostic method in this disease.

Summary

Measurement of urinary cyclic AMP (adenosine 3'5'-cyclic phosphate) and examination of calcium and phosphorus metabolism was carried out in two children with pseudohypoparathyroidism. In both patients infusion of parathyroid hormone failed to elicit any change in urinary cyclic AMP, while a dose-dependent increase in urinary cyclic AMP occurred in a normal control. The findings agree with the concept of unresponsiveness of renal cortical tissue to parathyroid hormone in pseudohypoparathyroidism and provide further evidence that measurement of urinary cyclic AMP during parathyroid hormone infusion may be the method of choice in the diagnosis of this disease.

The authors are indebted to Drs. F. H. A. Gaudin and K. P. Fellenz for permission to include their patients in the study and to Dr. D. Hardwick for technical assistance.

REFERENCES

- Albright, F., Burnett, C. H., Smith, P. H., and Parson, W. (1942). Pseudohypoparathyroidism—an example of Seabright-Bantam syndrome. *Endocrinology*, **30**, 922.

- Chase, L. R., Melson, G. L., and Aurbach, G. D. (1969). Pseudohypoparathyroidism: defective excretion of 3'5'-AMP in response to parathyroid hormone. *Journal of Clinical Investigation*, **48**, 1832.
- Gilman, A. G. (1970). A protein binding assay for adenosine 3'5'-cyclic monophosphate. *Proceedings of the National Academy of Sciences of the U.S.A.*, **67**, 305.
- Greenberg, S. R., Karabell, S., and Saade, G. A. (1972). Pseudohypoparathyroidism: a disease of the 'second messenger'. *Archives of Internal Medicine*, **129**, 633.
- Kaminsky, N. I., Broadus, A. E., Hardman, J. G., Jones, D. J., Jr., Ball, J. H., Sutherland, E. W., and Liddle, G. W. (1970). Effects of parathyroid hormone on plasma and urinary adenosine 3'5'-monophosphate in man. *Journal of Clinical Investigation*, **49**, 2387.
- MacGregor, M. E., and Whitehead, T. P. (1954). Pseudohypoparathyroidism. *Archives of Disease in Childhood*, **29**, 398.
- Mann, J. B., Alterman, S., and Hills, A. G. (1962). Albright's hereditary osteodystrophy comprising pseudohypoparathyroidism and pseudopseudohypoparathyroidism. *Annals of Internal Medicine*, **56**, 315.
- Murad, F. (1973). Clinical studies and applications of cyclic nucleotides. *Advances in Cyclic Nucleotide Research*, **3**, 355.
- Murad, F., and Pak, C. Y. C. (1972). Urinary excretion of adenosine 3'5'-monophosphate and guanosine 3'5'-monophosphate. *New England Journal of Medicine*, **286**, 1382.

WAH JUN TZE*, JOHN SAUNDERS†, and GEORGE IAN DRUMMOND‡
Department of Paediatrics and Pharmacology, University of British Columbia, and Children's Hospital, Vancouver, B.C.

*Correspondence to Dr. W. J. Tze, Children's Hospital, 250 West 59th Avenue, Vancouver, Canada V5X 1X2.

Present addresses: †St. Thomas's Hospital, London, S.E.1.
 ‡Department of Pharmacology, University of Calgary, Calgary, Alberta, Canada.

Lupus-scleroderma syndrome induced by ethosuximide

Systemic lupus erythematosus (SLE) induced by anticonvulsant drugs is well known to many clinicians, though Alarcón-Segovia (1969) in his excellent review article was able to find only 60 published cases. Various anticonvulsant drugs, like diphenylhydantoin, troxidone, and primidone, have this potential despite differences in chemical structure. Recently another anticonvulsant, ethosuximide, has also been implicated in inducing the lupus syndrome (Livingston *et al.*, 1968). However, scleroderma has never been reported to be induced by drugs. Winkelmann (1971) in his comprehensive review, mentioned no drugs in the pathogenesis of scleroderma.

This paper describes a young Chinese girl who developed SLE and scleroderma while on treatment with ethosuximide for epilepsy.

Case report

A 16-year-old Chinese girl had suffered from grand mal epilepsy since the age of 2 and was controlled with

phenobarbitone. When she was 12 years old she began to have more frequent grand mal convulsions with occasional minor seizures suggestive of petit mal epilepsy. She was then given phenobarbitone, diphenylhydantoin, and troxidone with partial success. Later ethosuximide was added by her paediatrician. She was on all four drugs for 2 years. One week before her first admission she noticed that her fingers were stiff and the ankles and wrists swollen and painful. Clinical examination revealed that she was grossly anaemic and febrile. The skin over her fingers, legs, and feet was tight and firm. The finger and wrist joints were slightly tender but were not swollen or inflamed. A maculopapular eruption was found on the trunk. Abdominal examination revealed hepatosplenomegaly of 3 cm each. There were no cardiovascular, respiratory, or neurological abnormalities.

Laboratory investigations showed haemoglobin 6 g/dl, white cell count 2000/mm³, platelet count 10 000/mm³, and reticulocyte count 1%. Peripheral blood film showed normochromic red blood cells and occasional normoblasts. Bone marrow aspirate showed hypocellular and hypoplastic marrow with increase in iron store. Erythrocyte sedimentation rate (ESR) was 146 mm/h. Lupus erythematosus (LE) cells were detected on many occasions. Antinuclear fact (ANF), direct Coombs's test, and VDRL were also positive. Rheumatoid factor was negative. Serum albumin and globulin were 3.0 g and 3.7 g/100 ml, respectively; γ -globulin was 2.4 g/100 ml. Urine analysis showed 1+ proteinuria. Blood urea, creatinine clearance, electrolytes, and liver function tests were all normal. Electrocardiogram, chest x-ray, and intravenous pyelogram showed no abnormalities.

A clinical diagnosis of anticonvulsant-induced SLE was made at that stage, and the tight, sclerotic skin was regarded as an unusual cutaneous feature of SLE. All previous medication except phenobarbitone was discontinued. She was given blood transfusion which raised Hb to 9 g/dl. In addition, she was started on prednisolone 15 mg four times a day. Fever and joint pain soon subsided and the fingers became less stiff, though the skin over the fingers remained sclerotic. Further improvement took place over the next 3 months, the skin became normal and the anaemia completely corrected. Hb was 13 g/dl, white cell count 5000/mm³, and platelet count 100 000/mm³. Remission of the drug-induced SLE was further confirmed by a normal ESR of 12 mm/h, disappearance of LE cells, and negative Coombs's test and VDRL. During this period phenobarbitone did not control her epilepsy. She had frequent grand mal seizures interspersed with fainting attacks of brief duration. Diphenylhydantoin 100 mg three times a day was therefore given in addition to phenobarbitone. No relapse of SLE was detected over the next 6 weeks. Hb, white cell count, platelet count, and ESR tests done at weekly intervals were normal, and the LE cells and Coombs's test remained negative. The addition of diphenylhydantoin reduced the frequency of grand mal attacks but the minor seizures continued. It was decided at that stage to put

her back on ethosuximide which was, in our opinion, less likely to induce SLE than troxidone. 3 weeks after starting ethosuximide 500 mg twice a day the patient developed fever, a maculopapular rash over the legs, and tightness and pain over the small finger joints.

Clinical examination showed that she was mildly anaemic and febrile. Cervical lymph nodes were enlarged. Finger joints were tender and the skin over them tight and shiny. A malar flush was seen on the face; a maculopapular eruption was seen over both thighs and legs. Widespread sclerosis of skin in the form of plaques over shoulders, forearms, abdomen, and both thighs was also noted. In addition, the sclerotic skin over the thighs was hyperpigmented and ichthyotic (Fig. 1). Hb was 11 g/dl, white cell count 3500/mm³, platelet count 80 000/mm³, and ESR 53 mm/h. LE cells and antinuclear factor were again present. As the cutaneous lesions clinically suggested scleroderma, a skin biopsy over the right thigh was done. The section showed mild hyperkeratosis and acanthosis. Rete ridges were present. Increased melanin was found in the basal layer. The collagen bundles were hyalinized with loss of fibrillar structure. There was mild perivascular lymphocytic infiltration. Sweat glands were few and atrophic. This histopathological picture was consistent with that of scleroderma (Fig. 2). Barium swallow did not show any defective oesophageal motility.

As this recurrence of SLE with coexisting scleroderma came on 3 weeks after ethosuximide was added, she was taken off the drug immediately. Prednisolone was again given. Fever, joint pain, and the maculopapular rash soon disappeared. ESR became normal, LE cells and the antinuclear factor were negative 3 months later. Prednisolone therapy was therefore discontinued. The dryness and pruritus of her skin improved with aqueous cream. 6 months later her skin was supple and normal in thickness, though some residual hyperpigmentation was still noted. For the next year she continued to receive phenobarbitone and diphenylhydantoin and remained well. There was no further recurrence of SLE or scleroderma.

Discussion

Though it is well known that some anticonvulsants can cause the lupus syndrome, it is important to be aware that epilepsy may be the initial manifestation of SLE (Haserick, 1955). However, we believe that our patient had idiopathic epilepsy since childhood and that SLE was induced by the anticonvulsant 14 years later. This is supported by the fact that all the features of SLE subsided soon after withdrawal of the anticonvulsant drugs. All these features of SLE were present again 6 months later when ethosuximide was readministered. Though diphenylhydantoin and troxidone have long been known to induce SLE, the first case of ethosuximide-induced SLE was reported by Livingston *et al.* (1968). There is no doubt that SLE in this patient was induced by etho-

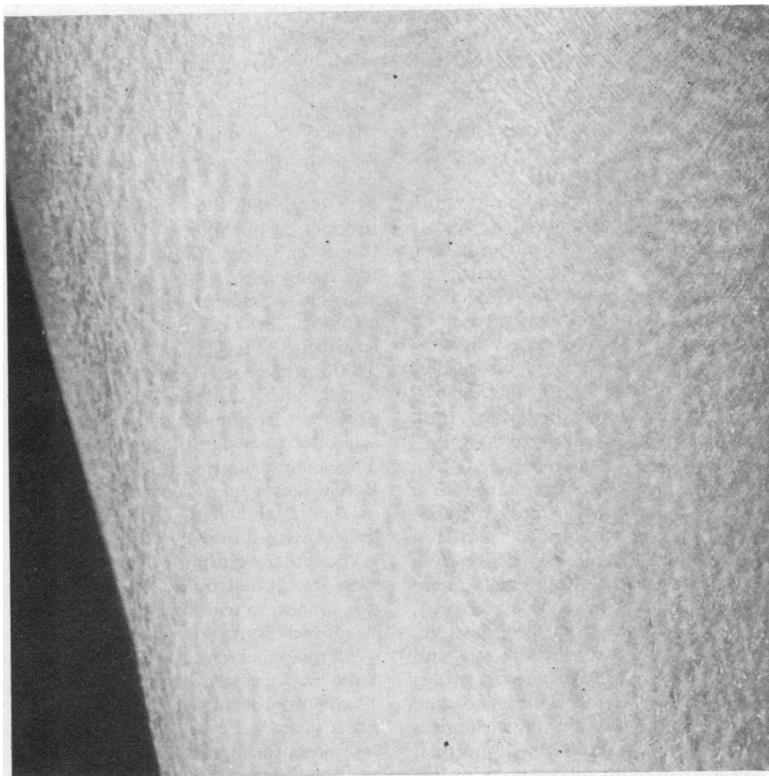


FIG. 1.—Sclerotic skin over right thigh with hyperpigmentation and ichthyosis.

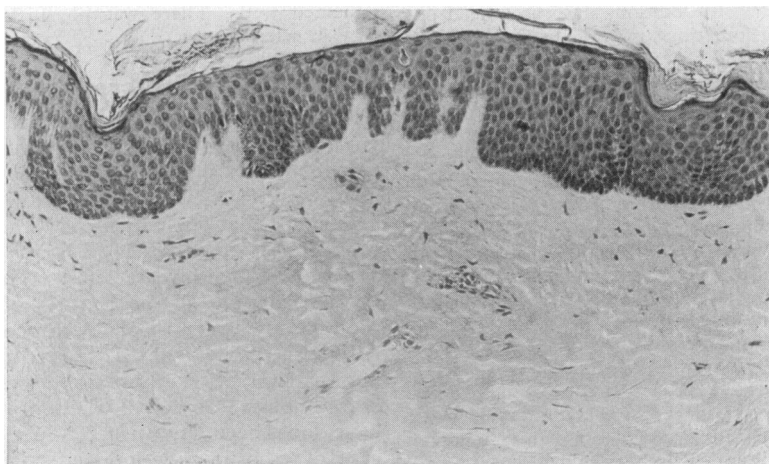


FIG. 2.—Skin biopsy showing the dermal collagen bundles to be homogeneous and hyalinized. Sweat glands and hair follicles are absent. (H. and E. $\times 80$).

suximide even though she was on four anticonvulsants, because symptoms and signs and the appearance of LE cells recurred after readministration of ethosuximide and subsided again when this was discontinued.

Though it was evident that she had drug-induced SLE during her first admission, features like stiffness of hand and tight and sclerotic skin were most unusual. Though these reminded us of scleroderma, there had been no published reports of cases of drug-induced scleroderma. However, during her second admission the cutaneous lesions were more florid and clinically suggestive of scleroderma. Skin biopsy was therefore done and the diagnosis confirmed. It is most interesting to note that coexisting SLE and scleroderma can occur after ethosuximide therapy and resolve after withdrawal of ethosuxinide.

Summary

Features of both systemic lupus erythematosus and scleroderma developed in a young Chinese girl while on multiple anticonvulsant therapy. These

were reversed after withdrawal of the drugs. Readministration of ethosuximide for control of epilepsy caused a relapse with predominant sclerodermatous features. These clinical signs again resolved after ethosuximide withdrawal.

We thank Professors O. T. Khoo and P. K. Wong, Department of Medicine, University of Singapore, for their permission to publish this case report.

REFERENCES

- Alarcón-Segovia, D. (1969). Drug-induced lupus syndromes. *Mayo Clinic Proceedings*, **44**, 664.
- Haserick, J. R. (1955). Modern concepts of systemic lupus erythematosus: a review of 126 cases. *Journal of Chronic Diseases*, **1**, 317.
- Livingston, S., Rodriguez, H., Greene, C. A., and Pauli, L. L. (1968). Systemic lupus erythematosus. Occurrence in association with ethosuximide therapy. *Journal of the American Medical Association*, **204**, 731.
- Winkelmann, R. K. (1971). Classification and pathogenesis of scleroderma. *Mayo Clinic Proceedings*, **46**, 83.

P. C. TEOH* and H. L. CHAN
Department of Medicine, University of Singapore, Singapore 3.

*Correspondence to Dr. P. C. Teoh.