

Sick sinus syndrome in children

OLIVE SCOTT, FERGUS J. MACARTNEY, and PHILIP B. DEVERALL

From the Department of Paediatric Cardiology, Killingbeck Hospital, Leeds

Scott, O., Macartney, F. J., and Deverall, P. B. (1976). *Archives of Disease in Childhood*, **51**, 100. **Sick sinus syndrome in children.** The ages of 6 male patients with the sick sinus syndrome ranged from 10–15 years when their symptoms began. At rest all had a heart rate of 60/min or less. Two had syncopal attacks which threatened life; 1 had only attacks of dizziness; the other 3 had no syncopal attacks but had recurrent attacks of supraventricular tachycardia ('brady-tachycardia syndrome') which were more resistant to drug therapy than is usual in childhood. They were not controlled or suppressed by digoxin when it was given. Substernal pain occurred in 2 patients who had syncope. In all patients the heart rate remained inappropriately slow after exercise and atropine. Cardiac pacemakers were used in the 2 patients with life-threatening syncope.

Any patient who has dizziness or syncopal attacks and an inappropriately slow heart rate should have electrocardiograms recorded at rest and after exercise to record the heart rate and to look for abnormal P-waves.

Dysfunction of the sinoatrial node has been increasingly recognized over the past few years. Most reported cases have been in adults and only a few in children. The term sick sinus syndrome, first used by Lown (1967), has been generally adopted. Ferrer (1973) uses it to describe clinical states in which there is a primary disorder of the normal pacemaker. The first manifestation is usually sinus bradycardia. This may progress to sinus arrest (when depolarization of the sinus node fails to occur) or to sinoatrial block (when the sinus node discharge is not propagated to the surrounding atrium). This results in cardiac arrest unless another pacemaker takes over. This new pacemaker is usually in the atrioventricular node, and the rhythm produced by it may be abnormally rapid or slow. If it is inappropriately slow, giddiness and syncope result. If it is rapid there is paroxysmal tachycardia. Some patients alternate between attacks of bradycardia and tachycardia. In the past sinus bradycardia has been regarded as a benign condition. It is important to differentiate physiological sinus bradycardia from the pathological variety in which there is an inappropriate response in heart rate to exercise and atropine.

Our recent experience suggests that the sick sinus syndrome may be a commoner cause of syncope, dizzy attacks, convulsions, and possibly

sudden death in childhood than has been previously recognized. An awareness of the condition may result in more cases being diagnosed. This paper describes 6 cases in which there was no demonstrable associated congenital heart lesion.

Case reports

Case 1. This was a 13-year-old boy who was first seen in November 1972. He had always been healthy and had led a normal athletic life until 6 months previously, when he had dizzy attacks on two occasions while playing football. Three months later he collapsed during a game of football and was noted to be dazed, blue, and frothing at the mouth. There was no history of injury. A month later after a game of football he was found breathless and cyanosed leaning against a wall and complaining of dizziness. He was helped home and did not fully recover for half an hour. One occasion while playing football he had had substernal pain and during the month before referral he had been excessively breathless on exertion. There was no history of similar episodes or sudden death in other members of his family. In particular there was no family history of deafness to suggest the Jervell-Lange-Nielson syndrome.

On examination he was a healthy looking boy, his height being on the 10th centile and his weight on the 25th. He had no cyanosis or dyspnoea. Brachial and femoral pulses were synchronous and of good volume, but the rate was only 56/min and an irregular irregularity was observed. The heart was of normal size and the activity of the ventricles was normal. There were no heart murmurs but on auscultation the irregular slow

rate and periods of asystole were observed. X-ray examination of the heart was normal. An electrocardiogram (ECG) confirmed the slow rate and showed periods of sinus arrest followed by slow junctional beats until sinus rhythm returned (Fig. 1). The boy had no symptoms during sinus arrest. The findings suggested that the dizzy attacks and syncope were probably associated with longer periods of sinus arrest, and he was admitted to hospital. A transvenous demand pacemaker was placed in the ventricle and his ECG was monitored. The following day he was exercised on a level treadmill at two miles per hour* with the pacemaker disconnected. Fig. 2 shows the slowing of the heart rate after exercise with a slow junctional rhythm. A permanent Cordis Stanicor ventricular demand pacemaker was inserted. This proved satisfactory, and examination at monthly intervals showed that the pacemaker was often active, there being alternating periods of sinus rhythm, sinus arrest, and pacing.

He remained symptom free for 10 months, when the pacemaker box eroded through the skin and had to be removed. Subsequently his heart rate fell to 48/min and there were alternating slow and rapid beats, the rapid rate being 86/min. After two minutes' exercise on the treadmill the heart rate increased to 140/min but after a further minute it fell to 56/min for a few seconds. The situation seemed unsatisfactory, but the child's father would not allow a further pacemaker to be inserted. Therefore atropine sulphate 0.5 mg was given twice daily by mouth. This increased the heart rate to between 72 and 80/min but periods of bradycardia still occurred, the rate falling to 50/min for three or four seconds and showing junctional beats. The dose of

atropine was increased to 0.5 mg 6-hourly and, although periods of slowing still occurred, sinus rhythm prevailed. An exercise test for three minutes showed that the rate did not increase to more than 80/min, and there was sinus arrest for two seconds followed by a slow rhythm of 60/min with junctional beats. Exercise at three miles per hour for three minutes increased the heart rate to 96/min but this was followed by sinus arrest for one second, then three slow sinus beats, and then junctional beats at 60/min for 14 seconds. After this sinus rhythm at 96/min returned. An increased dose of atropine resulted in dryness of the mouth and blurring of vision. The patient was therefore discharged from hospital on 0.5 mg six-hourly by mouth. He had no further attacks of syncope and was said to lead a normal life, but he did not play football with the same enthusiasm as before his symptoms began. He had only occasional dizziness. At rest his ECG often appeared normal with sinus rhythm at 72/min. Exercise one year after removal of the pacemaker showed sinus beats at 90/min followed by sinus arrest, then three slow sinus beats followed by slow junctional beats at 54/min for 15 seconds, after which sinus rhythm at 90/min returned (Fig. 3).

Case 2. This boy was aged 12 when referred to us in October 1973. He had always been healthy and athletic. He played in the school football team and was a keen swimmer. Eighteen months before referral he had been racing with friends when he felt 'things were going away from him' and he fell and banged his head. He had no sequelae and felt well. He remained well until 6 months later when he lost consciousness briefly while running up hill. The third episode occurred six months before referral. He was running in a relay race, collapsed after passing his baton, and was unconscious for a few seconds. The fourth and most

*Exercise tests were done on a level treadmill at two miles per hour for two minutes in all the patients unless otherwise stated.

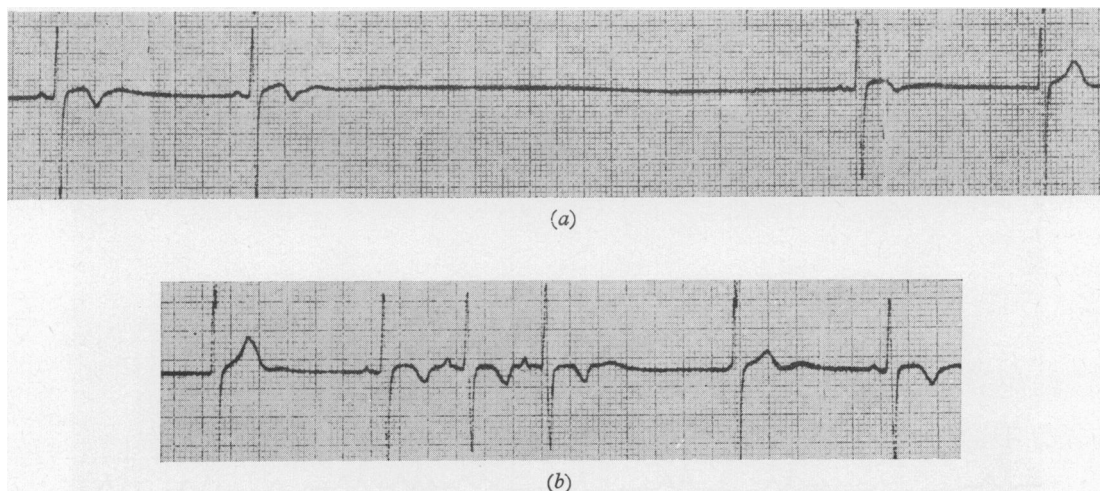


FIG. 1.—Case 1, ECG lead 2. (a) Two slow sinus beats followed by period of sinus arrest for three seconds followed by one sinus beat and one junctional beat; (b) is continuation of (a) and shows one junctional beat followed by three sinus beats, one junctional beat, and one sinus beat.

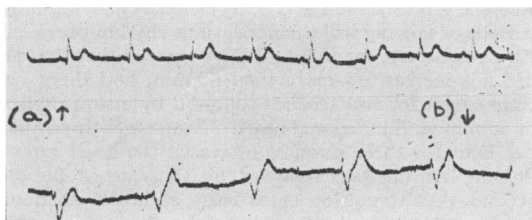


FIG. 2.—Case 1, ECG lead 2. (a) Sinus rhythm at rest; (b) slow junctional rhythm after exercising for two minutes.

alarming attack occurred 2 months before referral when he lost consciousness in the swimming pool. He was pulled to safety and quickly recovered. He had no recollection of the episode but remembered regaining consciousness on the side of the pool. Between attacks the boy had been very well and on many occasions exerted himself vigorously without loss of consciousness. His mother had ignored the attacks until the last one. He was referred in August 1973 to a paediatrician, who found no abnormality on physical examination. An ECG showed 'coronary sinus rhythm', there being inverted P-waves in standard leads 2 and 3. After exercise the P-waves became upright. The inverted P-waves were considered of no serious significance. A neurologist found no abnormality in the nervous system and recorded a normal electroencephalogram. He heard a short systolic murmur, however, and referred the boy to us.

On examination he was a healthy boy with no cyanosis or dyspnoea. The heart rate was 56/min and regular. The brachial and femoral pulses were synchronous and of good volume. The heart action was normal and there was a typical midsystolic innocent murmur. X-ray examination of his heart was normal. ECG confirmed the slow heart rate and during the recording the P-waves changed direction from being inverted to

being upright (Fig. 4). This with the slow rate raised the possibility of the sick sinus syndrome. An exercise test increased the heart rate to only 80/min and the P-waves remained upright throughout. At that time the child had been symptom-free for three months and the mother refused hospital admission for further investigation. He continued to be well and took part in all sports (including an 8-day skiing holiday) until March 1974, when he again became unconscious when swimming. He was given external cardiac massage and mouth-to-mouth resuscitation by the attendant, who thought he was dead. He was admitted to another hospital overnight and discharged when x-ray examination of the skull was normal and no abnormality was found on examination.

After readmission the heart rate was found to be 60/min but no abnormal P-waves were seen on ECG. An exercise test increased the heart rate to 80/min. Continuous monitoring of his ECG at rest was begun. This showed variation between sinus rhythm and junctional rhythm. The junctional rhythms varied in form, the P-waves at times being inverted, at times buried in the QRS complex. The rate was never more than 60/min. Periods of sinus arrest lasted only for two or three seconds. Atropine sulphate 0.2 mg was given intravenously without any increase in the heart rate; a further 0.2 mg 15 minutes later resulted in an increase of rate to 80/min with sinus rhythm maintained throughout. Twelve minutes later the patient was exercised and the rate increased to 100/min. After a further hour the ECG showed the same slow rate with varying sinus and junctional rhythms. Atropine sulphate 0.5 mg was then given intravenously and the heart rate increased to 100/min with sinus rhythm. After exercise the rate increased to 120/min, sinus rhythm being maintained throughout. Dryness of the mouth and blurring of vision occurred after the atropine intravenously but, since there seemed to be a favourable response, atropine by mouth was tried. At first 0.5 mg 6-hourly was given

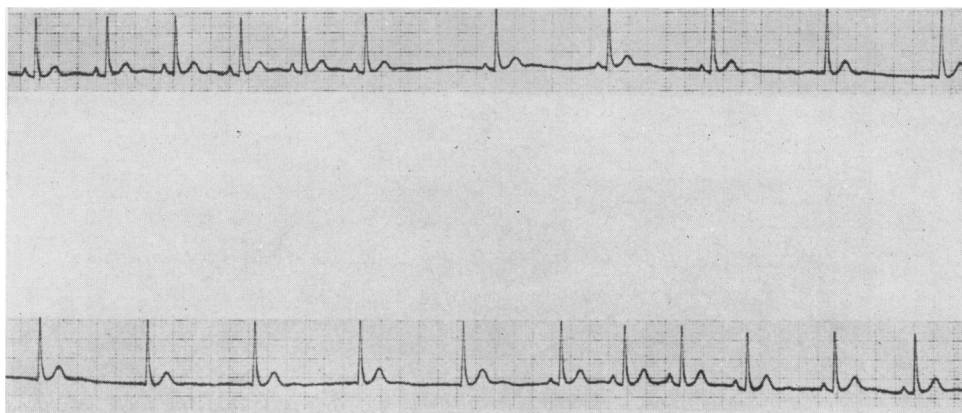


FIG. 3.—Case 1, ECG lead 2. Top, sinus rhythm at 90 beats/min, then sinus arrest, then three slow sinus beats followed by slow junctional rhythm. Bottom, junctional rhythm continuing at 54 beats/min followed by sinus rhythm at 90/min.

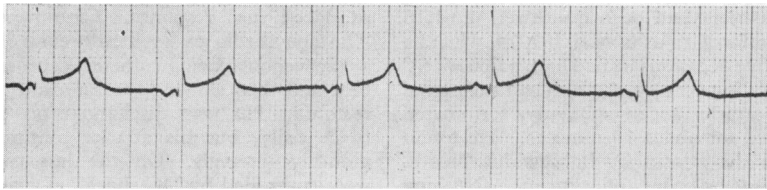


FIG. 4.—Case 2, ECG lead 2. Inverted P waves for three beats changing spontaneously to upright P waves for two beats.

but the heart rate did not increase at rest and rose only to 80/min after exercise. The dose was increased to 1.0 mg 6-hourly and the resting heart rate increased to 70/min but occasional nodal and coronary sinus beats were noted. On exercise the heart rate increased to 100/min. After 2 days of this regimen the resting pulse rate was 66/min, and the boy complained of blurred vision and inability to read. The varying P-waves had returned and after exercise the rate rose to 80/min with sinus rhythm.

Since the side effects of the atropine were intolerable the dose was decreased to 0.75 mg 6-hourly, but this did not influence the heart rate nor the frequency of abnormal P-waves and short periods of sinus arrest. It was therefore decided to discontinue atropine therapy. In view of his severe symptoms a Devices demand pacemaker was inserted in April 1974. After that he was free of symptoms and took part in all games and swimming.

Case 3. This patient was first referred to a paediatrician in July 1973 when 18 years old because of his small stature. He had had attacks of dizziness occasionally for three years but had never lost consciousness. The paediatrician referred him to us because his heart rate was unusually slow and irregular. The only abnormality we found on clinical examination of the heart was the slow rate of 56/min and an irregularity of a dropped beat every four beats. An ECG showed sinoatrial block resulting in a missing P-wave every fourth beat. The P-waves were of low voltage and rather broad. After exercise the heart rose to 72/min and sinus arrest occurred every sixth beat. After one minute of exercise at three miles per hour on a level treadmill the rate rose to 96/min and failure of atrial depolarization occurred every eighth or ninth beat. The patient led a quiet life and when last seen had not had any attacks of dizziness for a year. Since his symptoms were slight no treatment was given.

Case 4. This 10-year-old boy was well until Novem-

ber 1972 when he had sudden substernal pain when playing football and became very pale. He stopped exercising but the pain persisted for one hour and he felt his heart beating very quickly. His own doctor thought he had had a 'heart attack' and sent him to hospital for admission. When he reached the hospital the tachycardia and pain had subsided and he felt well. His ECG was then normal. Three further attacks occurred while playing football, and the tachycardia was always accompanied by substernal pain lasting for about one hour, when it stopped suddenly. He never lost consciousness.

When first seen by us in March 1973 he looked healthy and the only abnormality noted on clinical examination of his heart was that the rate (54/min) was unusually slow for a 10-year-old boy. An ECG confirmed the slow rate and showed broad, occasionally bifid P-waves. One episode of sinus arrest with nodal escape was recorded (Fig. 5). He was digitalized in the hope that this might suppress the attacks of tachycardia, and when seen 2 months later he had no further attacks. One month later he had an attack lasting for 2 hours after jumping from a (3.6 m) high wall. His mother then discontinued the digoxin and he did not take it again. He learned to stop his attacks by performing the Valsalva manoeuvre. After 15 months' follow-up he still had attacks every 6 to 8 weeks, usually associated with exercise. Subsequent ECGs at rest recorded three further episodes of sinus arrest with nodal escape. The P-waves remain unusually broad and rate has varied between 48 and 60/min. After exercising on a treadmill at three miles per hour for ten minutes the heart rate never rose above 84/min but sinus rhythm was maintained throughout and no attacks of tachycardia could be provoked.

This patient undoubtedly had periods of sinus arrest but the absence of syncope suggests that they were not prolonged. His symptoms were due to the paroxysmal tachycardia, which is often associated with the sick sinus syndrome.

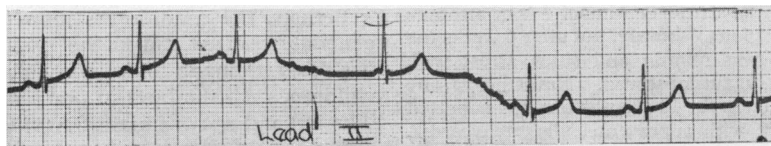


FIG. 5.—Case 2, ECG lead 2. Three sinus beats followed by sinus arrest during which nodal escape beat occurs, then sinus rhythm returns.

Case 5. This patient had been quite well until 18 months before his referral to us in March 1974, when he was aged 11. On five occasions he had had 'palpitations' and felt his heart beating very quickly and had substernal discomfort. The attacks began suddenly, terminated suddenly, and lasted for about 10 minutes. He found that he could end the attacks by holding his breath. He had never had episodes of syncope. Nothing abnormal was found on clinical examination except a heart rate of 56/min, which was very slow for an 11-year-old boy attending hospital. The only ECG abnormality was that the P-waves were rather broad and low. Probably this was another case of the sick sinus syndrome associated with the tachycardia—the so-called brady-tachy-syndrome—but this has not been proved. Unless the examiner is lucky enough to record an episode of sinus arrest these cases may be overlooked.

Case 6. This 11-year-old boy was admitted to hospital in March 1969 with a history that he had been quite well until three days previously, when he noticed his heart beating very quickly and then became breathless and developed some para-umbilical pain. He had vomited all his meals for the past 24 hours. He was slightly dyspnoeic, pale, shocked, and slightly cyanotic. His pulse rate was 240/min and he had congestive heart failure. An ECG showed supraventricular tachycardia. There was no response to carotid sinus or eyeball pressure. He was therefore digitalized and given diuretics, but the tachycardia persisted. Neostigmine and procainamide were given without any response. The digoxin was therefore stopped and a DC shock was given, which resulted in sinus rhythm. He reverted to supraventricular tachycardia 48 hours later but again responded to DC shock. He was discharged on digoxin, quinidine, and chlor-diazepoxide. He had no further attacks until March 1970, when again the attack was controlled by DC shock. Between attacks it was noted that his pulse rate was 48/min, unusually slow, and an episode of sinus arrest with nodal escape was recorded on an ECG. All medication was stopped, and he was admitted to hospital for continuous ECG monitoring in the hope that the onset of a tachycardia might be recorded. This was not recorded, but since the bradycardia persisted and further episodes of sinus arrest with nodal escape were recorded he was given 0.5 mg atropine sulphate by mouth six-hourly in July 1971. This did not increase the heart rate to more than 64/min and he still had episodes of tachycardia. After four weeks of treatment with atropine his resting pulse rate was 56/min. Propranolol, 10 mg three times a day, was added to the treatment but the bradycardia continued. The atropine was increased to 0.75 mg 6-hourly, but after 6 weeks the resting heart rate was 50/min and sinus arrest with nodal escape was again observed. Nevertheless, he remained free of attacks for 14 months but was admitted again in June 1972 with supraventricular tachycardia. On this occasion the tachycardia could not be controlled by any vagal stimulation or by procainamide, lignocaine, or intravenous propranolol. Intravenous phenytoin

produced no response. Cardioversion also failed. The tachycardia was eventually controlled by introducing a transvenous pacing catheter, capturing the ventricular beat and then slowing the rate until sinus rhythm was restored. He was discharged on practolol 100 mg twice daily, but his attacks continued at about six-monthly intervals. On the last two occasions they were controlled by DC shock. During the 6 years this boy has been under our care he has never had episodes of syncope, but one year ago he complained that he could feel his heart beating very slowly and forcefully at times.

Again the combination of tachycardia and bradycardia and periods of sinus arrest in this case point to a diagnosis of sick sinus syndrome.

Discussion

There have been many recent reports of the sick sinus syndrome (Ferrer, 1973; Rubenstein *et al.*, 1972; Kaplan *et al.*, 1973; Mandel *et al.*, 1972; Eraut and Shaw, 1971; Lloyd-Mostyn, Kidner, and Orman, 1973). It is often referred to as the brady-tachycardia syndrome because of the alternating slow and rapid rates in some cases. There has been only one report, however, of the condition in childhood—in a child aged 13 years (Eraut and Shaw, 1971)—though Nugent *et al.* (1974) described the syndrome in association with congenital heart defects. The aetiology of the condition is unknown. There was no history of similar symptoms in the relatives of our patients, nor was there any history of illness in the patients to suggest recent myocarditis or other infection. Viral studies were negative. The pathology of the condition is not defined. James, Froggatt, and Marshall (1967) describe the cases of two young male athletes who died suddenly during exertion. One was known to have had a slow, irregular pulse rate of 42/min which increased to 70/min after exercise. Unfortunately no ECG was recorded in either patient but at necropsy the sinus node artery in each case showed intimal proliferation and medial hyperplasia. This occluded the artery in one patient and caused severe obstruction in the other. The sinus node artery is an end artery, and it was concluded that these two patients had disordered function of the sinoatrial node.

Perhaps the condition is more common than is generally realized and in the past the bradycardia has been thought to be physiological in athletic children. All the boys in our series were athletic. The sex and age of onset of symptoms in our cases and those of James *et al.* (1967) were similar—between 10 and 15 years. The syncopal attacks occurred on exertion in both series. We have

not found any references to the syndrome in young girls.

Patients with the sick syndrome may first be referred to a neurologist or a paediatrician. Any patient who has attacks of syncope, dizziness, or tachycardia should have their resting pulse rate measured, and if this is 60/min or less an ECG should be recorded. It is not uncommon for the resting ECG to show slow sinus rhythm within normal limits for long periods, so records should be made for at least one minute and repeated at intervals. Recordings after exercise should also be made. The following abnormalities should be looked for. If they are present in a patient who has bradycardia with symptoms the sick sinus syndrome is the likely diagnosis. (1) Low voltage broad P-waves which may at times be bifid. (2) P-waves which alter shape and direction during the recording. (3) Periods of sinus arrest often followed by nodal escape beats. (4) Failure to increase the heart rate more than 30% after exercise on a treadmill at two miles per hour for two minutes. (5) Onset of an abnormal rhythm which may be slow after exercise. (6) Failure to increase the heart rate by more than 30% after giving atropine 0.01 mg/kg intravenously.

We have found in children, as in adults, that drugs do not much improve the bradycardia without causing unpleasant side effects (Nugent *et al.*, 1974; Kaplan *et al.*, 1973; Ferrer, 1973). Controlling the attacks of tachycardias is more difficult than controlling supraventricular tachycardia in childhood unassociated with the sick sinus syndrome. In particular, digoxin did not stop or suppress the tachycardia in the two patients to whom it was given, and in one patient (Case 6) it was resistant to all accepted drugs. Cardioversion carries a risk in this condition. (Lown, 1967).

In patients with syncopal attacks there is no way of knowing whether or when another attack may occur, which could be fatal. The only way of preventing sudden death in these *symptomatic* patients is to insert a cardiac pacemaker. We remain very anxious about the patient whose pacemaker was removed because of infection and who still has episodes of sinus arrest. Pacemakers continue to improve. They last longer, are becoming smaller, and will in the future be less troublesome to the patients. Pacemakers may also be used to control tachycardia in patients in whom the attacks cause serious interference with life and are resistant to drug therapy.

We thank Professor R. W. Smithells, who referred Case 1, and Dr. D. Sumner who referred Case 2.

REFERENCES

- Eraut, D., and Shaw, D. B. (1971). Sinus bradycardia. *British Heart Journal*, **33**, 742.
- Ferrer, M. I. (1973). The sick sinus syndrome. *Circulation*, **47**, 635.
- James, T. N., Froggatt, P., and Marshall, T. K. (1967). Sudden death in young athletes. *Annals of Internal Medicine*, **67**, 1013.
- Kaplan, B. M., Langendorf, R., Lev, M., and Pick, A. (1973). Tachycardia-bradycardia syndrome (so-called sick sinus syndrome). *American Journal of Cardiology*, **31**, 497.
- Lloyd-Mostyn, R. H., Kidner, P. H., and Oram, S. (1973). Sinus-atrial disorder including the brady-tachycardia syndrome. *Quarterly Journal of Medicine*, **42**, 41.
- Lown, B. (1967). Electrical reversion of cardiac arrhythmias. *British Heart Journal*, **29**, 469.
- Mandel, W. J., Hayakawa, H., Allen, H. N., Danzig, R., and Kerraier, A. I. (1972). Assessment of sinus node function in patients with the sick sinus syndrome. *Circulation*, **46**, 761.
- Nugent, E. W., Varghese, P. J., Pieroni, D. R., and Rowe, R. D. (1974). Sluggish sinus node syndrome as part of congenital heart disease. *American Journal of Cardiology*, **33**, 160.
- Rubenstein, J. J., Schulman, C. L., Yurchak, P. M., and DeSanctis, R. W. (1972). Clinical spectrum of the sick sinus syndrome. *Circulation*, **46**, 5.

Correspondence to Dr. O. Scott, Leeds Regional Thoracic Surgical Centre, Killingbeck Hospital, York Road, Leeds LS14 6UQ.