

Cows' milk allergy in the syndrome of thrombocytopenia with absent radius

M. F. WHITFIELD and D. G. D. BARR

From the Royal Hospital for Sick Children, and Medical Paediatric Unit, Western General Hospital, Edinburgh

Whitfield, M. F., and Barr, D. G. D. (1976). *Archives of Disease in Childhood*, **51**, 337. **Cows' milk allergy in the syndrome of thrombocytopenia with absent radius.** A girl with the syndrome of thrombocytopenia with absent radius had severe diarrhoea and dehydration relieved by withdrawal of cows' milk and aggravated by its reintroduction on three occasions. Deterioration in gastrointestinal symptoms was associated with haematological relapse with thrombocytopenia, leucocytosis, anaemia, and eosinophilia. There appeared to be a correlation between milk exposure and the haematological and gastrointestinal disturbances. Supporting evidence from published reports for such a correlation is reviewed.

Cows' milk protein intolerance may be a factor in precipitating haematological relapse in susceptible infants with radius aplasia. Early withdrawal of cow's milk protein should be tried in thrombocytopenia with absent radius, especially in cases with prominent gastrointestinal upset.

Thrombocytopenia with absent radius (TAR) or 'radius-platelet hypoplasia' is a recognized syndrome, reviewed by Hall *et al.* (1969), in which radial aplasia and frequently other skeletal defects occur in association with hypoplastic thrombocytopenia. Additional haematological features include a leukaemoid peripheral blood picture, eosinophilia, and anaemia. Marrow examination usually shows reduction or absence of mature megakaryocytes showing signs of active platelet production, contrasting with a general marrow hyperplasia affecting other cell lines. A proportion of cases have severe gastrointestinal symptoms with dehydration and gastrointestinal blood loss which, in the presence of thrombocytopenic crises, are responsible for an appreciable mortality within the first few months of life. Those surviving infancy have a good prognosis and show marked haematological improvement.

Hall *et al.* (1969) reviewed the world literature and found 27 cases in 1969 and added 13 new cases.

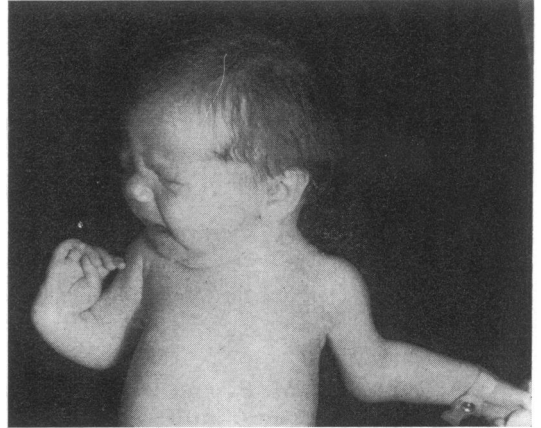We have found reports of a further 10 cases since then (Masson *et al.*, 1971; Day and Holmsen, 1972; Juif, Stoll, and Korn, 1972; Kucera, 1972; Stoll *et al.*, 1972; Omenn *et al.*, 1973; Carroll and Louis, 1974). We record a further case of TAR who showed marked gastrointestinal disturbance with clinical evidence of cows' milk allergy, and in whom there appeared to be a direct correlation between cows' milk exposure, gastrointestinal upset, and the haematological manifestations of the syndrome.

Case report

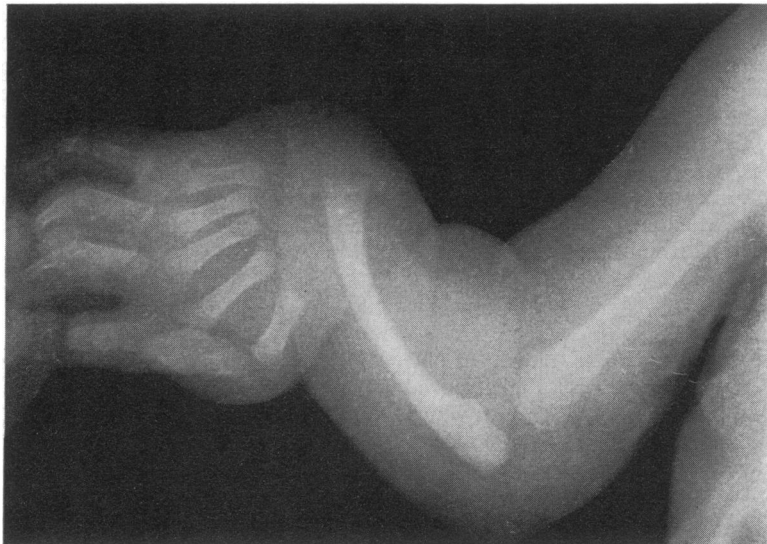A girl was born at term by vertex delivery with a birth-weight of 3.28 kg, being the second child of Caucasian parents. Pregnancy had been complicated only by hydramnios. The child had an obvious forearm deformity but was otherwise clinically normal. There was a radial club hand on the right side with radial aplasia, whereas the left forearm was normal apart from some limitation of movement at the elbow and radio-ulnar joints (Fig. 1 a, b). There was no malformation of the upper arms and shoulder girdle or of the pelvis and lower limbs. The bones and soft tissues of both hands were normal. There was no family history of

any haematological, skeletal, or allergic disorder, both parents and the one elder sib being entirely well.

She gained weight satisfactorily on artificial feeding during the first week of life but thereafter developed profuse diarrhoea and vomiting, rapidly leading to dehydration requiring withdrawal of milk feeds and administration of intravenous fluids. The stools contained mucus and blood, but repeated stool culture showed no gastrointestinal pathogens. The child deteriorated further with the passage of a number of bowel casts which had the histological appearance of necrotic segments of intact intestine. During this time there was a progressive fall in haemoglobin from 16.2 to 9.0 g/dl, accompanied by a rise in leucocyte count to $53\,100/\text{mm}^3$ (neutrophils 49%, lymphocytes 37%, monocytes 12%, eosinophils 1%) and a marked left-shift in the polymorph series with, at times, 1700 myelocytes/ mm^3 on peripheral blood film. The leucocytosis was associated with large numbers of normoblasts



(a)



(b)

FIG. 1.—(a) Forearm deformity. (b) x-ray of right arm.

in peripheral blood, numbering 8 per 100 white blood cells on one occasion. The platelet count was low at $25\,000/\text{mm}^3$ (Fig. 2). A tibial marrow specimen at this time showed granulocytic hyperplasia with myelocyte and metamyelocyte predominance. The normoblasts were few and scattered, the myeloid/erythroid ratio being 26:1. The megakaryocytes were markedly reduced in number and appeared immature and inactive.

After treatment with parenteral fluids and blood transfusion and withdrawal of oral feeding the vomiting settled and the frequency, fluidity, and blood staining of the stools diminished, with a consequent rapid improvement in general condition. Reintroduction of oral feeds with a dried cows' milk formula 5 days later

was accompanied, however, by haematological and gastrointestinal relapse with a further fall in platelet count to 16 000, a further fall in haemoglobin to 7 g/dl and a further rise in leucocyte count. The stools became more frequent and fluid, and there was a further loss in weight to 2.7 kg. By day 40 of life clinical and radiological signs of acute intestinal obstruction had developed. Oral feeding was again discontinued and further resuscitation with blood and intravenous fluids was required before the child was fit for laparotomy. No cause of obstruction could be found, but on account of equivocal narrowing of the distal colon, transverse colostomy was carried out and the colon was biopsied. This showed histological flattening of the colonic mucosa

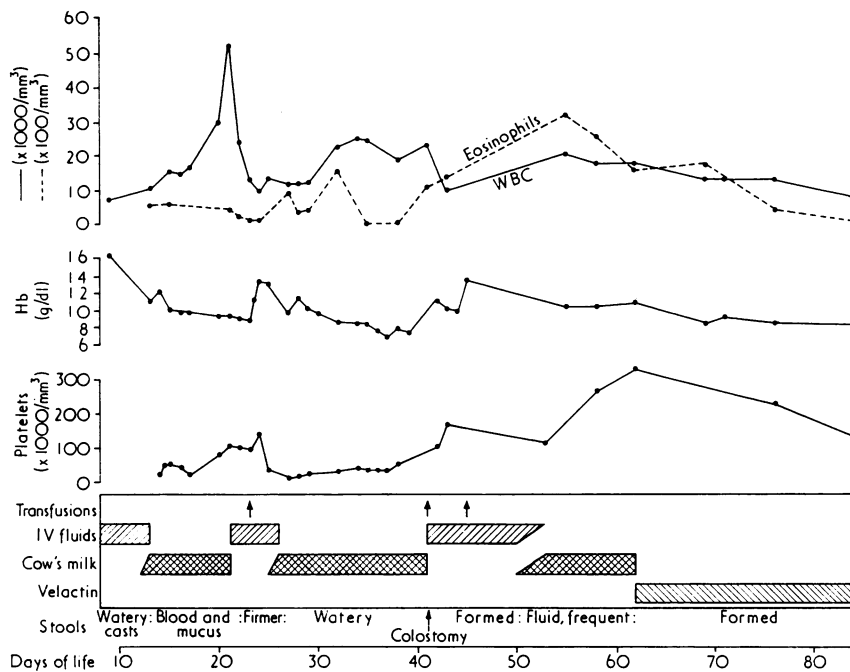


FIG. 2.—Haematological and gastrointestinal changes during the first 84 days of life

with an infiltrate of small numbers of macrophages, plasma cells, and eosinophils. Ganglion cells were clearly identified.

Postoperatively the colostomy functioned satisfactorily and oral fluids were gradually reintroduced. Reintroduction of milk feeding, however, with the same dried cows' milk formula produced an increase in the frequency, volume, and fluidity of the stools and an eosinophilia in peripheral blood of 3200/mm³. On day 62 of life all milk in the diet was replaced with Velactin, a soya bean milk substitute, with dramatic and immediate normalization of the stools and considerable general clinical improvement. Thereafter the white cell and eosinophil counts gradually returned to normal and the haemoglobin level and platelet count were maintained without further transfusion. During the following 3 months the baby remained in haematological remission and gained weight on a milk-free diet. She had two transient gastrointestinal upsets during this period but these were not associated with any haematological relapse or blood loss in the stools. Hb level varied between 8 and 12.5 g/dl, white cell count 5000–15 000/mm³, eosinophils 0–500/mm³, platelets 100 000–275 000/mm³, reticulocyte count 1–7%. Glucose, lactose, and maltose tolerance tests were all normal and induced no gastrointestinal or haematological relapse. Repeated tests for milk antibodies in the child's serum were negative and immunodiffusion tests against casein, lactalbumin, and whole milk were normal.

At 25 weeks of age the colostomy was closed and the baby then developed vomiting associated with the x-ray appearances of duodenal ileus. The symptoms settled with nursing in an upright posture, but not before there had been a weight loss of 700 g. In order to improve the child's nutrition a casein-hydrolysate milk substitute (Nutramigen) was introduced into the diet gradually from 27½ weeks (193 days) while Velactin was continued. There was no gastrointestinal upset but a dramatic change in haematological parameters (Fig. 3). Hb fell from 12 g/dl to 8 g/dl in 5 days, the platelet count fell to 40 000, and there was a moderate increase in eosinophils which showed abnormally large granules. There was also a striking reticulocytosis rising to 18% with accompanying increase in normoblasts in the peripheral blood. Although the amount of Nutramigen in the diet was gradually increased, these parameters returned to normal over the next 40 days and the baby rapidly gained weight. Just after Nutramigen was introduced, the direct and indirect Coombs's tests were shown to be negative, osmotic fragility and glucose-6-phosphate-dehydrogenase levels in the erythrocytes were normal, no acanthocytes were seen on blood smear, and no anti-platelet antibodies could be shown in the patient's serum.

The baby was discharged from hospital on Velactin and Nutramigen and continued to thrive. Cows' milk was gradually introduced into the diet between 9 and 14 months of age without ill effect and she was last seen at the age of 16 months making normal growth and

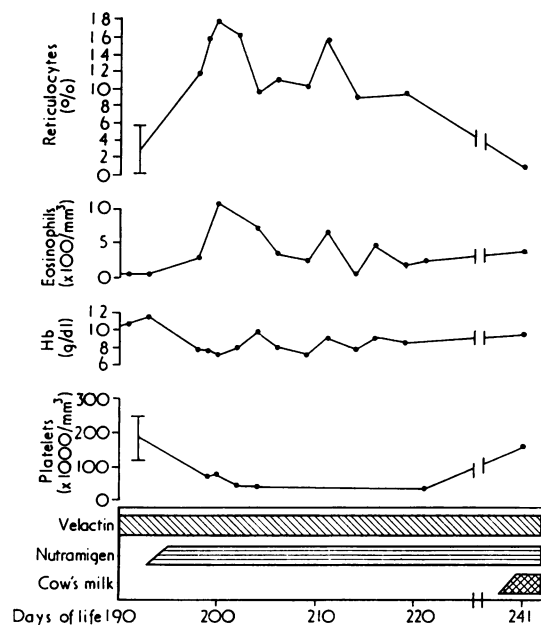


FIG. 3.—Haematological changes on exposure to Nutramigen (casein-hydrolysate milk substitute).

developmental progress with a stable and essentially normal blood picture (Hb 12.2 g/dl, reticulocytes 1.4%, WBC 10 400/mm³, eosinophils 100/mm³, platelets 101 000/mm³).

Discussion

This child has the accepted criteria for a diagnosis of TAR as outlined by Hall *et al.* (1969). The case is of interest in that the radial aplasia is unilateral, and is of significance because of the apparent implication of milk allergy as a precipitating cause of the gastrointestinal and haematological features.

Unilateral radial aplasia. Only one other case of TAR with unilateral radial aplasia is at present recorded (Nilsson and Lundholm, 1960, Case 2). This child had unilateral radial aplasia and rudimentary thumb on the same forearm and had thrombocytopenia during the first 3 months of life, but remained well. It has been suggested (Omenn *et al.*, 1973) that the presence of one recognizable normal fetal radius on radiographic examination of a 16-week fetus is strong evidence that the child would not subsequently be affected by TAR. Such a conclusion seems insecure in view of the occasional case with unilateral radial aplasia.

Evidence of milk allergy in this case. A diagnosis of cows' milk allergy is reached on clinical grounds with supportive laboratory evidence. The diagnostic criteria of Goldman *et al.* (1963) are accepted as proof of a firm diagnosis of cows' milk allergy (Freier and Kletter, 1972; Gerrard *et al.*, 1967), though Walker-Smith (1975) has considered these criteria to be too rigid. In our case elimination of dried cows' milk formula from the diet on three occasions, because of worsening gastrointestinal symptoms while on cows' milk feeds, at 21 days, 41 days, and 62 days of life, resulted in rapid and sustained reduction in gastrointestinal symptoms within 48 hours on each occasion (Fig. 2). Introduction of cows' milk into the diet at 13 days, 26 days, and 52 days produced a rapid and dramatic deterioration in feeding, and diarrhoea, at times blood-stained. The exclusion of cow's milk and its replacement by a soya-based milk substitute (Velactin) at 62 days produced a considerable improvement in the child's general condition with normalization of the stools, improvement in feeding, and steady weight gain. Goldman's criteria for a diagnosis of cows' milk allergy, therefore, appear to have been met.

The following observations provide additional support for a diagnosis of cows' milk allergy. Nutramigen, a casein-hydrolysate milk substitute, is tolerated by the majority of children with cows' milk allergy without gastrointestinal relapse, though it retains the antigenic characters of cows' milk but in reduced amount (Freier *et al.*, 1969). Nutramigen produced no gastrointestinal relapse in our patient but did induce a temporary haematological upset (see below). Both gastrointestinal blood loss and a clinical pattern of apparent intestinal obstruction are recognized complications of cows' milk allergy (Freier and Kletter, 1972). The histological appearances of the colonic biopsy taken after 15 days of cows' milk feeding agree with the reversible pattern described by Gryboski, Burkle, and Hillman, 1966) and Silver and Douglas (1968) in milk allergic subjects.

Disaccharide tolerance tests carried out while on the milk free diet were normal and provoked no gastrointestinal relapse, excluding primary and secondary intestinal disaccharidase deficiency. The lack of demonstrable milk antibodies and normal immunodiffusion tests against milk proteins neither support nor refute a diagnosis of cows' milk allergy (Stanfield, 1959; Gerrard *et al.*, 1967; Freier and Kletter, 1972).

There is therefore good clinical and supportive evidence to suggest that cows' milk allergy participated to a significant degree in the causation of this girl's gastrointestinal relapses.

Correlation between cows' milk exposure and haematological relapse. The introduction of cows' milk into the diet at 13 days and 26 days was associated with thrombocytopenia, leucocytosis, and progressive anaemia in addition to gastrointestinal relapse (Fig. 2). At 53 days, reintroduction of milk was associated with leucocytosis and a striking eosinophilia as well as gastrointestinal relapse, though no significant fall in the platelet count was detected. Gastrointestinal remission and sustained normal leucocyte, eosinophil, and platelet counts were only possible after complete exclusion of cows' milk and its replacement by Velactin for a period of several weeks.

Challenge with Nutramigen at 193 days (Fig. 3) produced a severe haematological upset with thrombocytopenia, eosinophilia, anaemia, and reticulocytosis despite continuing gastrointestinal remission. The haematological changes settled spontaneously despite continuation of Nutramigen in the diet, and a gradual reintroduction of cows' milk was possible without either haematological or gastrointestinal disturbance between 9 and 14 months of life.

The evidence is therefore strongly suggestive in this case of a correlation between episodes of cows' milk exposure, and haematological relapse during the period of milk sensitivity throughout the first 7 months of life.

Published cases in which milk allergy and TAR co-exist. In 3 cases of cows' milk allergy reviewed by Hall *et al.* (1969; Cases 5, 7, 12) milk elimination induced gastrointestinal remission with reduction in bleeding tendency. In Case 12 milk exposure induced gastrointestinal bleeding on three challenges. Case 7 had lactosuria and an abnormal lactose tolerance test compatible with a diagnosis of 'hereditary infantile lactose intolerance with lactosuria' (Holzel, 1965). This situation has, however, been described in a milk allergic subject by McCann, Gold, and Schwarz (1966). Lactosuria and secondary lactase deficiency are common features of cows' milk allergy (Kuitunen *et al.*, 1975; Liu *et al.*, 1968; Gerrard *et al.*, 1973; Freier and Kletter (1970). Case 7 died of an intracranial haemorrhage with a platelet count of 5000/mm³ at the age of 4½ months apparently despite being on a milk-free diet. In all 3 cases the evidence is strongly suggestive of cows' milk allergy and of a correlation between dietary milk exposure and haematological relapse, though, on the information provided, a strict direct correlation cannot be made in any of the 3 cases. Our case, though, appears to present such a correlation.

Circumstantial evidence for a link between TAR and cows' milk allergy. Review of the 40 cases of TAR in the world literature at present in which clinical details are fully reported shows 16 cases, in addition to ours, which share a pattern of early gastrointestinal crises within the first few weeks of life, associated with extreme thrombocytopenia, a leukaemoid reaction, and usually eosinophilia to a marked degree (Bayrakci and Walsh, 1963; Bernheim, Monnet, and Germain, 1963, Case 3; Claassen, Becker, and Pratt, 1964; Caldera *et al.*, 1965; Hall *et al.*, 1969, Cases 3-5, 7-10, 12, 13; Masson *et al.*, 1971; Juif *et al.*, 1972, Cases 1, 2, and our case). The eosinophilia is found in 14 of the 17 cases (82.5%) but occurs in only 7 out of the 23 cases in which severe gastrointestinal symptoms are not prominent (30.2%). There is a high mortality during the first 6 months of life (6 out of 17 died), but survival, particularly into the second half of the first year and into the second year of life, is associated with amelioration of both the gastrointestinal symptoms and haematological abnormality. There are many similarities in clinical course and laboratory data between these 17 cases and the severe gastrointestinal type of cows' milk allergy, as illustrated in the Table. Full details of gastrointestinal investigation are not available for the majority of the 17 cases. In spite of the apparent similarity of the two conditions none of the reviews of cows' milk allergy make any reference to TAR (Clein, 1954; Dees, 1959; Stanfield, 1959; Collins-Williams, 1962; Heiner, Wilson, and Lahey, 1964; Freier and Kletter, 1970, 1972; Gerrard *et al.*, 1973; Walker-Smith, 1975). This may be explained by the relative rarity of TAR cases, only a proportion of which may show recognizable features of cows' milk allergy. Death within the first few months of life due to dehydration and malnutrition has been described where a diagnosis of cows' milk allergy is missed or delayed (Freier and Kletter, 1972). A case of TAR in a breast-fed infant (Tönz, Keller, and Cottier, 1960) had a clinical course similar to the 17 cases described above, but the feeding history is incomplete.

Unresolved problems in TAR. The significance of the pancreatic changes in 2 cases and jejunal histology findings in one of these described by Juif *et al.* (1972) remains unclear. The jejunal histology in this case appears to differ from the partial or subtotal villous atrophy described by Kuitunen *et al.* (1975) and Fontaine and Navarro (1975) in cows' milk allergic subjects. No evidence of pancreatic insufficiency was found in a case of TAR investigated by Masson *et al.* (1971).

TABLE

Similarities between severe gastrointestinal cows' milk allergy and TAR with severe gastrointestinal symptomatology

	17 cases of TAR with severe gastrointestinal symptomatology	Gastrointestinal cows' milk allergy
<i>Natural history</i>		
Onset	87% within 1st month of life	75% within 1st month of life (Gerrard <i>et al.</i> , 1967)
Progress	Haematological and gastrointestinal improvement after the first few months; substantial improvement occurring in 47% by age 1 year	Waning of sensitivity to cows' milk between 3 months (Stanfield, 1959) and 3½ years (Gerrard, 1967); 80% of Clein's series (1958) could tolerate cows' milk by age 1 year
<i>Symptomatology</i>		
Vomiting and severe feeding difficulties	82%	Frequently occurring features of cows' milk allergy (Clein, 1954; Stanfield, 1959; Collins-Williams, 1962; Freier and Kletter, 1970, 1972)
Diarrhoea	82%	
Gastrointestinal bleeding	65%	
Dehydration and collapse	47%	
Failure to thrive (specifically mentioned)	35%	
Laparotomy for intestinal pseudo-obstruction	18%	Recognized complications of acute cows' milk allergy (Freier and Kletter, 1972; Kuitunen <i>et al.</i> , 1975)
Clinical improvement on cows' milk-free diet	5 out of 17 tried on diet-substantial improvement in 4, transient improvement in 1	100%
<i>Laboratory data</i>		
Anaemia	82%	Common feature of cows' milk allergy (Freier and Kletter, 1970; Wilson <i>et al.</i> , 1964)
Eosinophilia in peripheral blood Inflammatory cell and eosinophilic infiltrate in colonic mucosa	82% One case (present report)	Reversible changes found in cows' milk allergy (Silver and Douglas, 1968; Gryboski <i>et al.</i> , 1966; Gryboski, 1967)

As noted by Tönz *et al.* (1960) the degree and rapidity of progression of the anaemia appears to be out of proportion to the degree of haemorrhage in some cases. This is true of our case and though a haemolytic element has been suggested in some cases no uniform extra- or intracorpuscular or vascular cause has ever been delineated (Hall *et al.*, 1969). In addition to thrombocytopenia, it is now evident that at least in some cases there is an aggregation defect of the existing platelets in peripheral blood (Sultan *et al.*, 1972, 1973; Day and Holmsen, 1972).

The genetics of the syndrome are unclear. There appears to be a predilection of the syndrome for trisomy-18 (Stoll *et al.*, 1972). Radial aplasia is not an uncommon malformation and is associated with a wide range of other congenital abnormalities, and only rarely with congenital amegakaryocytic thrombocytopenia. Only 2 of 53 patients with radial aplasia collected retrospectively by Carroll and Louis (1974) had TAR.

Defects of the radial side of the forearm are also seen in Fanconi's familial constitutional pan-myelocytopeny (Fanconi, 1967) and in the syndrome of erythroid hypoplasia with triphalangeal thumbs (Aase and Smith, 1969). TAR, however, as noted by Hall *et al.* (1969) is perhaps not so rare as has been previously suggested by the number of published cases.

Conclusion

We have added to the published reports a case of TAR with a correlation between the early gastrointestinal crises, haematological relapse, and milk allergy. 3 other cases with rather less conclusive evidence of this correlation have already been documented. There are many reported cases with a similar clinical evolution, some of whom have died, in whom the possibility of cows' milk allergy does not appear to have been considered. We would advocate a trial of cows' milk exclusion in any future cases of TAR showing the progressive downhill

phase in early infancy, as survival of this period is associated with a relatively good prognosis.

We are grateful to Drs. W. Schutt and H. Simpson who were involved in the early management of this infant and to Mrs M. Whitfield for help with illustrations and Mrs G. Mckenzie for secretarial assistance.

REFERENCES

- Aase, J., and Smith, D. (1969). Congenital anemia with triphalangeal thumbs: a new syndrome. *Journal of Pediatrics*, **74**, 471.
- Bayrakti, C., and Walsh, J. R. (1963). Amegakaryocytic thrombocytopenia with bilateral absence of radii. *Postgraduate Medicine*, **33**, 401.
- Bernheim, M., Monnet, P., and Germain, D. (1963). La thrombopénie hypoplastique amégakaryocytaire congénitale (étude de trois nouveaux cas et revue de la littérature). *Pédiatrie*, **18**, 367.
- Caldera, R., Lambertz, J., Badoual, J., Pizzo, P., and Rossier, A. (1965). Thrombopénie amégakaryocytaire congénitale. *Le Médecine Infantile*, **7**, 513.
- Carroll, R. E., and Louis, D. S. (1974). Abnormalities associated with radial dysplasia. *Journal of Pediatrics*, **84**, 409.
- Claassen, S., Becker, W. F., and Pratt, P. T. (1964). Congenital thrombocytopenia with aplasia of the radii. *Nebraska State Medical Journal*, **49**, 419.
- Clein, N. W. (1954). Cow's milk allergy in infants. *Pediatric Clinics of North America*, **1**, 949.
- Clein, N. W. (1958). Cow's milk allergy in infants and children. *International Archives of Allergy and Applied Immunology*, **13**, 245.
- Collins-Williams, C. (1962). Cow's milk allergy in infants and children. *International Archives of Allergy and Applied Immunology*, **20**, 38.
- Day, H. J., and Holmsen, H. (1972). Platelet adenine nucleotide, 'Storage pool deficiency' in thrombocytopenic absent radii syndrome. *Journal of the American Medical Association*, **221**, 1053.
- Dees, S. (1959). Allergy to cow's milk. *Pediatric Clinics of North America*, **6**, 881.
- Fanconi, G. (1967). Familial constitutional panmyelocytopenia, Fanconi's anemia. *Seminars in Hematology*, **4**, 233.
- Fontaine, J. L., and Navarro, J., (1975). Small intestinal biopsy in cow's milk protein allergy in infancy. *Archives of Disease in Childhood*, **50**, 357.
- Freier, S., and Kletter, B. (1970). Milk allergy in infants and young children, current knowledge. *Clinical Pediatrics*, **9**, 449.
- Freier, S., and Kletter, B. (1972). Clinical and immunological aspects of milk protein intolerance. *Australian Pediatric Journal*, **8**, 74.
- Freier, S., Kletter, B., Gery, I., Lebenthal, E., and Geifman, M. (1969). Intolerance to milk protein. *Journal of Pediatrics*, **75**, 623.
- Gerrard, J. W., Lubos, M. C., Hardy, L. W., Holmlund, B. A., and Webster, D. (1967). Milk allergy: clinical picture and familial incidence. *Canadian Medical Association Journal*, **97**, 780.
- Gerrard, J. W., McKenzie, J., Goluboff, N., Garson, J., and Maningas, C. (1973). Cow's milk allergy: prevalence and manifestations in an unselected series of newborns. *Acta Paediatrica Scandinavica*, **Suppl.** 234.
- Goldman, A. S., Anderson, D. W., Sellers, W. A., Saperstein, S., Knikker, W. T., and Halpern, S. R., and collaborators (1963). Milk allergy. I. Oral challenge with milk and isolated milk proteins in allergic children. *Pediatrics*, **32**, 425.
- Gryboski, J. D. (1967). Gastrointestinal milk allergy in infants. *Pediatrics*, **40**, 354.
- Gryboski, J. D., Burkle, F., and Hillman, R., (1966). Milk induced colitis in an infant. *Pediatrics*, **38**, 299.
- Hall, J. G., Levin, J., Kuhn, J., Ottenheimer, E., van Berkum, P., and McKusick, V. A. (1969). Thrombocytopenia with absent radii (TAR). *Medicine*, **48**, 411.
- Heiner, D. C., Wilson, J. F., and Lahey, M. E. (1964). Sensitivity to cow's milk. *Journal of the American Medical Association*, **189**, 563.
- Holzel, A. (1965). Development of intestinal enzyme systems, and its relation to diarrhoea. *Pediatric Clinics of North America*, **12**, 635.
- Juif, J. G., Stoll, C., and Korn, R. (1972). Thrombopénie hypoplasique congénitale avec aplasie du radius. *Archives Françaises de Pédiatrie*, **29**, 513.
- Kucera, J. (1972). Aplasia of the radius combined with congenital hypoplastic thrombopenia. (In Czechoslovakian.) *Československá Peditre*, **27**, 125.
- Kuitunen, P., Visakorpi, J. K., Savilahti, E., and Pelkonen, P. (1975). Malabsorption syndrome with cow's milk intolerance: clinical findings and course in 54 cases. *Archives of Disease in Childhood*, **50**, 351.
- Liu, H., Tsao, M. U., Moore, B. A., and Giday, Z. (1968). Bovine milk protein-induced intestinal malabsorption of lactose and fat in infants. *Gastroenterology*, **54**, 27.
- Masson, A., Cronmuller, G., Rousselot, P., Lutz, D., Berger, J., and Schneegans, E. (1971). La thrombopénie hypoplastique congénitale avec aplasie radiale. *Annales de Pédiatrie*, **18**, 777.
- McCann, M., Gold, E., and Schwartz, R. (1966). Disacchariduria in an infant with milk sensitivity. Cited in Cornblath, M., and Schwartz, R. *Disorders of Carbohydrate Metabolism in Infancy*, p. 267. Saunders, Philadelphia.
- Nilsson, L. H. and Lundholm, G., (1960). Congenital thrombocytopenia associated with aplasia of the radius. *Acta Paediatrica* **49**, 291.
- Omenn, G. S., Fingley, M. M., Graham, C. B., and Heinrichs, W. Le R. (1973). Prospects for radiographic intrauterine diagnosis—the syndrome of thrombocytopenia with absent radii. *New England Journal of Medicine*, **288**, 777.
- Silver, H., and Douglas, D. M. (1968). Milk intolerance in infancy. *Archives of Disease in Childhood*, **43**, 17.
- Stanfield, J. P. (1959). A review of cow's milk allergy in infancy. *Acta Paediatrica*, **48**, 85.
- Stoll, C., Sacrez, R., Willard, D., and Freysz, H. (1972). Un cas de trisomie 18 avec aplasie bilatérale du radius et thrombopénie. *Pédiatrie*, **27**, 537.
- Sultan, Y., Scrobohaci, M. L., Rendu, F., and Caen, J. P. (1972). Abnormal platelet function, population and survival-time in a boy with congenital absent radii and thrombocytopenia. *Lancet*, **2**, 653.
- Sultan, Y., Scrobohaci, M. L., Jeanneau, C., Rendu, F., and Caen, J. P. (1973). Anomalies de la lignée plaquettaire au cours du syndrome d'aplasie radiale avec thrombocytopenie. *Nouvelle Revue Française d'Hématologie*, **13**, 573.
- Tönz, O., Keller, H., and Cottier, H. (1960). Beitrag zum Syndrom der Kongenitalen Megakaryocytopenie mit Radiusaplasie. *Helvetica Paediatrica Acta*, **15**, 1.
- Walker-Smith, J. (1975). Cow's milk protein intolerance. *Archives of Disease in Childhood*, **50**, 347.
- Wilson, J. F., Heiner, D. C., and Lahey, M. E. (1964). Milk-induced gastrointestinal bleeding in infants with hypochromic microcytic anemia. *Journal of the American Medical Association*, **189**, 568.

Correspondence to Dr. M. Whitfield, Department of Paediatrics, Western General Hospital, Edinburgh, EH4 2XU.