

Functional intestinal obstruction due to deficiency of argyrophil neurones in the myenteric plexus

Familial syndrome presenting with short small bowel, malrotation, and pyloric hypertrophy

M. S. TANNER, BARBARA SMITH, and JUNE K. LLOYD*

From The Hospital for Sick Children, Great Ormond Street, and St. Bartholomew's Hospital, London

Tanner, M. S., Smith, B., and Lloyd, J. K. (1976). *Archives of Disease in Childhood*, 51, 837. **Functional intestinal obstruction due to deficiency of argyrophil neurones in the myenteric plexus: familial syndrome presenting with short small bowel, malrotation, and pyloric hypertrophy.** In 3 infants functional intestinal obstruction, associated with a short small intestine, malrotation, and pyloric hypertrophy, was shown to be due to failure of development of the argyrophil myenteric plexus, with the absence of ongoing peristalsis. 4 infants with similar clinical features have been described previously, and there is evidence for an autosomal recessive mode of inheritance of this syndrome.

In 1899, Bayliss and Starling observed that peristaltic contractions of the intestine are reflex responses to local stimuli carried out by local nervous mechanisms but independent of the extrinsic nerve supply. Many observations since that time have confirmed that though smooth muscle has intrinsic motility and rhythmicity, organized forward peristalsis depends upon an intact myenteric plexus.

While much has been learned about the behaviour of isolated strips of intestine in organ baths, the study of the control of peristalsis in the intact gastrointestinal tract is more difficult and in this context the study of congenital abnormalities of the myenteric plexus yields useful information. In this paper we describe a syndrome of pyloric hypertrophy, short small intestine, malrotation, and functional obstruction of the bowel in which the latter was due to peristaltic failure associated with faulty development of the myenteric plexus.

Case reports

In all 3 cases the histological examination of the intestine was carried out by the same observer (B.S.).

Received 27 February 1976.

*Present address: Department of Child Health, St. George's Hospital, Blackshaw Road, Tooting, London SW17 0QT.

Case 1. This boy, the sixth child of healthy, unrelated parents, was born at 36 weeks' gestation weighing 2.94 kg. Exchange transfusions were performed at 30 and 67 hours of age for hyperbilirubinaemia due to Rhesus haemolytic disease. 2 of his 5 sibs had also required exchange transfusion but there was no other relevant family history.

He began vomiting on the 6th day of life, the vomit becoming bile-stained on the 13th day at which time he was transferred to The Hospital for Sick Children. Radiological examination showed malrotation of the small bowel and laparotomy was performed. At operation he was found to have hypertrophy of the pylorus forming a typical tumour, and a short small bowel (75 cm) which was dilated and situated on the right side with the caecum and colon on the left side. There were adhesions between the caecum and duodenum and a volvulus of the small bowel whose colour and peristalsis were poor. After derotation of the bowel and freeing of adhesions the colour of the bowel markedly improved. Ramstedt's operation and appendicectomy were performed and the bowel was replaced in the malrotated position.

He was fed intravenously for 9 days after surgery when oral feeds were reintroduced. Because of continuing abdominal distension and large amounts of gastric aspirate, a second barium study was performed on day 25. This showed that the small bowel was still dilated, and though there was no evidence of mechanical obstruction barium took 5 hours to reach the colon. The dilatation and delayed transit were attributed at the

time to vascular damage to the bowel. Oral feeding was continued but abdominal distension with moderate amounts of gastric aspirate persisted; he had loose frequent stools and failed to gain weight.

A second laparotomy was performed on day 63. The small bowel was noted to be extremely dilated and hypertrophic, being approximately as large as adult small bowel. Operative cholangiography showed no abnormality of the extrahepatic bile ducts, and a liver biopsy was obtained. Histological examination of the liver showed widespread single cell necrosis with an associated inflammatory infiltrate; there was marked bile stasis especially in the centrilobular areas, but no abnormality of the bile ducts was seen (Dr. J. R. Pincott).

He made a satisfactory recovery from the second laparotomy and gained weight while being fed intravenously for 11 days (days 63-74), but all subsequent attempts to establish oral feeding were unsuccessful. Many different types of feed were tried, each resulting in large volumes of gastric aspirate, gross abdominal distension, loose stools, and dehydration. On intravenous feeding he gained weight but abdominal distension persisted. Delayed transit time in the gut was shown by the presence of meat fibres in the stools 9 days after withdrawal of feeds containing comminuted chicken.

Further barium studies on day 133 showed a con-

siderably dilated duodenum which was the site of both prograde and retrograde peristalsis. The small intestine was also dilated but there was no mechanical obstruction. The colon was of normal calibre and barium refluxed into the dilated distal ileum. His clinical condition continued essentially unchanged and intravenous feeding was continued. He died at the age of 165 days after a chest infection and septicaemia.

Fresh post-mortem material was examined from several areas throughout the length of the alimentary tract. The entire tract was thicker than normal but pyloric hypertrophy was not obvious. In all areas paraffin sections showed that neurones were present, but most had no stainable cytoplasm, and their nuclei showed clumped chromatin, as do neuroblasts. Silver preparations of frozen material cut parallel to the bowel wall showed that the extrinsic nerve supply was probably normal. The intrinsic ganglia contained more neuronal nuclei than they should, but there were hardly any argyrophil cells, and no intrinsic axons or processes were visible (Figs. 1, 2). In the colon there were a few more mature ganglion cells with short axons and dendrites. The pyloric ganglia showed a marked overgrowth of extrinsic axon terminals forming a tangled mass of argyrophil material (Fig. 3). The liver was enlarged, and histological examination showed more

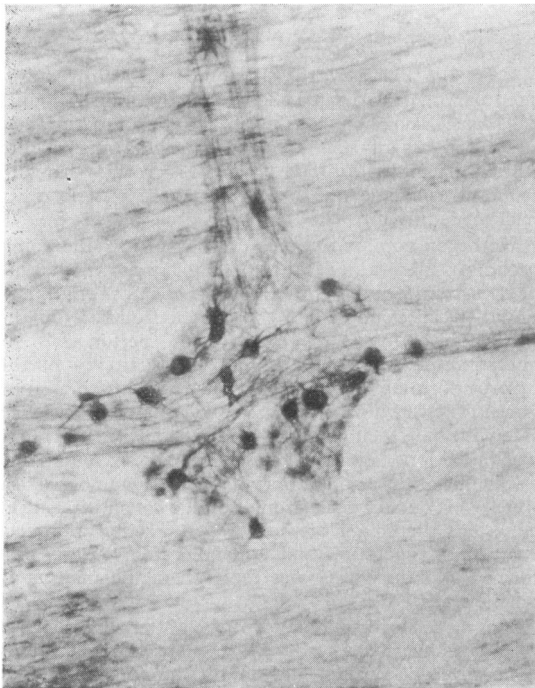

FIG. 1.—Myenteric plexus of normal ileum. Argyrophil neurones give off processes which enter the nerve trunks to run together with the extrinsic fibres. (Modified Schofield. $\times 73$.)

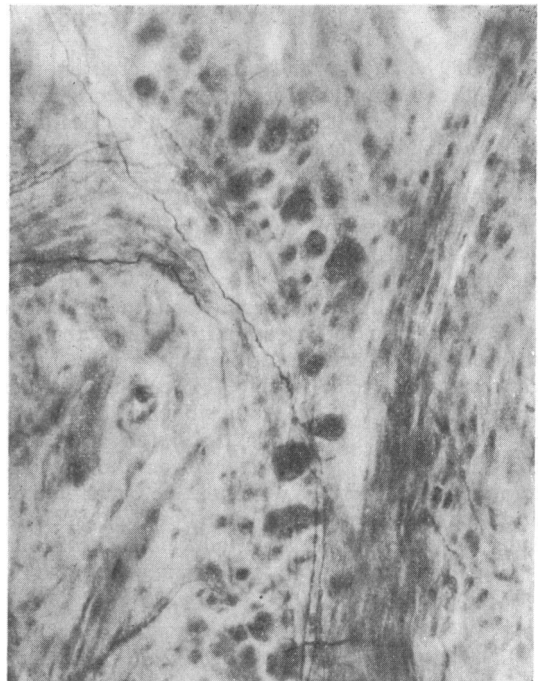


FIG. 2.—Case 1. Myenteric ganglion from the ileum. Extrinsic axons can be seen in relation to a ganglion containing neurones without processes. (Modified Schofield. $\times 195$.)

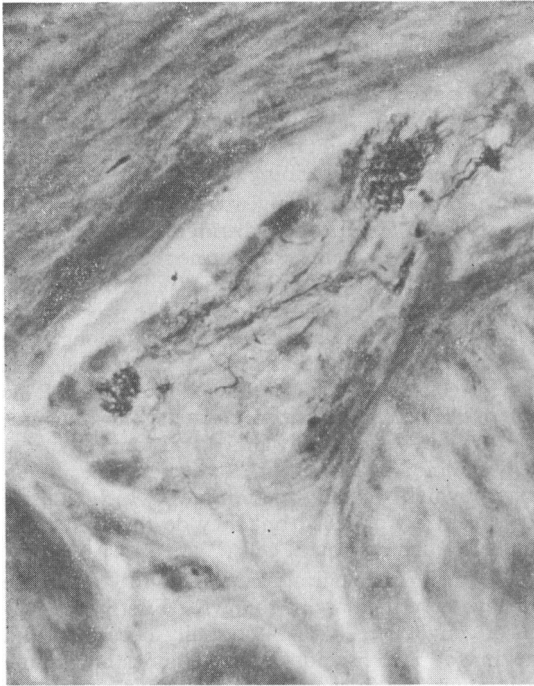


FIG. 3.—Case 1. Myenteric ganglion from the pylorus. Extrinsic nerve bundles entering from the two corners end in a tangled mass of axons, probably because the neuroblasts which can only be faintly seen do not have adequate dendrites on which the nerve fibres can terminate. (Modified Schofield. $\times 195$.)

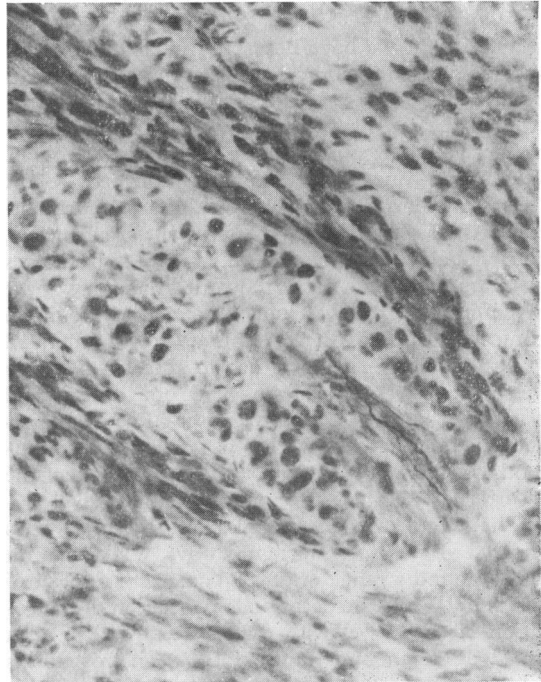


FIG. 4.—Case 2. Myenteric ganglion from the ileum. A leash of axons enters the ganglion which contains only nonargyrophil neurones, some of which are neuroblasts. (Modified Schofield. $\times 195$.)

extensive hepatocyte necrosis; the inflammatory infiltrate persisted, and there was now bile duct proliferation and some fibrosis. The appearances were those of early biliary cirrhosis (Dr. M. Erdohazi).

Case 2. The clinical course of this boy was reported in detail by Royer *et al.* (1974). A term infant, the product of a doubly consanguineous marriage, was admitted to hospital at 15 days of age because of bile-stained vomiting. Laparotomy showed pyloric hypertrophy, a short small intestine (45 cm), and malrotation. Subsequently he was maintained on intravenous nutrition for 6 months, each attempt at oral feeding causing a return of bilious vomiting. Two further laparotomies were performed at which the small intestine was found to be excessively distended, in contrast to the normal calibre of the large bowel. Two ileostomies were performed, but they did not relieve the functional obstruction.

Histological examination was carried out on a portion of ileum removed at ileostomy. Paraffin sections showed thickening of the muscle coats and an increased complement of neurones. Silver preparations showed that there were neuroblasts present (Fig. 4); only one

argyrophil cell could be found. No axons could be traced to parent cells, and thus all the axons seen were probably extrinsic, though this is not certain in a biopsy specimen.

Case 3. This girl and her sib were under the care of Professor J. Laugier of the Centre Hospitalier de Tours. The parents were unrelated; the sib had had a malrotated small intestine measuring only 40 cm in length, together with pyloric hypertrophy and functional small bowel obstruction, and had died at 2½ months of age after a period of intravenous feeding and unsuccessful attempts at oral feeding. Her case has been described in detail by Royer *et al.* (1974).

This case weighed 2.4 kg at birth at a probable gestational age of 36 weeks. Barium meal showed a malrotation at 18 hours of age. At 24 hours she had a convulsion followed by cardiac arrest, and resuscitation was unsuccessful. Necropsy examination immediately after death showed a short small bowel (40 cm), a short large bowel (32 cm), multiple adhesions, and pyloric hypertrophy. The cause of the convulsion could not be determined. Histological examination of a portion of ileum showed similar pathological changes to those found in Case 2. Though argyrophil cells are always scanty in the neonate, neuroblasts are not usually seen.

Discussion

The infant we have described in detail (Case 1) showed a striking clinical similarity to the 4 infants described by Royer *et al.* (1974), in one of whom we studied the gut histology (Case 2), and our Case 3 is the younger sib of one of Royer's patients. We found one other similar published report (Kern and Harris, 1973) where failure of co-ordinated peristalsis was the most significant abnormality, and though jejunal and rectal biopsy appearances were reported to be normal, detailed histology of the myenteric plexus was not obtained. The main clinical features of these 7 infants are summarized in the Table. The fact that in this small group there are two pairs of sibs and one other child was the product of a doubly consanguineous marriage (his grandfathers were brothers and his grandmothers were sisters) strongly suggests that the disorder is inherited as an autosomal recessive.

The length of the neonatal small intestine varies widely. In a post-mortem study, Walker-Smith (1971) found a range of 68–386 cm, with a mean of 243 cm. While the occasional association of malrotation of the bowel with pyloric stenosis has been noted (Rickham and Johnson, 1969), malrotation is rarely associated with a short small bowel. Hamilton, Reilly, and Morecki (1969) described a girl with malrotation of a small intestine that was only 40 cm in length at 7 months of age; the presenting feature was malabsorption which spontaneously improved over the first 7 years of life, and at no time was there evidence of abnormal peristalsis. She had a sib with a short small intestine who died

at 1 month of age. In the single case reports of Konvolinka (1970) and Yutani *et al.* (1973) of infants with malrotation and short small bowel, neither pyloric hypertrophy nor incoordinate peristalsis were noted. It is likely therefore that these cases have a different pathological basis from the syndrome we are describing.

In the normal adult myenteric plexus there are two types of neurone, distinguished by their affinity for silver stains, and termed argyrophil and argyrophobe. Argyrophil cells comprise 5–20% of the total number of neurones. The processes of the argyrophil cells run in the plexus along with the extrinsic sympathetic and parasympathetic fibres, constituting a neuronal network. This network controls organized peristalsis and ensures that the bolus moves onwards at the correct speed. Argyrophobe cells appear to secrete the transmitter which actually determines which muscle fibres contract or relax, but they do this under the control of the argyrophil cells.

The main histological features of the syndrome we have described are as follows. Firstly, the fall-out of ganglion cells which normally occurs around the time of birth has not occurred, and there are too many neurones in the ganglia. Secondly, many of the neuronal nuclei have the clumped chromatin characteristic of neuroblasts. Thirdly, intrinsic argyrophil ganglion cells and their processes are absent or much reduced. The extrinsic innervation is probably normal. Lack of argyrophil neurones is characteristic of hypertrophic pyloric stenosis (Rintoul and Kirkman, 1961), but an

TABLE

Clinical features of 7 infants with malrotation, short small bowel, pyloric stenosis, and functional intestinal obstruction

Case no.	Sex	Family history	Intestinal features				Other features	Survival (m)	Reference
			Pyloric hypertrophy	Length of small bowel (cm)	Malrotation	Functional obstruction			
1	M	None	Present	75	Present	Present	Hepatitis	5	Royer <i>et al.</i> (1974)
2	M	Double consanguinity	"	45	"	"		7	
3	F	} Sibs	"	45	"	"	Short colon	1 d	
4	F		"	40	"	"		2½	Royer <i>et al.</i> (1974)
5	M	} Sibs	"	70	"	"	Persistent ductus arteriosus	1	Royer <i>et al.</i> (1974)
6	M		"	Absent	25	"	"		1
7	M	None	Present	70	"	"		4	Kern and Harris (1973)

unusual feature of the pylorus in our Case 1 was the overgrowth of extrinsic axons at their termination. This suggests that the neuroblasts were too primitive, and had no dendrites on which the incoming axons could terminate.

In the total absence of innervation, smooth muscle of the bowel wall will contract spontaneously and rhythmically, a process of segmentation. Without the argyrophil plexus, segmentation is not co-ordinated and the bolus cannot be propelled onwards efficiently. This abnormality of motility was shown radiologically in Case 1 where to-and-fro movement of barium in the upper small bowel was clearly seen. It was also reflected in the markedly delayed transit time.

The thickening of the bowel wall, which was a striking feature at laparotomy and may be of diagnostic help, is probably related to two factors. Firstly, lack of bolus movement results in intestinal dilatation and muscle stretching; which then stimulates contraction and produces work hypertrophy. Secondly, in contrast to skeletal muscle, there is evidence that the innervation of smooth muscle decreases its contraction (Wood, 1975). Denervation may therefore actually increase segmentation.

Apart from Hirschsprung's disease, in which the neurones are absent in the contracted segment and the plexus is abnormal in the dilated portion (Smith, 1967), and the syndrome reported in this paper, other conditions have been described in which faulty neural control causes abnormal peristalsis in infants. Erdohazi (1974) reported an infant with 'retarded development of the enteric nerve cells' in whom the bowel was anatomically normal but there was functional obstruction. Histologically, the appearance differed from Hirschsprung's disease in that there were numerous small round or oval cells in the usual site of the myenteric and submucous plexuses, and there were no unmyelinated nerve trunks. Bughaighis and Emery (1971) described a heterogeneous group of babies with functional intestinal obstruction in whom delayed maturation of the myenteric ganglia was detected by routine staining methods. Finally, the occurrence of temporary functional intestinal obstruction in preterm infants is well recognized. The histology of this entity has not been studied by silver staining and it is tempting to speculate that it may be due to delayed maturation of argyrophil neurones.

The diagnosis of the syndrome of argyrophil neurone deficiency is unlikely to be made before laparotomy, unless a previous child has been affected. The marked thickening of the bowel wall is indicative of the underlying neural abnormality and if an ileostomy is performed, it is possible without added risk to obtain 2-3 cm of ileum upon which a histological diagnosis may be made. Accurate diagnosis is important not only because of the genetic implications, but also in guiding management. In the absence of the argyrophil plexus, ongoing peristalsis cannot be effected by pharmacological stimulation of either the nerve cells or the muscle fibres and the condition is therefore incompatible with life. Thus long periods of intravenous nutrition seem inappropriate.

We are grateful to Professor J. Laugier for permission to give details of Case 3 and to Professor P. Royer for permission to include the histological details in Case 2.

REFERENCES

- Bayliss, W. M., and Starling, E. H. (1899). The movements and innervation of the small intestine. *Journal of Physiology*, **24**, 99.
- Bughaighis, A. G., and Emery, J. L. (1971). Functional obstruction of the intestine, due to neurological immaturity. *Progress in Pediatric Surgery*, **3**, 37.
- Erdohazi, M. (1974). Retarded development of the enteric nerve cells. *Developmental Medicine and Child Neurology*, **16**, 365.
- Hamilton, J. R., Reilly, B. J., and Morecki, R. (1969). Short small intestine associated with malrotation: a newly described congenital cause of intestinal malabsorption. *Gastroenterology*, **56**, 124.
- Kern, I. B., and Harris, M. J. (1973). Congenital short bowel. *Australian and New Zealand Journal of Surgery*, **42**, 283.
- Konvolinka, C. W. (1970). Congenital short intestine: a rare occurrence. *Journal of Pediatric Surgery*, **5**, 574.
- Rickham, P. P., and Johnson, J. H. (1969). *Neonatal Surgery*. Butterworths, London.
- Rintoul, J. R., and Kirkman, N. F. (1961). The myenteric plexus in infantile hypertrophic pyloric stenosis. *Archives of Disease in Childhood*, **36**, 474.
- Royer, P., Ricour, C., Nihoul-Fekete, C., and Pellerin, D. (1974). Le syndrome familial de grêle court avec malrotation intestinale et sténose hypertrophique du pylore chez le nourrisson. *Archives Françaises de Pédiatrie*, **31**, 223.
- Smith, B. (1967). Myenteric plexus in Hirschsprung's disease. *Gut*, **8**, 308.
- Walker-Smith, J. A. (1971). Dissecting microscope appearances of the small intestine in childhood: a post-mortem study. M.D. thesis, University of Sydney.
- Wood, J. D. (1975). Neurophysiology of Auerbach's plexus and control of intestinal motility. *Physiological Reviews*, **55**, 307.
- Yutani, C., Sakurai, M., Miyajii, T., and Okuno, M. (1973). Congenital short intestine. *Archives of Pathology*, **96**, 81.

Correspondence to Dr. M. S. Tanner, Department of Child Health, King's College Hospital, Denmark Hill, London SE5 8RX.