

Extrahepatic biliary atresia versus neonatal hepatitis

Review of 137 prospectively investigated infants

ALEX P. MOWAT, H. T. PSACHAROPOULOS, AND ROGER WILLIAMS

From the Department of Child Health and the Liver Unit, King's College Hospital Medical School

Mowat, A. P., Psacharopoulos, H. D., and Williams, R. (1976). *Archives of Disease in Childhood*, 51, 763. **Extrahepatic biliary atresia versus neonatal hepatitis: review of 137 prospectively investigated infants.** In a prospective regional survey of neonatal hepatitis syndrome 32 infants had extrahepatic biliary atresia (EHBA) and 103 had hepatitis. No cause for the lesion was found in infants with extrahepatic biliary atresia, but in 32 with hepatitis a specific cause was identified, 24 having genetic deficiency of the serum protein α_1 -antitrypsin. No differences were observed in parental age, mother's health in pregnancy, month of birth, birth order, or sex of the infants. Familial idiopathic hepatitis occurred in 3 of 67 sibs of patients with idiopathic hepatitis, but the 33 sibs of EHBA patients had no liver disease. Of the infants with hepatitis, 36 were of low birthweight, <2.5 kg, and 23 were born prematurely. Infants with biliary atresia were all of normal birthweight and only one was born prematurely.

Consideration of clinical and biochemical abnormalities in the first 2 months of life showed no differences between the two groups except that infants with EHBA were more commonly jaundiced from birth (80%) and had more frequently acholic stools (83%). The frequency of these features in patients with hepatitis being 68% and 52%. Standard tests of liver function were not discriminatory. Percutaneous liver biopsies were diagnostic in 75% of those with EHBA and in 92% of those with hepatitis. The ^{131}I Rose Bengal faecal excretion was less than 10% in 26 of 28 infants with EHBA and in only 5 of 18 with hepatitis. These latter two investigations together allowed a correct preoperative diagnosis of EHBA in all instances. Bile drainage was achieved surgically in only 3 cases. A major reason for these poor results may have been the late referral of cases for diagnosis and laparotomy, which should be performed as soon as the diagnosis is suspected and always by 70 days of age.

Extrahepatic biliary atresia (EHBA) carries a poor prognosis. Only 5% of cases have distal obstructions with patent bile-containing proximal bile ducts which allow bile drainage by standard surgical techniques (Arima, Fonkalsrud, and Neerhout, 1974). Many of these will have developed cirrhosis by early childhood, though occasional cases survive to adulthood (Berenson, Garde, and Moody, 1974). The remaining 95% usually die by the age of 2 years (Campbell *et al.*, 1974a), though the operation of hepatic portoenterostomy introduced in Japan 15 years ago by Kasai and co-workers has given

encouraging results in such patients with symptom-free survival to the age of 17 years (Kasai, Watanabe, and Ohi, 1975). Confirmation of these Japanese results (Lilly and Altman, 1975) and the observation that portoenterostomy is most likely to be successful if carried out before 70 days of age necessitates careful assessment of investigations necessary to make the diagnosis at a sufficiently early stage.

Relevant to such considerations are new ideas about the pathogenesis of biliary atresia. Although the lesion is commonly regarded as congenital, it is now thought that the hepatic parenchymal cells develop as outgrowths from the primitive bile duct system (Koga, 1971), and as there is no evidence

that the former are abnormal a primary failure of development of the bile ducts seems unlikely. Further, the degree of duct involvement is very variable (Alagille, 1972; Strauss, Valderrama, and Alpert, 1972; Landing, 1974), which is difficult to explain on the basis of a single antenatal insult or abnormality in organogenesis. Also, in some infants with classical extrahepatic biliary atresia there is evidence that the bile ducts were previously intact (Holden, 1964; Poley *et al.*, 1972; Danks, 1974). The more likely pathogenesis, therefore, is that the condition results from a sclerosing inflammatory lesion initiated in the bile duct epithelium and involving part or all of the biliary tract, starting late in fetal life, or early in postnatal life. The aetiology is unknown. It has been suggested that both neonatal hepatitis and EHBA may be due to the same basic disease process with the major damage occurring in some instances in the bile ducts (Alagille, 1972; Strauss *et al.*, 1972; Landing, 1974). We report an analysis of data collected during a prospective study of the neonatal hepatitis syndrome, in which findings in 32 infants with extrahepatic biliary atresia are compared with 105 with other forms of the syndrome. Clinical and biochemical features of possible diagnostic importance during the first 2 months of life when surgery has the best chance of success, and the particular value of percutaneous liver biopsy and the ^{131}I Rose Bengal faecal excretion test, are also considered.

Materials and methods

Infants in this report are those born before June 1974 who are included in a prospective regional survey (Porter *et al.*, 1972) of the neonatal hepatitis syndrome. This was defined for the purpose of the study as a conjugated hyperbilirubinaemia starting within the first 4 months of life and accompanied by biochemical and pathological evidence of hepatocellular necrosis. This, therefore, includes both patients with EHBA and those with intrahepatic disease or hepatitis, but with patent biliary passages. Final proof of EHBA was obtained in all instances at laparotomy. In all cases known genetic, metabolic, infectious, or environmental causes of the neonatal hepatitis syndrome were fully investigated. Those patients with hepatitis in whom no causative agent was identified or in whom the association with the putative cause was tenuous, for example, sepsis or a rise in cytomegalovirus antibody titre in the serum without recovery of the cytomegalovirus from liver tissue, were classified as idiopathic hepatitis.

Standard laboratory methods were used to determine serum bilirubin, aspartate aminotransferase, alkaline phosphatase, and prothrombin time. Percutaneous liver biopsies were performed using the Menghini technique.

In the Rose Bengal excretion test, Lugol's iodine, 3 drops daily for 3 days was administered to block possible thyroid uptake of free radioactive iodine, followed by intravenous ^{131}I Rose Bengal in a dose of $1\ \mu\text{Ci}/\text{kg}$. Stools uncontaminated with urine were collected for 72 hours and the amount of isotope recovered in the stools expressed as a percentage of the administered dose. Excretion of $<10\%$ of the injected dose was taken to indicate extrahepatic bile duct obstruction or severe cholestasis. In cases in whom the initial excretion was $<10\%$ but in whom other findings, particularly the liver biopsy, were not diagnostic of EHBA, the test was repeated 18–21 days after starting cholestyramine orally in a dose of 1g four times a day, a measure associated with increased excretion in hepatitis but not in EHBA (Campbell *et al.*, 1974b).

Results

Of the 137 cases investigated, 32 infants were found to have EHBA. 2 infants had large choledochal cysts with narrow, totally obstructed bile ducts shown by cholangiography. The remaining 103 cases were classified as having hepatitis, a specific cause being identified in 32. Genetic deficiency of α_1 -antitrypsin was by far the most frequent, accounting for 24 of these 32 infants (Table I). None of these causes could be identified

TABLE I

Aetiological and structural classification of neonatal hepatitis syndrome

	No. of patients
Extrahepatic biliary atresia	32
Hepatitis group	103
α_1 -antitrypsin deficiency	24
Galactosaemia	1
Tyrosinosis	1
Hepatitis B	2
Rubella	2
Toxoplasmosis	1
Cytomegalovirus	1
Idiopathic hepatitis	71
Choledochal cyst	2
Total	137

in patients with EHBA. The remaining 71 patients with hepatitis are considered idiopathic, though 9 of these had conditions which may be associated with hepatitis but which were not definitely causative in these patients (chromosomal trisomy, 4; sepsis, 3; cystic fibrosis, 2; halothane, 1). One other infant in this idiopathic hepatitis group was shown to have hypoplasia of intrahepatic bile ducts and normal extrahepatic ducts at laparotomy.

There may have been other infants in the series with similar pathologies in whom jaundice cleared and therefore did not come to surgery and wedge biopsy of the liver.

Comparison of factors of possible aetiological importance. When findings in patients with EHBA are compared with those of the hepatitis cases, no seasonal variation in the month of birth was found (Fig.) or in the distribution of

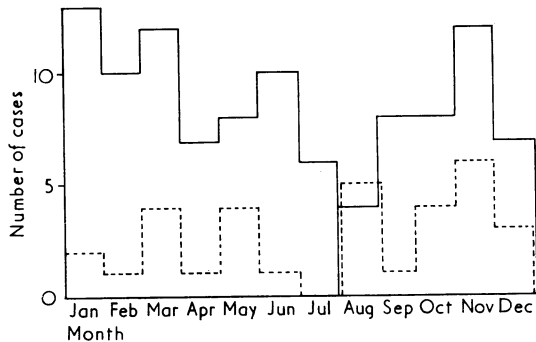


FIG.—Total number of cases born each month with neonatal hepatitis syndrome (continuous line) and with extrahepatic biliary atresia (broken line) in prospective regional survey of neonatal hepatitis syndrome.

birth order. Of the EHBA infants, 46% were first-born, 18% second-born, 18% third, 12% fourth, 3% fifth and sixth in family position. Parental ages were not significantly different; the mean (\pm SD) age of the fathers being 31.4 ± 7.4 , 29.3 ± 6.4 , 30.7 ± 6.7 years, and of the mothers,

27.8 ± 6 , 26.3 ± 6 , 27.1 ± 6.2 years in the EHBA group, total hepatitis group, and idiopathic cases respectively. In the same groups of patients the percentage of males was 59%, 62%, and 60.5% respectively. No liver disease could be detected in the 33 sibs of patients with EHBA, but 3 of 67 sibs of those with idiopathic hepatitis had chronic liver disease which started as neonatal hepatitis.

There was no difference in the incidence of minor intercurrent infections or exposure to drugs during pregnancy and labour in the EHBA cases compared with those with hepatitis. As shown in Table II, one child with EHBA had a gestation of <37 weeks, and only one mature child was light-for-gestational age; whereas in the hepatitis group a significantly greater number of infants had short gestations ($P < 0.005$). None of these infants with EHBA weighed less than 2.5 g at birth, in contrast to the 35% of infants in the complete hepatitis group and 39% of those with idiopathic hepatitis who had a birthweight of less than 2.5 g ($P < 0.005$).

Chromosomal abnormalities were present only in the hepatitis patients, 4 of whom had trisomy. Identifiable congenital abnormalities such as congenital heart disease, meningomyeloceles, and cleft palate, and significant clinical disorders outside the gastrointestinal system occurred more commonly in hepatitis than in EHBA.

Clinical features. Jaundice had started in the first 2 weeks of life in 80% of those with EHBA as opposed to only 68% of those with hepatitis. In 6 patients with EHBA, however, jaundice was first noted at varying times between the third and

TABLE II
Incidence of factors of possible aetiological significance

	EHBA		Hepatitis group		Idiopathic hepatitis	
	No. of patients	%	No. of patients	%	No. of patients	%
Gestation (w)						
<32	0		4	3.8	4	5.6
33-37	1	3.1	18	18.3	14	19.7
38-40	28	87.5	63	60.9	42	59.1
40	3	9.4	17	16.3	11	15.4
Birthweight (kg)						
<2.0	0		12	11.5	12	16.9
2-2.5	0		24	23.1	17	23.9
2.5-3.0	13	40.6	27	26.0	17	23.9
>3.0	19	59.3	40	39.4	25	35.2
Light-for-dates	1	3.2	19	18.3	18	25.4
Congenital abnormalities	3	9.3	11	10.4	9	12.6
Disorders outside gastrointestinal system	6	18.7	35	33.7	24	33.8

EHBA, extrahepatic biliary atresia.

sixth week of age (Table III). 83% of those with EHBA were recorded as having acholic stools in the first 2 months of life as opposed to 52% of those with hepatitis and 41% of those with idiopathic hepatitis ($P < 0.005$).

There were no significant differences in the frequency of abnormal physical features in the three groups except hepatomegaly (a liver edge palpable more than 5 cm below the costal margin), which occurred more commonly in EHBA than in the hepatitis group ($P < 0.05$). Splenomegaly, or at least palpable splenic enlargement, was also more common in this group.

Comparison of liver function tests in the first 2

months of life showed considerable overlap between the three groups, but serial determinations of serum bilirubin concentrations showed that a steady fall occurred only in hepatitis and that a stable bilirubin was significantly more common in EHBA ($P < 0.005$). In both EHBA and hepatitis, however, a progressive rise in bilirubin or fluctuations of serum bilirubin concentration of more than 51 $\mu\text{mol/l}$ (3 mg/100 ml) occurred with equal frequency. A direct reacting bilirubin of 68 $\mu\text{mol/l}$ (4 mg/100 ml) was found significantly more frequently in EHBA ($P < 0.001$) but the frequency of serum bilirubin levels of $> 235 \mu\text{mol/l}$ (15 mg/100 ml) was similar in the two groups (Table IV). Raised

TABLE III
Clinical features in first 2 months of life

	EHBA		All hepatitis		Idiopathic hepatitis	
	No. of patients	%	No. of patients	%	No. of patients	%
Age at onset of jaundice (w)						
0-2	26	81.3	67	64.7	46	64.7
3-4	5	15.6	16	16.2	11	15.4
5-6	1	3.1	11	10.4	7	9.8
7-12	0		5	4.76	4	5.6
> 12	0		4	3.8	3	4.2
Acholic stools	25	83.3	52	52.5	29	42.6
Oedema	4	12.5	9	8.7	7	9.8
Haematic lesions	4	12.5	11	10.6	8	11.2
Palpable spleen	22	68.7	56	53.8	38	53.5
Hepatomegaly > 5 cm below costal margin	18	56.3	21	20.2	14	19.7

TABLE IV
Biochemical abnormalities in first 2 months of life

	EHBA		All hepatitis		Idiopathic hepatitis	
	No. of patients	%	No. of patients	%	No. of patients	%
<i>(a) Pattern of serial serum bilirubin concentrations</i>						
Progressive increase	5	15.6	13	13.1	7	10.6
Stable	22	68.8	27	27.2	18	27.2
Fluctuations of $> 51 \text{ IU/l}$	5	15.6	13	13.1	8	12.1
Steady fall	0		46	46.4	33	50.0
<i>(b) Maximum abnormality</i>						
Total bilirubin $> 235 \mu\text{mol/l}$	6	19.3	23	22.3	20	28.5
Direct bilirubin $> 68 \mu\text{mol/l}$	24	88.8	51	53.1	36	52.9
<i>Aspartate aminotransferase (IU/l)</i>						
< 200	15	50.0	58	57.4	38	55.0
200-400	14	46.6	30	29.7	22	31.4
> 400	1	3.3	13	12.8	9	12.8
<i>Alkaline phosphatase (IU/l)</i>						
< 150	2	7.4	17	17.5	10	15.3
150-300	14	50.0	42	43.0	30	46.1
> 300	12	42.8	38	39.1	25	38.4
<i>Prothrombin time</i>						
Prolonged $> 4 \text{ s}$	6	19.3	16	16.2	7	10.7

Conversion: SI to traditional units—Bilirubin: 1 $\mu\text{mol/l} \approx 0.06 \text{ mg/100 ml}$.

aspartate transaminase levels more than twice normal occurred in all instances, but levels >400 IU/l were more frequent in hepatitis than in EHBA ($P < 0.05$). Serum alkaline phosphatase levels were raised in all patients with levels >300 IU/l (43 KA units/100 ml), occurring as frequently in hepatitis as in EHBA. A prothrombin time prolonged by more than 4 s was equally common in both groups (EHBA 19%, hepatitis 16%).

Liver biopsy interpretation. In 15 of the 20 infants with EHBA who had percutaneous liver biopsies the histological abnormalities were suggestive or diagnostic of EHBA (Table V). EHBA

TABLE V
Percutaneous liver biopsy in EHBA cases

Duration of jaundice at biopsy (w)	Pathological diagnosis	
	EHBA (n=15)	Hepatitis (n=5)
<4	1	1
4-7	5	1
8-11	2	1
>12	7	2

was considered to be the most likely diagnosis if the biopsy showed widened portal tracts with prominent, distorted, elongated, angulated bile ducts, increased fibrosis, and inflammatory cell infiltrate with preservation of normal hepatic architecture and cholestasis with bile lakes. The diagnosis of hepatitis made in 5 of the EHBA patients was on the basis of prominent hepatocellular necrosis, disorganization of liver cords, giant cell transformation, and inflammatory cell infiltrate in the parenchyma and portal tracts. Cholestasis, prominent particularly within the hepatocytes, also favoured a diagnosis of hepatitis. While portal bile duct proliferation was often noted, the severity of the bile duct lesion was much less than that of the hepatocellular lesion. Mistakes in pathological diagnosis occurred as frequently if the biopsy was done early, i.e. between 9 and 12 weeks, as after this time (Table V). The 2 infants with choledochal cysts showed features of extrahepatic biliary atresia. 76 of the 82 patients with hepatitis who had percutaneous liver biopsies were correctly diagnosed but in 6 histological features were either diagnostic or more suggestive of EHBA than of hepatitis. No complications of percutaneous biopsy occurred.

¹³¹I Rose Bengal faecal excretion. 26 of 28 patients with EHBA excreted $<10\%$ of the

injected dose in 72 hours on initial investigation. Both those with high excretion were females and in one of these the test was repeated during cholestyramine administration with excretion falling from 11.2 to 7%. 13 patients in whom excretion was $<10\%$ on first testing but in whom the biopsy appearances were those of hepatitis, or were only suggestive of extrahepatic biliary atresia, also had repeat excretion determined during cholestyramine administration and in all of these the excretion remained $<10\%$.

These findings are to be contrasted with the excretion in hepatitis which was $>10\%$ in 13 of 18 infants. Of the 5 who excreted $<10\%$, 2 excreted 17 and 31% on repeat testing during cholestyramine administration, jaundice subsequently cleared completely, and they were not subjected to laparotomy. Excretion remained persistently low (5%) during cholestyramine administration in 2 patients who at laparotomy had patent extrahepatic ducts; one had severe hepatitis and cirrhosis, the other intrahepatic biliary hypoplasia. The remaining child proceeded to laparotomy without repeat testing and was found to have intact extrahepatic bile ducts.

Results of operative management. In only 3 of the 32 patients with EHBA was bile drainage established. One patient had distal atresia with patent proximal extrahepatic bile ducts which contained bile and allowed cholecystenterostomy to be carried out. Subsequently, jaundice remitted and liver function returned to normal, and at follow-up at 8 months of age this child is clinically and biochemically normal. The other 2 had a hepatic portoenterostomy. In this procedure the portahepatis is explored, residual bile ducts are removed, together with any fibrous tissue in the portahepatis, and an anastomosis fashioned between the portahepatis and a Roux-en-Y loop from the jejunum. In both of these children effective biliary drainage was established in operations at 5 months of age. Both however had subsequent intermittent attacks of jaundice and fever due to cholangitis, with persistently abnormal liver function tests and icterus at 33 months in one and clinical features of cirrhosis already at the age of 26 months in the other. The same operation carried out in 13 others produced no clinical or biochemical improvement, but in only 4 was portoenterostomy carried out before 70 days of age. In 2 patients hepatic bile ducts were anastomosed to bowel, one had a cholecystenterostomy, and one a hepatic lymphaticojejunostomy, all without apparent benefit to the patient.

Eight who had attempted anastomosis of liver

or bile duct to bowel are dead, the mean age of death being 11.6 months (range 2–27 months). The 7 survivors of portoenterostomy who did not have biliary drainage range in age from 20–38 months (mean 26 months). In 13 patients advanced cirrhosis was found at laparotomy and no surgical therapy was considered worthwhile. 9 of these died at a mean age of 19 months (range 8–26 months), while the 4 survivors have a mean age of 32 months (range 30–34 months).

Discussion

Early and positive differentiation of biliary atresia from the various forms of neonatal hepatitis is clearly essential if hepatic portoenterostomy is to be carried out by 10 weeks of age and unnecessary laparotomy avoided in hepatitis. Unfortunately, analysis of prospectively collected data, including a wide range of clinical and biochemical findings in the first 2 months of life in 32 patients with EHBA and 103 with hepatitis, shows that only a progressive fall in serum bilirubin concentration is of discriminatory value in the individual patient. The observation that prematurity and low birthweights are unusual in atresia may be of negative diagnostic value. In contrast to the findings in older children or adults presenting with features suggestive of hepatitis or biliary obstruction, in whom splenomegaly would suggest hepatitis, in this series splenomegaly was more commonly observed in atresia. While certain biochemical features occurred significantly more frequently in one or other group of patients, for example high aspartate transaminase levels in hepatitis, such levels did occur in atresia patients. Thus clinical findings and standard laboratory tests of liver function are as likely to be misleading as helpful in the individual patient.

None of the patients with EHBA were shown to have any of the recognized specific infectious or metabolic causes of hepatitis. Thus, systematic screening for such causes which is essential since specific treatment may be required, is also of value in limiting patients in whom EHBA must be considered. It is particularly important to examine for α_1 -antitrypsin deficiency, which is found in 25% of the hepatitis patients in this series, particularly since histological features may mimic atresia (Porter *et al.*, 1972). Unless this condition and biliary atresia are mutually exclusive both could occur in the same patient, but this has not yet been recorded. The extrahepatic biliary hypoplasia recorded in some infants with α_1 -antitrypsin deficiency is thought to be due to diminished bile secretion rather than a primary disease process

affecting extrahepatic bile ducts. (Porter *et al.*, 1972; Christen, Bau, and Halsband, 1975). Unfortunately, indirect methods of diagnosing EHBA, such as the ratio of serum bile salts (Javitt *et al.*, 1973), red cell haemolysis test (Lubin *et al.*, 1971), and serum α -fetoprotein concentration (Zeltzer *et al.*, 1974), which have been claimed to be of discriminatory value, have not been confirmed in practice (Manthorpe and Mowat 1975; Mowat, 1973; Johnston *et al.*, 1976). The safety and value of percutaneous liver biopsy in distinguishing patients with EHBA from those with hepatitis is well illustrated in this study. By the early use of this technique a diagnosis of hepatitis is confirmed in a large percentage of cases. In the majority of patients with EHBA the correct diagnosis was made. Nevertheless, in a number of instances the biopsy was not considered suggestive of EHBA though this proved to be the correct diagnosis, a difficulty reported by other authors (Alagille, 1972; Thaler and Gellis, 1968). In this series the timing of percutaneous liver biopsy in relation to the duration of jaundice did not seem to influence significantly the correct histological diagnosis of EHBA.

We have used the Rose Bengal faecal excretion test primarily to confirm liver biopsy findings where they have been diagnostic or suggestive of EHBA, or in instances in which persistent jaundice and acholic stools have made this diagnosis a possibility even though the biopsy appearances were not typical. We have repeated the test during cholestyramine administration when the biopsy was not diagnostic and confirmed that a persistently low excretion is of value in distinguishing patients with extrahepatic biliary obstruction from those with patent ducts. In this study the distinction, however, was not complete as had been previously reported (Campbell *et al.*, 1974b). 2 patients with intact extrahepatic ducts, one having severe liver disease and the other intrahepatic biliary hypoplasia, had persistently low excretion. Whether the improvement in excretion with hepatitis is attributable to the beneficial effect of cholestyramine on liver function, or to a reduction in the enteric reabsorption of Rose Bengal, is not clear. Urinary contamination of stools is particularly difficult to prevent in female infants and this may account for the false high excretion found in 2 infants. In this series both tests indicated that laparotomy was necessary in the 2 patients with choledochal cysts. The combination of percutaneous liver biopsy and ^{131}I Rose Bengal faecal excretion test thus distinguishes satisfactorily between patients with extrahepatic biliary obstruction who require laparotomy in case they have a surgically correctable lesion, and

those with hepatitis. The observations of Thaler and Gellis (1968), that laparotomy and careful examination of extrahepatic biliary system caused an increased incidence of cirrhosis in neonatal hepatitis, have not been refuted and remain a powerful argument against the unnecessary use of laparotomy to detect remedial lesions of the biliary tract.

The disappointing results of surgical intervention, including portoenterostomy, in this series are similar to those recently reported by Campbell *et al.* (1974a). Ineffective surgery in this series did not cause increased morbidity or significantly earlier death. Although successful biliary drainage was achieved in 2 patients operated on at 5 months of age, both rapidly developed advanced liver disease as occurred in the patients reported by Danks *et al.* (1974). In all of these series surgery was carried out after 3 months of age in most infants. These poor results must be contrasted with the most recent reports with high short-term success rates from North American clinics (Lilley and Altman, 1975), and particularly the Japanese studies of Kasai *et al.* (1975). The latter workers reported improved biliary excretion in 19 of 59 patients with complete extrahepatic biliary atresia in whom portoenterostomy was performed before 16 weeks of age. Jaundice cleared in 11 of these patients, 10 were thought to be 'cured', one for 17 years after operation. Even more remarkable is the finding that in 7 of 8 infants operated on before the age of 70 days jaundice cleared completely. Major surgical problems which have to be resolved include the prevention of ascending cholangitis and detection of secondary obstruction to bile flow occurring after successful hepatic portoenterostomy, usually due to local factors at the anastomotic site. The main modifications introduced to overcome these difficulties usually involve a cutaneous enterostomy which allows observation of bile drainage, and lengthening or increasing the complexity of the Roux-en-Y loop anastomosed to the liver (Kasai *et al.*, 1975; Lilley and Altman, 1975).

Extrahepatic biliary atresia is clearly a very variable condition both in the extent of extrahepatic duct obliteration and in the associated changes within the liver. Without effective surgery, there always follow marked intrahepatic changes with gradual destruction of bile ducts and extensive periportal fibrosis. Whether these changes arise from the primary cause or are secondary to the extrahepatic biliary lesion and can be prevented by early surgery in all instances is unresolved. In some infants at least hepatic portoenterostomy is

effective in arresting the process. These observations and the low success rate in the series of patients we report lead us to advocate at the present time a policy of surgical intervention as soon as the diagnosis of extrahepatic biliary atresia is suspected on the basis of biopsy findings and the Rose Bengal excretion studies. Conjugated hyperbilirubinaemia in infants is never a benign condition, biliary atresia should be suspected if it persists for more than 2 weeks, and patients should be submitted to surgery in all instances by 70 days of age rather than wait until 4 to 5 months of age, as is still common practice. Such early surgical intervention might cause an increased number of infants with intrahepatic lesions and intact extrahepatic ducts to be subjected to laparotomy with its attendant risks, including possible destruction of normal patent but collapsed hypoplastic ducts by indiscrete surgery (Mason, Northway, and Kohn, 1966). It is essential therefore that such cases be operated on in centres where there is the necessary expertise available, both in making a presumptive diagnosis and in assessing the condition of the bile ducts at laparotomy.

From the present study no clues emerge as to what initiates extrahepatic biliary atresia. Males predominated in this series, but as in other reports (Alagille, 1972) the sex incidence was not significant. Neither seasonal factors, adverse factors in the pregnancy or perinatal period, nor birth order have been implicated in this study. Nor could the condition be related to the age of the parents, as reported from Hawaii and Japan (Shim, Kasai, and Spence, 1974) in a study which also suggested that familial cases occurred and that the birthweights in biliary atresia were low. This was not confirmed in the present series in which prematurity and low birthweight was a feature of the hepatitis group only. The exact reason for the poor intrauterine growth in the hepatitis cases was rarely identified, but such reduction in intrauterine growth is commonly found in fetuses subjected to a massive prenatal insult, such as rubella embryopathy. There is thus no evidence that the patients with extrahepatic biliary atresia were subjected to such a cause, and it seems that the adverse factor or factors which affect only the bile ducts must be very selective whether it operates antenatally or only postnatally. Our observation that in 6 of 32 infants jaundice was not observed until the third week of life supports the contention that the lesion is acquired rather than congenital in some patients at least. These observations provide a basis for hoping that in some cases removing the diseased extrahepatic bile ducts may allow the

liver to function normally, and cause us to be cautiously optimistic about the place of hepatic portoenterostomy in the management of biliary atresia.

The study would not have been possible without the co-operation of many paediatricians and paediatric surgeons in the South of England. Many data were collected by Dr. Andrew Porter, Canterbury Hospital, and Dr. K. Cottrall, The Hospital for Sick Children, London, while Research Assistants in the Department of Child Health, King's College Hospital.

We are grateful to Mr. H. H. Nixon, and to Mr. E. R. Howard for valuable discussion. H. D. P. is supported by a grant from Maws Ltd.

REFERENCES

- Alagille, D. (1972). Clinical aspects of neonatal hepatitis. *American Journal of Diseases of Children*, **123**, 287.
- Arima, A., Fonkalsrud, E. W., and Neerhout, R. C. (1974). Experiences in the management of surgically correctable biliary atresia. *Surgery*, **75**, 228.
- Berenson, M. M., Garde, A. R., and Moody, F. G. (1974). Twenty-five year survival after surgery for complete extrahepatic biliary atresia. *Gastroenterology*, **66**, 260.
- Campbell, D. P., Poley, J. R., Bhatia, M., and Smith, E. I. (1974a). Hepatic portoenterostomy—is it indicated in the treatment of biliary atresia? *Journal of Pediatric Surgery*, **9**, 329.
- Campbell, D. P., Poley, J. R., Alaupovic, P., and Smith, E. I. (1974b). The differential diagnosis of neonatal hepatitis and biliary atresia. *Journal of Pediatric Surgery*, **9**, 699.
- Christen, H., Bau, J., and Halsband, H. (1975). Hereditary alpha-1 antitrypsin deficiency associated with congenital extrahepatic bile duct hypoplasia. *Klinische Wochenschrift*, **53**, 90.
- Danks, D. M. (1974). Discussion of pathology of the bile retention syndrome. *Postgraduate Medical Journal*, **15**, 347.
- Danks, D. M., Campbell, P. E., Clarke, A. M., Jones, P. J., and Solomon, J. R. (1974). Extrahepatic biliary atresia: the frequency of potentially operable cases. *American Journal of Diseases of Children*, **128**, 684.
- Holden, T. M. (1964). Atresia of the extrahepatic bile duct. *American Journal of Surgery*, **107**, 485.
- Javitt, N. B., Morrissey, K. P., Siegel, E., Goldberg, H., Gartner, L. M., Hollander, M., and Kok, E. (1973). Cholestatic syndromes in infancy: diagnostic value of serum bile acid pattern and cholestyramine administration. *Pediatric Research*, **7**, 119.
- Johnston, D. J., Mowat, A. P., Kohn, J., and Orr, H. (1976). *Acta Paediatrica Scandinavica*, **65** (in press).
- Kasai, M., Watanabe, I., and Ohi, R. (1975). Follow-up studies of long-term survivors after hepatic portoenterostomy for 'non-correctable' biliary atresia. *Journal of Pediatric Surgery*, **10**, 173.
- Koga, A. (1971). Morphogenesis of intrahepatic bile ducts of the human fetus. *Zeitschrift für Anatomie und Entwicklungsgeschichte*, **135**, 156.
- Landing, B. H. (1974). Considerations of the pathogenesis of neonatal hepatitis, biliary atresia and choledochal cyst—the concept of infantile obstructive cholangiopathy. *Progress in Pediatric Surgery*, **6**, 113.
- Lilly, J. R., and Altman, R. P. (1975). Hepatic portoenterostomy (the Kasai operation) for biliary atresia. *Surgery*, **78**, 76.
- Lubin, B. H., Baehner, R. L., Schwartz, E., Shohet, S. B., and Nathan, D. G. (1971). The red cell peroxide hemolysis test in the differential diagnosis of obstructive jaundice in the newborn period. *Pediatrics*, **48**, 562.
- Manthorpe, D., and Mowat, A. P. (1975). Serum bile acids in neonatal hepatitis and extrahepatic biliary atresia. *Advances in Bile Acid Research: Proceedings of the III Bile Acid Meeting*. Ed. by S. Matern, J. Hackenschmidt, P. Back, and W. Gerok. Schattauer, Stuttgart and New York.
- Mason, G. R., Northway, W., and Cohn, R. B. (1966). Difficulties in the operative diagnosis of congenital atresia of the biliary-ductal system. *American Journal of Surgery*, **112**, 183.
- Mowat, A. P. (1973). Failure of red cell haemolysis test to differentiate neonatal hepatitis from extrahepatic biliary atresia (unpublished).
- Poley, J. R., Smith, E. I., Boon, D. J., Bhatia, M., Smith, C. W., and Thompson, J. B. (1972). Lipoprotein X and the double ¹³¹I Rose Bengal test in the diagnosis of prolonged infantile jaundice. *Journal of Pediatric Surgery*, **7**, 660.
- Porter, C. A., Mowat, A. P., Cook, P. J. L., Haynes, D. W. G., Shilkin, K. B., and Williams, R. (1972). α -1 antitrypsin deficiency and neonatal hepatitis. *British Medical Journal*, **3**, 435.
- Shim, W. K. T., Kasai, M., and Spence, M. A. (1974). Racial influence on the incidence of biliary atresia. *Progress in Pediatric Surgery*, **6**, 53.
- Strauss, L., Valderrama, E., and Alpert, L. I. (1972). Bile tract anomalies: the relationship of biliary atresia to neonatal hepatitis. *Birth Defects: Original Article Series*, Vol. 8, No. 2, p. 135. National Foundation, March of Dimes.
- Thaler, M. M., and Gellis, S. S. (1968). Studies in neonatal hepatitis and biliary atresia. *American Journal of Diseases of Children*, **116**, 257.
- Zeltzer, P. M., Neerhout, R. C., Fonkalsrud, E. W. and Stiehm, E. R. (1974). Differentiation between neonatal hepatitis and biliary atresia by measuring serum-alpha-fetoprotein. *Lancet*, **1**, 373.

Correspondence to Dr. Alex P. Mowat, Department of Child Health, King's College Hospital Medical School, Denmark Hill, SE5 8RX.