

Summary

The upper intestinal microflora was studied in 10 malnourished Indonesian children using the paediatric Enterotest Capsules. Trophozoites of *Giardia lamblia* were found in 2 specimens, profuse fungal mycelia in 3, and ascaris worms and eggs in 1. In 9 patients an abnormally profuse small intestinal bacterial flora was found. Provided precautions are taken to exclude artefactual contamination of the line on its withdrawal, this is a safe and simple method for studying the upper gut flora which could be applied to field conditions since it does not require radiological facilities.

We thank Mrs. J. Beaman for expert technical assistance, and Dr. C. Beal of Hedeco Corporation for supplies of the Enterotest capsules. This work was supported by a grant from the Wellcome Trust, London.

References

- Beal, C. B., Viens, P., Grant, R. G. L., and Hughes, J. M. (1970). A new technique for sampling duodenal contents. *American Journal of Tropical Medicine and Hygiene*, **19**, 349-352.
- Gracey, M., and Stone, D. E. (1972). Small-intestinal microflora in Australian Aboriginal children with chronic diarrhoea. *Australian and New Zealand Journal of Medicine*, **3**, 215-219.
- Gracey, M., Suharjono, Sunoto, and Stone, D. E. (1973). Microbial contamination of the gut: another feature of malnutrition. *American Journal of Clinical Nutrition*, **26**, 1170-1174.
- Heyworth, B., and Brown, J. (1975). Jejunal microflora in malnourished Gambian children. *Archives of Disease in Childhood*, **50**, 27-33.
- Lancet* (1970). Classification of infantile malnutrition. A report of the Wellcome Trust International Working Party, **2**, 302-303.
- Mata, L. J., Jiménez, F., Córdón, M., Rosales, R., Prera, E., Schneider, R. E., and Viteri, F. (1972). Gastrointestinal flora of children with protein-calorie malnutrition. *American Journal of Clinical Nutrition*, **25**, 1118-1126.

MICHAEL GRACEY*, SUHARJONO, and SUNOTO

Princess Margaret Children's Medical Research Foundation, Perth, Western Australia and Department of Child Health, University of Indonesia, Jakarta, Indonesia.

*Correspondence to Dr. M. Gracey, Gastroenterological Research Unit, Princess Margaret Hospital for Children, GPO Box D 184, Subiaco, Perth, Western Australia, 6001.

Hepatic dysfunction in association with pancreatic insufficiency and cyclical neutropenia

Shwachman-Diamond syndrome

The syndrome of pancreatic achylia and cyclical neutropenia (Shwachman-Diamond syndrome), has been recognized for 13 years, though it now encompasses a far wider range of clinical abnormalities than was initially realized. In 1964 Shwachman *et al.* first distinguished these patients from those suffering from cystic fibrosis, and commented on an association of pancreatic insufficiency with growth retardation, bone marrow dysfunction, raised Hb-F levels, and galactosuria. Skeletal abnormalities were next noted, and in 1967 Burke *et al.* observed metaphyseal dysostosis in 3 cases; subsequent reports by others have recently been reviewed by McLennan and Steinbach (1974). In addition to metaphyseal disturbances, abnormal tubulations of long bones, clinodactyly, phalangeal hypoplasia, and narrowing of the sacrosciatic notches have been noted. Dys- γ -globulinaemia was next noted by Goldstein (1968) and has been described in 5 further patients (Doe, 1973), in each case involving a reduction in the serum concentrations of one or more of the immunoglobulins. As far as we can determine only one living patient with histological but not clinical evidence of liver dysfunction has previously been described (Bodian *et al.*, 1964). In a retrospective review of 18 children whose necropsies had shown exocrine hypoplasia and lipomatosis of the pancreas they noted that 11 had shown a fatty liver or cirrhosis. Cyclical neutropenia had not been shown in life in any of them. Higashi *et al.* (1967) observed inflammatory cell infiltration in the periportal tissue of the liver obtained at necropsy in a 2-year-old child with pancreatic insufficiency and cyclical neutropenia.

We presently have 4 children with this syndrome under our care as detailed in the Table. One of them (Case 1) has clinical evidence of hepatic dysfunction and is the subject of the case report.

Case report

A male, weighing 2.9 kg at birth, is the son of healthy unrelated parents. Frequent, loose, offensive stools were noted from birth, but appetite was good and there was no unusual frequency of respiratory or other infections. Height and weight remained below the 3rd centile, and he was referred (with his sister, Case 2) for investigation at the age of 9 months. On examination there were no abnormalities apart

Table Results of investigations on 4 children with pancreatic insufficiency and associated abnormalities

Case no.	Age (yrs)	Lipase* (units/0.1 ml)	Trypsin† (units/100 ml)	Neutrophils (range = 10 ⁹ /l)	Skeletal abnormality			Height & weight centile	Serum immunoglobulins (g/l)			Hepatic involvement
					Rib end expansion	Meta-physeal dysostosis	Other		IgA	IgM	IgG	
1	3.0	0.23	0.3	0.18-9.96	Present	Femora	—	<3rd	Trace	0.07	4.8	+
2	6.5	0.2	0.3	6.27-8.71	—	Femora	—	<3rd	0.18	0.78	3.8	—
3	16.0	0.11	0.23	0.23-6.82	Present	Tibia, fibula, femora	—	<3rd	5.8	0.29	16.0	—
4	7.7	0.3	5.9	0.16-9.52	—	—	Clinodactyly; hypoplasia middle phalanges 5th fingers; coxa valga	<3rd	0.54	0.37	3.8	—

*Normal >2 units/0.1 ml.

†Normal >8 units/100 ml.

from his stature and a mild degree of abdominal distension. Steatorrhoea was present (46.2 mmol fat/24 hours), and fat globules were present in the stool. After stimulation of the pancreas with pancreozymin no trypsin appeared in the duodenal juice, and the lipase level was very low (0.25 units/0.1 ml; normal >2 units/0.1 ml). Sweat electrolytes were normal on three occasions, as was xylose absorption. Hb was 11.7 g/dl and the range of white cell counts was 7.2-23.0 × 10⁹/l (neutrophils 2.6-13.3 × 10⁹/l). Platelet count was normal but has fallen to 11.7 × 10⁹/l under further observation. Hb electrophoresis showed an increase in the proportion of Hb-F (3.3%). Serum calcium, phosphorus, cholesterol, and α₁-antitrypsin levels were normal, as were urine and plasma amino acids. There were no reducing substances present in the urine.

Radiological examination showed normal lung fields and bone age, but there was expansion of the anterior ends of the ribs. At that time no other metaphyseal abnormalities were present; however by the age of 2 years dysostosis of the femoral metaphyses was noted, while the rib changes were less marked.

Immunological studies showed normal IgG levels (4.8 g/l) but reduced IgM (0.07 g/l) and only a trace of IgA. Salivary IgG was increased (0.22 g/l) but only trace levels of IgA were detected. Alanine aminotransferase levels (70 IU/l), and aspartate aminotransferase levels (135 and 179 IU/l) were high. Alkaline phosphatase was 32 KA units and serum albumin 42 g/l. At no stage over the next 4 years was he jaundiced, nor was hepatosplenomegaly observed. During this time he was given pancreatin with meals and vitamin supplements. He has remained well, his height increasing to the 3rd centile but his weight remaining

below that level. Further investigation has confirmed the continuing presence of steatorrhoea (40.7 mmol fat/24 hours), cyclical neutropenia (0.18-9.96 × 10⁹/l) and a raised aspartate aminotransferase level (76 IU/l). A needle liver biopsy taken at the age of 2 years showed variation in size of the hepatocytes and expansion of the portal tracts due to the presence of reticulin fibres (Fig.)

Discussion

We consider that this patient clearly falls within the so-called Shwachman-Diamond syndrome, and shows many of the features more recently described. The presence of a degree of portal fibrosis and continuing high serum transaminase levels, in the absence of any episode of acute liver disturbance, suggest that these findings represent chronic liver damage and should perhaps be regarded as forming part of the spectrum of the syndrome. The pathogenesis of this disorder remains obscure. It has been noted by others among sibs. It is therefore of interest that this patient's sister (Table, Case 2) has pancreatic insufficiency and other features including metaphyseal dysostosis of the femora, low IgG, short stature, and increased concentration of Hb-F (3.5%). Neutropenia, however, has not been observed despite a careful search. Her sweat test and liver function tests are normal.

Flaring of the anterior ends of the ribs was noted in 3 of the children described by Burke *et al.* (1967), and in one of those in the review of McLennan and Steinbach (1974). It is notable that these patients were under 2 years of age, as was the boy we describe and one other patient under our care with a similar finding (Table, Case 2). By the age of 4 years the ribs of both our patients had returned to normal, but metaphyseal dysostosis had become apparent. All

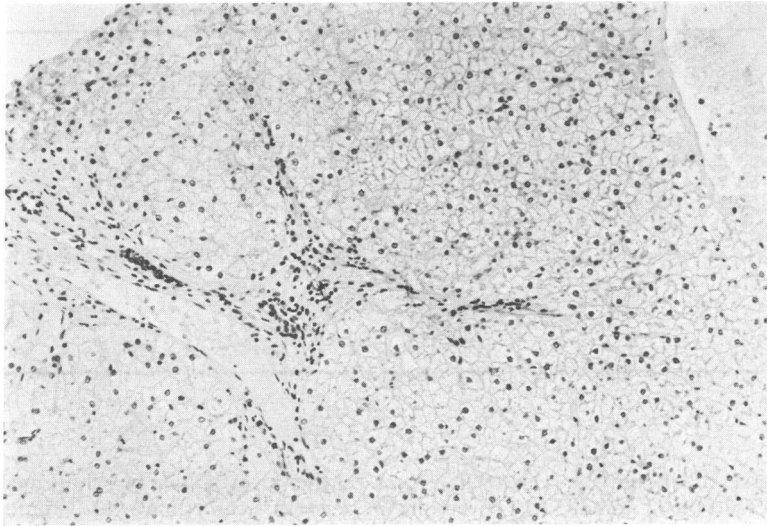


Fig. Liver biopsy of Case 1. (Haematoxylin and eosin $\times 130$.)

our 4 patients have skeletal changes and are of short stature.

The dys- γ -globulinaemias described have involved a reduction in IgA levels in all but one case, while low levels of IgG or IgM were found in 4 cases (Hudson and Aldor, 1970; Doe, 1973; McLennan and Steinbach, 1974). The patient described here shows a more complete IgA deficiency than previously described, and the other patients in the Table show the wide variation in immunoglobulin abnormalities that can occur.

This report illustrates the broad spectrum of this curious condition, and supports the contention that hepatic involvement should be regarded as a feature of the syndrome.

Summary

A patient with pancreatic insufficiency and cyclical neutropenia is described who also has evidence of hepatic dysfunction. He and 3 other patients whose findings are given emphasize the wide range of abnormalities seen in this syndrome.

We are indebted to Dr. R. Astley for reviewing the x-rays of these children and to Dr. A. H. Cameron for preparation of the liver biopsy.

References

Bodian, M., Sheldon, W., and Lightwood, R. (1964). Congenital hypoplasia of the exocrine pancreas. *Acta Paediatrica Scandinavica*, **53**, 282-293.

Burke, V., Colebatch, J. H., Anderson, C. M., and Simons M. J. (1967). Association of pancreatic insufficiency and chronic neutropenia in childhood. *Archives of Disease in Childhood*, **42**, 147-157.

Doe, W. F. (1973). Two brothers with congenital pancreatic exocrine insufficiency, neutropenia and dysgammaglobulinaemia. *Proceedings of the Royal Society of Medicine*, **66**, 1125-1126.

Goldstein, R. (1968). Congenital lipomatosis of the pancreas. Malabsorption, dwarfism, leukopenia with relative granulocytopenia and thrombocytopenia. *Clinical Pediatrics*, **7**, 419-422.

Higashi, O., Hayashi, T., Ohara, K., Honda, Y., Konno, T., Sato, Y., Yoshida, T., Dohi, S., and Takezawa, Y. (1967). Pancreatic insufficiency with bone marrow dysfunction (Shwachman-Diamond-Oski-Khaw's syndrome). *Tohoku Journal of Experimental Medicine*, **92**, 1-12.

Hudson, E., and Aldor, T. (1970). Pancreatic insufficiency and neutropenia with associated immunoglobulin deficit. *Archives of Internal Medicine*, **125**, 314-316.

McLennan, T. W., and Steinbach, H. L. (1974). Shwachman's syndrome; the broad spectrum of bony abnormalities. *Radiology*, **112**, 167-173.

Shwachman, H., Diamond, L. K., Oski, F. A., and Khaw, K. T. (1964). The syndrome of pancreatic insufficiency and bone marrow dysfunction. *Journal of Pediatrics*, **65**, 645-663.

M. J. BRUETON,* J. MAVROMICHALIS,
MARY C. GOODCHILD, and CHARLOTTE
M. ANDERSON

*Institute of Child Health, University of Birmingham,
Francis Road, Birmingham B16 8ET.*

*Correspondence to Dr. M. J. Brueton.