

SHORT REPORTS

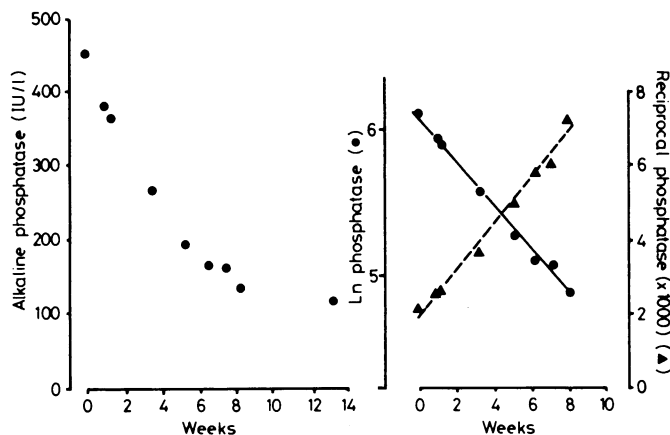
Linear decline in serum alkaline phosphatase activity during treatment of renal osteodystrophy

Raised serum alkaline phosphatase activity is important in the diagnosis of renal osteodystrophy, particularly as an indicator of secondary hyperparathyroidism. The response to treatment with vitamin D derivatives or parathyroidectomy or both is shown by declining alkaline phosphatase activity after a variable latent period.¹ The rate of decline is a convenient index of skeletal response to treatment. In addition, clinical experience has shown that hypercalcaemia tends to occur as the phosphatase activity falls to within normal limits, which necessitates frequent biochemical review in the first weeks of treatment. We describe here the use of transformed values of serum alkaline phosphatase activity to characterise these events.

Methods and results

We reviewed the records of 17 consecutive adult patients treated for renal osteodystrophy with vitamin D derivatives or subtotal parathyroidectomy or both. Details of these patients are available on request. Renal osteodystrophy was established by x-ray findings of hyperparathyroidism (periosteal erosions) or bone biopsy. Total serum alkaline phosphatase activity was assayed using a commercial kit (Boehringer), with a 95th centile value of 190 IU/l.² Phosphatase activity was plotted against time and transformed as a logarithm or reciprocal, and coefficients of linear correlation were calculated.³

Initial phosphatase activity lay between 723 and 165 IU/l; when the raw data were plotted against time the declining values gave a curvilinear relation (figure (left)). In 11 cases the logarithm and the reciprocal of



Left: Serum alkaline phosphatase activity plotted against time from onset of response to 1- α -hydroxycholecalciferol. Right: Linear decline in log transformed phosphatase activity compared with linear increase in reciprocal values.

phosphatase activity showed rectilinear relations in time, with correlation coefficients above 0.95 for both transforms (figure (right)). The latent period before the first decline in phosphatase activity during treatment with 1- α -hydroxycholecalciferol varied from one to seven weeks (mean 3.2 weeks). Phosphatase activity fell in each patient to a characteristic plateau value, from 0.46 to 0.96 of the upper limit.

The range of declining phosphatase activity from peak to plateau values may be regarded as the pathological increase, with a nominal value of 100%. Intermediate phosphatase values were recalculated as a percentage of this using the formula

$$\frac{\text{Alkaline phosphatase (t)—final (plateau) phosphatase}}{\text{Initial (peak) phosphatase—final (plateau) phosphatase}} \times 100$$

and the logarithm plotted against time. Standardised curves for each individual were compared in terms of the half time and showed a range of 1.7-9.3 weeks (mean 3.3 weeks) (n=10). The shortest value occurred after parathyroidectomy. There was no correlation between initial phosphatase activity and half time.

Five patients became hypercalcaemic at phosphatase activities between

0.55 and 1.10 of the upper limit. In four of these five hypercalcaemia occurred as the phosphatase activity fell into the normal range but at a value well above the final "plateau." The time required for the upper limit of normal to be reached could not be predicted from the starting values or the half time. Both variables were necessary for the prediction.

Comment

After an observation made during routine clinical work 17 unselected patients with renal osteodystrophy were studied; in 11 transformed alkaline phosphatase activity showed a rectilinear relation with time. This group all had evidence of secondary hyperparathyroidism. The half time shown by some patients was surprisingly short, and the maximal half time (1.7 weeks) may represent a physiological limit to the response of an osteoblast population.⁴ The half time is potentially useful in indicating an optimum dose of vitamin D derivatives, with three weeks used as a model half time for treatment. The most desirable rate of response to treatment is not yet known.

The rectilinear behaviour of phosphatase activity permitted a prediction of the time at which it dropped to the upper limit of the normal range; in four instances this coincided with, or just preceded, the development of hypercalcaemia (no dose adjustments were made during this study). Hypercalcaemia may therefore be predictable, and a review of blood variables can potentially be timed to coincide with the period of greatest risk.

We thank Dr R P Burden, some of whose patients were included in this study, and Mrs J Hayes and Mrs L Hodgson for typing the manuscript.

¹ Kanis JA, Cundy T, Earnshaw M, *et al.* Treatment of renal bone disease with 1-alpha hydroxylated derivatives of vitamin D₃. *Q J Med* 1979;48:289-322.

² Hausamen T-U, Helger R, Rick W, Gross W. Optimal conditions for the determination of serum alkaline phosphatase by a new kinetic method. *Clin Chim Acta* 1967;15:241-5.

³ Gore S. Assessing methods: transforming the data. *Br Med J* 1981;283:548-50.

⁴ Walton RJ, Preston CJ, Russell RGG, Kanis JA. An estimate of the turnover rate of bone-derived plasma alkaline phosphatase in Paget's disease. *Clin Chim Acta* 1975;63:227-9.

(Accepted 4 October 1982)

Renal Unit, City Hospital, Nottingham

ERIC J WILL, BM, MRCP, senior registrar (now consultant renal physician, St James's University Hospital, Leeds LS9 7TF)
MARTIN S KNAPP, MD, FRCP, consultant physician
DAMIEN MCGIVERN, MB, MRCP, medical registrar

Albendazole in hydatid disease

Surgery is usually successful in the removal of uncomplicated primary cysts, but the management of disseminated or recurrent hydatid disease is a much greater problem.¹ The first report of the clinical use of mebendazole was encouraging,² and good experimental evidence of its potency exists. Some subsequent workers found many patients resistant to treatment. The reason for this is probably the very poor absorption of mebendazole.³ Albendazole is another benzimidazole compound which at least in animals has much better absorption properties.⁴

Patients, treatment, and results

Four patients in whom surgery was decided against owing to multiple cysts, advanced age, or outright refusal of surgery were treated with albendazole 10 mg/kg/day in two divided doses. The first patient presented with chest and abdominal pain due to multiple recurrent mediastinal, pleural, pulmonary, pancreatic, and retroperitoneal hydatid cysts clearly shown by CT scan, and the second patient ruptured her large hepatic cyst into the pleural cavity as a result of an injury. The third patient's hepatic cysts were detected by an antenatal ultrasound scan, but in retrospect she had suffered back and loin pain for several years. The final patient suffered

abdominal pain, virtual obstruction of the rectum, and dyspareunia due to two recurrent pelvic hydatid cysts. She had been treated with mebendazole 50 mg/kg for one year without benefit.

All patients were monitored for bone marrow, hepatic, or renal toxicity. Two patients became feverish within 48 hours of beginning treatment; the only other symptoms complained of were pain in the area of the cyst in one patient and headache and nausea in another.

One of our patients failed to respond to two months' albendazole treatment. She developed an anaphylactic reaction two weeks after stopping the drug and was admitted to another hospital, where laparotomy failed to detect obvious rupture of the cyst and it was removed.

In the remaining three patients there was evidence of improvement. A repeat CT scan in case 1 showed a dramatic reduction in size of all cysts after one month's treatment. In the second patient an ultrasound scan showed pronounced reduction in the size of the cyst, and regular drainage of 100 ml/day from an intercostal chest drain became minimal during the first week of treatment. In the remaining case the tension of the cysts (easily assessable on rectal examination) was noticeably reduced at one month; the drug was continued for a second month, after which there was pronounced symptomatic improvement. Repeat CT scan showed reduction in cyst size and loss of the spherical shape of the cysts. On rectal examination the cysts were found to be soft, rather like a half-filled hot-water bottle.

Three of the four patients had a positive complement fixation test result (1/32) before treatment; and two showed a two-titre improvement in hydatid complement fixation tests after treatment. In the remaining patient, who failed to improve, there was initially an encouraging fall in the complement fixation test result, but this returned to the pretreatment value at the end of two months' treatment.

The blood concentrations of albendazole sulphoxide (a metabolite with anthelmintic activity) were measured by high-performance liquid chromatography.⁵ The parent drug albendazole was not detected. The mean of peak albendazole sulphoxide concentrations was just below 1000 µg/l (table). The

Blood concentrations of albendazole sulphoxide in the four patients

Case No	Dose	Administration times (hours)	Day of treatment	Sample time (hours)	Albendazole sulphoxide (µg/l)
1	400 mg twice daily	0 + 7	8	1	1830
				4	1820
				7	1330
2	400 mg twice daily	0 + 7	5	5	670
				1	50
3	400 mg twice daily	0 + 7	5	1	160
				2	340
				4	880
				8	280
				12	20
				21	20
				24	460
4	400 mg morning, 200 mg evening	0 + 7	5	1	170
				2	430
				4	260
				8	460
				12	140
				21	30
				24	420

two serial studies suggest that albendazole sulphoxide is rapidly eliminated from plasma, and serum concentrations after one week's treatment were little different from those attained during the first 24 hours.

Comment

Albendazole produced radiographic evidence of cyst regression in three of our first four patients treated with this drug. In one patient continuous external drainage of cyst fluid stopped on beginning treatment. Subsequent observation at three to six months showed no evidence of recurrence but it was too early to assess long-term results.

The serological improvement in treated cases was also encouraging. The serum concentrations of albendazole sulphoxide achieved at 10 mg/kg were some one hundred times better than would be expected with the same dose of mebendazole.

The speed of shrinkage of cysts in a solid structure such as the liver may well be slower than for cysts in other sites. The duration of treatment in the former may need further consideration. The concentrations of albendazole achieved in these cysts is as yet unknown.

Albendazole has been shown to be teratogenic and embryotoxic in some animals and so must not be used in pregnancy, and prolonged treatment should be avoided. Frequent monitoring of hepatic, renal, and bone marrow function is indicated during treatment. Albendazole is available as a gastrointestinal anthelmintic as a single 400 mg

treatment but does not have a product licence for the treatment of hydatid disease.

We are grateful to Dr John Morris (Bridgend General Hospital) and Professor Lennard Jones (the London Hospital) for allowing us to treat their patients, and to Dr D Cox, Dr H Skene-Smith, and the staff of the CT scanning unit, Queen Elizabeth Hospital, Birmingham.

- Mottaghion H, Saidi F. Postoperative recurrence of hydatid disease. *Br J Surg* 1978;**65**:237-42.
- Bekhti A, Schaaps JP, Capron M, Dessaint J-P, Santoro F, Capron A. Treatment of hepatic hydatid disease with mebendazole: preliminary results in four cases. *Br Med J* 1977;ii:1047-51.
- Morris DL, Gould SE. Serum and cyst concentrations of mebendazole and flubendazole in hydatid disease. *Br Med J* 1982;**285**:175.
- Marriner SE, Bogan JA. Pharmacokinetics of albendazole in sheep. *Am J Vet Res* 1980;**41**(7):1126-9.
- Bogan JA, Marriner SE. Analysis of benzimidazoles in body fluids by high performance liquid chromatography. *J Pharm Sci* 1980;**69**(4):422-3.

(Accepted 6 October 1982)

General Hospital, Birmingham B4 6NH

D L MORRIS, MB, FRCS, research fellow
P W DYKES, MD, FRCP, consultant gastroenterologist

Overseas Medical Division, Smith Kline and French Laboratories, Welwyn Garden City, Herts AL7 1EY

B DICKSON, MB, BS, regional medical director

University Department of Veterinary Pharmacology, Glasgow

S E MARRINER, MRCVS, PHD, research fellow
J A BOGAN, MSC, PHD, reader in veterinary pharmacology

Queen Elizabeth Hospital, Birmingham B15 2TH

F G O BURROWS, FRCS, FFR, consultant radiologist

Streptococcus pyogenes as probable cause of dysentery

Apart from *Staphylococcus aureus* no spherical bacteria are known to cause diarrhoea or dysentery.¹ I report a case of dysentery in which *Streptococcus pyogenes* was thought to be the causative organism.

Case report

A 54-year-old Caucasian woman developed colicky abdominal pain and diarrhoea with blood and mucus. A faecal specimen was liquid, consisting mostly of blood and mucus with only a small amount of faecal material. On microscopy no cyst, protozoa, ova, or helminths were seen but pus cells and red blood cells were plentiful. Selective culture procedures for all probable enteric pathogens (*Salmonella*, *Shigella*, *Campylobacter*, *Yersinia*, and *Staphylococcus aureus*) yielded negative results. As she was still passing blood and mucus the possibility of a ruptured abscess in the rectum or gut was considered. The specimen was therefore cultured on routine non-selective blood-agar plates and incubated aerobically and anaerobically. This produced heavy growths of *Str pyogenes* (Lancefield group A) in almost pure cultures with a few colonies of *Escherichia coli*.

Another sample of faeces and a rectal swab were obtained on the fifth day of her illness and cultured on selective media and blood-agar plates as before. Both specimens produced heavy growths of *Str pyogenes* and no other pathogen on the blood-agar plates, while no pathogen was grown on the selective media; the identity of *Str pyogenes* was confirmed repeatedly using standard laboratory techniques.² The organism was sensitive to penicillin and erythromycin. She was given 1 MU benzylpenicillin intramuscularly followed by a 10-day course of phenoxymethylpenicillin and erythromycin, both 500 mg by mouth four times daily.

Throughout her illness she had no clinical signs or symptoms other than diarrhoea. Thorough clinical examination, including rectal and vaginal examinations, and detailed inquiries about contacts, foods, travel abroad, history of abdominal problems, and prior use of antibiotics did not yield any useful information on the cause or source of her illness. Blood counts, haemoglobin concentration, and erythrocyte sedimentation rate were within normal limits. Swabs from her nose, throat, axillas, inguinal regions, and vagina were cultured: the vaginal swab produced a light growth of *Str pyogenes* with a moderate amount of normal flora while the others grew only normal flora. Sera obtained on the fifth day of illness and 10 days later contained normal titres of antistreptolysin O antibody.

She started passing formed stools normal in appearance and frequency two days after beginning antibiotic treatment. She had no subsequent