

SHORT REPORTS

Simple drug delivery system for use by young asthmatics

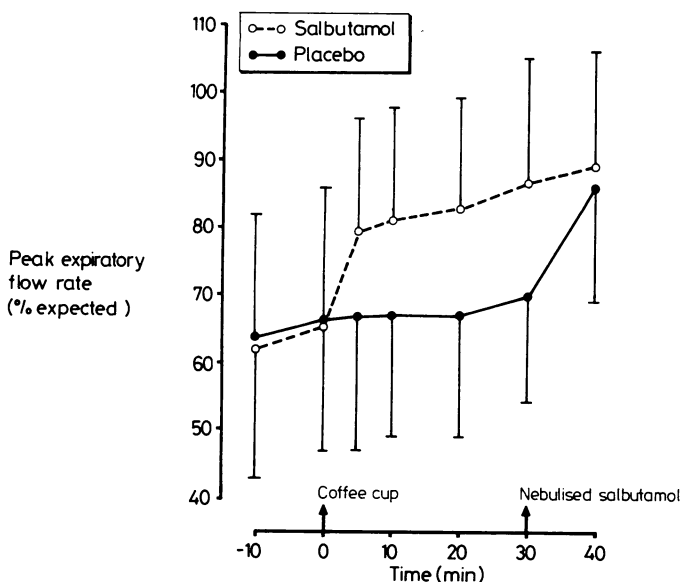
Young asthmatic children find it difficult to coordinate the use of beta agonist inhaler devices, particularly during acute attacks of airways obstruction.¹ This problem may be overcome by the use of nebuliser systems² but these are expensive, cumbersome, and not widely available for home use. Alternatively, a standard disposable coffee cup with a hole in the bottom for the metered aerosol may be applied to the face of a young child with asthma, acting as an extension tube.³ Our aim was to confirm the clinical observation that even without the child's cooperation this system would allow sufficient drug to enter the airways to achieve useful bronchodilatation.

Patients, methods, and results

Twelve asthmatic children aged 3.7 to 7.8 years (mean 5.5 years) participated in the study. Two were assessed while they were in hospital with an acute attack of asthma; the rest were seen during the interval phase between acute episodes. Baseline measurements of peak expiratory flow rate were recorded 10 minutes apart. Then a hole was made in the bottom of a disposable insulated coffee cup for the insertion of a metered aerosol and the open end of the cup was applied to the child's face. The nose was gently pinched to ensure mouth breathing. We administered 10 puffs of either placebo or salbutamol (0.1 mg per puff) at the rate of one puff every 10 seconds; administration was double blind. No attempt was made to coordinate activation with inspiration nor did we ask the children to make a deep inspiratory effort. Peak expiratory flow rates were recorded 5, 10, 20, and 30 minutes after start of inhalation. Each child then inhaled a 2 ml nebulised solution containing 2.5 mg salbutamol. A final measurement of peak expiratory flow rate was made at 40 minutes. Pulse rates were measured before each measurement of peak expiratory flow rate.

The procedure was repeated on the second day with the other treatment.

The response to salbutamol was dramatic and rapid compared with the gradual and non-significant response to placebo (figure). At 5, 10, 20, and



Mean (SD) peak expiratory flow rate of 12 children with asthma expressed as a percentage of expected before and after administration of placebo or salbutamol via disposable cup delivery system. In both cases nebulised salbutamol was given after the 30 minute recording.

30 minutes the improvement from second baseline was significantly greater after salbutamol than placebo (p values all < 0.001). After nebulised salbutamol, we found a slight but significant improvement in those who had inhaled salbutamol from the cup ($p < 0.01$) but a large improvement in those who had received placebo ($p < 0.001$). The mean rise in pulse rate after inhaling salbutamol from the coffee cup was 4 beats/min with no change after placebo. Both groups showed significant increases in average pulse rates after nebulised salbutamol, 8 beats/min in the placebo group ($p < 0.01$) and 6 beats/min in the treated group ($p < 0.02$).

Both inpatients responded to treatment with the coffee cup delivery system, with improvement in peak expiratory flow rate from baselines of 33% and 67% predicted to 55% and 81% predicted. After 2.5 mg of nebulised salbutamol, the readings were 58% and 81% predicted respectively.

Comment

Delivery of 1 mg salbutamol using a disposable coffee cup was simple, cheap, and effective and did not necessitate the child's cooperation. Over two years one of us (JGD) used this system to treat more than 50 children while they were in hospital with acute asthma. In most cases the clinical outcome was good and only a few children failed to respond and required nebulised treatment. A formal dose response curve was not performed but experience suggested that 10 puffs of salbutamol (total dose 1 mg) was clinically effective and without significant toxicity. The dose offered was considerably lower than the standard oral or nebulised doses for children.

This method of delivering bronchodilators does not replace the need for nebulised treatment in severe attacks of asthma. It should, however, enable many children unable to manage a rotahaler during acute asthma attacks to be treated successfully at home. Obviously, if there is inadequate response the children need reassessment, which will almost certainly include nebulised sympathomimetics delivered via a compressor pump.

Financial support was provided by the Asthma Research Council and Nestle Paediatric Travelling Fellowship (Australia). Allen and Hanbury provided the unlabelled aerosols.

¹ Landau LI. Out-patient evaluation and management of asthma. *Pediatr Clin North Am* 1979;26:581-601.

² Lenney W. Nebulised salbutamol in treatment of acute asthma in children. *Lancet* 1978;ii:440.

³ Morén F. Drug deposition of pressurised inhalation of aerosols. Influence of actuator tube design. *International Journal of Pharmaceutics* 1978;1:205-12.

(Accepted 7 April 1983)

Department of Child Health, University Hospital, Nottingham NG7 2UH

R L HENRY, FRACP, research fellow

A D MILNER, MD, FRCP, professor of paediatric respiratory medicine

Walsgrave Hospital, Coventry

J G DAVIES, MRCP, consultant paediatrician

Correspondence to: Professor A D Milner, Department of Child Health, E Floor, East Block, University Hospital, Nottingham NG7 2UH.

Cellulose granulomas in the lungs of a cocaine sniffer

Pulmonary granulomatosis is well recognised in drug addicts who inject intravenously drugs intended for oral use, talc filler being the most common offending agent.¹² We describe foreign body granulomas in the lungs of a cocaine sniffer.

Case report

A 26 year old university student complained of abdominal colic, breathlessness on exertion, and cough; bilateral miliary opacities were seen in chest radiographs. Fibreoptic transbronchial lung biopsy specimen showed foreign body granulomas containing numerous birefringent needle shaped particles measuring up to 120 μ m in length (figure). A relation to blood vessels could not be established but the particles were assumed to be talc crystals reaching the lungs after intravenous injection of drugs intended for oral use.

The patient freely confessed to taking drugs but vehemently denied injecting himself; he claimed that his drug abuse was limited to sniffing cocaine. Assuming that the needle shaped birefringent particles represented the plate like crystals of talc cut across, it was reasoned that they were too heavy to have reached the pulmonary alveoli by inhalation and that the