

# Crohn's disease of the large intestine

H. E. LOCKHART-MUMMERY AND B. C. MORSON

*From St. Mark's Hospital, London*

**EDITORIAL SYNOPSIS** This paper sets out clearly the clinical and pathological features of Crohn's disease of the large intestine as seen in a series of 75 patients. The distinctions from ulcerative colitis are pointed out and the transmural nature of the inflammation in Crohn's disease emphasized, also the importance of anal lesions, which occurred in 81% of the cases. Absence of the typical sarcoid reaction on one histological examination does not rule out Crohn's disease. This combined clinical and pathological study makes it clear that Crohn's disease is a different disease from ulcerative colitis and that the two do not occur together in the same patient.

Since the clinico-pathological syndrome now called Crohn's disease was described by Crohn, Ginzburg, and Oppenheimer in 1932, the original concept that this was a disorder solely affecting the terminal part of the small intestine has been gradually abandoned. However, it still does not seem to be widely appreciated how frequently and extensively the large intestine and anal region can be affected, for many such cases are wrongly diagnosed as 'colitis' or 'ulcerative colitis'. There are, however, not only pathological differences, but also distinct clinical and radiological features, which in most cases clearly separate Crohn's disease from other inflammatory disorders of the large intestine.

These differences have been increasingly recognized in the literature in recent years (Brooke, 1959; Morson and Lockhart-Mummery, 1959a; Lindner, Marshak, Wolf, and Janowitz, 1963). In 1960, we reported on 25 patients with Crohn's disease of the large intestine seen at St. Mark's Hospital, with special emphasis on the pathological differences from ulcerative colitis (Lockhart-Mummery and Morson, 1960). Since then, many more patients with Crohn's disease of the large intestine have been seen and treated at St. Mark's Hospital and the purpose of this paper is to describe a larger series of 75 patients (including the 25 previously reported) with greater emphasis on the clinical features and diagnosis.

## NOMENCLATURE

In Great Britain and Europe the eponymous term 'Crohn's disease' is used synonymously with the expressions 'terminal ileitis' and 'regional enteritis' favoured in the American literature. Recently, however, the term 'Crohn's disease' has been

appearing in some American publications (Wolf and Marshak, 1962). Since the original description of terminal ileitis in 1932 a great variety of names has been used to describe the one disease as it affects different parts of the gastro-intestinal tract. For example, Crohn and Yarnis (1958) give the terms 'terminal ileitis', 'regional ileitis', 'regional enteritis', 'chronic cicatrizing enteritis', 'ileo-jejunitis', 'chronic ulcerative enteritis', and 'ileo-colitis'. Others have used the expressions 'regional colitis' and 'segmental colitis' while the most recent for disease of the colon is 'granulomatous colitis' (Lindner *et al.*, 1963). In other publications Crohn's disease has masqueraded as 'sarcoid' or 'sarcoidosis' of a segment of the gastrointestinal tract. Sarcoid is a word which should only be used to describe the particular type of histological reaction which is seen, for example, in sarcoidosis, beryllium poisoning, and Crohn's disease; there is no evidence that sarcoidosis ever involves the gastrointestinal tract except possibly the stomach (Fahimi, Deren, Gottlieb, and Zamcheck, 1963) and even this is controversial.

It is important that inflammatory diseases of the large intestine should be more accurately classified and differences in the pathological, clinical and radiological appearances of each recognized (Barron, Jarkowski, Ruel, and Meyers, 1963; Ferguson, Spencer, and Kirsner, 1963). An important step forward would be an agreed nomenclature, and we make a strong plea for the adoption of 'Crohn's disease' rather than 'granulomatous colitis'. The latter expression indeed makes the distinction from ulcerative colitis but fails to emphasize that it has the same pathology as that described by Hadfield (1939) for the clinical condition described by Crohn and his colleagues in 1932.

## ANATOMICAL LOCATION OF DISEASE

The same classification has been adopted as in our previous paper (Lockhart-Mummery and Morson, 1960). (Five cases are not classified as they were treated medically, and there is no certainty about the extent of disease.)

1 Diffuse involvement of most or the whole of the large intestine in 41 patients (a) with disease of the terminal ileum (20 patients) and (b) without disease of the terminal ileum (21 patients).

2 Strictures of the large intestine in 18 patients (a) with single segments of diseased bowel (nine patients) and (b) with multiple strictures separated by areas of normal intestine (nine patients).

3 Disease confined to the distal large intestine, that is, the sigmoid colon, rectum, and anal canal (11 patients)

Figure 1 illustrates the extent of bowel involved in patients with diffuse disease, Fig. 1a showing those with associated disease of the terminal ileum and Fig. 1b those without ileal disease. We have included in Fig. 1a three patients with recurrent disease after previous right hemicolectomy. We should emphasize that in nearly all these patients with diffuse involvement of the large bowel there is seldom such complete mucosal disease as in ulcerative colitis.

There are nearly always small patches of remaining normal mucosa, and this is seen so frequently (and so rarely in ulcerative colitis) that it can be regarded as characteristic of Crohn's disease.

Figure 2 illustrates the extent of disease in the 18 patients with one or more relatively short segments of involved bowel. Figure 2a are those with only a single segment of diseased bowel, one being a 'recurrence' after previous right hemicolectomy, while in Fig. 2b the distribution of multiple strictures separated by extensive areas of normal bowel is illustrated. One of these was a recurrence and two of them had involvement of the terminal ileum in continuity. The rectum was normal in all 18 patients with single and multiple strictures of the large bowel.

The remaining 11 patients had disease of the distal large bowel, and Fig. 3 indicates diagrammatically the extent of the disease. Ten of them had disease of the distal sigmoid colon and rectum, in two of whom the appendix was found on microscopic examination to be affected. In most of these 10 patients the disease appeared to be most severe in the rectum, and became patchy and less intense more proximally, fading to normal bowel in the sigmoid colon. The last patient, a young girl, had severe disease which appeared to be confined to the lower third of the rectum and anal canal, the bowel above that level

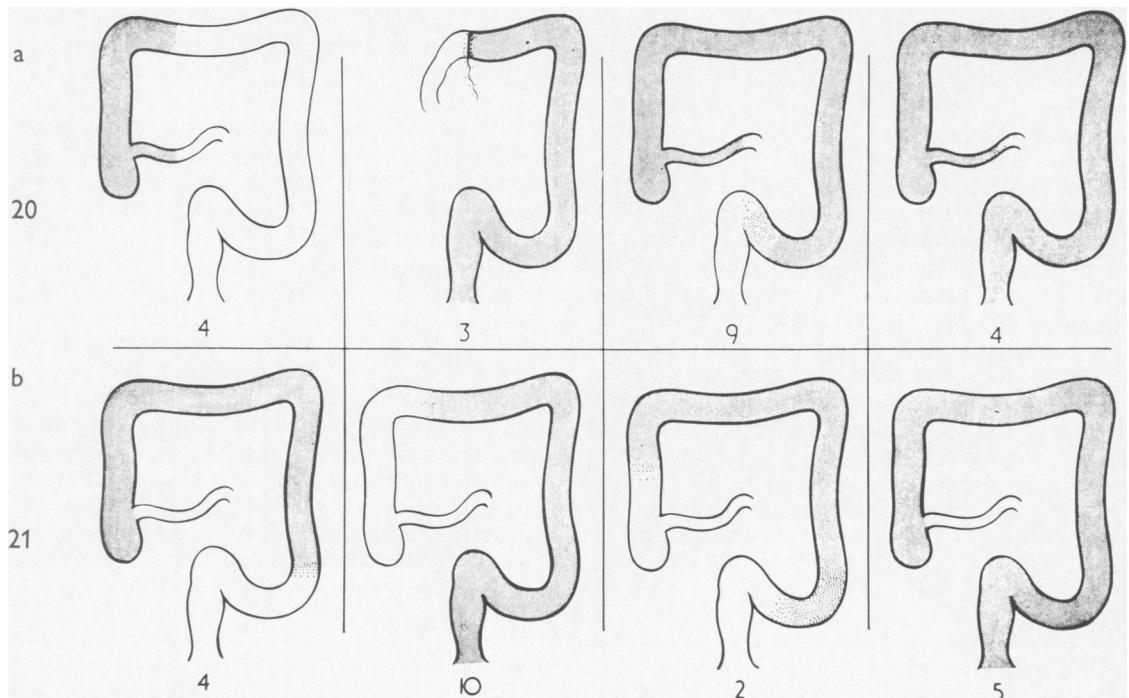


FIG. 1. Anatomical location of disease in 41 patients with diffuse involvement of most or the whole of the large intestine; (a) those with disease of the terminal ileum, and (b) those without. The numbers in each group and subgroup are indicated.

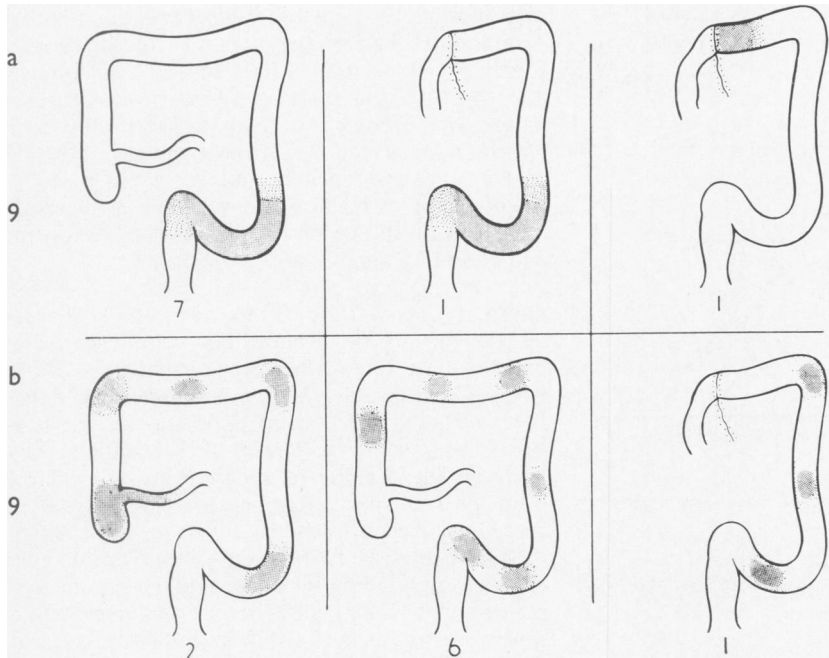


FIG. 2. Anatomical location of disease in 18 patients with segmental involvement; (a) those with a single diseased segment, and (b) those with multiple diseased segments. The numbers in each group and subgroup are indicated.

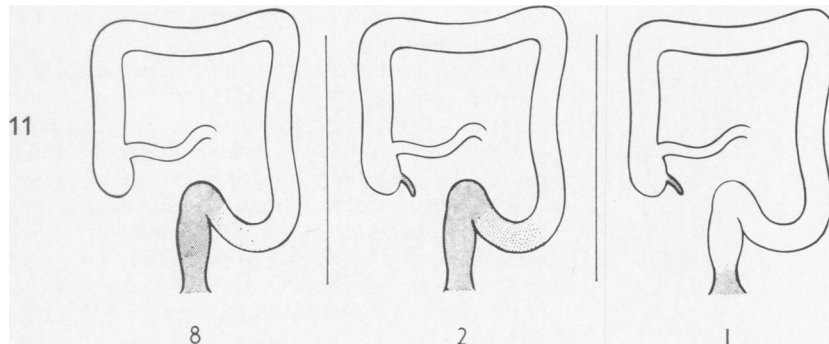


FIG. 3. Anatomical location of disease in 11 patients with involvement of the distal large bowel. The appendix was also involved in three of these.

being normal macroscopically and microscopically; but the appendix contained sarcoid foci. These cases with disease involving only the distal large bowel seem to form a definite group of great clinical and pathological interest. One of them is known to have had the disease for over 20 years before excision was carried out, yet it still remained confined to the rectum and sigmoid colon.

It will be seen that of these 75 patients with Crohn's disease of the large bowel only 22 (about 30%) had associated disease of the terminal ileum at any time during their illness. Moreover, in only 38 (about 50%) was the rectum involved, so that half the patients might be expected to show normal appearances on sigmoidoscopy.

#### CLINICAL ANALYSIS

**AGE** The age incidence is greatest in the second and third decades, but a surprising number of patients presented with the disease in their later years, and some were past their sixtieth year when first seen (Fig. 4). The youngest patients were a boy and a girl both aged 10 and the eldest was a woman whose symptoms started at the age of 70. It will be seen from Fig. 4 that there is little difference between the sexes in the age pattern.

The age pattern differed from that reported for Crohn's disease of the ileum (quoted by Crohn and Yarnis, 1958), in that a higher proportion of our patients were middle-aged or elderly.

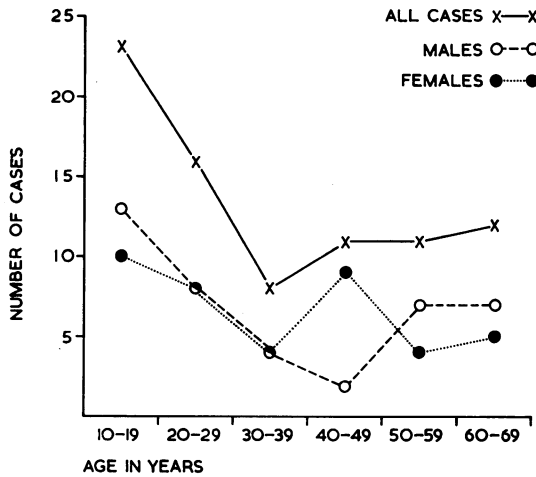


FIG. 4. Graph of the age incidence for each sex separately and together.

**SEX** The sex incidence was equal: 37 females and 38 males.

**SYMPTOMS** The incidence of clinical features is summarized in Tables I and II.

TABLE I

PERCENTAGE INCIDENCE OF CLINICAL FEATURES

Diarrhoea	88
Anal lesions	81
Loss of weight	65
Abdominal pain	45
Rectal bleeding	45
Anaemia	20
Palpable mass	8
Malaise and weakness	15

TABLE II

FIRST SYMPTOMS

Diarrhoea	52%
Anal lesions	27%
Abdominal pain	13%
Rectal bleeding	5%

Diarrhoea was the most frequent symptom and occurred at some stage in 85% of patients. In more than half it was the main symptom which brought the patient to hospital. Sometimes the diarrhoea was continuous and severe, but in others it was intermittent and the history extended over many years. It was often accompanied by abdominal pain, particularly in those patients with involvement of the proximal colon and terminal ileum, and by rectal bleeding in patients whose disease was mainly distal in distribution. Abdominal pain was the most frequent symptom after diarrhoea, occurring in 45% of all patients, and though usually accompanied by

diarrhoea, this was not invariable. In 13% abdominal pain was the first symptom of the disease. Rectal bleeding was mentioned as frequently as pain, in about 45%, but in nearly every patient was accompanied by diarrhoea or pain, and in only four patients was it the dominant symptom. Loss of weight was very common, and was noted by 65%. A complaint of malaise and weakness was noted, most often in those who had severe diarrhoea, pain, and loss of weight.

**PHYSICAL EXAMINATION** There was nothing characteristic on general examination although many patients were thin with recent weight loss. Those who had active disease when admitted were sometimes pyrexial, and looked tired and ill, but it is very exceptional for patients to present with a really acute episode leading to a dangerously ill clinical state, or requiring emergency surgery, as seen in acute toxic ulcerative colitis.

Several looked sallow and were considerably anaemic, and had minor septic skin lesions, such as multiple small boils and septic spots, but none had a full pyoderma. None of this series had arthritis or synovitis, but we have since seen these complicating Crohn's disease of the colon, and do not doubt that they can occur. One of our patients had a classical erythema nodosum.

In most patients, abdominal examination was negative, and none was admitted with toxic dilatation of the colon. Many were tender over the course of the affected bowel, and in some this could be felt as a tender thickening. In addition six patients were found to have a definite mass on examination, five being felt abdominally and one bimanually. These were subsequently operated on when five were found to have one or more localized affected segments, and one was an example of diffuse large-bowel disease with particularly active disease in the sigmoid colon. The finding of such a mass led in many cases to erroneous diagnosis, a point which will be discussed later and under differential diagnosis.

**ANAL LESIONS** Figures 5 and 6 illustrate the typical appearances of the anal lesions. The high incidence of anal lesions in patients with intestinal Crohn's disease has been stressed before (Crohn and Yarnis, 1958; Morson and Lockhart-Mummery, 1959b; Appleman and Jackman, 1962; Davis, 1962). In predominantly large bowel disease the incidence was about 70% in the 25 cases previously reported (Lockhart-Mummery and Morson, 1960). Sixty-one of the 75 patients analysed here had ulceration or infection around the anus at some stage of the illness, which is an incidence of over 80%. All except five of the 41 with diffuse disease had an anal lesion

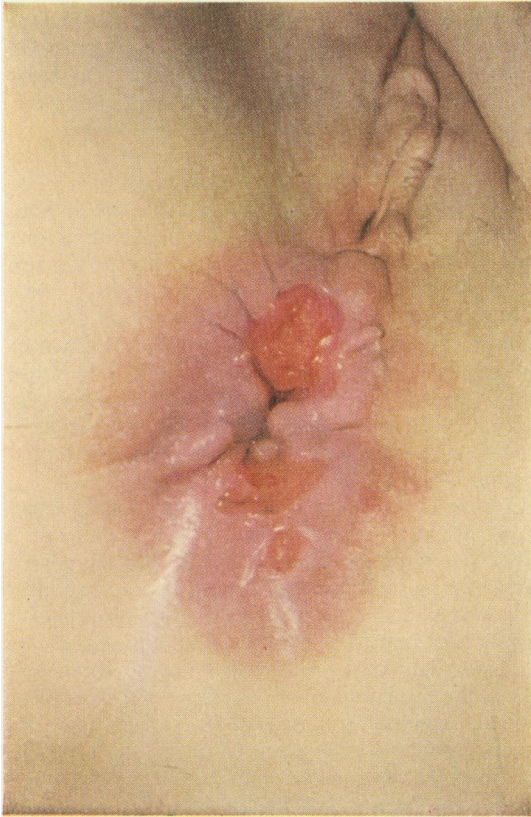


FIG. 5

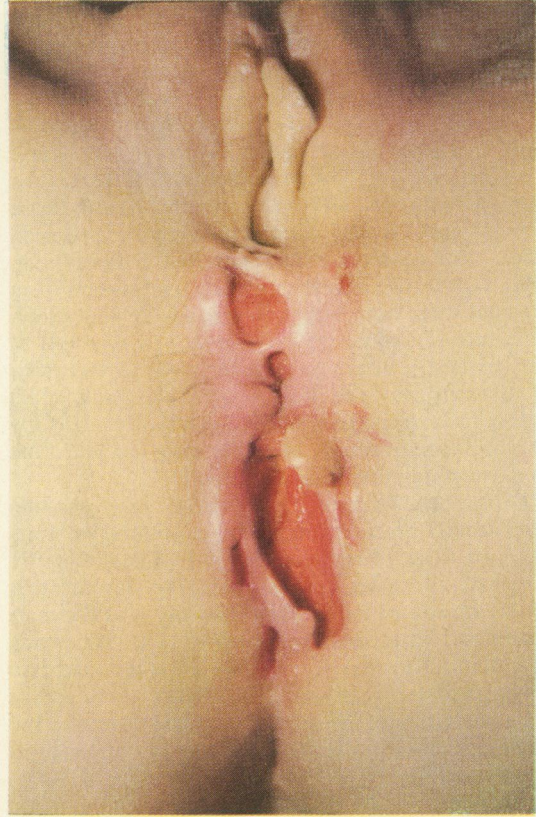


FIG. 6

FIGS. 5. and 6. *Two examples of anal ulceration in Crohn's disease of the large intestine. The patient whose anal lesion is illustrated in Fig. 5 had disease confined to the sigmoid and rectum, while the patient of Fig. 6 had diffuse involvement of most of the large intestine.*

(87%), there being no marked difference in incidence between those with and those without involvement of the terminal ileum. Of the group with single or multiple strictures, 10 of 18 had an anal lesion (about 60%), whereas all the patients with disease confined to the rectum and lower sigmoid had anal lesions and in most of this group they were florid and present throughout the course of the disease.

For comparison, we have recently analysed the incidence of anal lesions in over 100 patients with ulcerative colitis submitted to surgery in this hospital, the diagnosis being confirmed by pathological examination of the removed bowel. We found that 23% of them had a lesion at the anus at some stage of their illness. In most of them, a painful acute anal fissure had formed, and in others a fistula followed an abscess. In only one patient was marked anal oedema and ulceration seen, and this did not have the destructive course and indolent appearance that is so frequent in Crohn's disease.

We have used the rather vague term 'anal lesion'

deliberately, thus including various conditions which can be found by inspection alone. Probably the most common lesion was an anal fissure, but its appearance usually differed from simple painful fissure. Often more than one fissure was present, and they were as frequent anteriorly and laterally as in the dorsal position. More characteristically, they had a curious indolent and undermined appearance, being broader and shallower than a simple anal fissure. Severe pain was seldom a feature, though anal discomfort and soreness were common. Many were accompanied and surrounded by an unusual degree of oedema, which led to large anal tags that made the fissure difficult to see. In a few patients, particularly the more elderly, the peri-anal region had a curious dusky appearance, with several small shallow radiating fissures between oedematous folds. Other patients presented with peri-anal or ischio-rectal abscesses, which after spontaneous rupture or surgical incision led to a persisting anal fistula. Some of these did not differ clinically from ordinary

pyogenic fistulae-in-ano, and both low-level and more complex fistulae were seen. Others, however, presented an indolent appearance or a lack of induration similar to that seen in tuberculosis.

The anal lesion that we have come to regard as most characteristic of large bowel Crohn's disease is ulceration which has been seen most frequently in patients with active disease involving the distal sigmoid and rectum, but was not confined to such cases. The ulcers are indolent and undermining, often with a thin purulent exudate, and extend from the anal verge both outwards and up the anal canal. They have varied in size from about  $\frac{1}{2}$  in. diameter to very extensive ulcers passing forwards to the vulva or outwards to the ischial tuberosity and often deeply to involve the ischio-rectal fat, destroying the anal sphincter mechanism and leading in some cases to a horrifying degree of ulceration.

Crohn and Yarnis (1958) note that perianal fistulae may precede abdominal symptoms by many years in cases of regional ileitis. In 20 of these 75 patients (27%), an anal abnormality was the first manifestation of the disease. The lesion at the anus sometimes preceded other symptoms by many months and in one young man by three years. In other patients, the lesion at the anus occurred during the course of the illness, sometimes insidiously, but in others more manifestly, often as the first sign of fresh activity of the colonic disease. In seven patients the lesion at the anus was the dominant feature of the disease, anyway for some months; and in two of them the discomfort caused by the anal ulceration remained the most distressing symptom throughout the entire illness.

The clinical course of these anal lesions varied considerably. In most patients, the anal lesion remained active until the large bowel disease had been successfully excised surgically; even then local surgery was necessary before complete healing. Other patients had anal surgery carried out (usually for a painful fissure or an abscess) while active Crohn's disease was present in the bowel; in them, the wounds usually became indolent and failed to heal until definitive treatment of the large bowel disease was undertaken. In a few other patients anal lesions healed spontaneously, usually in association

with clinical remission of other symptoms, whether spontaneous or induced by medical treatment. But in others, clinical remission of abdominal symptoms did not lead to improvement in the anal condition, and most of these relapsed and required surgery.

**RECTAL EXAMINATION AND SIGMOIDOSCOPY** The results are seen in Table III. In addition to anal inspection, rectal and sigmoidoscopic examinations were done in every one of these patients and many of them were repeatedly sigmoidoscoped during their illness. In those in whom the disease was entirely confined to the more proximal bowel, with rectum and sigmoid unaffected, sigmoidoscopy was often completely normal. In some of these patients the rectal mucosa was within normal limits or slightly hyperaemic but definite pus was noted in the lumen as an indication of more proximal disease.

In a few of those in whom the rectum was diseased it was noted to be narrowed on palpation with a thickened, nodular, indurated wall. On sigmoidoscopy the most frequent finding was an irregularly thickened and congested mucosa with pronounced oedema, leading to a 'cobble-stone' appearance, as is seen in many of the excised specimens. Abnormalities in the rectum were often patchy with islands of normal intervening mucosa. In some cases, an irregular oedema with scattered ulcers was found in the lower rectum, while above 10 cm. or so the ulcers were larger and more numerous, the oedema greater and the bowel rigid and narrowed. Frank pus in the lumen of the bowel was a frequent finding.

We cannot agree with the statement by Lindner *et al.* (1963) that there are no distinct sigmoidoscopic findings that distinguish Crohn's disease from ulcerative colitis. In our experience, it is only occasionally that the sigmoidoscopic changes seen in Crohn's disease closely resemble those of ulcerative colitis.

**ABDOMINAL FISTULAE** A feature which can be regarded as characteristic of Crohn's disease is the occurrence of spontaneous fistulae from the diseased bowel, either to skin surface or to another viscus. Such internal fistulae are a well-recognized complica-

TABLE III

A SUMMARY OF THE MAIN CLINICAL DIFFERENCES BETWEEN ULCERATIVE COLITIS AND CROHN'S DISEASE OF THE LARGE INTESTINE

	<i>Ulcerative Colitis</i>	<i>Crohn's Disease</i>
Symptoms	Bleeding in 95%; abdominal pain rare	Bleeding in 45%; abdominal pain in 45%
Abdominal examination	Mass never	Mass in 8%
Sigmoidoscopic appearances	Rectum involved in 95%; uniformly granular mucosa	Rectum involved in 50%; cobblestone mucosa with oedema; varying severity of changes
Anal lesions	In 25%	In 80%; often ulceration

tion of Crohn's disease of the ileum, and it is not surprising that they should also occur from the large bowel. Six of 75 patients (8%) had spontaneous fistulae, of which two were colo-colic, one from colon to duodenum, and one from colon to small bowel; the other two had formed paracolic abscesses which had discharged on the skin surface with faecal fistulae. Two of the six patients had more than one fistula, that is, both an internal visceral fistula and a faecal fistula to skin surface.

In the experience of this hospital such spontaneous abdominal fistulae never occur in patients with ulcerative colitis. On the other hand, recto-vaginal fistulae can probably occur in both Crohn's disease and ulcerative colitis and were found in four of our 75 patients.

**SPREADING ULCERATION OF THE SKIN** In two patients with Crohn's disease initially thought to be confined to the sigmoid colon and rectum, a sigmoid loop colostomy established in bowel believed to be healthy above the diseased area was followed by indolent undermining ulceration of the abdominal wall around the stoma. In each case the disease was later found to have involved bowel proximal to the colostomy, and colectomy was followed by healing of the ulcerated skin.

These two patients appeared to be akin to cases of anal ulceration in that there was continuity between the diseased bowel and the ulcerated skin. But we have also seen patients in whom ulceration of the skin has persisted after total removal of diseased bowel. For instance, delayed healing of the perineal wound after excision of the rectum has been seen and in one such patient a biopsy from the indolent wound showed a sarcoid reaction. No specific treatment was given, however, and healing was spontaneous one year later.

Two patients seen recently have had especially severe and extensive skin ulceration, both after total proctocolectomy with ileostomy. They have had painful, spreading, undermining, indolent ulceration of the perineum, extending forward into the groins and vulva in the woman and into the groins and base of the scrotum in the man; in addition the man had similar ulceration round the base of the penis and to a lesser extent round the ileostomy (though there was no small-bowel Crohn's disease). In both these patients numerous biopsies from the ulcerated areas showed a florid sarcoid reaction, indicating that this ulceration was due to Crohn's disease and not to secondary infection in debilitated patients. Both patients responded to treatment and have now healed. But a patient treated at St. Mark's 10 years ago by total procto-colectomy died at home later of 'spreading ischio-rectal sepsis' by his doctor's

account, though he was not seen again at the hospital. He may be another example of spreading ulceration of the skin due to Crohn's disease but no histological evidence is available.

We have set out in tabular form (Table III) the main clinical points of difference between ulcerative colitis and Crohn's disease of the colon. In most patients with inflammatory disease of the large bowel, diagnosis will lie between these two disorders. Yet in most cases, clinical examination alone should suggest the right diagnosis.

#### RADIOLOGY

Nearly all the patients were examined by barium enema, many of them on several occasions. Some have also had barium meals with follow-through examination of the small bowel. Although the distinction between Crohn's disease, ulcerative colitis, and other inflammatory conditions is not always clear, certain characteristic radiological features can usually be found in Crohn's disease of the large bowel.

**DISTRIBUTION OF DISEASE** It has been explained that the rectum was involved in only about half of the patients in this series. Moreover, in 18 patients, only localized areas of the colon were diseased. These changes have, in most cases, been shown radiologically, hence an abnormal colon in association

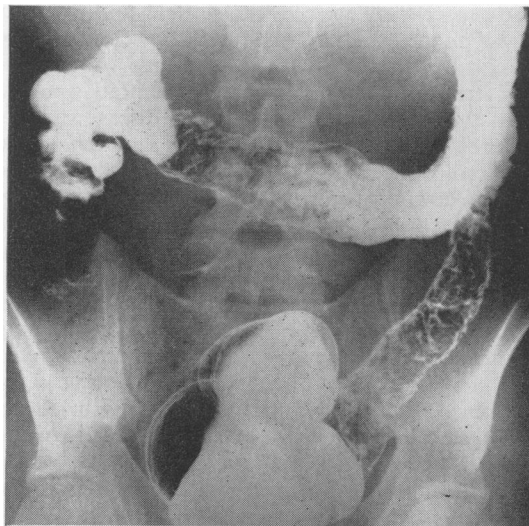


FIG. 7. Crohn's disease of the large intestine. Barium enema showing normal rectum with extensive and severe changes in the colon. There is incomplete haustral loss and eccentric involvement in the transverse part.

with a normal rectum, or segments of diseased colon separated by normal bowel, can be regarded as suggestive of Crohn's disease (Fig. 7). There are occasional cases of ulcerative colitis that do not involve the rectum, and there are conditions other than Crohn's disease that lead to segmental disease in the colon, which means that on the distribution of the changes alone the diagnosis can only be tentative.

In some patients with Crohn's disease confined to the rectum and distal sigmoid colon, marked radiological narrowing has been demonstrated in these parts, yet with a normal proximal colon. In patients with ulcerative colitis, on the other hand, most of the colon is usually involved by the time that radiological changes of this degree are present in the rectum.

**RADIOGRAPHIC SIGNS** In chronic ulcerative colitis the diseased part of the bowel is usually shortened and uniformly contracted with loss of haustration and a granular mucosal surface, though in severe and more active cases ulcers and inflammatory polyps can be demonstrated. In Crohn's disease the changes are seldom so uniform, and in general the outline of the bowel is more irregular, with narrowing of the lumen and rigidity of its walls, but with variation in the severity of the changes and of the diameter of the bowel in different parts. Moreover, patches of normal mucosa can be demonstrated even in those parts that appear to be extensively involved. Disease may not always involve the entire circumference, and a normal mucosa and haustral fold on one aspect may emerge into a rigid and irregular bowel on the other. In general, the bowel extensively involved with Crohn's disease seems to be less shortened in length than in chronic ulcerative colitis.

In those patients with extensive disease there is a 'cobblestone' appearance which can usually be seen radiologically as a shaggy and irregular outline to the bowel, and in the earlier stages this may disappear on further distention of the intestine. As the disease progresses, the irregular polypoid appearance becomes constant. In some severe cases extensive linear ulceration can be demonstrated between the remaining oedematous mucosa. Among the most characteristic pathological changes of Crohn's disease are the deep fissures that occur in the thickened submucosa, penetrate the bowel wall and may lead to internal fistulae or to a pericolic abscess cavity. These fissures can often be shown radiologically as little spikes radiating outwards from the lumen, and this finding seems to be characteristic of Crohn's disease (Fig. 8). Similarly the demonstration of a spontaneous internal fistula or leak of spontaneous origin to an abscess cavity or skin surface is practically diagnostic, as internal fistulae

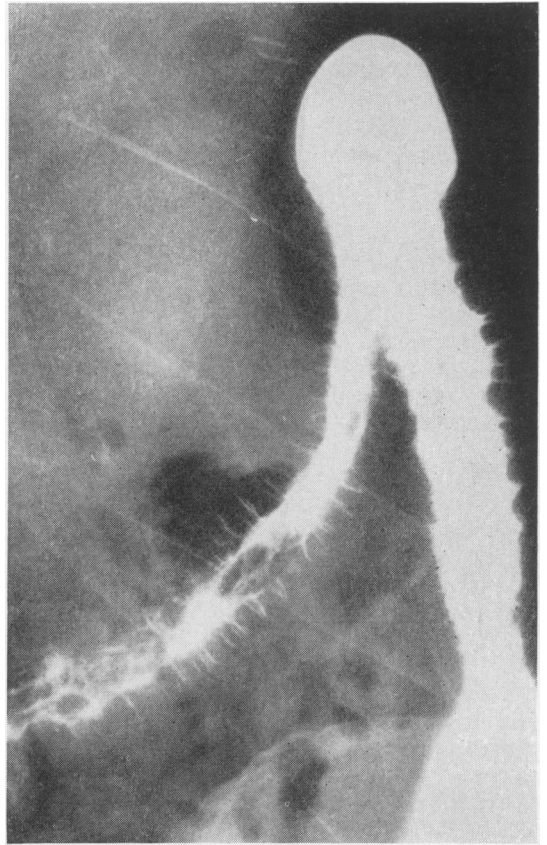


FIG. 8. Barium enema showing Crohn's disease of the large intestine with prominent 'spiking'.

(other than recto-vaginal) do not occur in ulcerative colitis.

Good accounts of the radiological changes in Crohn's disease of the colon have been given by Wolf and Marshak (1962) and by Lindner *et al.* (1963). The radiological aspects of the present series of cases are being reported in greater detail by Young (personal communication).

We have set out the main radiological points of difference between ulcerative colitis and Crohn's disease of the large bowel in Table IV.

#### LABORATORY INVESTIGATIONS

**THE MANTOUX TEST** Phear (1958) showed that about 70% of patients with Crohn's disease had a negative Mantoux reaction. A similar figure is given by Williams (1963), working on the St. Mark's Hospital series of patients. The Mantoux test can therefore be helpful in the distinction between Crohn's disease and tuberculosis of the intestines or anal region, a



TABLE IV

A SUMMARY OF THE MAIN RADIOLOGICAL DIFFERENCES BETWEEN ULCERATIVE COLITIS AND CROHN'S DISEASE OF THE LARGE INTESTINE

	<i>Ulcerative Colitis</i>	<i>Crohn's Disease</i>
Distribution	Rectum involved in 95%; disease in continuity	Rectum involved in 50%; disease often discontinuous
Contour	Bowel uniformly contracted in chronic cases; complete absence of haustral pattern	Bowel of varying diameter; eccentric involvement; incomplete haustral loss; normal patches in diseased areas.
Detail	Usually granular outline; never 'spiking'	Irregular polypoid pattern; often 'spiking'
Small bowel	If involved: in continuity with colon disease; Ileo-caecal valve dilated; terminal ileum dilated	If involved: often discontinuous. Ileo-caecal valve normal or narrowed; terminal ileum stenosed
Spontaneous internal fistulae	Never	Sometimes

negative one for all practical purposes ruling out a diagnosis of chronic tuberculosis. This is especially true if there is no radiological evidence of tuberculosis, for at the present time in Great Britain at least, intestinal or anal tuberculosis is nearly always secondary to a pulmonary infection. Exceptions to this general rule are found among immigrants to this country, notably those from Asia.

**BIOPSY OF ANAL LESIONS** The presence of the sarcoid reaction in biopsies of the anal lesions of Crohn's

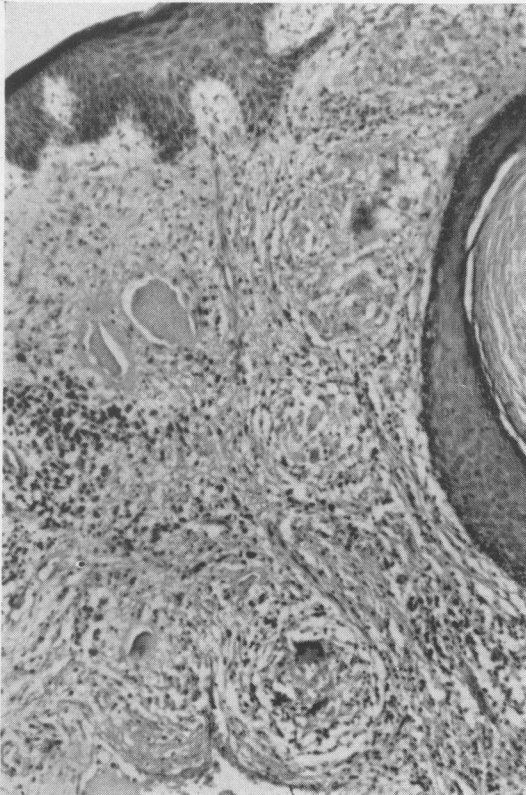


FIG. 9. Biopsy of edge of anal lesion showing sarcoid reaction beneath the peri-anal skin. ( $\times 10$ .)

disease has been reported earlier (Morson and Lockhart-Mummery, 1959b). In our experience the practice of biopsy for all anal fistulae at the time of operation continues to be valuable in directing attention to clinically latent Crohn's disease, for the anal manifestations often antedate the onset of abdominal symptoms by years.

Of the 75 patients in this series, 61 (81%) had anal lesions. Biopsy was performed in 29 of these and in 25 a sarcoid reaction was clearly present in the anal tissues (Fig. 9).

Biopsy of an anal lesion has sometimes failed to help when all other evidence has strongly suggested Crohn's disease as the correct diagnosis. This can be due to inadequate biopsy, but more commonly it is a reflection of the absence or sparseness of the sarcoid reaction.

The histological appearances of the anal lesions have to be distinguished from those due to tuberculosis and to a foreign body giant cell reaction. The absence of caseation in tuberculoid foci is generally accepted as definitive of a sarcoid reaction but non-caseating tuberculosis is sometimes seen in anal fistulae, though such cases are rare and there is usually evidence of tuberculosis in the lungs. If there is any doubt it is wise to carry out a guinea-pig inoculation with fresh tissue from the anal lesion.

Considerable care must be taken to distinguish the sarcoid reaction of Crohn's disease from foci of foreign-body reaction in which the giant cells are usually larger, more spherical, and have a greater number of nuclei. The latter are found more towards the centre of the cell whereas in the Langhans giant cell the nuclei tend to be peripheral in position. Epithelioid cells are exceptional in a foreign-body reaction which can be distinguished in tissue from anal lesions by the identification of foreign material, usually vegetable matter derived from the faeces.

**RECTAL BIOPSY** This is particularly useful in the distinction between Crohn's disease of the large intestine and ulcerative colitis. As Crohn's disease is so often a patchy condition, without the continuity

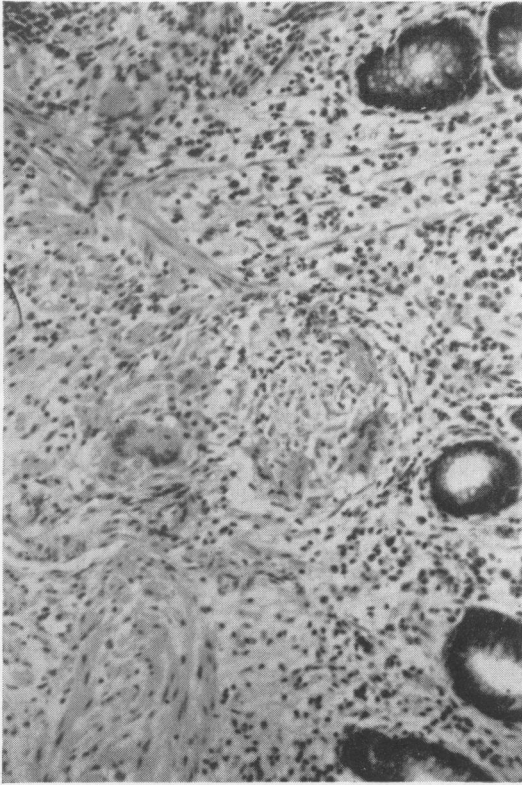


FIG. 10. Rectal biopsy showing focus of sarcoid tissue in the lamina propria of intact mucosa. ( $\times 200$ .)

of mucosal disease characteristic of ulcerative colitis some care must be taken in selecting the right site for biopsy. The edges of frankly ulcerated areas are usually productive of sarcoid foci provided there is plenty of submucosa in the tissue submitted (Fig. 10). Sites of mucosal nodularity in non-ulcerated areas are also good, as this appearance may be caused by a tissue reaction in the submucosa lifting up the overlying mucous membrane.

Nineteen of the 75 patients in this series had a rectal biopsy. In 16 the sarcoid reaction of Crohn's disease was found in the submucosal or mucosal tissues. It was present in association with chronic inflammatory changes and hyperplasia of lymphoid tissues which were mainly submucosal in distribution and lying beneath a relatively intact mucosa. In the three negative biopsies the histological changes were non-specific in character; these patients had Crohn's disease of the large bowel and a sarcoid reaction was subsequently found in the surgical specimen.

**BIOPSY AT OPERATION** The diagnosis of Crohn's

disease can sometimes be established or confirmed by examination of tissues removed at laparotomy when resection of the intestinal lesion is contra-indicated. Biopsy of diseased tissue or removal of a regional lymph node for histology may reveal foci of sarcoid tissue, and similar changes can be found in tissue from the walls of intraabdominal fistulae or abscesses.

#### DIFFERENTIAL DIAGNOSIS

There are a number of different conditions with which Crohn's disease of the large intestine are commonly confused. These include ulcerative colitis, 'right-sided colitis', 'segmental colitis', tuberculosis, diverticular disease, and carcinoma of the colon.

Before the clinical and pathological picture of Crohn's disease of the large intestine was clearly recognized the most common misdiagnosis was ulcerative colitis, for it was assumed that Crohn's disease was a condition peculiar to the small intestine, and that any diffuse inflammation of the colon not one of the dysenteric disorders was ulcerative colitis. Several of our patients had previously had an operation for Crohn's disease of the terminal ileum, but it was not at that time realized that Crohn's disease could involve the colon so widely, and it was thought that they were also affected by ulcerative colitis. The main findings that suggest Crohn's disease have already been described; it is particularly in the differential diagnosis between ulcerative colitis and Crohn's disease that anal or rectal biopsy may be of value. The findings of a sarcoid reaction will strongly suggest Crohn's disease, though the absence of such changes on a single biopsy by no means excludes the diagnosis.

'Right-sided colitis' is a term which should only be used to describe that variant of ulcerative colitis in which the rectum appears normal. Such cases are rare in our experience, amounting to less than 5% of the cases of proven ulcerative colitis in this hospital. The distinction from Crohn's disease can usually be made on sigmoidoscopic and radiological evidence and by examination of biopsy material from any anal lesion which may be present. Rectal biopsy can also be helpful, for a sigmoidoscopically 'normal' rectum may show histological evidence of disease (Dick and Grayson, 1961). A certain diagnosis may not be possible until the bowel has been removed and examined microscopically.

There is an uncommon variety of segmental colitis the pathogenesis of which remains obscure (Kellock, 1957; Boreham, 1957; Morson, 1961). Investigation of the clinical history, pathology, and follow-up of such patients does not suggest a diag-

nosis of either Crohn's disease or ulcerative colitis. In our experience this condition is recognizable. There is usually a rather short segment of diseased bowel, most commonly situated in the region of the splenic flexure or descending colon. The patients have a short history, usually of rectal bleeding or subacute intestinal obstruction; the radiologist suggests carcinoma, the pathological appearances are non-specific, and the patient is cured by segmental resection. It is possible that this form of non-specific segmental colitis has a vascular basis.

A common difficulty is the distinction between Crohn's disease and tuberculosis. Clinical features such as purulent rectal discharge, indolent undermining ulceration of the anal region, and the presence of a 'tuberculoid' reaction in biopsy material cause uncertainty. Eighteen of our 75 patients had at some time during their illness been diagnosed as 'tuberculous colitis' and 12 of them had received one or more courses of anti-tuberculous therapy (including sanatorium treatment) from which none derived any benefit whatever. In some patients, an initial diagnosis of tuberculosis was later changed to ulcerative colitis when diffuse colonic involvement was found, or when the Mantoux was found to be negative. In Great Britain, Crohn's disease is certainly far more common than tuberculous colitis, of which there has been no case at St. Mark's in the last 10 years, and we believe should be considered as the first diagnosis when undermining anal ulceration is seen in association with disease of the large bowel.

Distinction between Crohn's disease and sigmoid diverticulitis is not always easy. There were five patients in whom the latter diagnosis was made initially, all of them being over 50 years old, and with disease apparently confined to the sigmoid colon. In three of them there was a palpable mass in the left iliac fossa, and four had anal lesions when first seen. A barium enema showed diverticula and some narrowing of the sigmoid colon. Diverticulosis of the sigmoid colon is of course a frequent finding in middle-aged and elderly patients. It is not uncommonly found in association with ulcerative colitis as well as in patients with diffuse Crohn's disease of the large intestine. In such cases the diverticular disease is clearly coincidental. When Crohn's disease confined to the sigmoid is superimposed on diverticular disease the distinction may be impossible until pathological examination of an operation specimen. However, in three of our four patients biopsy of the associated anal lesions showed a sarcoid histology and led to the correct diagnosis.

The distinction between carcinoma and a single stricture of the colon due to Crohn's disease can be impossible before examination of an operation

specimen. The radiological differences are difficult to interpret and even at laparotomy the appearances may be equivocal. In three of our patients a pre-operative diagnosis of carcinoma was made, and laparotomy undertaken. In each case a hard stricture was found, which was clearly inflammatory in two patients, but which was thought to be an anaplastic carcinoma in the third. In each case resection was successfully carried out. In two others, the diagnosis of carcinoma was considered when the patient was first seen because of stenosis with ulceration found on sigmoidoscopy; in both, however, a biopsy of the mass showed a sarcoid histology.

#### PATHOLOGY

##### MACROSCOPIC APPEARANCE OF SURGICAL SPECIMENS

Careful macroscopic inspection of a well-prepared surgical specimen of Crohn's disease will reveal features which are characteristic and different from those seen in other inflammatory disorders of the large intestine, particularly ulcerative colitis. Indeed it is usually possible to make a diagnosis of Crohn's disease on macroscopic evidence alone, just as a hose-pipe stricture of the terminal ileum is accepted as characteristic. The appearances of the disease in the large bowel are similar to those for the small bowel, any differences being a reflection of the dissimilar anatomy of the two parts of the gut.

Inspection of the serous coat of the colon will sometimes provide clues to the diagnosis of Crohn's disease. If the peritoneum appears granular or fibrous Crohn's disease rather than ulcerative colitis may be suspected. Tiny 'tubercles' are sometimes seen on the serous coat and in many cases there is a patchy pericolicitis due to penetration of all layers of the gut wall by the inflammation.

The appearance of the mucosal surface in Crohn's disease of the large intestine is similar in every way to that seen in disease of the small bowel. The characteristic 'cobblestone' appearance is not always present but is a most useful diagnostic feature (Fig. 11). It is due to intact mucosa being lifted up by inflammatory changes in the submucosa. In between the 'cobblestones' intercommunicating cracks or crevices can be seen extending into the gut wall. These are really linear ulcers. They tend to undermine adjacent intact mucosa which sloughs off leaving larger and more extensive areas of ulceration. The phenomenon of mucosal ulceration is probably a rather late manifestation of Crohn's disease, being secondary to the submucosal inflammation. In specimens of Crohn's disease of both the small and the large gut it is quite common to find extensive submucosal inflammation in the complete absence of ulceration, the mucosal surface appearing coarsely

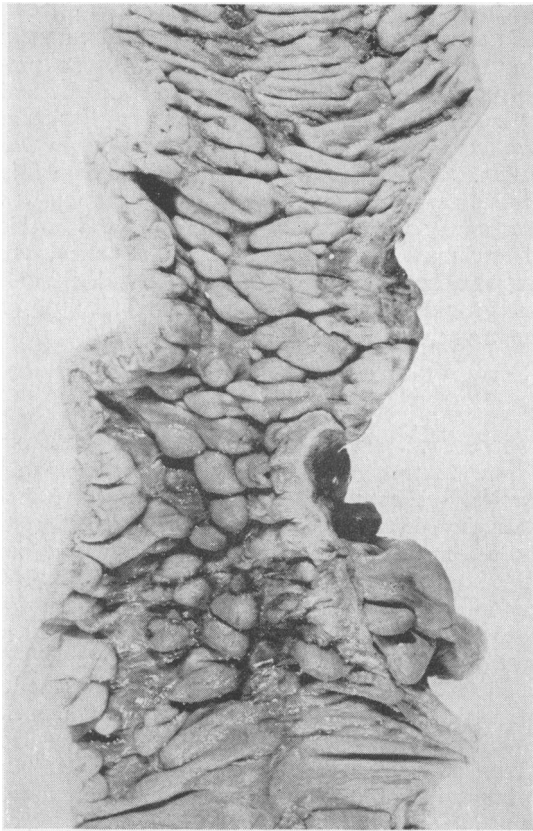


FIG. 11. Cobblestone appearance of mucosal surface in Crohn's disease of the large intestine. Intercommunicating fissures or linear ulcers are present between the 'cobblestones'.

nodular. Even when ulceration is extensive, cracks and crevices may be demonstrated on the surface of the ulcerated areas.

It is difficult to assess the significance of enlarged regional lymph nodes in Crohn's disease of the small or large intestine. Most authorities agree that lymph-node hyperplasia is the rule. However, it should be remembered that ileo-caecal and mesenteric lymph glands in particular are normally large and especially so in young persons. Certainly the sarcoid reaction of Crohn's disease can be found in very small lymph nodes as often as in large ones. In Crohn's disease of the large intestine the regional lymph nodes are not invariably enlarged and there is poor correlation between size and the presence of a sarcoid reaction.

In some of our specimens there has been associated diverticular disease of the sigmoid colon. Here the muscle layers are thick and corrugated and there is an unusual degree of stenosis of the lumen.

The diverticula are all involved by the inflammatory process and pericolic inflammatory changes are very diffuse and far advanced. The distinction between the two conditions is simple when most or the whole of the large intestine is involved by the Crohn's disease. In such cases it is obvious that the diverticular disease is coincidental. With a solitary stricture of the sigmoid, however, the distinction may be more difficult, especially on radiological evidence alone.

**HISTOLOGY** The most useful diagnostic feature of Crohn's disease is the presence of a sarcoid reaction in the tissues of the bowel wall and regional lymph nodes, as described by Blackburn, Hadfield, and Hunt (1939). Unfortunately this is not present in every case. It has been found in 75% of 150 surgical specimens of Crohn's disease of the small and large intestine examined at St. Mark's Hospital since 1955. The incidence in the present series of surgical specimens of large intestinal disease is 87%. This high incidence of a sarcoid reaction in the St. Mark's series of cases is probably a reflection of the relatively large number of sections examined. The sarcoid reaction can be very florid in the sense that the lesions are present in very great numbers throughout the tissue under examination, including the regional lymphatic glands. Alternatively the number of sarcoid foci may be so few that they escape detection except by the examination of many sections. In those surgical specimens of large intestinal disease with a sarcoid reaction in the tissues of the bowel wall 25% also had sarcoid foci in the regional lymphatic glands. There has been no case in this series of glandular involvement without a similar reaction in the gut wall.

Schauman bodies are occasionally found within the giant cells of the sarcoid reaction of Crohn's disease. They are similar in every way to those described in sarcoidosis, chronic beryllium disease, and in tuberculosis (Williams, 1960). The incidence in the present series of surgical specimens of large intestinal disease was 10% of those with a sarcoid reaction.

Although the sarcoid reaction of Crohn's disease remains the most reliable diagnostic feature, increasing experience suggests that its presence is not essential in the histological diagnosis. In the absence of a sarcoid reaction the most valuable diagnostic feature is the presence of 'fissures' or microscopic sinuses passing from the ulcerated mucosal surface deep into the bowel wall, and sometimes beyond into the peri-intestinal tissues (Fig. 12). In some histological sections they appear as intramural or extramural abscesses but in serial preparations they can be traced to the surface. They are lined by granu-

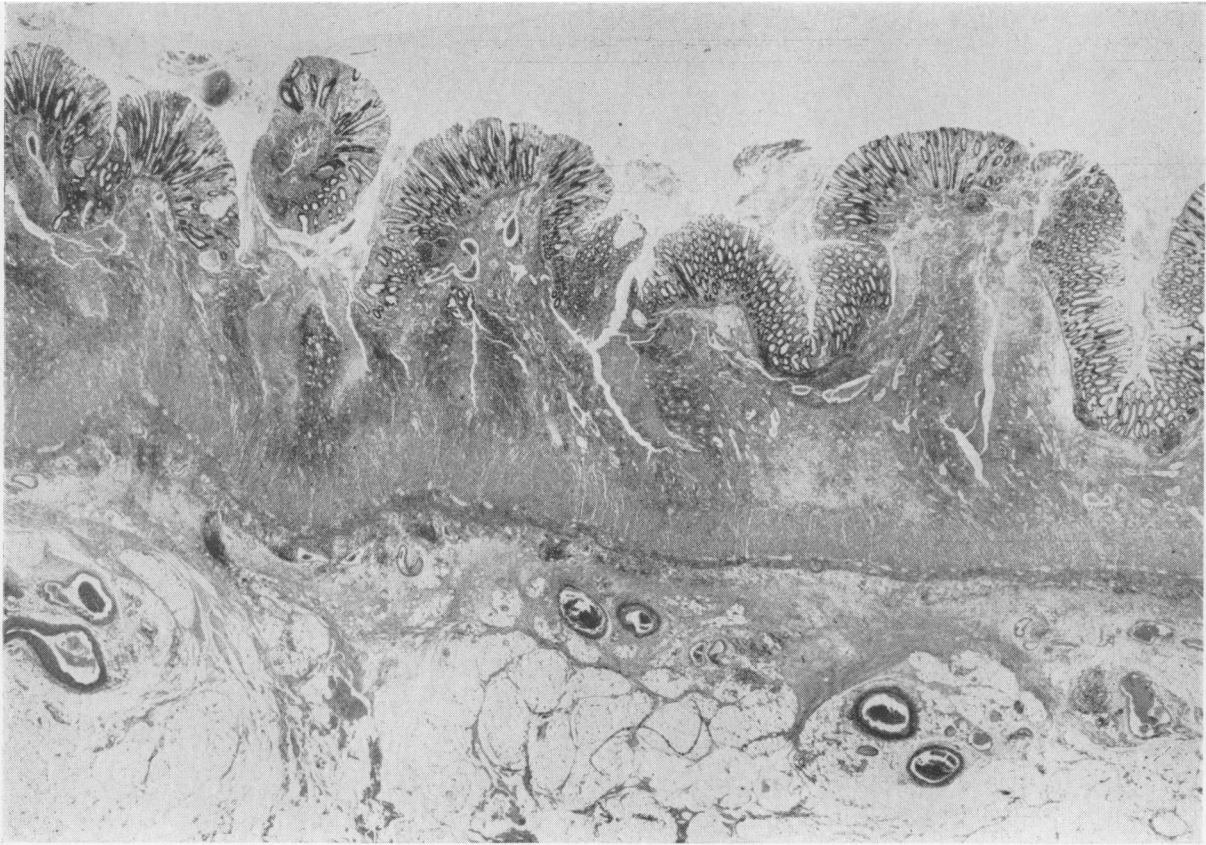


FIG. 12. Crohn's disease of the large intestine, with 'fissures' or linear ulcers passing from the mucosal surface deep into the bowel wall. Most of the mucous membrane is intact but raised up by underlying inflammation. This accounts for the typical cobblestone appearance illustrated in Figure 11. ( $\times 15$ .)

lation tissue which has a superficial zone of necrotic inflammatory cells including polymorphs, lymphocytes, and plasma cells. Beneath this layer the cells are mostly lymphocytes, with few plasma cells and histiocytes. The whole may be surrounded by foci of proliferating lymphoid tissue containing prominent follicles, but this is variable. In some specimens of Crohn's disease fissures are very prominent and easily identified. In others they are few and difficult to find unless many sections are examined. 'Fissures' were found in 25% of the present series of specimens of large intestinal Crohn's disease. They are particularly useful when sarcoid foci are absent, because they do not seem to occur in other inflammatory disorders of the gastrointestinal tract. The fissures of Crohn's disease are, of course, observed macroscopically as cracks or crevices in the mucosal surface of the bowel wall. They provide the pathological basis for the formation of intra-abdominal and entero-cutaneous fistulae.

Although the sarcoid foci and fissures of Crohn's disease may be specially useful in diagnosis, there are other less tangible histological changes which may be regarded as peculiar to Crohn's disease rather than to other varieties of inflammation such as ulcerative colitis or diverticulitis. In Crohn's disease there is marked widening of the submucosa by oedema and inflammatory infiltrate, with a largely intact mucosa showing only patchy full-thickness ulceration. The inflammation in Crohn's disease consists of focal collections of lymphocytes, often with prominent follicle formation scattered through all layers of the bowel wall including the serosa (Fig. 13). These foci usually lie alongside an artery or vein and may be even more closely related to lymphatic channels. The inflammation of Crohn's disease is essentially transmural. In contrast it is exceptional for the histological changes of ulcerative colitis to spread beyond the mucosa and submucosa. It is essentially a superficial type of inflammation.

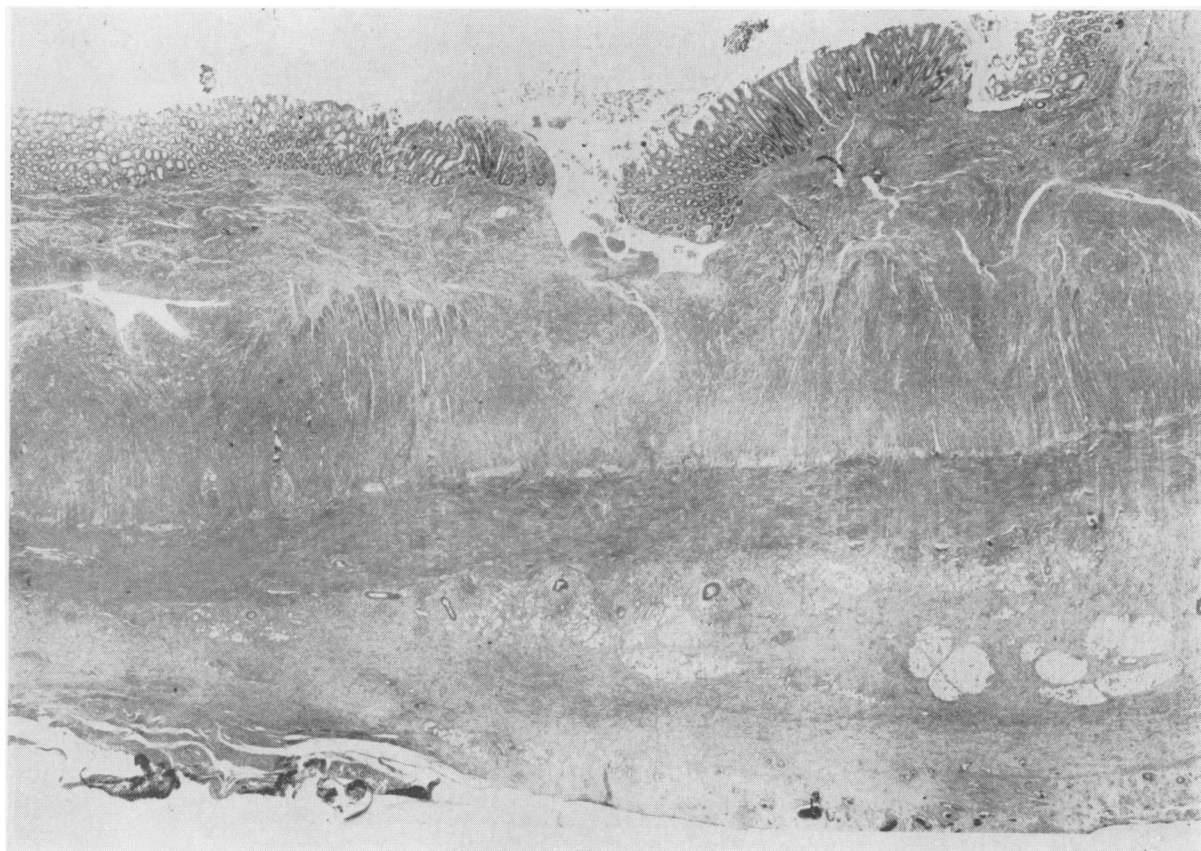


FIG. 13. *Transmural inflammation in Crohn's disease of the large intestine. Mucous membrane is largely intact. Fissuring and an intramural abscess cavity are also present. The serosa shows extensive changes. ( $\times 10$ ).*

In diverticulitis (Morson, 1963) the inflammation is wholly extramural, the mucosa, submucosa, and muscle layers being entirely free of inflammation. The histological differences between Crohn's disease, ulcerative colitis, and diverticulitis are summarized in Table V.

In occasional specimens of diffuse and segmental inflammation of the large intestine macroscopic and microscopic appearances make no positive contribution to the diagnosis. It is best to label these patients

as 'unclassified colitis' and recognize our inability to be more precise. In such cases the pathological appearances are not necessarily due either to Crohn's disease or to ulcerative colitis, and it may be that there are further clinico-pathological varieties of inflammation in the large intestine which, for the present, remain unrecognized.

**DISEASE OF THE APPENDIX** There were five patients in this series who had Crohn's disease of the

TABLE V

HISTOLOGICAL DIFFERENCES BETWEEN CROHN'S DISEASE, ULCERATIVE COLITIS, AND DIVERTICULITIS

	<i>Crohn's Disease</i>	<i>Ulcerative Colitis</i>	<i>Diverticulitis</i>
<i>Sarcoid reaction</i>			
Bowel wall	Present (75%)	Absent	Absent
Lymph nodes	Present (25%)	Absent	Absent
Anal lesions	Present (75%)	Absent	Absent
Fissuring	Present (25%)	Absent	Absent
Distribution of inflammation	Transmural	Mucosal and submucosal	Extramural

appendix. In two of these the diseased appendix was in continuity with disease of the caecum but in three the pathology in the appendix was isolated and in association with disease confined to the distal large bowel (see Fig. 3). Microscopic examination of all these cases showed focal involvement of the appendix by a sarcoid reaction which was mainly situated in the mucosal lymphoid tissue. In one case the sarcoid reaction was present in all layers but mainly in the submucous coat.

The question arises whether such changes can be termed Crohn's disease of the appendix. Crohn and Yarnis (1958) report that the appendix had previously been removed in about 25% of patients with terminal ileitis. However, they report that the appendix is never involved by the 'typical granulomatous' changes of Crohn's disease. If it is accepted, however, that Crohn's disease can involve any part of the gastrointestinal tract, including the large intestine of which the appendix is developmentally and anatomically a part, then it does not seem unreasonable to suggest that this organ should occasionally be involved alone or in association with disease of the ileum or colon.

#### DISCUSSION

Our ignorance of the aetiology of Crohn's disease at the present time is absolute (see Crohn and Yarnis, 1958). Nor should we presume that there is a single cause, for inconsistencies in both the clinical and pathological picture may indicate multiple aetiological factors. The same comment can also be applied to the aetiology of ulcerative colitis. Some authorities have favoured a unified approach to both conditions based on theories of autoimmunity but evidence of a common aetiology is still lacking. On the other hand, there are distinct differences between the pathology of Crohn's disease and ulcerative colitis that are readily recognizable and which, for the present, indicate separate aetiologies.

There are two main reasons why Crohn's disease of the large intestine has remained insufficiently recognized. The first is a failure to appreciate the clinical and pathological differences from ulcerative colitis, and, in particular, the diagnostic importance of the anal lesions. The second is a problem of nomenclature, already discussed.

The concept of Crohn's disease of the large intestine has been resisted because of a reluctance to accept segmental, regional or diffuse inflammation of the large intestine as anything, other than colitis or ulcerative colitis. Wells (1952) and Brooke (1954) suggested that some forms of segmental colitis were Crohn's disease and Warren and Sommers (1954)

state that regional ileitis and ulcerative colitis are morphologically distinguishable and rarely coexist.

Patients with inflammation of both terminal ileum and large intestine have been recognized for many years but some authors still have stated or implied that Crohn's disease of the ileum and ulcerative colitis often occur in the same patient; that granulomatous histological changes are frequently present in ulcerative colitis; and that there are no significant clinical differences between ulcerative colitis and the granulomatous forms of colon disease (Yarnis, Marshak, and Crohn, 1957; Yarnis and Crohn, 1960; Colcock, Vansant, and Contreras, 1961). All these opinions we believe to be incorrect.

One of the main points of controversy seems to be the interpretation of pathological changes, and the criteria on which a diagnosis of Crohn's disease should be based. These have been clearly stated (Blackburn *et al.*, 1939; Hadfield, 1939; Laipply, 1957; Lockhart-Mummery and Morson, 1960; Saltzstein and Rosenberg, 1963). But there is still some reluctance to accept the histology of Crohn's disease as recognizable and in most cases distinguishable from ulcerative colitis (Valdes-Dapena and Vilardell, 1962). We repeat that we have never seen Crohn's disease and ulcerative colitis in the same patient, either synchronously or metachronously. Moreover, we are convinced that there are clinical and radiological features in Crohn's disease of the colon and rectum which make diagnosis possible in most cases before pathological confirmation is forthcoming.

Most of the earlier papers emphasizing the distinction between ulcerative colitis and Crohn's disease of the large bowel were in the British literature (Brooke, 1959; Morson and Lockhart-Mummery, 1959a; Lockhart-Mummery and Morson, 1960; Cornes and Stecher, 1961). But in 1959 Marshak, Wolf, and Eliasoph gave an account of some of the radiological features of 'granulomatous colitis', and Wolf and Marshak (1962) have since published an excellent detailed study of the radiological appearances. The distinction between ulcerative colitis and 'granulomatous colitis' has been accepted at the Mt. Sinai Hospital, New York. Leichtling and Garlock (1962) published five case reports with complications due to internal fistula formation, and a clinical study has recently been published by Lindner *et al.* (1963).

It is unfortunate that many reports in the literature about the incidence of complications in patients with colitis are misleading because those with Crohn's disease of the colon have not been recognized. Some of the clinical features ascribed to ulcerative colitis do not in our experience occur in that disease, such

as spontaneous internal fistulae and certain reported cases of perineal ulceration (Scott, 1961; Hunter-Craig, 1961).

The distinction between Crohn's disease, ulcerative colitis, and other inflammatory disorders of the colon may have important therapeutic implications. The increasing effectiveness of medical as opposed to surgical treatment of ulcerative colitis has not been matched by any corresponding improvement in the medical treatment of Crohn's disease. Nearly all the patients analysed in this study have had surgical treatment for advanced disease which in some cases had clearly been present for many years. The results of this treatment will be the subject of a separate paper. However, it can be stated now that the decision to treat these patients by radical surgical operation was only taken after it had become quite clear that purely medical measures were failing and that the patient's health and life were at great risk from serious complications. It is possible that the correct diagnosis made at a much earlier stage of the disease could have led to successful medical treatment.

There is some evidence that the incidence of Crohn's disease of the large intestine and anal region is increasing. Much of this increase may be a reflection of an increased awareness of the diagnosis coupled with the fact that some patients previously labelled ulcerative colitis are now known to have Crohn's disease of the colon. It would be of great interest to know the true incidence of Crohn's disease of the large intestine relative to ulcerative colitis but such information cannot be obtained from this hospital where the true incidence of disease is masked by the specialized nature of its practice.

#### SUMMARY

Seventy-five patients with Crohn's disease of the large intestine have been described with particular emphasis on the clinical picture and the diagnostic importance of the anal lesions.

Crohn's disease affects the large intestine both in the form of diffuse disease simulating ulcerative colitis and as single or multiple strictures of the colon. There was associated disease of the terminal ileum in 30% of patients. The rectum was normal in 50%.

Diarrhoea was the most frequent symptom, occurring in 85% of patients and pain and rectal bleeding in 45%. Anal lesions were found at some stage of their illness in 61 (80%) of the 75 patients.

The sigmoidoscopic and radiological findings are described and the appearances distinguished from those found in ulcerative colitis.

Although the sarcoid reaction remains the most

reliable feature in the histological diagnosis of Crohn's disease, increasing experience has shown that the presence of intramural fissures as well as a rather characteristic distribution of inflammation in the bowel wall are peculiar to Crohn's disease. The sarcoid reaction of Crohn's disease may be found in rectal biopsies and in biopsies of anal lesions and is especially valuable in confirming diagnosis.

The differential diagnosis between Crohn's disease and other inflammatory disorders of the large bowel, particularly ulcerative colitis, is described. The problem of nomenclature is discussed and a strong plea is made for the adoption of the expression 'Crohn's disease' to describe this condition whatever part of the gastrointestinal tract is involved.

We are indebted to our medical colleagues at St. Mark's Hospital for permission to study their patients. Mr. H. J. R. Bussey and Mr. Lloyd Soodeen have given valuable technical assistance. The photographs were taken by Mr. Norman Mackie. The expenses of this investigation were mainly provided out of a grant to the research department of St. Mark's Hospital from the Board of Governors of the Hammersmith and St. Mark's group of Hospitals.

#### REFERENCES

- Appleman, R. M., and Jackman, R. J. (1962). Regional enteritis: proctoscopic clues in diagnosis. *Dis. Colon. Rect.*, **5**, 361-363.
- Barron, R. A., Jarkowski, T. L., Ruel, R. E., and Meyers, S. G. (1963). Ileocolitis: importance of a more precise definition. *Gastroenterology*, **44**, 815-816.
- Blackburn, G., Hadfield, G., and Hunt, A. H. (1939). Regional ileitis. *St. Bart. Hosp. Rep.*, **72**, 181-224.
- Boreham, P. (1957). Benign strictures of the colon. *Proc. roy. Soc. Med.*, **50**, 601-604.
- Brooke, B. N. (1954). *Ulcerative Colitis and its Surgical Treatment*. Livingstone, Edinburgh and London.
- (1959). Granulomatous diseases of the intestine. *Lancet*, **2**, 745-749.
- Colcock, B. P., Vansant, J. H., and Contreras, O. (1961). Surgical treatment of coexisting regional enteritis and ulcerative colitis. *Surg. Gynec. Obstet.*, **112**, 96-100.
- Cornes, J. S., and Stecher, M. (1961). Primary Crohn's disease of the colon and rectum. *Gut*, **2**, 189-201.
- Crohn, B. B., Ginzburg, L., and Oppenheimer, G. D. (1932). Regional ileitis: a pathologic and clinical entity. *J. Amer. med. Ass.*, **99**, 1323-1329.
- and Yarnis, H. (1958). *Regional Ileitis*, 2nd ed. Grune and Stratton, New York and London.
- Davis, J. M. (1962). The large bowel complications of Crohn's disease of the small intestine. *Proc. roy. Soc. Med.*, **55**, 704-706.
- Dick, A. P., and Grayson, M. J. (1961). Ulcerative colitis: a follow-up investigation with mucosal biopsy studies. *Brit. med. J.*, **1**, 160-165.
- Fahimi, H. D., Deren, J. J., Gottlieb, L. S., and Zamcheck, N. (1963). Isolated granulomatous gastritis: its relationship to disseminated sarcoidosis and regional enteritis. *Gastroenterology*, **45**, 161-175.
- Ferguson, L. A., Spencer, J. A., and Kirsner, J. B. (1963). Ileocolitis: a clinical and pathologic analysis. *Ibid.*, **44**, 823.
- Hadfield, G. (1939). The primary histological lesion of regional ileitis. *Lancet*, **2**, 773-775.
- Hunter-Craig, C. J. (1961). Granuloma of the groins and perineum secondary to chronic proctocolitis. *Proc. roy. Soc. Med.*, **54**, 1019.
- Kellock, T. D. (1957). Acute segmental ulcerative colitis. *Lancet*, **2**, 660-663.



- Laipply, T. C. (1957). Pathological anatomy of regional enteritis. *J. Amer. med. Ass.*, **165**, 2052-2054.
- Leichtling, J. J., and Garlock, J. H. (1962). Granulomatous colitis complicated by gastrocolic, duodenocolic, and colopulmonic fistulas. *Gastroenterology*, **43**, 151-165.
- Lindner, A. E., Marshak, R. H., Wolf, B. S., and Janowitz, H. D. (1963). Granulomatous colitis: a clinical study. *New Engl. J. Med.*, **269**, 379-385.
- Lockhart-Mummery, H. E., and Morson, B. C. (1960). Crohn's disease (regional enteritis) of the large intestine and its distinction from ulcerative colitis. *Gut*, **1**, 87-105.
- Marshak, R. H., Wolf, B. S., and Eliasoph, J. (1959). Segmental colitis. *Radiology*, **73**, 707-716.
- Morson, B. C., and Lockhart-Mummery, H. E. (1959a). Crohn's disease of the colon. *Gastroenterologia (Basel)*, **92**, 168-173.
- , — (1959b). Anal lesions in Crohn's disease. *Lancet*, **2**, 1122-1123.
- (1961). The surgery of non-malignant ulcerative diseases of the large intestine. *Trans. med. Soc. Lond.*, **78**, 30-37.
- (1963). The muscle abnormality in diverticular disease of the sigmoid colon. *Brit. J. Radiol.*, **36**, 385-392.
- Phear, D. N. (1958). The relation between regional ileitis and sarcoidosis. *Lancet*, **2**, 1250-1251.
- Saltzstein, S. L., and Rosenberg, B. F. (1963). Ulcerative colitis of the ileum, and regional enteritis of the colon: a comparative histopathologic study. *Amer. J. clin. Path.*, **40**, 610-623.
- Scott, O. L. S. (1961). Granuloma of the groins and perineum secondary to chronic proctocolitis. *Proc. roy. Soc. Med.*, **54**, 1019.
- Valdes-Dapena, A., and Vilardell, F. (1962). Granulomatous lesions in ileocolitis. *Gastroenterologia (Basel)*, **97**, 191-204.
- Warren, S., and Sommers, S. C. (1954). Pathology of regional ileitis and ulcerative colitis. *J. Amer. med. Ass.*, **154**, 189-193.
- Wells, C. (1952). Ulcerative colitis and Crohn's disease. *Ann. roy. Coll. Surg. Engl.*, **11**, 105-120.
- Williams, W. Jones, (1960). The nature and origin of Schaumann bodies. *J. Path. Bact.*, **79**, 193-201.
- (1963). The laboratory diagnosis of Crohn's syndrome. *Proc. roy. Soc. Med.*, **56**, 409.
- Wolf, B. S., and Marshak, R. H. (1962). Granulomatous colitis (Crohn's disease of the colon): roentgen features. *Amer. J. Roentgenol.*, **88**, 662-670.
- Yarnis, H., and Crohn, B. B. (1960). Segmental (ulcerative) colitis. *Gastroenterology*, **38**, 721-728.
- , Marshak, R. H., and Crohn, B. B. (1957). Ileocolitis. *J. Amer. med. Ass.*, **164**, 7-13.
- Young, A. C. Personal communication.