

Multiple strictures of the jejunum

J. HARROP SHOESMITH, G. T. TATE, AND C. J. E. WRIGHT

*From the General Infirmary at Leeds and the Department of Pathology,
University of Leeds*

EDITORIAL SYNOPSIS The two patients the subject of this paper had a hitherto undescribed cause of multiple strictures of the intestine consisting of little more than mucosal diaphragms.

Intrinsic strictures of the jejunum are rare, and apart from developmental defects incompatible with life, are usually examples of Crohn's disease. Two examples are described, in which the strictures are unusual and little more than mucosal folds.

CASE REPORTS

CASE 1 A man, aged 48, was admitted to the General Infirmary at Leeds in October 1958. Eight years previously he had started to complain of a burning pain in the epigastrium and behind the sternum, coming on one and a half to two hours after food and relieved by alkalis or food. There was no vomiting or diarrhoea but on several occasions he had passed dark stools. For the resultant secondary anaemia he received blood and iron therapy. In March 1958, after a further episode of melaena, a laparotomy was carried out at another hospital but no ulcer was found. In spite of this, a partial gastrectomy was performed and when the anastomosis was made the upper jejunum was seen to be distended and had a saccular appearance due to a series of constricting rings at short intervals. These were thought to be due to spasm and an anticolonic afferent loop to lesser-curve partial gastrectomy was performed.

Since the operation, the patient had not experienced burning pain but instead he complained of attacks of gripping pain in the epigastrium relieved by vomiting. The attacks occurred several times a week, at any time of day or night; the vomiting was often copious but rarely contained food. He had lost 2 to 3 stones in weight.

Apart from a little tenderness in the centre of a right paramedian scar, obvious loss of a good deal of weight and a little dehydration, physical examination was negative.

The blood picture, serum proteins and electrolytes, and glucose tolerance test were normal.

A barium meal showed that the oesophagus was normal. The gastric remnant filled out well and barium passed freely through the stoma. The jejunal mucosa was thickened. Both afferent and efferent loops filled readily. There was considerable dilatation of the afferent loop and a stricture was present about 4 in. distal to the stoma.

The follow-through film taken two hours later showed a number of strictures in the upper jejunum. After four

hours the head of the meal had reached the proximal colon, but some barium was still seen, held up in the upper jejunum.

The dehydration was corrected and the patient was given a strict ulcer régime but the pain and vomiting persisted. A surgical opinion was sought and a laparotomy decided upon.

Operation The presence of an antecolic, afferent loop to lesser-curve partial gastrectomy was confirmed and the anastomosis appeared satisfactory. The efferent loop was grossly dilated and hypertrophied due to a stricture 5 in. from the anastomosis. Distal to this stricture, which was later shown to admit only the tip of an artery forcep, was a series of further strictures, 25 in all, stretching a further 2½ to 3 ft. down the jejunum. The mesentery in association with this portion of jejunum was thickened and contained numerous large fleshy lymph nodes. The rest of the intestinal tract appeared normal.

The portion of jejunum containing the strictures was resected and an end-to-end anastomosis carried out.

The post-operative course was uneventful except for some diarrhoea, which settled within two weeks without treatment. Follow-up four years later showed the patient to be well and symptom free.

Pathology The excised loop of jejunum measured some 2 ft. in length in its partially fixed state and presented a peculiar, uniformly segmented or haustrated appearance due to a series of constrictions (Fig. 1). The serosa was normal, without obvious vascular injection, scarring, or evidence of adhesions. Moderately enlarged lymph nodes were present in the mesentery and on section presented a uniform fleshy appearance. On opening the gut the constrictions, which were ½ in. to 1½ in. apart, were most pronounced at the upper end, becoming less severe towards the other. The more proximal lesions were frequently ulcerated (Fig. 2) and covered by yellowish slough and the central openings of the diaphragms measured as little as 2 to 3 mm. in diameter. Distally the folds became progressively less prominent until only perceptible on stretching open the bowel, when they appeared as a mere exaggeration of the normal circular folds.

Histologically this impression persisted to a certain extent. The folds (Fig. 3) were covered with mucosa with a fibrous tissue core which was fairly rich in scattered bundles of smooth muscle distinct from the muscularis

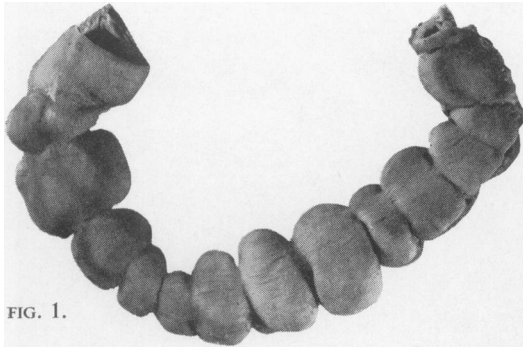


FIG. 1.

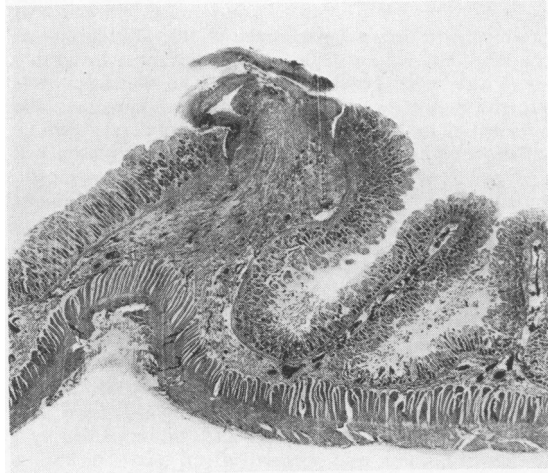


FIG. 3.



FIG. 2.

FIG. 1. *The jejunum in case 1 showing the constrictions (x 0.8).*

FIG. 2. *A longitudinal section through one of the proximal strictures, with ulceration of the margin (x 2.8).*

FIG. 3. *A low-power photomicrograph of Figure 2 (x 6).*

FIG. 4. *A pseudo-tubercle follicle in the mucosa (x 140).*

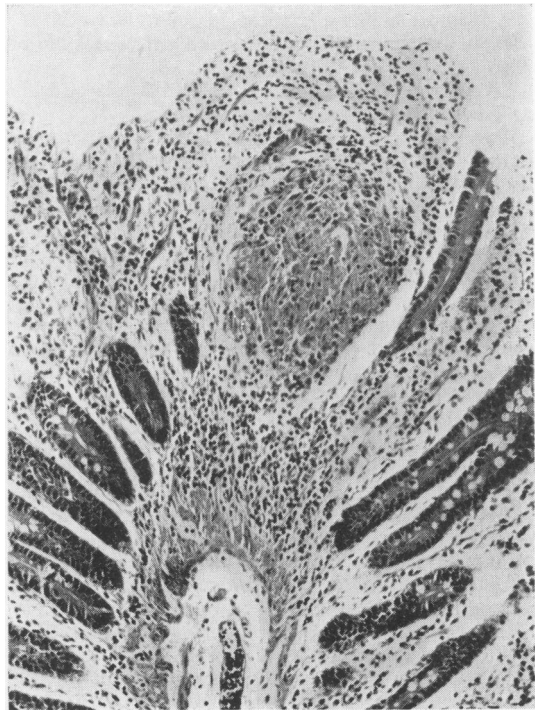

FIG. 4.

mucosa. The main muscle coats were indrawn, so producing the deep external constrictions. The margins of the strictures were usually ulcerated, almost invariably so in the more proximal lesions. The ulceration was superficial but destroyed the muscularis mucosae. The adjacent tissues and mucosa showed moderate chronic inflammatory change with heavy lymphocytic plasma cell and polymorph infiltration, but the change was mostly superficial and the core of the fold showed only relatively little focal plasma cell and lymphocytic infiltration. Many sections were examined and occasional follicles of epithelioid cells were encountered, but always in the mucosa only (Fig. 4). The lymph nodes showed simple reactive changes.

CASE 2 A man, aged 46, was admitted to St. James's Hospital, Leeds, for laparotomy in June 1961. For 10 years he had experienced abdominal pain after food. The pain was central, colicky in character, accompanied by a feeling of fullness, and occurred about one hour after a meal. The attacks were episodic with free periods up to three months. Vomiting occurred frequently, often with relief of pain, but alkalis were not effective. Weight was steady and the bowels normal. There was no history of diarrhoea in the past.

He had been investigated on three occasions, including barium meals, and with normal findings each time.

Physical examination revealed no abnormality.

The blood picture was normal with a haemoglobin of 82%.

A barium meal (Dr. Rowden) showed no abnormality in the oesophagus, stomach, or duodenum.

The severity of the pain was such that the patient was afraid to eat and his symptoms appeared to be so genuine that laparotomy was undertaken.

Operation The stomach and duodenum, gall bladder, and pancreas were normal. There were four strictures in the small gut. Three, separated by intervals of 6 in. were in a group, 3 ft. from the duodeno-jejunal flexure, and a fourth, solitary one 3 ft. from the ileo-caecal junction. Between the middle and distal strictures of the upper group was a solitary, hard enterolith which was quite unable to pass either way. There were no associated enlarged lymph nodes, and minimal dilatation of the bowel was evident proximally.

The upper group of strictures was by-passed by a side-to-side entero-anastomosis. The enterolith was too hard to break up and was removed through a small incision. The lower, solitary stricture was excised and continuity restored by end-to-end anastomosis.

The post-operative course was quite uneventful, and the patient was well and without complaints when seen two and a half years later.

Pathology The operative specimen consisted of a piece of small bowel 4.5 cm. in length with a central constriction. Tortuous vessels were evident on the serosa. At the site of the stricture the lumen was almost completely occluded by a circular valve of mucosa with a small orifice at the centre (Fig. 5).

The histological structure (Fig. 6) proved very similar to that in case 1, except that the main muscle coats were drawn right up into the stricture and merged with the

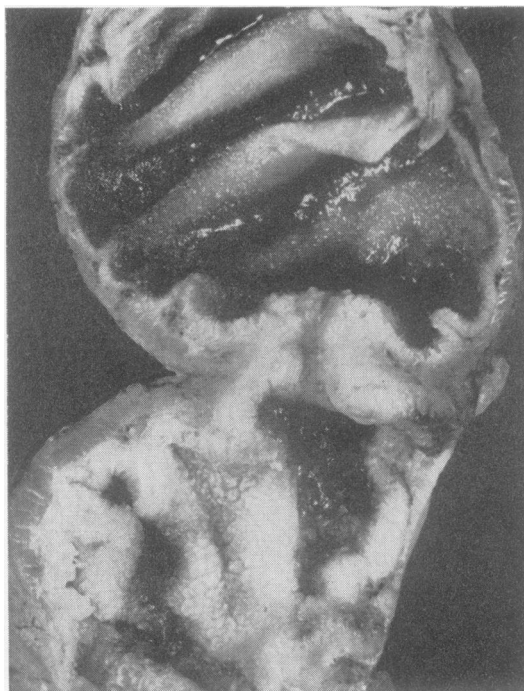

FIG. 5. A longitudinal section through the ileal stricture in case 2 ($\times 2.4$).

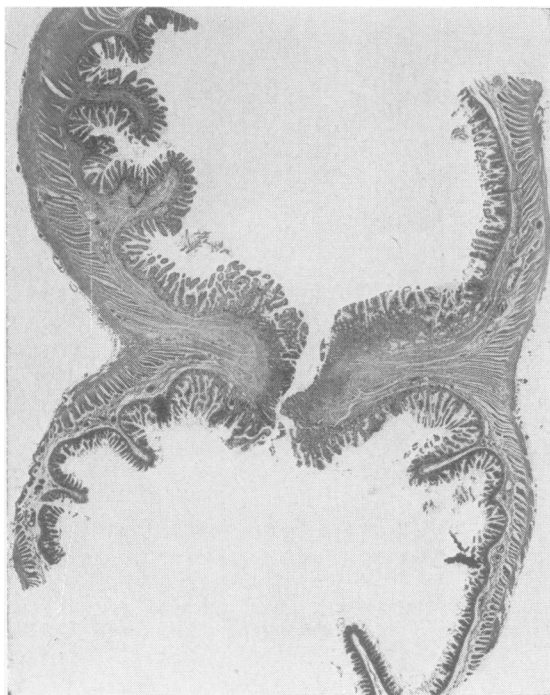


FIG. 6. A low-power photomicrograph of Figure 5 ($\times 4.5$).

muscularis mucosae. Though there was no actual ulceration to be seen there was evidence of mucosal regeneration. There was also moderate, superficial lymphocytic eosinophil and plasma cell infiltration. Little fibrosis was evident in the core of the fold.

DISCUSSION

The clinical symptoms of these two patients were similar in that both experienced colicky abdominal pain relieved by vomiting. In the first patient, it was noted that the pain was quite different in character from that which preceded gastrectomy. Owing to the fluid nature of the normal jejunal contents it is likely that the strictures became manifest only because of certain additional factors. In the first patient pieces of unbroken food could pass through the gastrectomy stoma, and in the second there was the enterolith. The strictures might well have remained symptomless but for these two events.

In neither patient were there any other symptoms of small bowel dysfunction except for colic. Diarrhoea was absent and the blood pictures showed no evidence of a macrocytic anaemia in spite of a history which, in the second man, extended over a number of years.

The treatment of the condition, once found, is fairly obvious. It is considered that excision of the affected segment of bowel is the treatment of choice and not a bypass, as was done on the upper group in the second patient. There is a chance that a 'blind loop' syndrome will develop because of the bypass.

There are many diverse causes of strictures of the small intestine but intrinsic strictures are uncommon. Congenital atresia and strictures are usually incompatible with life and although a few alleged examples in adults have been recorded, adequate proof of their congenital nature would be difficult to establish. It seems most probable that our pathological findings are examples of Crohn's disease (regional enteritis). This commonly affects the distal part of the ileum but there may be associated jejunal lesions or the disease may be restricted to the jejunum.

Van Patter, Barga, Dockerty, Feldman, Mayo, and Waugh (1954) in 315 cases of regional enteritis found that nine affected ileum and jejunum and that 11 were confined to the jejunum. In a series of 100 patients Rappaport, Burgoyne, and Smetana (1951) encountered eight jejunal examples. In one instance with multiple lesions there was also a typical lesion in the terminal ileum and another later involved the terminal ileum. Ginzburg, Marshak, and Eliasoph (1960) reported 22 cases of the jejunal form.

Jejunal Crohn's disease does appear to differ in certain respects from the characteristic 'hose-pipe' terminal ileal lesion. The formation of fistulae and sinuses is said to be uncommon and multiple areas of stenosis more frequent. Ginzburg *et al.* state that stenosis with obstruction is more common and that areas of involvement are much shorter and frequently annular, multiple segments being commonly encountered. They also consider that ulceration and perforation are less common and that less mesenteric thickening is evident.

In both our patients the lesions consisted of little more than mucosal diaphragms, were multiple, and in one instance there was an associated ileal lesion of similar character. We have not encountered anything comparable in a survey of the literature but feel that the likelihood is that these strictures are atypical variants of Crohn's disease. The disease as such in our patients appears to be in a quiescent phase, borne out by the lack of recurrence of symptoms after four years and two and a half years respectively.

We wish to thank Mr. H. S. Shucksmith for his kind permission to allow us to publish these findings.

REFERENCES

- Ginzburg, L., Marshak, R. H., and Eliasoph, Joan (1960). Regional jejunitis. *Surg. Gynec. Obstet.* **111**, 626-632.
Rappaport, H., Burgoyne, F. H., and Smetana, H. F. (1951). The pathology of regional enteritis. *Milli. Surg.*, **109**, 463-502.
Van Patter, W. N., Barga, J. A., Dockerty, M. B., Feldman, W. H., Mayo, C. W., and Waugh, J. M. (1954). Regional enteritis. *Gastroenterology*, **26**, 347-450.