

Methods and techniques

Crosby small-intestinal capsule with radio-opaque tube and latex sheath

S. N. SALEM, R. H. SALT, AND S. C. TRUELOVE *From the Nuffield Department of Clinical Medicine and the Nuffield Department of Anaesthetics, Radcliffe Infirmary, Oxford.*

We have met four technical difficulties when using the Crosby biopsy capsule (Crosby and Kugler, 1957): 1 difficulty in localizing the capsule in the alimentary tract; 2 occasional difficulty in withdrawing the capsule through the pylorus; 3 loss of the dome of the capsule in the intestine; 4 uncertainty as to whether the capsule has 'fired'. These difficulties have been overcome in the following ways.

LOCALIZATION

The Odman-Ledin red arterial catheter (approximately 1 mm. bore and 2 mm. diameter) is sufficiently radio-opaque to show plainly on radiographs of the abdomen

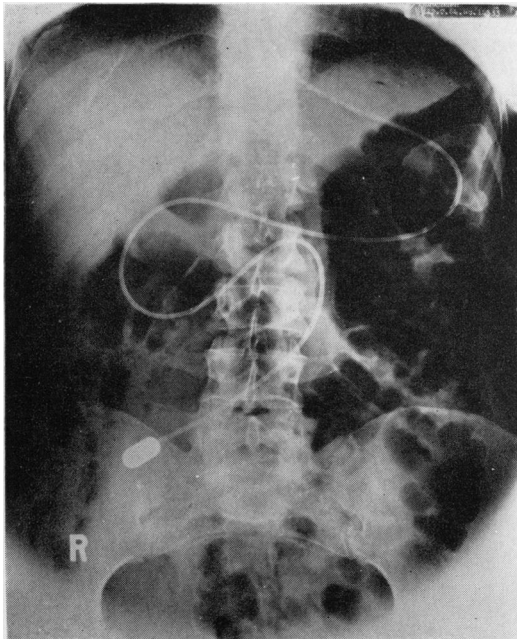


FIG. 1. Radiograph showing Crosby capsule in small intestine.

(Fig. 1). It has the additional advantage of being rigid enough to help introduction into the throat and to prevent coiling in the throat. It does not kink in the alimentary tract, and if indented by the patient's teeth, the marks may be removed by immersing the tube in water at 70°C. for one minute and then hanging the tube vertically until cool. The tube described by Cox (1963) is less radio-opaque and lacks the other advantages.

WITHDRAWAL

Intravenous injection of 15 mg. propantheline bromide in 10 ml. of normal saline will relax pyloric spasm within a few minutes.

LOSS OF DOME

The dome of the capsule sometimes comes apart from the capsule in the patient's intestine. To prevent this, the manufacturers provide a spring clip to hold the dome in place, but with this there is always a possibility of tearing the mucosa during withdrawal of the capsule. We have replaced this spring clip by a latex sheath which holds the dome firmly and covers the edges of the diaphragm (Fig. 2).¹ This ensures a streamlined surface

¹The latex sheath was originally made by one of us (R.H.S.) but it is now manufactured by Eschmann Bros. and Walsh Ltd. and is available from The Genito-Urinary Manufacturing Company, 28a Devonshire Street, London, W.1.

The British agents for the Kifa catheters are Messrs. A. S. Williamson, Harting, Petersfield, Hants.

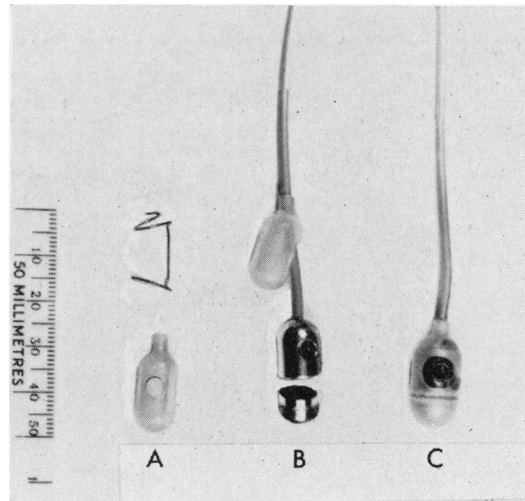


FIG. 2. Details of the latex sheath.

A The spring clip (above) and the latex sheath which replaces it.

B The latex sheath slipped up the tube so that the Crosby capsule can be taken apart.

C The latex sheath in position over the capsule ready for use.




FIG. 3. Details of the flexible connector. A Radio-opaque tubing leading to the Crosby capsule B Hard polythene or metal connector C Flexible vinyl tubing D Hard polythene or metal connector for attaching syringe.

which makes swallowing the capsule much more easy for the patient and also makes withdrawal easy. The latex sheath has a thin wall and does not interfere with the functioning of the capsule. To fit the latex sheath, the proximal connector is removed and the sheath is threaded over the tubing as shown in Fig. 2B; once fitted, the same latex sheath can be used for a number of biopsy examinations.

Since we began to use the latex sheath we have performed 60 jejunal biopsies with no difficulty and have had no occasion to use propantheline bromide. The spring clip, which the latex sheath replaces, prevents the Crosby capsule from being completely smooth and may therefore encourage pyloric spasm, as well as making swallowing more difficult than with the latex sheath.

ENSURING 'FIRING' OF CAPSULE

This has been achieved by a small fitting interposed between the syringe by which suction is applied and the tubing of the Crosby capsule. The fitting consists of two

Catalogue no. 8E Portex tubing, manufactured by Portland Plastic, Ltd., Hythe, Kent.

hard connectors, one at each end, with a length of soft vinyl tubing between them (Fig. 3). When suction is applied, the flexible vinyl tubing collapses under the influence of the suction, the two sides coming into apposition. The essential point is to wait a few seconds (about 5) because, if the tubing remains collapsed, this is a sign that the capsule has fired. If, after collapsing, the tube opens up again almost immediately, it is a sign that the hole in the capsule was not plugged by mucosa but merely with mucus or food debris and the capsule has not fired. Since employing this modification, more than 50 small-intestinal and gastric biopsy examinations have been done with 100% success.

The exact specification of the flexible vinyl tubing² is as follows: length = 5 cm., external diameter = 6 mm., internal diameter = 4 mm.

REFERENCES

- Cox, A. G. (1963). Easier localization of the Crosby capsule in the alimentary tract. *Gut*, 4, 413.
 Crosby, W. H., and Kugler, H. W. (1957). Intraluminal biopsy of the small intestine. *Amer. J. dig. Dis.*, 2, 236-241.