

## The stomach in tropical sprue

S. K. VAISH, J. SAMPATHKUMAR, R. JACOB, AND S. J. BAKER

*From the Wellcome Research Unit, Christian Medical College Hospital,  
Vellore, South India*

**EDITORIAL SYNOPSIS** The authors describe the results of a study of the gastric secretion and gastric histology of 15 control subjects and 30 patients with tropical sprue. Patients with sprue show a marked depression of gastric secretion and varying degrees of gastritis as compared with control subjects. There is no relation between the severity of the gastric lesion and the severity of the intestinal lesion. The possible aetiology of the gastritis is discussed.

For many years it has been shown that hypochlorhydria and achlorhydria may occur in cases of tropical sprue (Baumgartner and Smith, 1927; Serra, 1929; Fairley, 1930). However, these observations were made before the development of standardized techniques for evaluating gastric secretion. The introduction of the augmented histamine test by Kay (1953), and its widespread use in many centres, has enabled accurate and reproducible studies of gastric acid secretion to be carried out.

This paper reports the results of augmented histamine test meals and gastric biopsies in control subjects and in a group of patients with tropical sprue, and the correlation of these findings with other investigations.

### MATERIAL AND METHODS

Thirty male patients aged 15 to 50 years (mean 32.8 years) with tropical sprue, and 15 suitable control male subjects of similar age (range 18-40 years, mean 30.0), socio-economic status, and dietary habits were studied. The patients with tropical sprue all had steatorrhoea, radiological changes in the small intestine, and other evidence of malabsorption (Baker, 1957; Paterson and Baker, 1958). All the control subjects had a normal fat balance, normal d-xylose excretion, and normal radiological findings on barium meal examination. Five control subjects suffered from iron-deficiency anaemia, the remainder were apparently normal. All the patients and the control subjects were South Indians belonging to the lower socio-economic group.

Gastric function was studied by the augmented histamine test (Kay, 1953). After an overnight fast, a radio-opaque tube was passed into the stomach and adjusted under fluoroscopic control until its tip lay in the gastric antrum. The tube was connected to a continuous suction apparatus and the fasting contents aspirated. Throughout the period of the test an attendant ensured the patency of the tube at frequent intervals.

The gastric secretion was collected for one hour under basal conditions. An injection of 25 mg. of mepyramine maleate (Anthisan) was given 30 minutes after the commencement of the collection of the basal secretion. At the end of the basal hour, histamine acid phosphate, 0.04 mg./kg. body weight, was injected subcutaneously. After the histamine injection, the gastric secretion was collected for a further one hour, in four 15-minute pools. Free and total acidity were measured by titrating against freshly prepared N/10 NaOH using Topfer's reagent and phenolphthalein as indicators. The total output of free acid during the post-histamine hour has been termed the 'maximal acid output'. The total output of free acid during the half-hour period from 15 to 45 minutes after the histamine injection has been termed the 'maximal histamine response'. Duplicate or triplicate tests were done in each subject within a few days of each other and the final result expressed as a mean of the observations. In some cases, a number of duplicate tests were done before, during, and after the correction of anaemia.

Multiple gastric biopsies were taken in all cases from the body of the stomach by Wood's suction gastric biopsy tube (Wood, Doig, Motteram, and Hughes, 1949) used under fluoroscopic control. The histology of the gastric biopsy specimens was evaluated 'blind' without knowledge of the subject they came from, or of the results of the augmented histamine test, and were classified into four groups according to following criteria:—

Group I Normal gastric mucosa.

Group II Superficial gastritis, namely, varying degrees of cellular infiltration of the lamina propria with round cells, plasma cells, and polymorphs, but little or no atrophy of the glands.

Group III Mild to moderate atrophic gastritis, namely, varying degrees of cellular infiltration of the lamina propria with mild to moderate atrophy of the gastric glands.

Group IV Severe atrophic gastritis, namely, severe atrophy of the mucosa with distorted glands, and cellular infiltration varying from slight to marked.

Jejunal biopsies were performed with a multiple retrieving intestinal biopsy tube (Baker and Hughes, 1960) or a Crosby capsule (Crosby and Kugler, 1957).

Daily 24-hour faecal fat estimations were done by the method of van de Kamer, ten B. Huinink, and Weyers (1949). Xylose absorption was studied by feeding 5 g. of d-xylose to the fasting subject, and estimating the amount excreted in the urine during the next five hours.

Haematological investigations were carried out as described by Dacie (1956). Vitamin B<sub>12</sub> absorption was studied by the faecal excretion method (Heinle, Welch, Scharf, Meacham, and Prusoff, 1952) using a 1 µg. dose of labelled vitamin B<sub>12</sub> containing 0.25 µc of Co<sup>58</sup>.

RESULTS

**ACID SECRETION** In the control subjects the maximal acid output varied from 3.6 to 29.4 mEq. with a mean of 17.3 (standard error 1.80) (Fig. 1). The results of duplicate tests were in general in good agreement, the coefficient of variation of the maximal acid output being 6.2%.

In the patients the maximal acid output ranged from 0 to 14.0 mEq. with a mean of 4.9 (standard error 0.75) (Fig. 2). Four patients had complete achlorhydria. The pH of the gastric juice in these four cases was 7.0 to 7.4. The difference between the mean maximal acid output of the control and patient groups is statistically significant ( $t = 6.39, P < 0.001$ ).

The maximal histamine response in the controls varied from 2.3 to 21.2 mEq. with a mean of 10.8 (standard error 1.19). In the patients the maximal

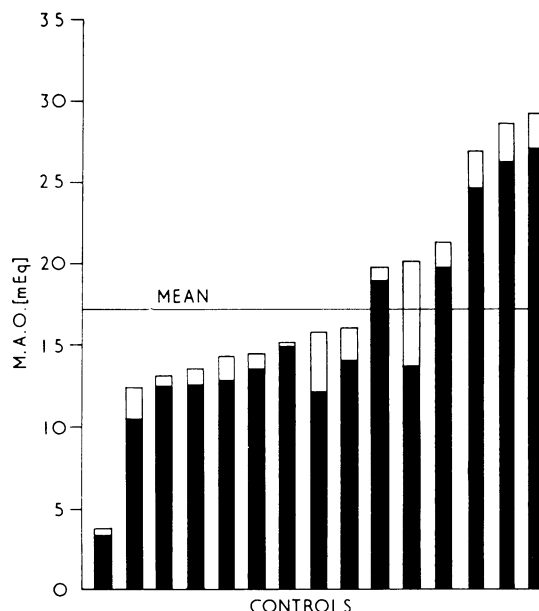


FIG. 1. Maximum acid output in milliequivalents in control subjects. Duplicate estimations were done in each case, the lower value being represented by the black column and the higher by the open column.

histamine response ranged from 0 to 9.5 mEq. with a mean of 3.0 (standard error 0.5). The difference between the means of the two groups is statistically significant ( $t = 6.07, P < 0.001$ ).

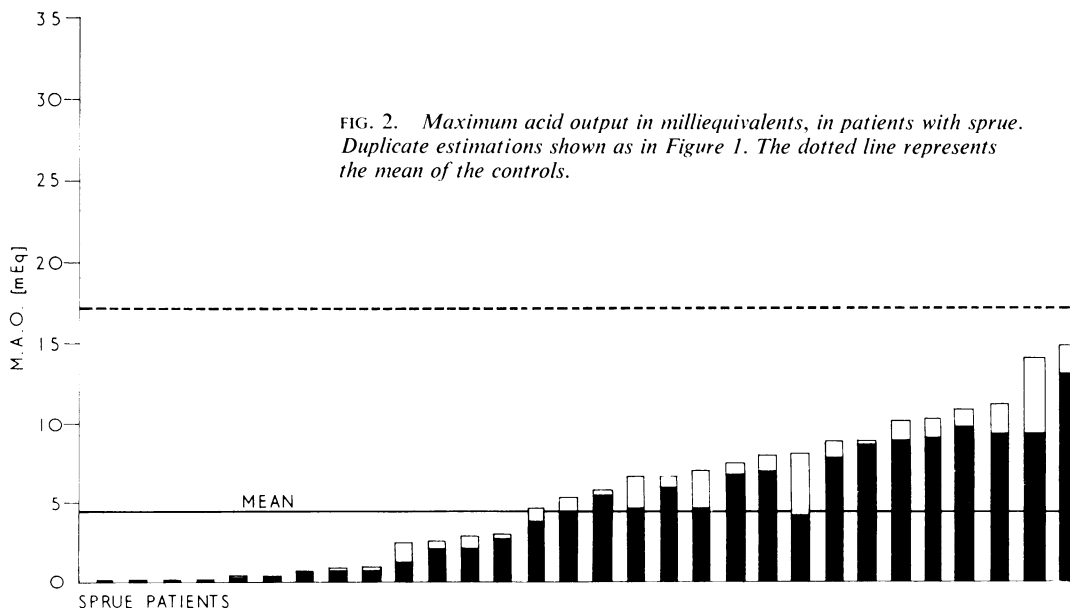


FIG. 2. Maximum acid output in milliequivalents, in patients with sprue. Duplicate estimations shown as in Figure 1. The dotted line represents the mean of the controls.

**GASTRIC BIOPSIES** In 12 of the control subjects gastric biopsies were within normal limits (group I). Two had mild superficial gastritis with cellular infiltration of the lamina propria with plasma cells, round cells, and polymorphs. but no atrophy of the mucosa (group II), and one had cellular infiltration with moderate atrophy (group III).

In the patients three had apparently normal mucosa (Fig. 3); 10 had superficial gastritis (group II) (Fig. 4); 13 had varying degrees of cellular infiltration of the lamina propria with varying degrees of atrophy of the mucosa (group III) (Fig. 5); and the remaining four patients had severe atrophic gastritis (group IV) (Fig. 6).

The relation between the maximal acid output and the histological appearances of the gastric biopsies is shown in Figure 7. The mean maximal acid output of all subjects (control and patients) in group I was 17.4 mEq.; in group II, 8.3 mEq.; in group III, 3.2 mEq.; and in group IV all subjects had achlorhydria.

No correlation was found between the histo-

logical appearances of gastric and jejunal biopsies. Similarly no correlation was found between the maximal acid output and the d-xylose excretion (Fig. 8), the fat excretion (Fig. 9), or the jejunal biopsies.

**GASTRIC SECRETION AND ANAEMIA** The maximal acid output in the five control subjects who had an iron-deficiency anaemia with a haemoglobin of less than 10 g./100 ml. ranged from 11.7 to 15.6 mEq. with a mean of 13.5.

In the patient group the haemoglobin ranged from 3.4 to 15.3 g. with a mean of 9.4. Sixteen patients had a haemoglobin level of 10 g. or less, together with a megaloblastic bone marrow. The mean maximal acid output in these patients was 4.83, and in patients with haemoglobin above 10 g. it was 4.86. Of the 16 patients with haemoglobin of less than 10 g., seven were examined before, during, and after treatment. In six there was no change in maximal acid output after treatment of the anaemia (Fig. 10). However in one case (Vi)

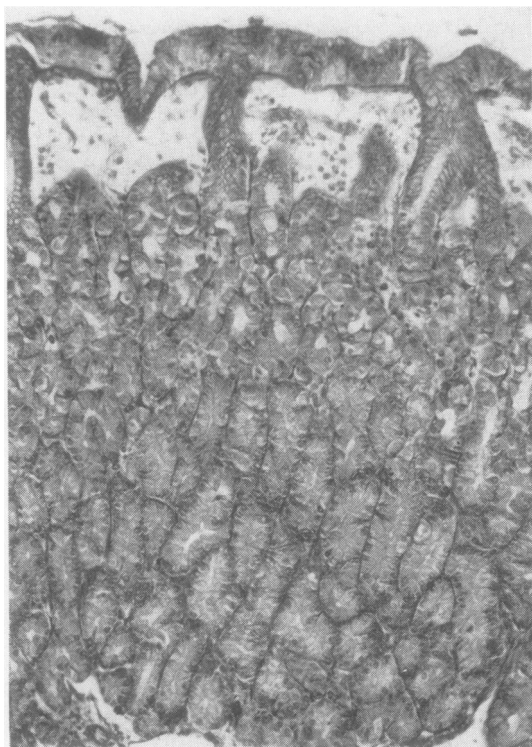


FIG. 3.

FIG. 3. Gastric biopsy from a patient with sprue showing normal gastric mucosa (group I) (haematoxylin and eosin  $\times 100$ ).

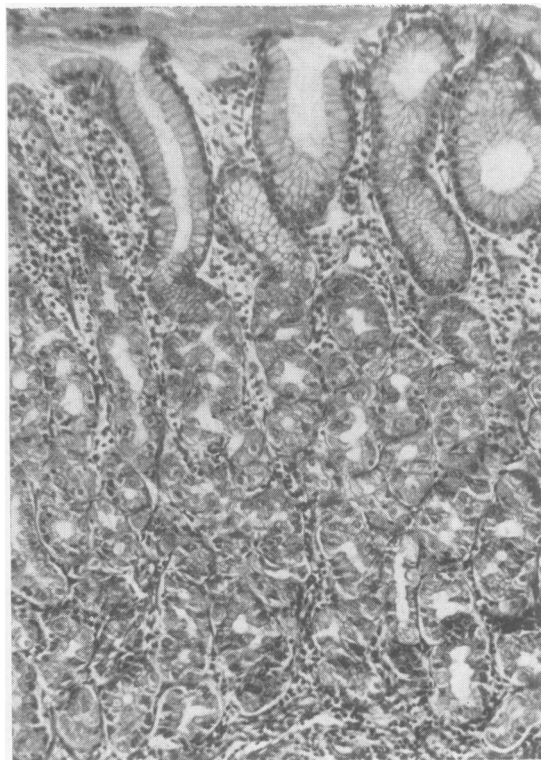


FIG. 4.

FIG. 4. Gastric biopsy from a patient with sprue showing cellular infiltration of the lamina propria, but little or no atrophy (group II) (haematoxylin and eosin  $\times 100$ ).

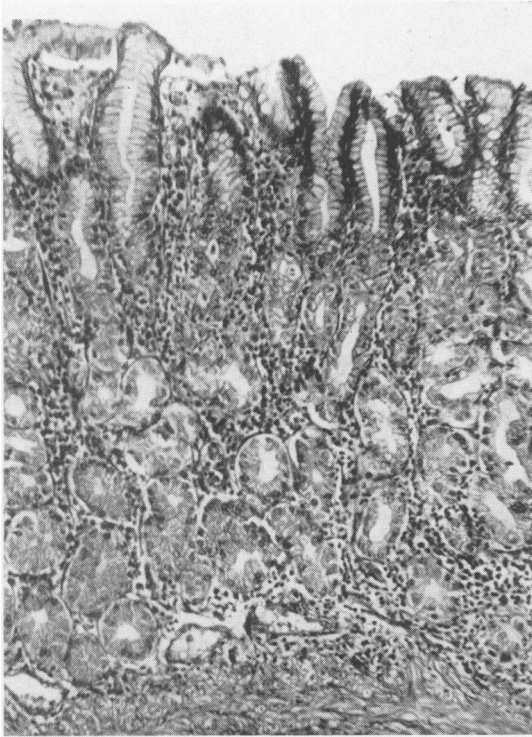


FIG. 5.

FIG. 5. Gastric biopsy from a patient with sprue showing marked cellular infiltration of the lamina propria together with some atrophy of the gland structure (group III) (haematoxylin and eosin  $\times 100$ ).

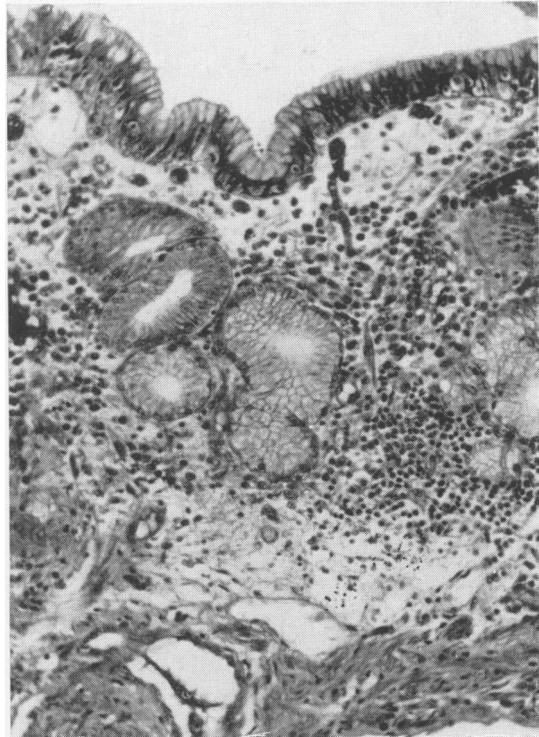


FIG. 6.

FIG. 6. Gastric biopsy from a patient with sprue showing moderate cellular infiltration of the lamina propria and marked atrophy of the gland structure (group IV) (haematoxylin and eosin  $\times 100$ ).

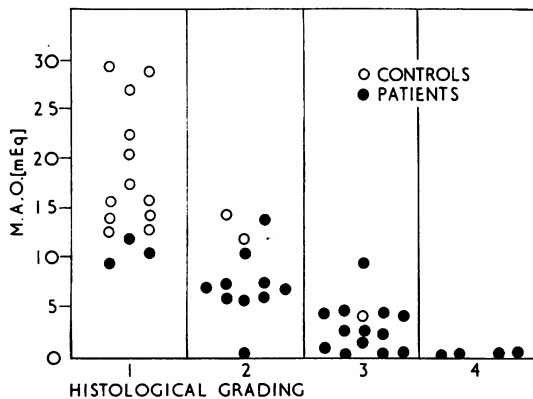


FIG. 7. Relation between maximal acid output and the histological grading of gastric biopsies.

there was a marked improvement in acid secretion coincident with the correction of the megaloblastic anaemia and improvement in the patient's general

condition as shown by a decrease in steatorrhoea and increase in body weight (Fig. 11).

**VITAMIN B<sub>12</sub> ABSORPTION** One third of the patients absorbed less than 0.25  $\mu\text{g}$ . of vitamin B<sub>12</sub> when the dose was given alone. All of these subjects showed no significant increase in absorption when the test was repeated with added intrinsic factor. In fact absorption was sometimes depressed further when extra intrinsic factor was given with the test dose.

Patient N. was studied over a three-year period (Table I). When first seen in 1961 he had steatorrhoea, defective vitamin B<sub>12</sub> absorption with and without added intrinsic factor (Fig. 12), histamine-fast achlorhydria, and marked atrophy of the gastric mucosa with pseudo-villus formation (Fig. 13). When seen again in 1962 he still had steatorrhoea, his vitamin B<sub>12</sub> absorption without intrinsic factor was still defective but with added intrinsic factor was now normal. In 1963 the steatorrhoea had cleared up and the vitamin B<sub>12</sub> absorption tests were similar to those in 1962 (Fig. 12). Throughout

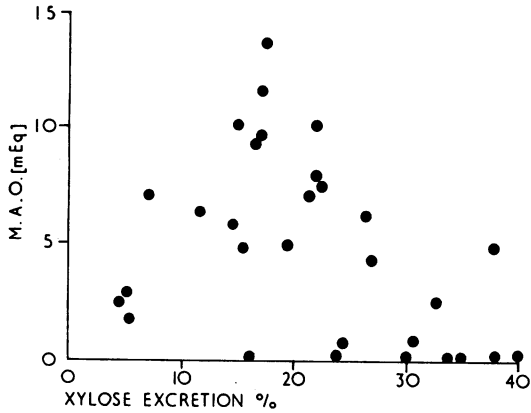


FIG. 8.

FIG. 8. Relation between maximal acid output and xylose excretion as a percentage of an oral dose.

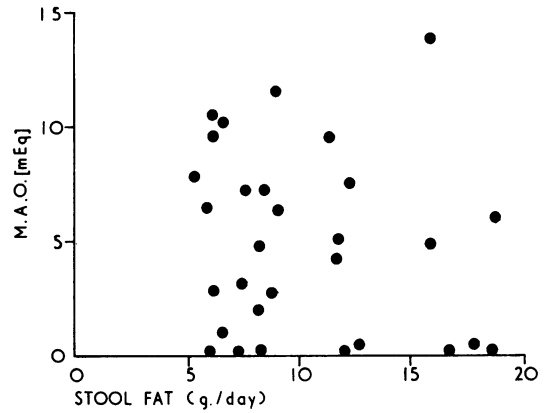


FIG. 9.

FIG. 9. Relation between maximal acid output and stool fat excretion (three-day mean).

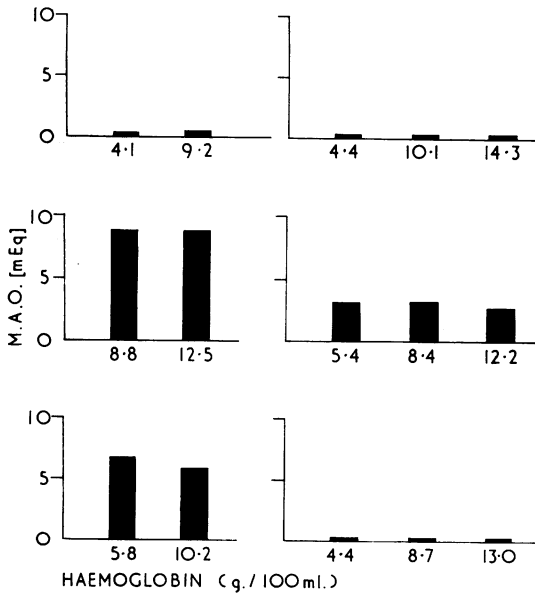


FIG. 10. Maximal acid output in six patients before and after treatment of anaemia.

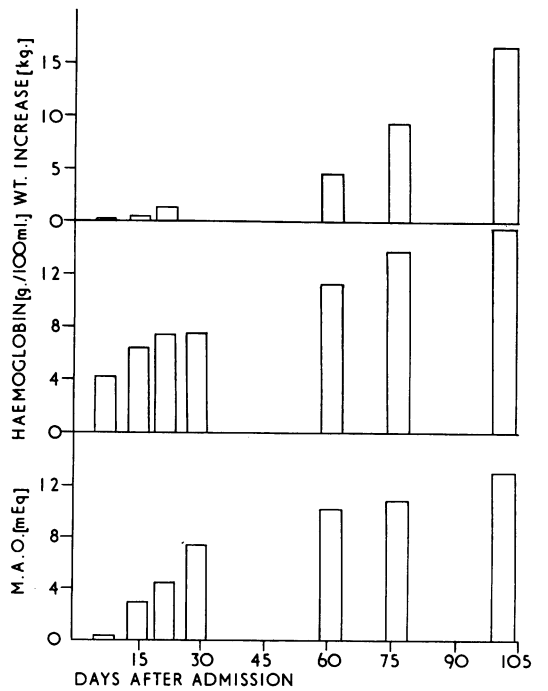


FIG. 11. Maximal acid output, haemoglobin, and weight increase in patient Vi at intervals after admission to hospital.

TABLE I

INVESTIGATIONS IN PATIENT N. 1961-63

Test	Year		
	1961	1962	1963
Hb on admission (g./100 ml.)	4.4	5	9.8
Marrow on admission	Megaloblastic grade III	Megaloblastic grade III	Megaloblastic grade II
Serum B <sub>12</sub> (μμg./ml.)	40	27	33
Serum folic acid (mμg./ml.)	—	15	22
Stool fat (mean of 6 days, in g.)	11	8	3
Barium meal	Dilated jejunal loops and coarse mucosal folds	Dilated loops coarse mucosal folds	Normal
Maximal acid output (mEq.)	0	0	0
Gastric biopsy	Gastric atrophy	Gastric atrophy	Gastric atrophy
Jejunal biopsy (dissecting microscope)	Convulsions and leaves	Ridges and leaves	Leaves
Jejunal biopsy	Partial villus atrophy, cellular infiltration of lamina propria	Almost normal; slight increase in cell infiltration	Normal

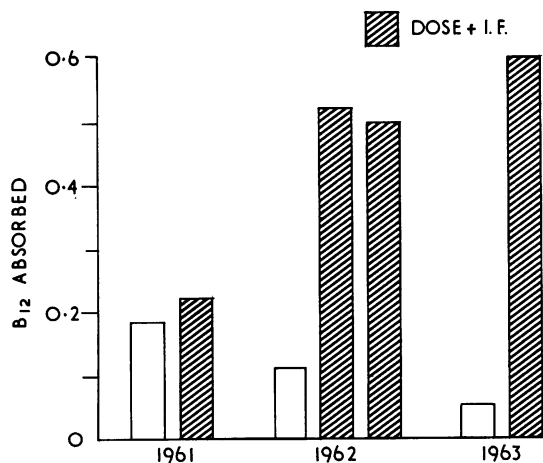


FIG. 12. Patient N. Amount of vitamin B<sub>12</sub> absorbed from a test dose of 1 μg. labelled vitamin B<sub>12</sub>.

FIG. 13. Patient N. Gastric biopsy showing marked gastric atrophy with pseudo-villous formation (haematoxylin and eosin × 100).

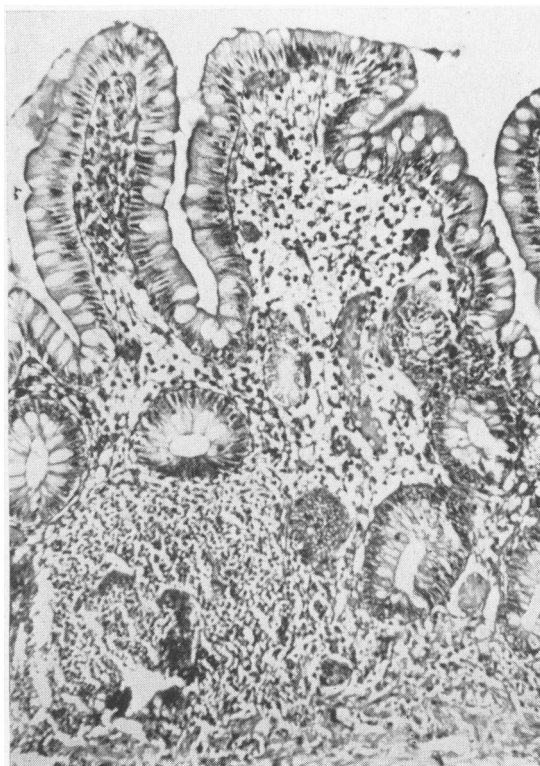

FIG. 13.

the period of observation the results of the augmented histamine test and the gastric biopsy findings were unaltered.

DISCUSSION

**MEASUREMENT OF ACID OUTPUT** The measurement of acid secretion in the control subjects in this series shows a high degree of reproducibility in duplicate tests (coefficient of variation in maximal acid output 6.2% and maximal histamine response 5.6%). The mean maximal acid output of 17.3 agrees well with the mean of 17.0 obtained by Raju, Ganguly, Bhat, and Narielwala (1964) in a

larger group of 40 normal South Indian control subjects. In some of the patients where it was low, duplicate tests gave values of a similar order, but because of the low initial value, slight changes result in a higher percentage variation (mean coefficient of variation for all the patients 20%).

**ACID SECRETION IN SPRUE PATIENTS AND CONTROLS** In this study there is a clear-cut and statistically significant difference in acid secretion between the

control subjects (maximal acid output mean 17.3) and the patients (maximal acid output mean 4.9), thus emphasizing the frequent occurrence of hypochlorhydria in tropical sprue. Floch, Thomassen, Cox, and Sheehy (1963) found hypo- or achlorhydria in 10 out of 18 of their untreated patients. Hansky and Shiner (1963) studied 10 cases of non-tropical sprue by means of the augmented histamine test, and found low acid output in two cases and achlorhydria in four cases. However, the mean age of their patients was 53 and no control subjects were studied, so it is difficult to assess the significance of their findings.

**BIOPSY FINDINGS** In this study a good correlation was observed between the results of the augmented histamine test and the gastric biopsy findings (Fig. 8). A similar correlation was previously observed by Wood *et al.* (1949), Funder and Weiden (1952), and Joske, Finckh, and Wood (1955) before the general introduction of the augmented histamine test.

Floch *et al.* (1963) studied the gastric mucosa in cases of tropical sprue in Puerto Rico, and found that two-thirds had histological evidence of gastritis. However, many of their patients were in the older age group (mean 55.9 years) and unfortunately they did not study the incidence of lesions in a control group, so that it is difficult to evaluate the role of sprue in the causation of the gastric lesion. This is especially so since it has been shown that there is an increasing incidence of gastritis in older patients (Joske *et al.*, 1955; Coghill and Williams, 1958; Mangold, 1960). Moreover, Floch and Meroney (1962) found gastritis in four out of eight non-anaemic control Puerto Rican subjects, suggesting that there may be a high incidence of gastritis in the normal Puerto Rican population irrespective of the incidence of sprue.

Our patients were an unselected group, and in 90% gastric biopsy findings were abnormal, whereas in a group of control subjects only 20% showed any histological abnormalities. Thus both histological findings and secretory studies emphasize the frequent involvement of the stomach in patients with tropical sprue in this region.

**INTRINSIC FACTOR SECRETION** Vitamin B<sub>12</sub> absorption was low (less than 0.25  $\mu$ g.) in one third of the patients, and was not improved by the administration of intrinsic factor. It was therefore not possible to assess the output of intrinsic factor in these cases. In patient N., however, the progression was seen from a typical sprue-like B<sub>12</sub> absorptive defect in 1961 to a pernicious anaemia-like lesion in 1963, when the steatorrhoea and ileal B<sub>12</sub> absorptive defect had

cleared up. If this patient had not been seen previously, in 1963 he could have been diagnosed as a case of classical Addisonian pernicious anaemia. It would therefore appear that tropical sprue may result in damage to the stomach sufficient to cause gastric atrophy with complete achlorhydria and greatly diminished intrinsic factor secretion, such as occurs in true pernicious anaemia.

**AETIOLOGY** The cause of the gastric lesion is unknown. We have confirmed the findings of Floch *et al.* (1963) that there is no relation between the severity of the gastric lesion and the severity of the intestinal lesion.

The role of anaemia in causing gastritis is debatable. Davidson and Markson (1955) and Witts (1956) suggest that iron deficiency as such causes chronic gastritis and achlorhydria. However, Lees and Rosenthal (1958), Coghill (1960), and Ikkala and Siurala (1964) could not find any evidence to support this hypothesis. In five of our control subjects iron-deficiency anaemia was present, but gastric biopsies were normal in four and only slight changes present in one, while gastric acid secretion was in the lower part of the normal range in all. In the sprue patients there was no difference in the mean maximal acid output of those with haemoglobin of 10 g./100 ml. or more, and those with a haemoglobin of less than 10 g./100 ml. In six patients with anaemia the results of the augmented histamine test were similar before and after treatment of the megaloblastic anaemia. In one case only, serial tests showed a gradual and progressive improvement in acid secretion, but little change in biopsy findings. This increased acid secretion was coincident with improvement in the anaemia and in the general condition, so it is not possible to relate the increased acid output specifically to improvement in the anaemia. There is therefore no evidence from this study that anaemia as such affects the gastric function, and it is unlikely that the changes found can be attributed to anaemia alone.

Gastritis has been recorded as occurring in apparently normal subjects, and in a variety of apparently unrelated conditions such as rheumatoid arthritis, ulcerative colitis, Crohn's disease, cirrhosis of the liver (Palmer, 1954; Wood and Taft, 1958; Coghill, 1960; Salem, Truelove, and Richards, 1964). The recorded incidence of gastritis varies in different conditions, and in the same condition studied by different authors. Moreover many of the reported figures are difficult to interpret because of inadequate data on a control population. The very high incidence of hypochlorhydria and gastritis found in this study as compared with the control group may possibly be due to damage to the stomach by the

same agent as damages the small intestine and causes the malabsorption. However, full elucidation of the aetiology of these changes must await further study.

## SUMMARY

Gastric acid secretion and gastric histology were studied in a group of 15 control subjects and in a group of 30 patients with tropical sprue.

Patients with sprue show a marked depression of acid secretion, and varying degrees of gastritis as compared with control subjects.

The gastric damage in sprue may be so severe as to produce gastric atrophy, achlorhydria, and depression of intrinsic factor secretion such as is seen in classical pernicious anaemia.

There was no relation between the gastric lesion and the severity or presence of anaemia, the jejunal biopsy findings, or the small intestinal dysfunction. The possible aetiology of the gastritis is discussed.

We wish to acknowledge with gratitude the help of Sister Thomas and Mr. J. Fernandez. The intrinsic factor used in this study was kindly supplied by Dr. L. Ellenbogen of Lederle Laboratories Limited, New York.

## REFERENCES

- Baker, S. J. (1957). Idiopathic tropical steatorrhea—a report of sixty cases. *Indian J. med. Sci.*, **11**, 687-703.
- and Hughes, A. (1960). Multiple-retrieving small-intestinal biopsy tube. *Lancet*, **2**, 686-687.
- Baumgartner, E. A., and Smith, G. D. (1927). Pernicious anemia and tropical sprue. *Arch. intern. Med.*, **40**, 203-215.
- Coghill, N. F. (1960). The significance of gastritis. *Postgrad. med. J.*, **36**, 733-742.
- and Williams, A. W. (1958). The gastric mucosa in hypochromic anaemia. *Proc. roy. Soc. Med.*, **51**, 464.
- Crosby, W. H., and Kugler, H. W. (1957). Intraluminal biopsy of the small intestine: the intestinal biopsy capsule. *Amer. J. dig. Dis.*, **2**, 236-241.
- Dacie, J. V. (1956). *Practical Haematology*, 2nd ed. Churchill, London.
- Davidson, W. M. B., and Markson, J. L. (1955). The gastric mucosa in iron-deficiency anaemia. *Lancet*, **2**, 639-643.
- Fairley, N. H. (1930). Sprue: its applied pathology, biochemistry and treatment. *Trans. roy. Soc. trop. Med. Hyg.*, **24**, 131-186.
- Floch, M. H., and Meroney, W. H. (1962). Human gastric electrolyte secretion in certain anemias. *Amer. J. med. Sci.*, **244**, 564-574.
- , Thomassen, R. W., Cox, R. S. Jr., and Sheehy, T. W. (1963). The gastric mucosa in tropical sprue. *Gastroenterology*, **44**, 567-577.
- Funder, J. F., and Weiden, S. (1952). The correlation between test meal findings and the histology of the stomachs as shown by gastric biopsy. *Med. J. Aust.*, **1**, 600-602.
- Hansky, J., and Shiner, M. (1963). Gastric studies in idiopathic steatorrhea. *Gastroenterology*, **45**, 49-56.
- Heinle, R. W., Welch, A. D., Scharf, V., Meacham, G. C., and Prusoff, W. H. (1952). Studies of excretion (and absorption) of  $CO^{14}$ -labelled vitamin  $B_{12}$  in pernicious anemia. *Trans. Ass. Amer. Phycns*, **65**, 214-222.
- Ikkala, E., and Siurala, M. (1964). Gastric lesion in iron deficiency anaemia. *Acta haemat. (Basel)*, **31**, 313-324.
- Joske, R. A., Finckh, E. S., and Wood, I. J. (1955). Gastric biopsy—a study of 1,000 consecutive successful gastric biopsies. *Quart. J. Med.*, **24**, 269-294.
- Kamer, J. H. van de, Huinink, H. ten B., and Weyers, H. A. (1949). Rapid method for the determination of fat in faeces. *J. biol. Chem.*, **177**, 348-355.
- Kay, A. W. (1953). Effect of large doses of histamine on gastric secretion of HCl: an augmented histamine test. *Brit. med. J.*, **2**, 77-80.
- Lees, F., and Rosenthal, F. D. (1958). Gastric mucosal lesions before and after treatment in iron deficiency anaemia. *Quart. J. Med.*, **27**, 19-26.
- Mangold, R. (1960). Die chronische gastritis, ihre Erkennung und Bedeutung. *Helv. med. Acta*, **27**, 439-464.
- Palmer, E. D. (1954). Gastritis: a reevaluation. *Medicine (Baltimore)*, **33**, 199-290.
- Paterson, D. E., and Baker, S. J. (1958). The radiological investigation of the small intestine in tropical idiopathic malabsorption. *J. Fac. Radiol. (Lond.)*, **9**, 183-194.
- Raju, S., Ganguly, P. C., Bhat, H. S., and Narielwala, F. M. (1964). The place of augmented histamine test as a study of gastric acid secretion based on 120 duodenal ulcer patients and 40 controls. *1st Asian Congr. Gastroent. Abstr.*, 10-12.
- Salem, S. N., Truelove, S. C., and Richards, W. C. D. (1964). Small intestinal and gastric changes in ulcerative colitis. *Brit. med. J.*, **1**, 394-298.
- Serra, A. (1929). The relation of sprue to pernicious anemia, with a report on blood changes in 45 cases of sprue. *Amer. J. trop. Med. Hyg.*, **9**, 49-65.
- Witts, L. J. (1956). *Anaemia and the Alimentary Tract. The Relationship between Changes in the Alimentary Tract and Deficiencies of Iron, Folic Acid and Vitamin  $B_{12}$* . (Roy. Coll. Phycns Edinb., Publ. No. 7). R.C.P., Edinburgh.
- Wood, I. J., Doig, R. K., Motteram, R., and Hughes, A. (1949). Gastric biopsy: report of fifty-five biopsies using a new flexible gastric biopsy tube. *Lancet*, **1**, 18-21.
- , and Taft, L. I. (1958). *Diffuse Lesions of the Stomach*. Arnold, London.