

Adenomyoma in the pylorus

I. JANOTA¹ AND P. G. SMITH²

From the Department of Pathology, Royal Free Hospital, London

EDITORIAL SYNOPSIS Two cases of adenomyoma, composed chiefly of Brunner's glands, ducts, and smooth muscle, involving the submucosa and muscle of the pylorus, are described and discussed.

Gland structures in the submucosa and muscle other than carcinoma are amongst the infrequent lesions of the pyloric region of the stomach. While pancreatic tissue accounts for a majority, adenomyoma is rare. Two further examples were recently encountered in partial gastrectomy specimens, and the cases are presented.

CASE REPORTS

CASE 1 A 27-year-old man had epigastric pain, relieved by antacids, occurring two hours after meals, for three years. A clinical diagnosis of peptic ulcer was made. At laparotomy a hard white thickening of the pylorus was found. Partial gastrectomy with closure of the duodenal stump and anastomosis of the stomach and jejunum was performed.

Naked-eye examination revealed a localized thickening up to 1.5 cm., involving the muscle and submucosa of the anterior wall and lesser curve of the pyloric canal for 2 cm., extending into the pyloric sphincter, with minute spaces scattered through the submucosa and muscle.

CASE 2 A 39-year-old woman was treated medically for recurring epigastric and lower chest pain for 12 years. The pain occurred shortly after meals, was aggravated by food, and there were exacerbations with vomiting. A prepyloric gastric ulcer was repeatedly demonstrated by barium meal x-ray examinations, which also showed a persistent narrowing of the pyloric canal with two shallow narrow tracks. Eventually a laparotomy showed, apart from an ulcer in the lesser curve of the stomach, a large firm mass in the anterior wall of the pyloric region and a partial gastrectomy and gastroduodenostomy was performed.

Naked-eye examination showed narrowing of the pyloric canal by a thickening of the submucosa and muscle anteriorly for about 2 cm. The submucosa was firm, grey, up to 0.5 cm. thick, and the muscle up to 1.2 cm. thick. There were spaces in the submucosa and in the underlying part of the muscle.

Present address: ¹Department of Neuropathology, Institute of Psychiatry, The Maudsley Hospital, London. ²Department of Pathology, The London Hospital, London.

MICROSCOPY

CASE 1 The thickening, which was ill defined, included Brunner's glands (Figs. 1 and 2) around ducts lined by columnar epithelium, with occasional cells containing acid mucopolysaccharide. Some of the ducts were dilated and rounded in cross section (Fig. 3) while in others there were epithelial projections into the lumen. The ducts and glands were surrounded by loose connective tissue resembling lamina propria or by closely adjacent muscle bundles. These were either a part of the thickened main muscle coat or ran in the thickened submucosa. Large nerves were present close to some of the deep-seated ducts (Fig. 3). Pancreatic elements were present both in submucosa and in the muscle, and included exocrine glands (Fig. 2), islets of Langerhans (Figs. 4, 5, and 6), and ductules and small ducts (Figs. 5 and 6). In places the pancreatic exocrine and Brunner's acini were intermingled (Fig. 7). Few groups of exocrine pancreatic acini lay in the surface gastric mucosa, which formed a depression communicating with the submucosal part of the lesion (Fig. 2).

CASE 2 The lesion resembled that of case 1, but contained almost exclusively Brunner's glands and ducts (Figs. 8 and 9) and no exocrine pancreatic glands or islets of Langerhans. A very small submucosal nodule was formed by ductules lined by cuboidal epithelium like the pancreatic ductules in the first case. A track ran from the submucosa through the prepyloric mucosa into the lumen of the stomach (Fig. 10). The gastric ulcer was small, chronic, and benign.

DISCUSSION

In both cases the lesion consisted of Brunner's glands and ducts in the muscle and submucosa communicating with the gastric lumen. The communication was suggested by the barium meal x-ray examination in case 2, but in both cases only became apparent in histological section. In case 1 there was, in addition, pancreatic tissue which included islets of Langerhans, exocrine glands, ducts, and ductules. An element of the last may have been present in case 2.

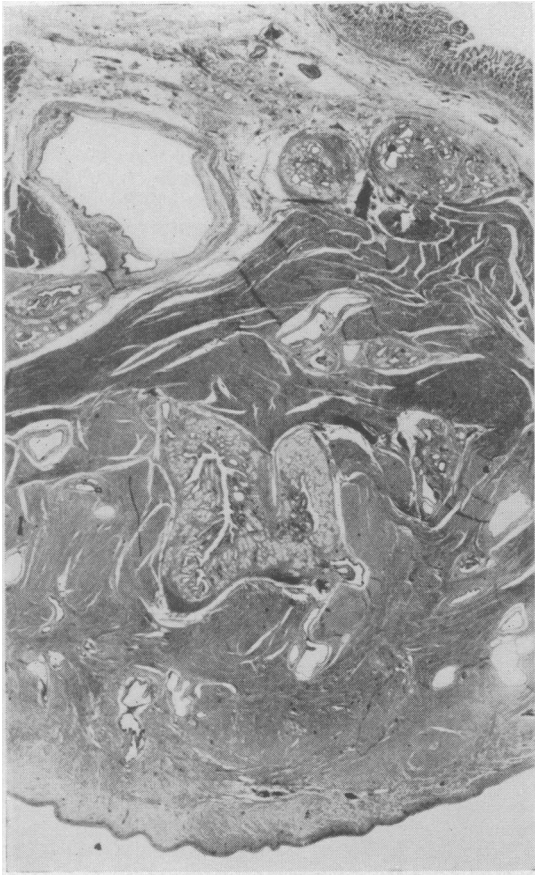


FIG. 1.

FIG. 1. *Full thickness of lesion. Note Brunner's glands deep in the muscle (case 1). Haematoxylin and eosin $\times 8$.*

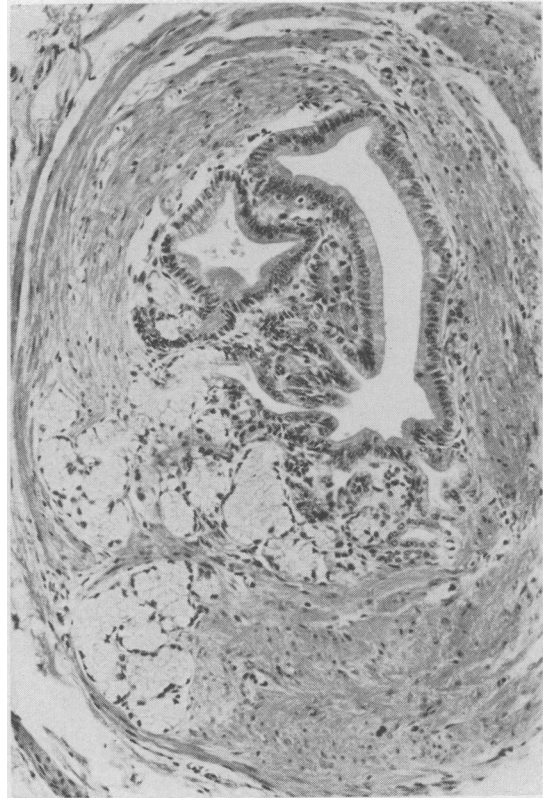


FIG. 2.

FIG. 2. *Pale Brunner's glands embedded in muscle with a system of ducts lined by tall columnar epithelium with occasional vacuoles (case 1). Haematoxylin and eosin $\times 80$.*

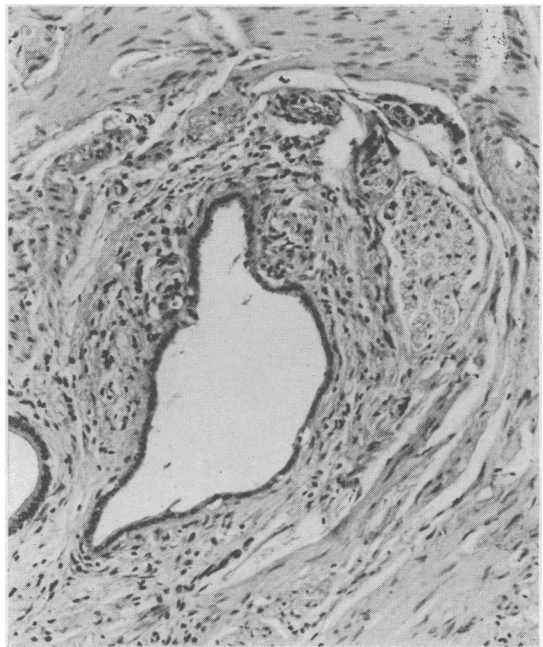


FIG. 3.

FIG. 3. *Ducts and a nerve deep in muscle (case 1). Haematoxylin and eosin $\times 80$.*

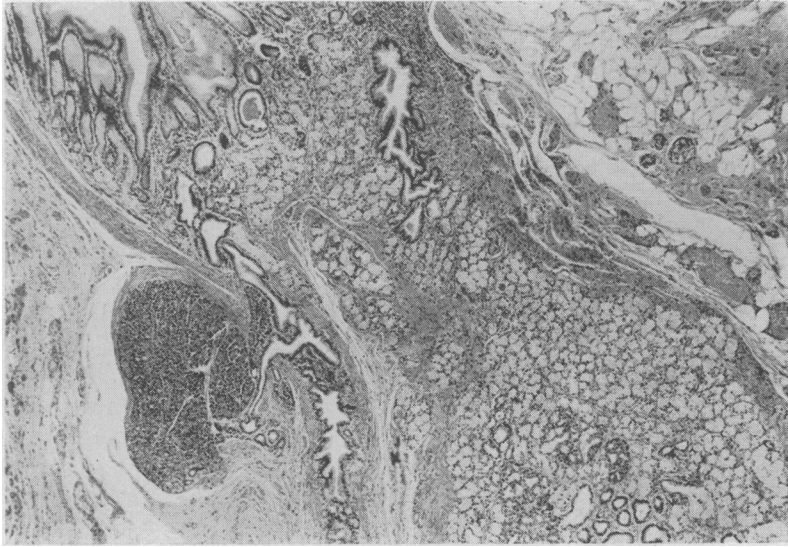


FIG. 4. *Base of depression in pyloric mucosa with ducts connecting with a pancreatic exocrine lobule. Islets of Langerhans and Brunner's glands are also present in the submucosa (case 2). Haematoxylin and eosin $\times 20$.*

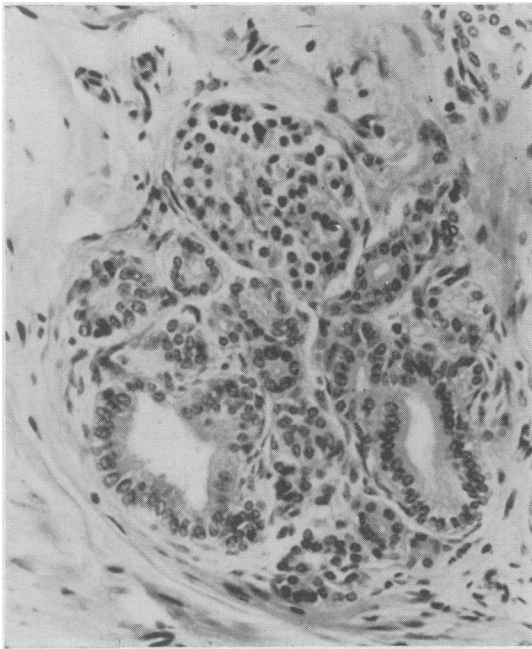


FIG. 5.

FIG. 5. *Islet of Langerhans and pancreatic ductules (case 1). Haematoxylin and eosin $\times 160$.*

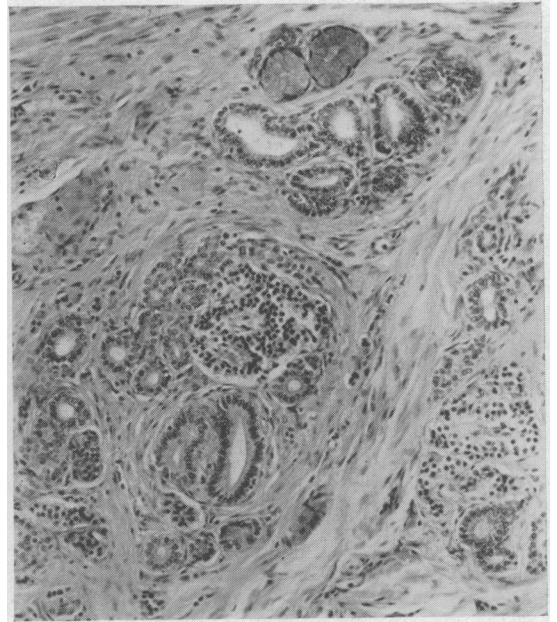


FIG. 6.

FIG. 6. *Islets of Langerhans, pancreatic ductules, small ducts lined by columnar epithelium and two Brunner's acini (case 1). Haematoxylin and eosin $\times 80$.*

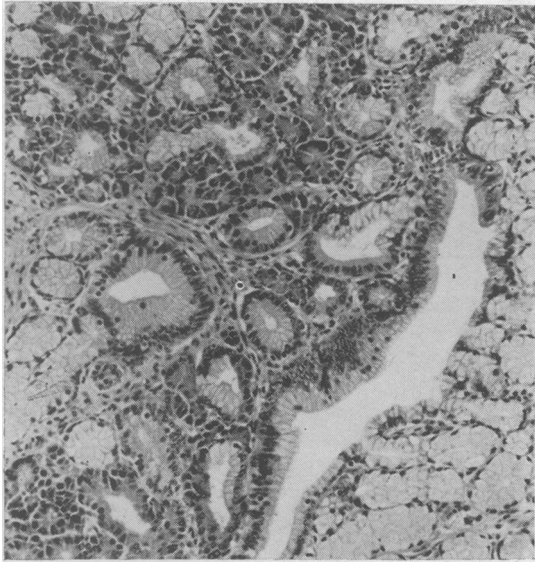


FIG. 7. Intermingled Brunner's and pancreatic exocrine glands (case 2). Haematoxylin and eosin $\times 80$.

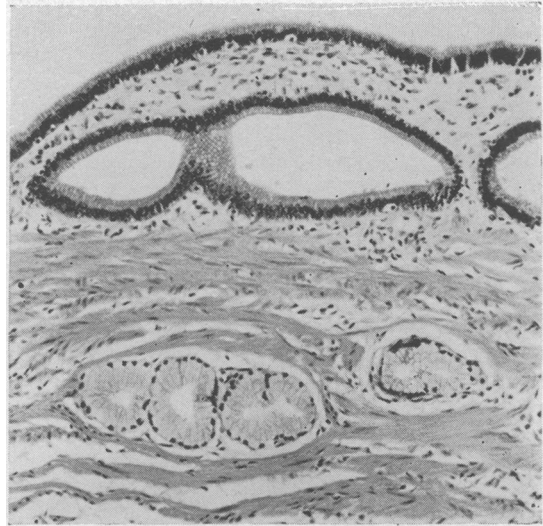

FIG. 9. Loose connective tissue resembling lamina propria around smaller ducts in the wall of a dilated large duct (case 2). Haematoxylin and eosin $\times 80$.

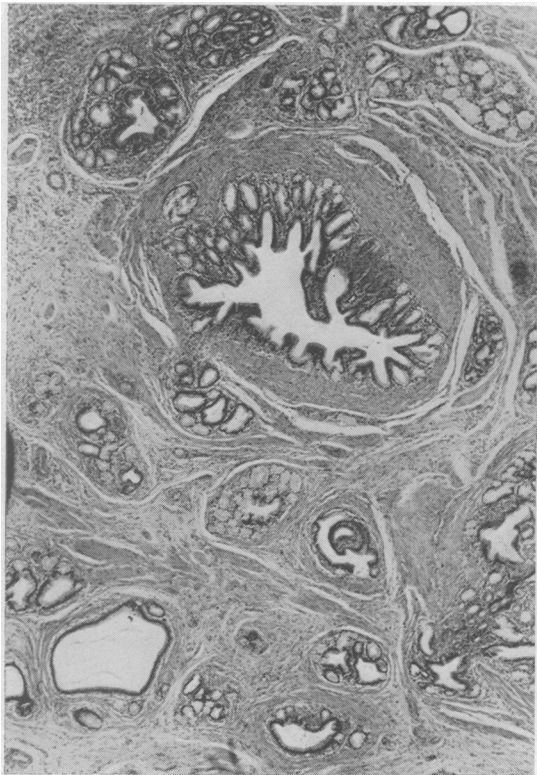


FIG. 8. Ducts and Brunner's glands in submucosa. Note muscle bundles (case 2). Haematoxylin and eosin $\times 20$.

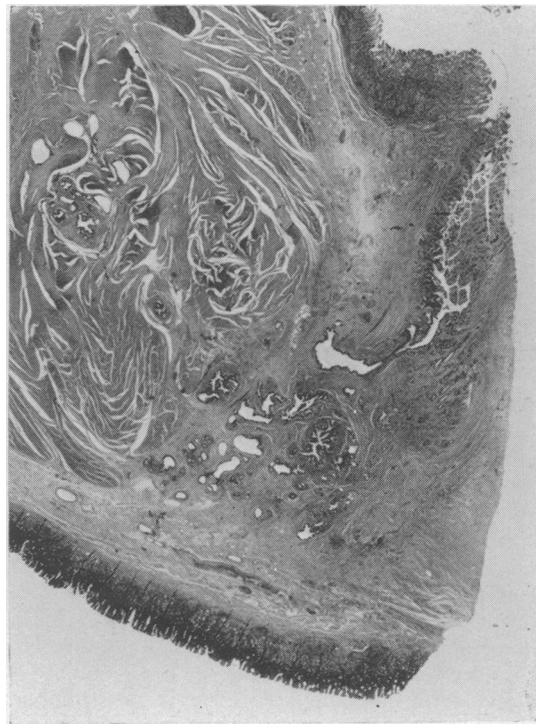

FIG. 10. Lesion in muscle and submucosa communicating with gastric lumen (case 2). Haematoxylin and eosin $\times 5$.

The terminology of the ectopic or heterotopic gland structures in relation to the alimentary canal, amongst which adenomyoma is included (Clarke, 1940), is not definitive. This reflects the inconclusive status of the various aetiological theories, which do not concern us here. In the pyloric region the commonest ectopia is that of pancreatic tissue (Palmer, 1951; Marshall, 1955; Martinez, Morlock, Dockerty, Waugh, and Weber, 1958; Hudson and Richardson, 1959). A depression, a pseudo-diverticulum, over ectopic pancreas with ducts opening into it, which occurs in a proportion of cases, has been stressed by Benner (1951). Such a depression occurred in our case 1, and a communication between the lesion and the gastric lumen in both our cases. Structures described as embryonic, undifferentiated, or incompletely differentiated ducts are often associated with aberrant pancreas at any site, and are not then considered to be a separate entity (Taylor, 1927). The small pancreatic ducts and ductules in our case 1 are the counterparts of what Lauche (1924) called 'incompletely differentiated aberrant pancreas', an excess of duct structures which were not readily related to adult pancreas. The prevalence of Brunner's glands in the lesion was called by Stewart and Taylor (1925) adenomyoma, a term earlier employed for a variety of lesions composed of epithelial structures and smooth muscle in the absence of exocrine pancreatic glands or islets of Langerhans (Askanazy, 1923; Delhougne, 1924; Lauche, 1924). The presence of Brunner's glands, together with pancreatic tissue, in the pyloric lesions is referred to in standard works (Stout, 1953; Willis, 1958; Ackerman, 1964). It seems that some of these lesions have been called Brunner's adenoma (Frantz, 1959), a term better reserved for the rare solid neoplasm of Brunner's glands, of which we have recently encountered an example, generally occurring in the mucosa and submucosa in the duodenum and lacking in ducts or pancreatic tissue (Borow and Hurwitt, 1955). Clarke (1940) employed the term 'myoepithelial hamartoma' to include 'fully differentiated and incompletely differentiated aberrant pancreas', adenomyoma, and any epithelial structure associated with an increased amount of smooth muscle in the alimentary tract. Adenomyoma, as defined by Stewart and Taylor (1925), is confined to the pyloric region of the stomach (Taylor, 1927), with possible exceptions, such as one of Clarke's cases in the duodenum (Clarke, 1940) and some of the duodenal 'Brunner's adenomas'.

The term adenomyoma should not imply a neoplasm or a hamartoma. The terms undifferentiated, incompletely differentiated, or embryonic gland tissue, were prompted by developmental considerations. Evaluation of the appearance of the lesions

and of the natural history of the cases reported earlier does not indicate a neoplastic process. Some of the larger ducts may not be readily identified as a part of any normal structure in the alimentary tract, but this reflects the limitations of morphological method. The demonstration of acid mucopolysaccharide with periodic-acid-Schiff, alcian blue, mucicarmine, and Hale's techniques did not allow a definite classification as gastric, intestinal, biliary, or pancreatic. The close proximity of the small ducts and ductules to pancreatic tissue in the lesion, which has been stressed by Taylor (1927), and their resemblance to pancreatic ducts and ductules, suggest that they are, in fact, pancreatic. The increased amount of smooth muscle in association with the lesions under consideration remains unexplained. The diffuse thickening of the pyloric muscle and excess of smooth muscle in the submucosa does not resemble any neoplasm of smooth muscle. It would seem appropriate to keep the term adenomyoma for a lesion composed of Brunner's glands, ducts, and smooth muscle without or with a pancreatic element because of its distinct appearance at a site where it is likely to be noticed, while agreeing with Clarke (1940) and Lauche (1924) that it is but one of a range of related abnormalities.

SUMMARY

Two cases of adenomyoma in the pylorus are described. Ectopic pancreas is the most likely, if infrequent, ectopic pyloric lesion that any surgeon or pathologist may encounter. It can be symptomless or associated with a plethora of clinical symptoms, shared with adenomyoma. Ectopic pancreas can often be recognized on naked-eye examination by its solid yellowish appearance. The recognition of adenomyoma, a cystic innocent lesion, when carcinoma may have been suspected, remains of practical importance.

We are indebted to Mr. R. H. Maingot and Mr. J. H. Hopewell for permission to publish the cases, to Mr. R. Phillips for assistance with the photomicrographs, and to Dr. G. B. D. Scott for advice.

REFERENCES

- Ackerman, L. V. (1964). *Surgical Pathology*, 3rd ed., p. 380. Mosby, St. Louis.
- Askanazy, M. (1923). Zur Pathogenese der Magenkrebe und über ihren gelegentlichen Ursprung aus angeborenen epithelialen Keimen in der Magenwand. *Dtsch. med. Wschr.*, 49, 3-6, 49-51.
- Benner, W. H. (1951). Diagnostic morphology of aberrant pancreas of the stomach. *Surgery*, 29, 170-181.
- Borow, M., and Hurwitt, E. S. (1955). Benign peripyloric tumours. *Amer. J. Surg.*, 90, 977-985.
- Clarke, B. E. (1940). Myoepithelial hamartoma of the gastrointestinal tract. *Arch. Path.*, 30, 143-152.
- Delhougne, F. (1924). Über Pankreaskeime im Magen. *Langenbecks Arch. klin. Chir.*, 129, 116-123.

- Frantz, V. K. (1959). *Atlas of Tumor Pathology*, fasc. 27 and 28, p. 11. Armed Forces Institute of Pathology, Washington.
- Hudson, R. V., and Richardson, W. W. (1959). Intramural gastric tumours. *Brit. J. Surg.*, **46**, 361-363.
- Lauche, A. (1924). Die Heterotopien des ortsgehörigen Epithels im Bereich des Verdauungskanal. *Virchows Arch. path. Anat.*, **252**, 38-88.
- Marshall, S. F. (1955). Gastric tumors other than carcinoma. *Surg. Clin. N. Amer.*, **35**, 693-702.
- Martinez, N. S., Morlock, C. G., Dockerty, M. B., Waugh, J. M., and Weber, H. M. (1958). Heterotopic pancreatic tissue involving the stomach. *Ann. Surg.*, **147**, 1-12.
- Palmer, E. D. (1951). Benign intramural tumors of the stomach. *Medicine (Baltimore)*, **30**, 81-181.
- Stewart, M. J., and Taylor, A. L. (1925). Adenomyoma of the stomach. *J. Path. Bact.*, **28**, 195-202.
- Stout, A. P. (1953). *Tumours of the Stomach, Atlas of Tumour Pathology*, fasc. 21, p. 22. Armed Forces Institute of Pathology, Washington.
- Taylor, A. L. (1927). The epithelial heterotopias of the alimentary tract. *J. Path. Bact.*, **30**, 415-449.
- Willis, R. A. (1958). *The Borderland of Embryology and Pathology*, p. 317. Butterworths, London.

The February 1966 Issue

THE FEBRUARY 1966 ISSUE CONTAINS THE FOLLOWING PAPERS

- Ischaemic colitis ADRIAN MARSTON, MURRAY T. PHEILS, M. LEA THOMAS, and B. C. MORSON
- Early course of ulcerative colitis J. MCK. WATTS, F. T. DE DOMBAL, G. WATKINSON, and J. C. GOLIGHER
- Auto-immune reactions in ulcerative colitis RALPH WRIGHT and S. C. TRUELOVE
- Some observations on the response of normal human sigmoid colon to drugs *in vitro* P. G. WRIGHT and J. J. SHEPHERD
- Effect of secretin and cholecystokinin-pancreozymin extracts on gastric motility in man L. P. JOHNSON, J. C. BROWN, and D. F. MAGEE
- Inhibition of histamine-stimulated gastric secretion by acid in the duodenum in man D. JOHNSTON and H. L. DUTHIE
- Proteolytic activity in the human stomach during digestion and its correlation with the augmented histamine test S. J. RUNE
- Two cases of acute torsion of the gall bladder MONORANJAN DUARI
- Cirrhosis and hepatoma in alcoholics FRANK I. LEE
- Histochemical study on the Paneth cell in the rat E. O. RIECKEN and A. G. E. PEARSE
- Role of the azygos venous system in the investigation of portal hypertension M. JOHN MURRAY
- Intrinsic factor secretion in gastric atrophy S. ARDEMAN and I. CHANARIN
- The British Society of Gastroenterology

Copies are still available and may be obtained from the PUBLISHING MANAGER
BRITISH MEDICAL ASSOCIATION, TAVISTOCK SQUARE, W.C.1, price 18s. 6d.