

Observations on the mechanism of abdominal pain

D. J. HOLDSTOCK, J. J. MISIEWICZ, AND SHEILA L. WALLER

From the Medical Research Council Gastroenterology Research Unit, Central Middlesex Hospital, Park Royal, London

Abdominal pain is one of the commonest presenting symptoms in gastroenterology. In some patients an organic lesion is responsible but in many others the cause of pain remains obscure, despite thorough investigation. There is some evidence, however, that the motor activity of the colon may be abnormal in patients with various alimentary disorders (Connell, 1959, 1962; Chaudhary and Truelove, 1961; Wangel and Deller, 1965; Misiewicz, Connell, and Pontes, 1966), but very little is known about the relationship between pain and changes of intraluminal pressure in individual patients (Connell, Jones, and Rowlands, 1965). In this paper we present the results of manometric studies in nine patients suffering from attacks of severe abdominal pain for which no cause was found after thorough investigation, including laparotomy in some cases. The attacks seemed to be related to changes in intraluminal pressures in either small or large intestine.

METHODS AND PATIENTS

Intraluminal pressure in the sigmoid and rectum was measured with small (7 × 10 mm) air-filled balloons (Atkinson, Edwards, Honour, and Rowlands, 1957) mounted on narrow tubes and placed through a sigmoidoscope at approximately 25, 20, and 15 cm proximal to the anal margin; the sigmoidoscope was then withdrawn. Pressure in the small intestine and proximal colon was recorded with radiotelemetering capsules (Rowlands and Wolff, 1960), which were located by fluoroscopy and by reference to the characteristics of the pressure record (Connell, McCall, Misiewicz, and Rowlands, 1963; Misiewicz, Waller, Fox, Goldsmith, and Hunt, 1968). The pressures were recorded on a multichannel pen writer; respiration and somatic movements were monitored in all the studies with a stethograph. In some patients measurements were carried out simultaneously in the distal colon and in the small intestine or proximal colon. Patients were asked to indicate the onset of abdominal pain by means of a signal switch which produced an appropriate mark on the record; they were unable to see the pressure trace during the study. The tests were carried out in a quiet room with the subjects resting comfortably on a couch. Motor activity was measured in the fasting state, following the ingestion of a standard meal, and after the injection of 0.75 mg of

prostagline subcutaneously. Intravenous propantheline, 5 to 10 mg, was used to abolish motor activity.

The nine patients described in this study were selected from a larger group referred for manometric investigation of various abdominal symptoms, because abdominal pain, for which no definite cause could be found on routine investigation, was a prominent symptom in all of them. All the patients were normal on physical and sigmoidoscopic examination; their haemoglobin and ESR levels were within normal limits. Barium studies showed no evidence of organic disease. Relevant additional investigations are listed below under individual patients and the findings are summarized in Table 1.

TABLE I

Patient No.	Clinical Diagnosis	Correlation of Intraluminal Pressure with Pain	Site of Pressure Activity
1	Postgastrectomy syndrome	+	Small intestine
2	Postgastrectomy syndrome	+	Small intestine and colon
3	Constipation and abdominal pain	+	Small intestine
4	Irritable colon syndrome	+	Colon
5	Irritable colon syndrome	+	Colon
6	Irritable colon syndrome	+	Colon
7	Irritable colon syndrome	+	Colon
8	Postdysenteric colon	-	Colon
9	Irritable colon syndrome	-	Colon

RESULTS

PATIENT NO. 1 A 54-year-old man had had a Polya partial gastrectomy for duodenal ulcer 12 years previously. Postoperatively he suffered from dumping, diarrhoea, and steatorrhoea, but the most disabling symptom was abdominal pain which invariably followed the ingestion of food. The symptoms persisted despite a multiplicity of medical treatments and conversion of his gastrectomy to Billroth I four years after the original operation. Barium studies suggested that pain coincided with the entry of the contrast material into the small intestine. The patient was much disabled by the pain, which caused him to abstain from eating during the day; he had to lie down for one hour after the evening meal. Psychiatric assessment suggested an anxious personality with a low threshold to intestinal discomfort.

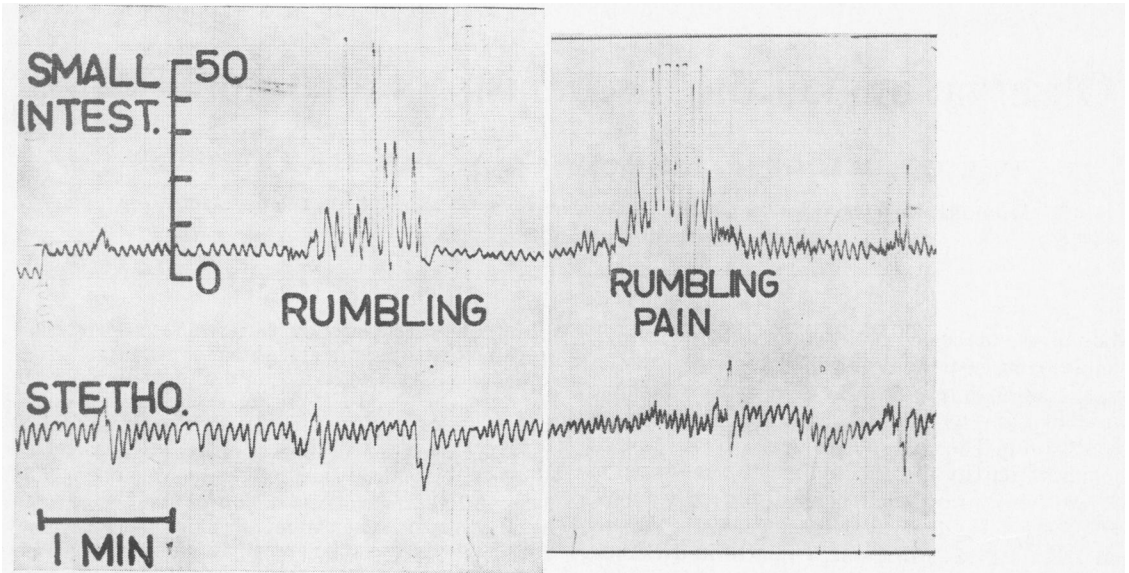


FIG. 1a.

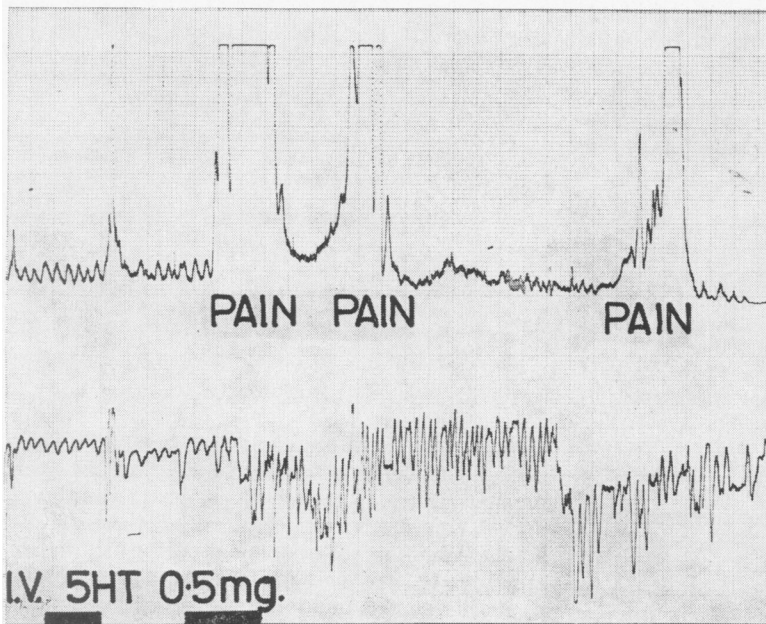


FIG. 1b.

FIG. 1. Patient no. 1. Small intestinal pressure activity coinciding with symptoms after a meal (a) and after intravenous 5-hydroxytryptamine, 0.5 mg at each signal (b). (In this and all subsequent figures calibration is in centimetres of water pressure. Stetho = stethograph.)

Pressure records from the small intestine are shown in Figure 1. The patient's pain coincided with bursts of small intestinal pressure activity after food (Fig. 1a), or with small intestinal activity induced by intravenous injections of 5-hydroxytryptamine (Fig. 1b), whilst intravenous saline

administered in identical circumstances had no effect. Both motor activity and symptoms were abolished by intravenous propantheline.

PATIENT NO. 2 This 49-year-old man's postgastrectomy symptoms were so disabling that prefrontal

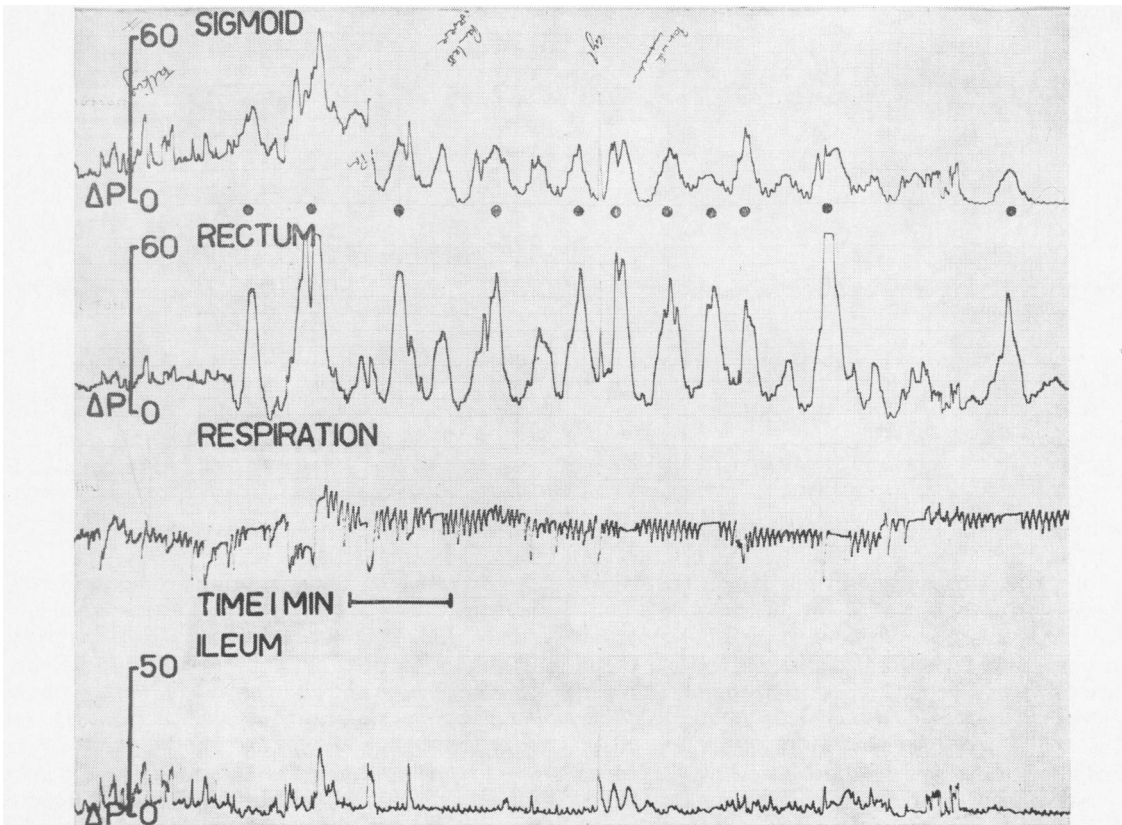


FIG. 2a.

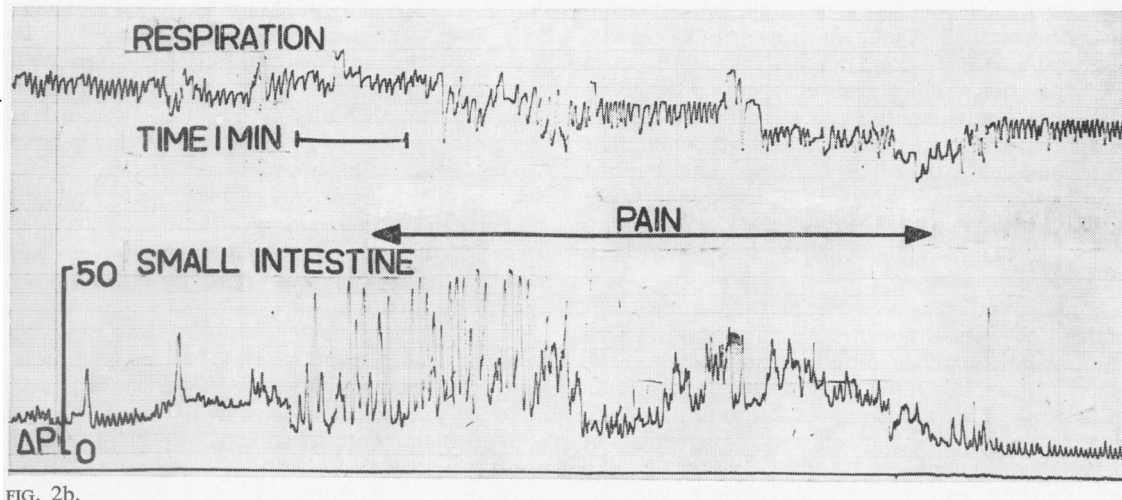


FIG. 2b.

FIG. 2. Patient no. 2. (a) High pressure waves in the rectal lead following 0.75 mg of prostigmine; dots mark the patient wincing. (b) Postprandial small intestinal motor activity coinciding with pain. (c) Marked motor activity in large and small intestine after 0.75 mg of prostigmine. Activity and pain abolished by 10 mg intravenous propantheline given at P. Vertical bar represents an interval of five minutes.

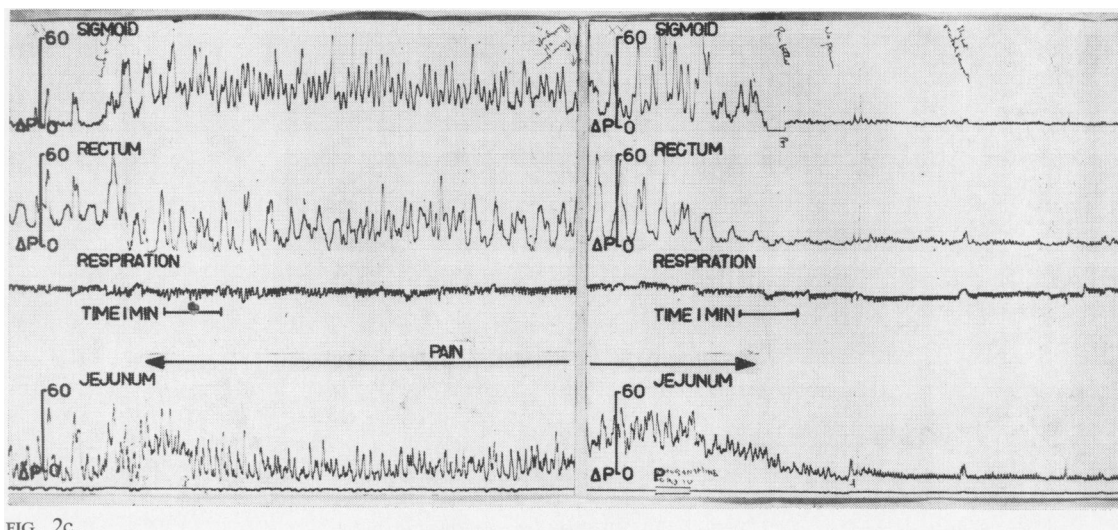


FIG. 2c.

lobotomy was considered at one stage. Abdominal pain began at the age of 32. At the age of 38 a duodenal ulcer was diagnosed, for which a Polya partial gastrectomy was performed two years later. From then onwards he complained of postprandial upper abdominal pain and also of pain in the left iliac fossa which was associated with constipation: these symptoms were persistent and disabling. Repeated investigations were negative and various treatments (including conversion of the gastrectomy to a Roux-en-y anastomosis three years after the original operation) produced only temporary benefit. Psychiatric opinion was that he suffered from a personality disorder with a marked propensity to anxiety.

Pressure records from this patient are shown in Figure 2. After 0.75 mg of subcutaneous prostigmine vigorous contractions were present in the rectum, and each peak of pressure coincided with cramp-like lower abdominal pain likened by the patient to the pain he felt when constipated; he was seen to wince at the height of each pressure peak (Fig. 2a). Intravenous propantheline stopped both the symptoms and the pressure activity.

On another occasion, after starting a meal this patient developed upper abdominal pain, which coincided with bursts of small intestinal pressure activity (Fig. 2b). During a third study, an injection of 0.75 mg of prostigmine produced both the lower and the upper abdominal pain, with hyperactivity of the jejunum, sigmoid, and rectum. This activity was abolished by intravenous propantheline with immediate relief of symptoms (Fig. 2c).

PATIENT NO. 3 A 49-year-old housewife presented with progressive constipation, vomiting, and severe

left-sided abdominal pain, during her first and only pregnancy 22 years previously. Lumbar sympathectomy and subtotal colectomy with ileorectal anastomosis carried out elsewhere were ineffective. The constipation and abdominal pain were so severe that ileostomy was being considered. Examination under anaesthesia was normal and biopsy at 24 cm from the anal margin showed normal colonic mucosa with ganglion cells present in normal numbers. X-ray studies showed gaseous distension of the large bowel remnant.

Pressure activity of the small intestine before, during, and after a bout of pain is shown in Figures 3a, b, and c. The resting record was normal (Fig. 3a) but during the pain small intestinal motor activity was markedly increased (Fig. 3b), subsiding again when the pain abated (Fig. 3c). The symptoms and the motor activity were abolished by intravenous propantheline. Pressure activity in the colonic remnant did not increase during the episodes of pain. Because the evidence from the pressure studies suggested that small intestinal activity was playing a part in the patient's symptoms, it was decided not to perform an ileostomy.

PATIENT NO. 4 This 23-year-old salesman had been suffering during the previous six years from attacks of lower abdominal colic and diarrhoea: he had been unable to work for nine months before admission because of the severity of his symptoms. Two laparotomies performed elsewhere had shown no abnormality apart from adhesions around the caecum, and numerous other investigations were negative. Sigmoidoscopy showed marked spasm of the sigmoid colon and his pain was triggered off by

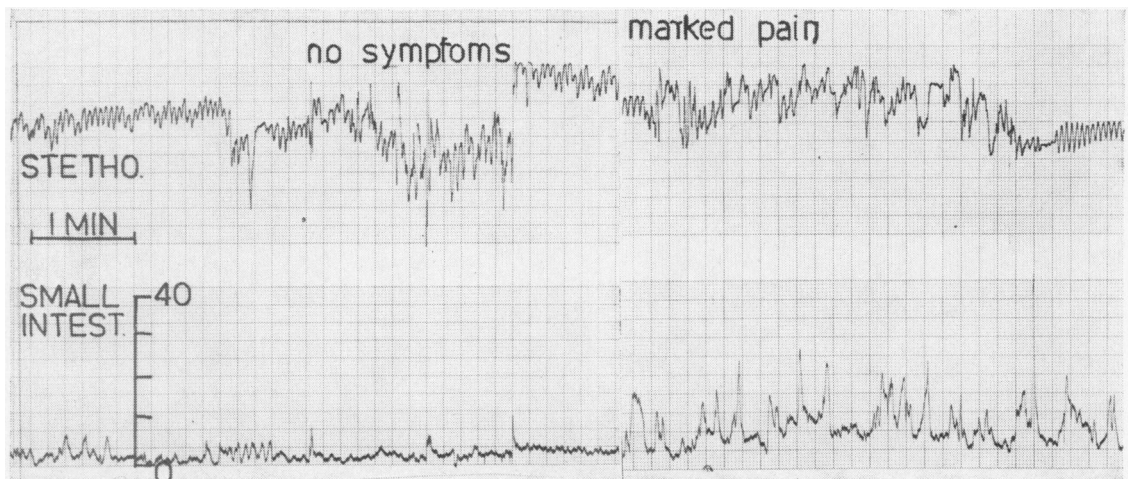


FIG. 3a.

FIG. 3b.

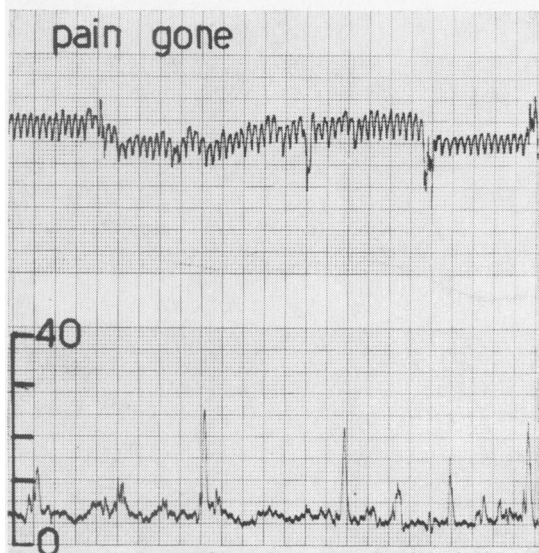


FIG. 3c.

FIG. 3. Patient no. 3. Small intestinal pressure activity (a) before, (b) during, and (c) after an attack of pain.

FIG. 4. Patient no. 4. Radiotelemetered pressure record from lower descending colon. Onset of pain (P) coincided with high frequency motor activity.

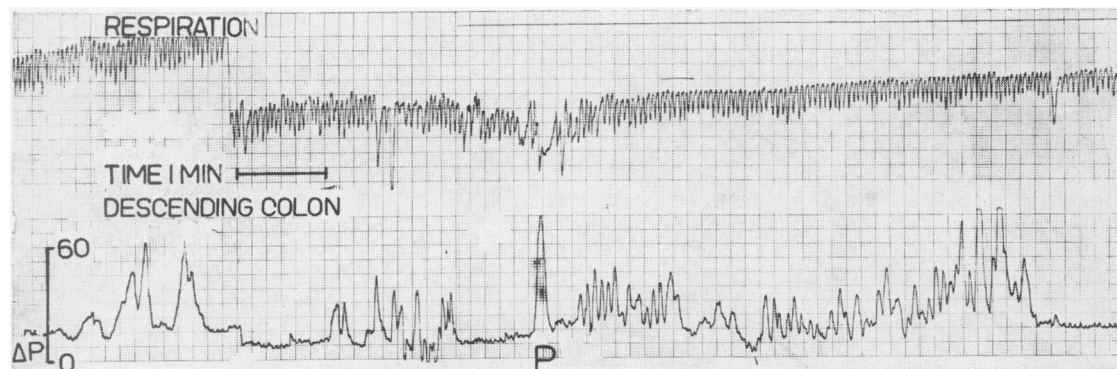


FIG. 4.

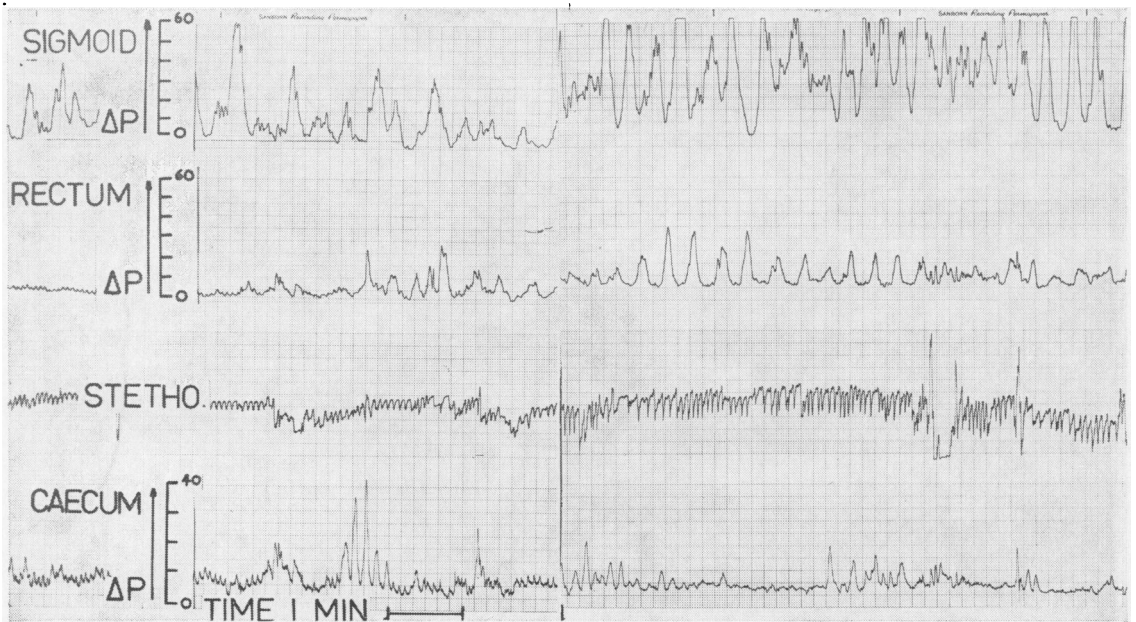


FIG. 5a.

FIG. 5b.

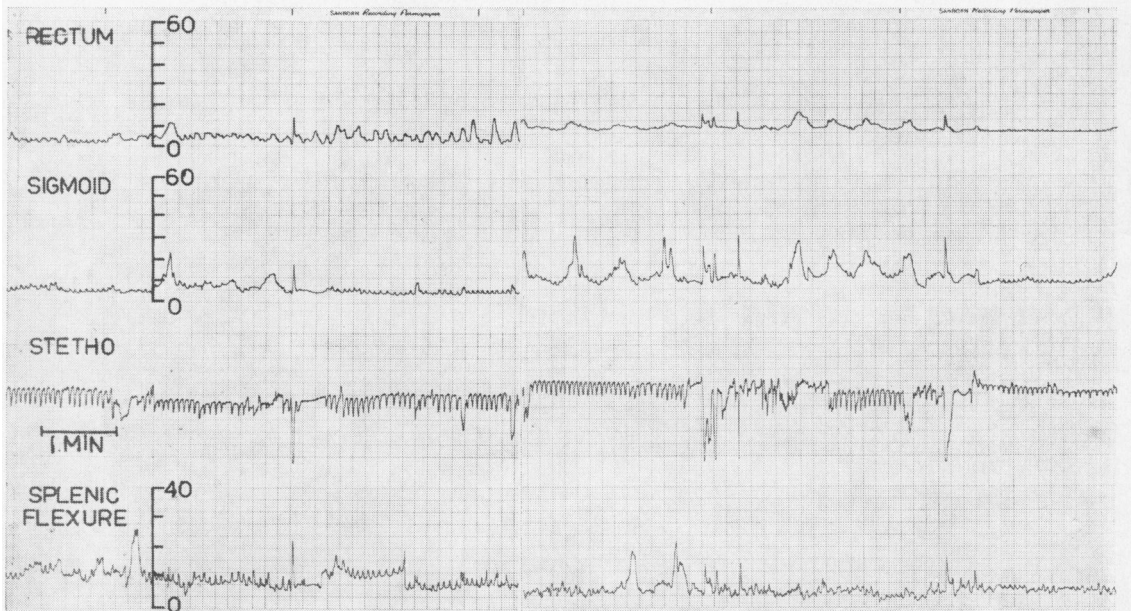


FIG. 5c.

FIG. 5d.

FIG. 5. Patient no. 5 (a) and (b). Fasting and postprandial pressure records from the proximal and distal colon with symptoms present after a meal; (c) and (d) similar records on the following day, when symptoms were absent.

the instrumentation. The spasm and the pain prevented the insertion of tubes to the usual extent and the pressure record from the lower sigmoid and rectum was normal.

As the relevant segment of the colon was not accessible through the sigmoidoscope, a radio-telemetering capsule was given to the patient and its position followed fluoroscopically until it reached the lower descending colon. Intraluminal pressures recorded from that part of the colon included bursts of waves characterized by high amplitude and frequency, which coincided with the patient's pain indicated by point P in Figure 4. A barium enema carried out subsequently without prior lavage showed painful spasm of that area of the sigmoid from which pressure waves had been recorded. Both the pain and the spasm were relieved by intravenous propantheline.

PATIENT NO. 5 A 43-year-old priest complained for two years of pain in the left iliac fossa and the epigastrium, worse after meals or under stress, which was accompanied by the passage of 'rabbity' stools. His sigmoid colon was palpable and tender. A barium enema showed spasm of the sigmoid colon which was relieved by propantheline, but no anatomical abnormality. Studies of colonic motor activity were performed on two successive days. On the first day his postprandial symptoms were present and the sigmoid pressure record showed a high level of basal activity followed by a marked response to a meal (Figs. 5a and b). On the second day the patient felt well and experienced no discomfort following the ingestion of an identical meal. On this occasion the motor activity of the sigmoid was much less both in the basal and in the postcibal periods (Figs. 5c and d).

PATIENT NO. 6 A 35-year-old clerk suffered from abdominal pain since the age of 15. While in the RAF a diagnosis of duodenal ulcer was considered, but antacids gave little relief. At the age of 22 he developed achalasia of the cardia; a cardiomyotomy performed three years later resulted in a complete relief of the dysphagia. However, the episodes of abdominal pain persisted and eventually were accompanied by diarrhoea, with the passage of up to eight loose motions daily. Examination and sigmoidoscopy were always normal, though insufflation of the bowel with air sometimes reproduced his pain. Several barium meals and enema examinations and numerous other investigations were normal, and a variety of treatments, including a milk drip during a period of inpatient investigations, were ineffective.

Studies on this patient were performed on two occasions. On the first he had been free of symptoms for several days and the colonic pressure response to

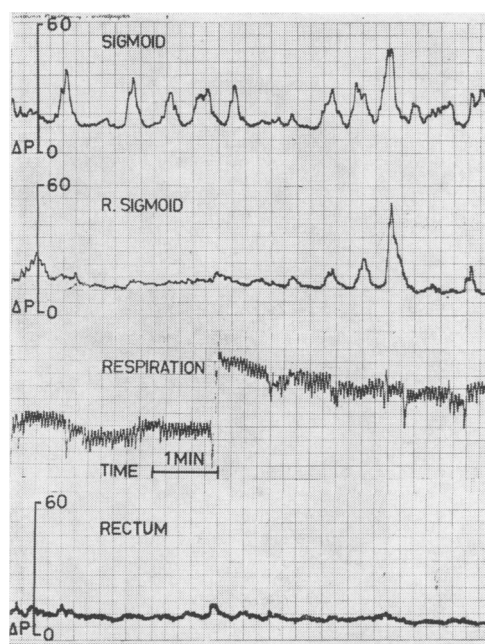


FIG. 6a. Patient no. 6. Pressure response of the left colon to prostigmine during remission.

prostigmine was not striking (Fig. 6a). The studies were repeated several months later during a relapse. On this occasion right-sided abdominal pain began in the postprandial period, but the pressure records from the sigmoid and rectum remained normal. The pain spread to the left side following an injection of prostigmine and this was accompanied by waves with amplitudes exceeding 100 cm of water pressure (Fig. 6b). After intravenous propantheline the pain was relieved and the pressure activity abolished (Fig. 6c).

PATIENT NO. 7 A woman aged 58 suffered from diarrhoea for 20 years, becoming worse after an attack of gastroenteritis; the symptoms were aggravated by fatty foods or fruit. She averaged about six loose or watery motions daily with the passage of mucus, but no blood, per rectum. The diarrhoea was accompanied by lower abdominal pain which was worse before defaecation. She was an anxious person with abdominal tenderness, especially on the left side. The rectal mucosa appeared oedematous at sigmoidoscopy, but biopsy was normal. Barium enema showed no evidence of inflammatory disease of the colon, and other relevant investigations, including stool culture and lactose tolerance test, were normal.

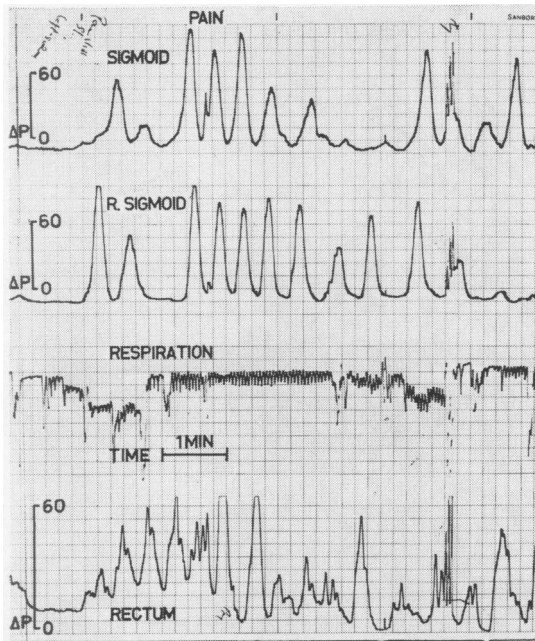


FIG. 6b.

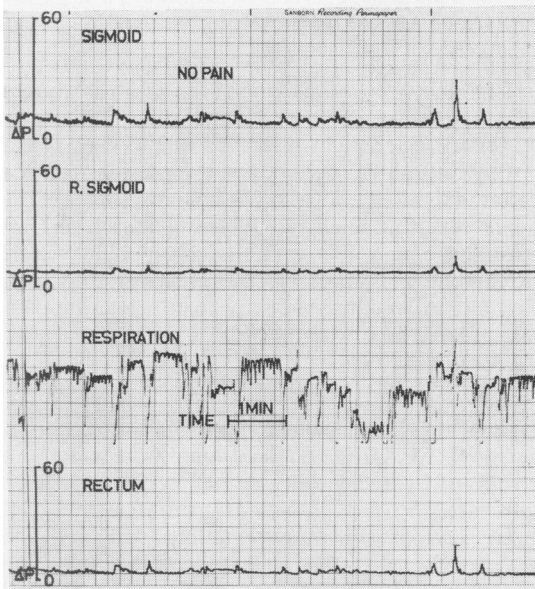


FIG. 6c.

FIGS. 6b and 6c. (b) Pressure response to the same dose of prostigmine during relapse. High pressure waves in two upper leads coincide with pain. Note change in pressure scale. (c) Effect of 10 mg intravenous propantheline on the activity in (b). Abolition of symptoms and of pressure waves. (All the pressure waves in (c) are artefacts due to body movement.) (R. sigmoid in this and remaining figures indicates rectosigmoid.)

Her basal colonic pressure record was normal (Fig. 7a), but after a meal containing items of food which sometimes upset her she developed marked left-sided abdominal pain with an urge to defaecate. These symptoms coincided with the appearance on the pressure record of waves at an increased frequency and amplitude (Fig. 7b). Following the injection of prostigmine the severity of her symptoms increased to such an extent that the test had to be terminated, and she passed five loose stools in the next two hours.

PATIENT NO. 8 A 50-year-old naval surgeon had recurrent attacks of diarrhoea since an episode of Sonne dysentery during the war. The diarrhoea was accompanied by abdominal pain before each bowel movement. All investigations, including barium enema and repeated stool cultures, were negative.

Studies of colonic motor activity were performed during a phase of active symptoms, when he was passing up to five fluid motions daily. His basal pressure record was unusual, showing bursts of activity of high amplitude and frequency (Fig. 8a). These features became progressively more marked following a meal (Fig. 8b), and the injection of prostigmine (Fig. 8c); at no time were the waves propulsive. Some of the pressure waves recorded reached the height of 97 mm Hg, which compares with his blood pressure of 100/70 mm Hg. Despite the active pressure record he had no abdominal pain during the period of study, although his bowels were opened three times in the two hours afterwards.

PATIENT NO. 9 A 25-year-old girl suffered from attacks of diarrhoea and lower abdominal pain during the previous four years. Symptoms began following the sudden death of her father. Amoebae were said to have been found in the stools on one occasion, but previous specific antiameobic chemotherapy had no effect and extensive investigations at a specialist centre in this country showed no evidence of amoebiasis. She was tender in the left iliac fossa; air insufflation during sigmoidoscopy precipitated abdominal pain. At the time of the study she was having up to six loose bowel movements daily.

Her basal (Fig. 9a) and postprandial colonic pressure records showed no unusual features, but after subcutaneous prostigmine there was sustained activity, with waves up to 140 cm water (103 mm Hg) pressure: this compares with her arterial blood pressure of 115/80 mm Hg. The waves were not propulsive (Fig. 9b). In spite of this she felt no pain at all, noticing only some gurgling in the lower abdomen. There was no exacerbation of diarrhoea after the study.

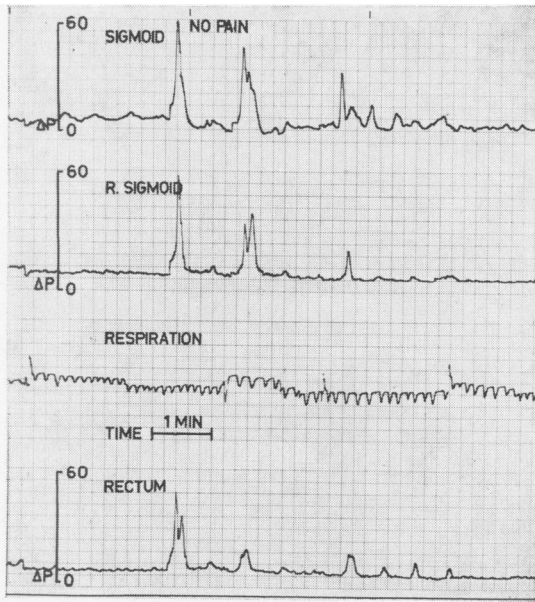


FIG. 7a.

FIG. 7. Patient no. 7. Colonic pressure records: (a) basal; (b) 20 min after a meal with left-sided abdominal pain and an urge to defaecate. High-frequency, high-pressure motor activity in upper two leads.

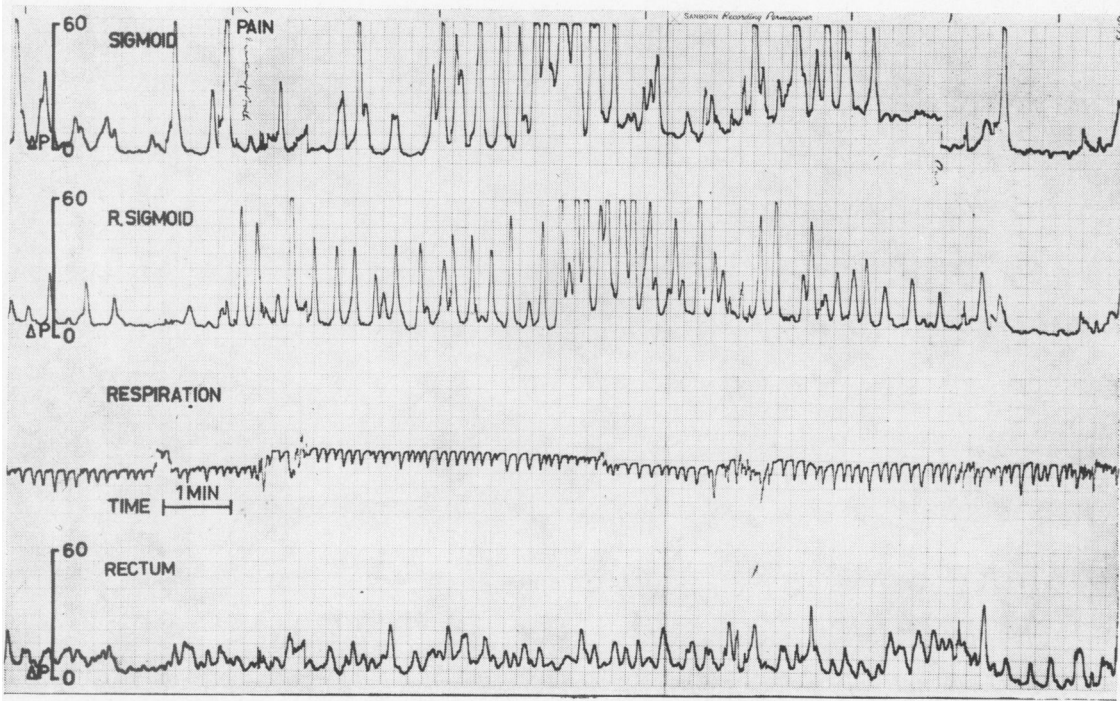


FIG. 7b.

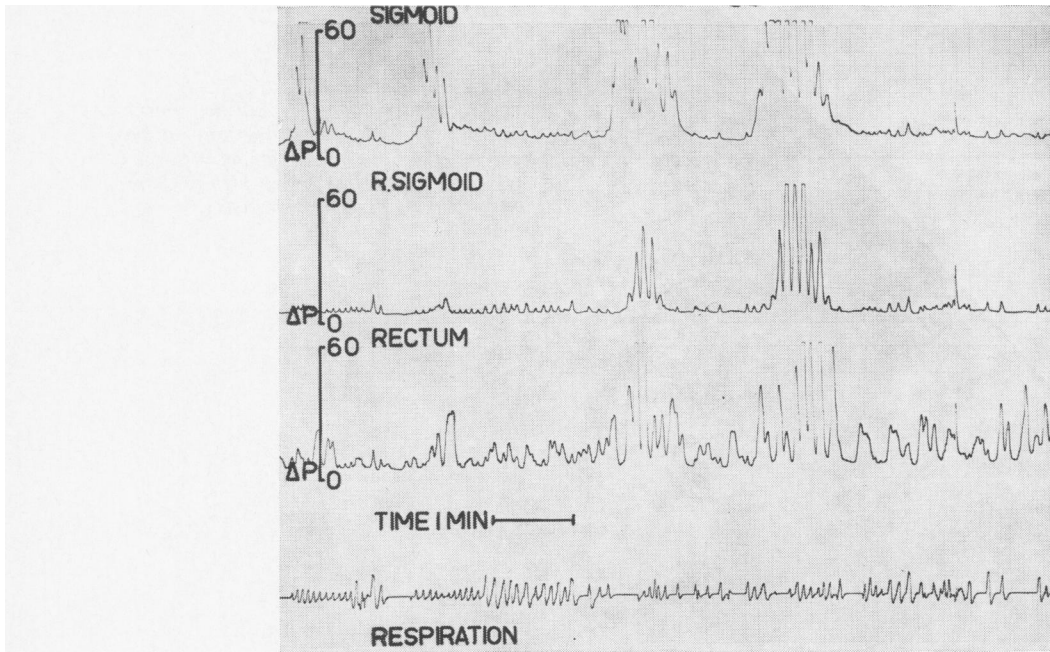


FIG. 8a.

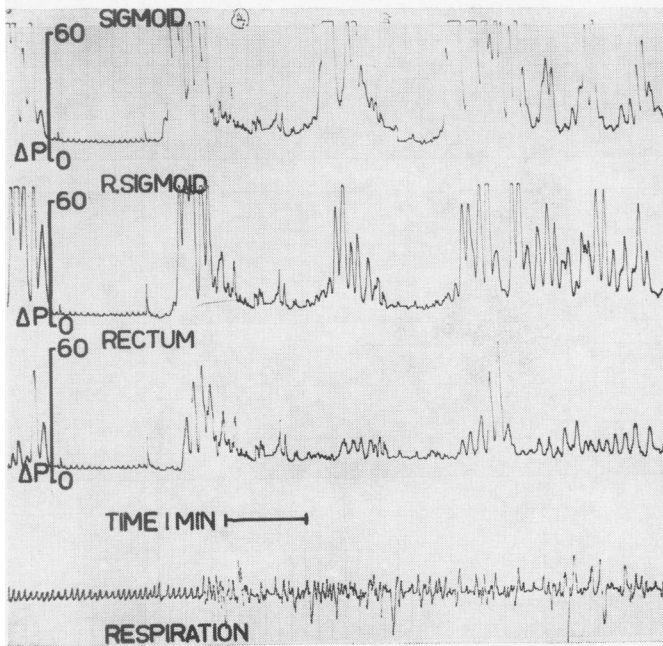


FIG. 8b.

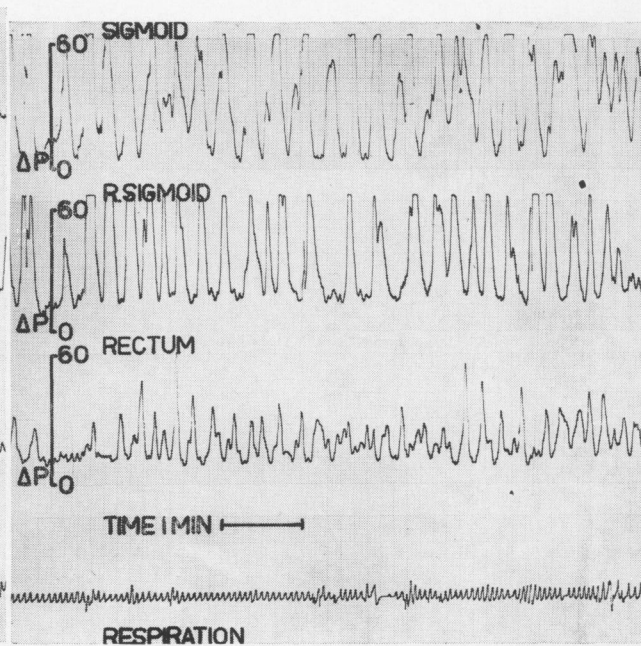


FIG. 8c.

FIG. 8. Patient no. 8. Colonic pressure records: (a) basal; (b) while eating, and (c) 12 min after prostigmine 0.75 mg intramuscularly. No symptoms, although high-frequency, high-pressure motor activity was present throughout. The waves are not progressive.

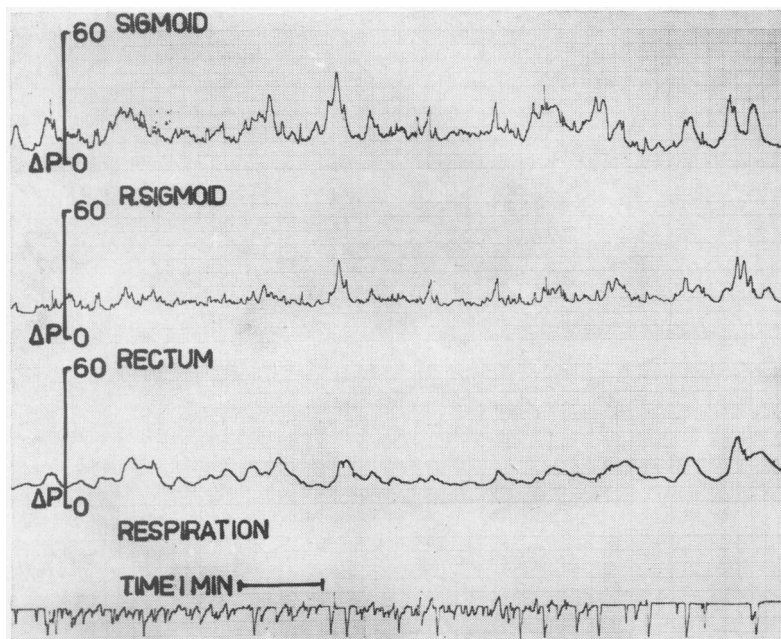


FIG. 9a.

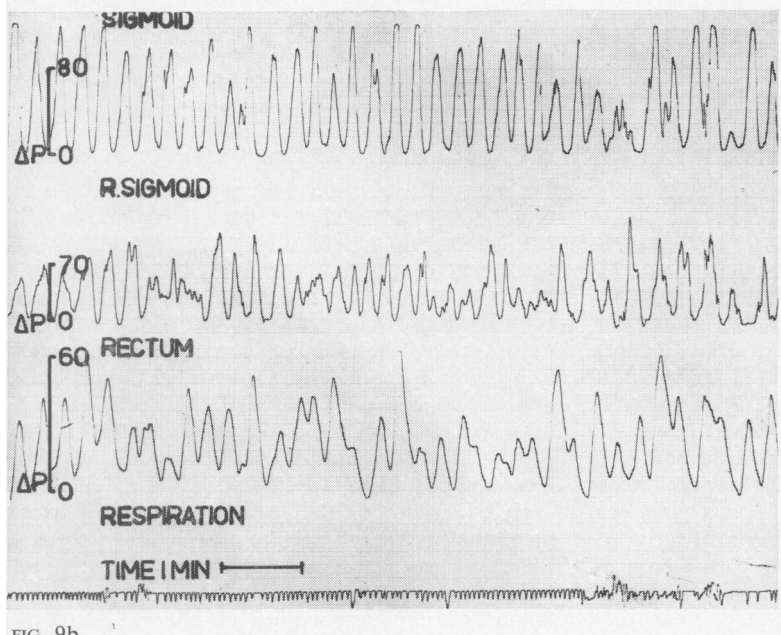


FIG. 9b.

FIG. 9. Patient no. 9. Colonic pressure records: (a) basal; (b) 15 min after prostigmine 0.75 mg intramuscularly. High pressure rapid waves produced no symptoms; not progressive. Note change of pressure scale in upper two leads in (b).

DISCUSSION

In this type of study assessment of pain must necessarily rely on subjective interpretation by the patient, and the normal range of intestinal response to the various stimuli used is not known. Nevertheless it

was felt that careful observation under standard conditions, combined with simultaneous measurements of intraluminal pressures, would result in a meaningful correlation between pain and motor activity.

In all the nine patients described here abdominal

pain was a prominent symptom. No organic disease of the small or large intestine was found, although three patients (nos. 1, 2, and 3) had had previous surgical procedures. Both postgastrectomy patients had symptoms of dumping intermittently, but these were relatively mild and were absent during the manometric studies. Seven patients (nos. 1 to 7) developed typical attacks of abdominal pain during the manometric studies and in every case the symptoms coincided with striking alterations in the records of intraluminal pressure. Such alterations occurred in all the patients and were often the only positive finding on investigation.

Pain coincided with small intestinal pressure activity in one of the patients with the postgastrectomy syndrome (patient no. 1) and in the patient who had had a subtotal colectomy (patient no. 3). The other patient with the postgastrectomy syndrome (no. 2) suffered from upper and lower abdominal pain and in him changes in both small and large intestinal motor activity were observed. Virtually nothing is known of the role of small intestinal motor activity in the production of abdominal pain in the absence of organic obstruction. Horowitz and Farrar (1962) described two patients in whom cramping pain coincided with bursts of jejunal pressure waves, and Connell *et al* (1965) found ileal hypermotility in one of their cases of postprandial abdominal pain. Many authors have studied the motility of the small intestine during dumping but no generally accepted conclusion has emerged and attacks of dumping are not usually accompanied by pain. Motor activity of the small intestine usually increases following the ingestion of meals, and distension of the intestine in animals results in the release of 5-hydroxytryptamine (5-HT) (Bülbring and Lin, 1958), which stimulates the human small bowel to contract, but inhibits the motor activity of the stomach and colon (Misiewicz, Waller, and Eisner, 1966). Since it is unlikely that abdominal pain could result from relaxation of smooth muscle in the intestinal wall, it is possible that 5-HT could be used to localize the site of origin of abdominal symptoms to the small intestine in some patients. In this context it is interesting that intravenous 5-HT precipitated pain in patient no. 1.

In five patients (nos. 2 and 4 to 7) the onset of abdominal pain coincided with a marked increase in the motor activity of the colon after a meal or an injection of prostigmine. Two further patients (nos. 8 and 9) showed similar changes in colonic pressure but remained symptom-free. Of these seven patients, five had the irritable bowel syndrome, whilst the other two suffered from the post-dysenteric bowel syndrome and postgastrectomy syndrome respectively (Table I).

Patients with the irritable bowel syndrome often show a much greater increase of pressure in the distal colon after food or prostigmine than do normal subjects (Chaudhary and Truelove, 1961; Wangel and Deller, 1965). Excessive pressure response was especially marked in the presence of symptoms (Chaudhary and Truelove, 1961), and this is confirmed in our two patients (nos. 5 and 6) who were studied on separate occasions when symptom-free and in relapse. Connell *et al* (1965) described in detail 12 patients with hypermotility of the pelvic colon associated with postprandial abdominal pain.

The question arises as to how excessive motor activity of intestinal smooth muscle can cause pain in the absence of organic obstruction. Observations made at laparotomy under local anaesthesia indicate that the intestine is sensitive only to distension, and rapid distension of a balloon in the small intestine causes pain (Rowlands, 1952). It has been suggested that the pressure waves recorded from the colonic lumen represent dissociated segmenting contractions which delay rather than accelerate the transit of colonic contents (Connell, 1962). Simultaneous cineradiography and pressure recording shows that pressure waves can occur without movement of contents and vice versa (Ritchie, Ardran, and Truelove, 1962). Excessive segmenting activity might thus create a functional obstruction and cause pain by distension of bowel proximal to the hypersegmenting segment (Connell *et al*, 1965). However, the evidence (Connell, 1962; Wangel and Deller, 1965) for a delaying effect of colonic pressure waves is not conclusive and in five of our patients with marked colonic activity diarrhoea, as well as pain, was a prominent symptom. It could be argued that in the two patients (nos. 8 and 9) with excessive colonic activity but no pain the recorded waves were propulsive but there is no evidence of this on careful inspection of the records. In the other patients it is difficult to accept that pain due to functional obstruction produced by hypersegmentation was present simultaneously with diarrhoea due to increased propulsive activity.

If the hypothesis that pain is due to hypersegmentation causing functional obstruction is correct, the abnormal motor activity might well be focal rather than generalized. Circumstantial evidence in favour of the focal nature of abnormal colonic motor function is provided by the clinical observation that pain in the irritable colon syndrome is often well localized to the left iliac fossa and that, as far as is known, the muscle abnormality in diverticular disease of the colon is limited to the sigmoid (Morson, 1963). Some further support for this concept is provided by the present results. In

two patients (nos. 3 and 4) rectal records were normal, but at the same time small intestinal motor activity in one (no. 3) and upper sigmoid activity in the other patient (no. 4) coincided with bouts of pain. Another patient (no. 2) had pain coinciding with high-amplitude pressure waves in the rectum, and synchronous pressure waves were recorded from the sigmoid lead but at a much lower amplitude, whilst a simultaneous record from the ileum was not abnormal (Fig. 2a). In patient no. 4 spasm of the sigmoid prevented the insertion of tubes to their full extent and pressures thus recorded were normal, whilst pressure records obtained from beyond the reach of the sigmoidoscope were judged to show an excessive response (Fig. 4). It must be admitted, however, that knowledge of the extent of spread of motor abnormalities during bouts of pain is meagre, and the changes observed in patient no. 6 suggest that they may progress from the proximal to the distal colon.

The often disappointing results of treatment with oral propantheline and similar drugs in the clinical management of such cases are presumably due to the difficulty of obtaining adequate dosage without intolerable side-effects. A trial of self-administered subcutaneous injection of propantheline in patients 1 and 2 was unsuccessful for the same reason. However, in the four patients given intravenous propantheline, the simultaneous relief of pain and cessation of pressure activity were impressive, suggesting a relationship between symptoms and motor activity. On the other hand, the present results do not support the conclusion that this relationship is simple, because two patients (nos. 8 and 9), whose records were qualitatively similar to others in this study, remained free of pain throughout their tests, despite the fact that pain was a feature of their illness. In these two patients the intraluminal pressures approached the level of the arterial blood pressure, making it unlikely that ischaemia of the bowel wall is an important factor in the production of this type of abdominal discomfort. Individual variations in sensitivity to painful stimuli and in the threshold of awareness to visceral sensations undoubtedly play a part, but are difficult to measure objectively. For example, it was our impression that patient no. 2 was unusually aware of his visceral sensations and had a low pain threshold, but that these features were much less marked in patient no. 1.

SUMMARY

Intraluminal pressures were measured in the small or large intestine of nine patients suffering from recurrent attacks of severe abdominal pain, for which no cause was found after extensive investigation.

Abdominal pain was correlated with pressure changes in the small or large intestine in seven patients; two patients remained symptom-free despite excessive pressure activity.

The relationship between abdominal pain and intraluminal pressures is discussed in the light of these findings.

We are grateful to Dr F. Avery Jones and Dr T. D. Kellock, Central Middlesex Hospital, and Dr G. Watkinson, York County Hospital, for allowing us to study patients under their care, and to Dr Alan Young, St Mark's Hospital, London, for radiological studies on patients 4 and 5. We thank Mrs Moira Black for much technical assistance and Mr A. Booker, F.P.S., of the Photographic Department, Central Middlesex Hospital, for the illustrations.

REFERENCES

- Atkinson, M., Edwards, D. A. W., Honour, A. J., and Rowlands, E. N. (1957). Comparison of cardiac and pyloric sphincters. A manometric study. *Lancet*, 2, 918-922.
- Bülbring, E., and Lin, R. C. Y. (1958). The effect of intraluminal application of 5-hydroxytryptamine and 5-hydroxytryptophan on peristalsis; the local production of 5-HT and its release in relation to intraluminal pressure and propulsive activity. *J. Physiol. (Lond.)*, 140, 381-407.
- Chaudhary, N. A., and Truelove, S. C. (1961). Human colonic motility: a comparative study of normal subjects, patients with ulcerative colitis, and patients with the irritable colon syndrome. I. Resting patterns of motility. II. The effect of prostigmin. III. Effects of emotions. *Gastroenterology*, 40, 1-36.
- Connell, A. M. (1959). Intraluminal pressures in the pelvic colon. *Proc. roy. Soc. Med.*, 52, suppl., pp. 69-72.
- (1962). The motility of the pelvic colon. II. Paradoxical motility in diarrhoea and constipation. *Gut*, 3, 342-348.
- , Jones, F. A., and Rowlands, E. N. (1965). Motility of the pelvic colon. IV. Abdominal pain associated with colonic hypermotility after meals. *Ibid.*, 6, 105-112.
- , McCall, J., Misiewicz, J. J., and Rowlands, E. N. (1963). Observations on the clinical use of radio pills. *Brit. med. J.*, 2, 771-774.
- Horowitz, L., and Farrar, J. T. (1962). Intraluminal small intestinal pressures in normal patients and in patients with functional gastrointestinal disorders. *Gastroenterology*, 42, 455-464.
- Misiewicz, J. J., Connell, A. M., and Pontes, F. A. (1966). Comparison of the effects of meals and prostigmine on the proximal and distal colon in patients with and without diarrhoea. *Gut*, 7, 468-473.
- , Waller, S. L., and Eisner, M. (1966). Motor responses of human gastrointestinal tract to 5-hydroxytryptamine *in vivo* and *in vitro*. *Ibid.*, 7, 208-216.
- , Fox, R. H., Goldsmith, R., and Hunt, T. J. (1968). The effect of elevated body temperature and of stress on the motility of stomach and colon in man. *Clin. Sci.*, 34, 149-159.
- Morson, B. C. (1963). The muscle abnormality in diverticular disease of the sigmoid colon. *Brit. J. Radiol.*, 36, 385-392.
- Ritchie, J. A., Ardran, G. M., and Truelove, S. C. (1962). Motor activity of the sigmoid colon of humans. A combined study by intraluminal pressure recording and cineradiography. *Gastroenterology*, 43, 642-668.
- Rowlands, E. N. (1952). Gastrointestinal motility in man. Functions of extrinsic nerves. In *Modern Trends in Gastroenterology*, Series I, edited by F. Avery Jones, pp. 548-549. Butterworth, London.
- , and Wolff, H. S. (1960). The radio pill. Telemetering from the digestive tract. *Brit. Commun. Electron.*, 7, 598-601.
- Wangel, A. G., and Deller, D. J. (1965). Intestinal motility in man. III. Mechanisms of constipation and diarrhoea with particular reference to the irritable colon syndrome. *Gastroenterology*, 48, 69-84.