

# Persistent haemolysis after infectious hepatitis

MARCEL E. CONRAD

*From the Department of Hematology, Walter Reed Army Institute of Research, Washington, DC*

Viral hepatitis is a pantropic disease which often has haematological manifestations (Lucké, 1944; Conrad, Schwartz, and Young, 1964; Conrad, Weintraub, Schwartz, and Young, 1965). Frequently there is transient suppression of bone marrow function or a mild haemolytic disorder (Kjellberg, 1941; Havens, 1948; Neumann and Hommer, 1949; Hirscher, 1950; Bornemann and Michel, 1955; Kalk, 1955; Miescher, 1958; Horváth and Iványi, 1959; Kivel, 1961; Fodor and Tănăsescu, 1962; Sansone, Rovei, and Rasore-Quartino, 1963; Conrad *et al*, 1964 and 1965; Frick and Schmid, 1965). Rarely, patients with hepatitis develop either a fatal aplastic anaemia or moderately severe haemolytic anaemia (Kjellberg, 1941; Lorenz and Quaiser, 1955; Kivel, 1961; Sansone *et al*, 1963; Rubin, Gottlieb, and Vogel, 1968).

The mild haemolytic disorder associated with viral hepatitis is often undetected because bilirubinaemia is attributed solely to liver disease, the rate of haemolysis is usually insufficient to cause anaemia, and reticulocytosis does not occur until most patients recover from the acute symptoms of hepatitis.

The compensated haemolytic disorder of viral hepatitis is usually brief in duration and abates within a few months after the onset of jaundice (Conrad *et al*, 1965). Only a few patients have a persistent haemolytic disorder which may last for longer intervals. The aetiology of this haemolytic state is difficult to establish unless the acute hepatitis was well documented.

This communication reports three patients with viral hepatitis who had a compensated haemolytic disorder long after recovery from liver disease.

## SUBJECTS AND METHODS

The subjects of this study were three US servicemen who had persistent reticulocytosis and indirect bilirubinaemia for more than one year after recovery from viral hepatitis. These patients were found among a group of 68 soldiers who developed icteric hepatitis in Korea and had laboratory studies performed at intervals for one year after the onset of jaundice. Each of the patients was maintained on modified bed rest and a regular hospital diet during

the acute stage of the disease (Chalmers, Eckhardt, Reynolds, Cigarroa, Deane, Reifenstein, Smith, and Davidson, 1955). No other treatment was employed.

The diagnosis of viral hepatitis was established in each patient by observation of the clinical illness and by the demonstration of elevated serum direct bilirubin and transaminase levels. The diagnosis was confirmed in each patient by examination of a liver biopsy specimen obtained during the first week of admission to hospital for hepatitis (Menghini, 1958; Smetana, 1963). It was believed unlikely that the three patients had serum-transmitted hepatitis. One patient received parenteral injections of penicillin for gonococcal urethritis four weeks before admission to the hospital (case 3) and another had a smallpox vaccination two weeks before the onset of jaundice (case 1). No other inoculations or drugs were received during the six months before admission to the hospital with hepatitis.

Clinical symptoms, physical findings, and laboratory tests were quantified by previously described methods (Conrad *et al*, 1964). Heterophile agglutination studies and microagglutination tests showed no evidence of infectious mononucleosis or leptospirosis.

The red blood cell life span was measured by transfusion of both autologous and homologous <sup>51</sup>Cr-labelled cells (Ebaugh, Emerson, and Ross, 1953). The range of normal values for the  $t_{\frac{1}{2}}$  of <sup>51</sup>Cr-transfused erythrocytes in this laboratory was 27 to 35 days. Homologous blood was obtained for these studies from a normal compatible donor whose blood had been transfused into numerous recipients without the occurrence of hepatitis. This donor had a  $t_{\frac{1}{2}}$  of 29 days following autotransfusion of <sup>51</sup>Cr-labelled red blood cells.

Haematological laboratory studies were performed as described by Dacie and Lewis (1963).

## RESULTS

Serial observations in 68 patients with viral hepatitis showed that most patients had a significant decrease in the haematocrit during the second and third week after the onset of jaundice and developed reticulocytosis during the third or fourth week of admission to hospital (Fig. 1). Previously reported studies in a group of these patients showed that 25% had a shortened survival of <sup>15</sup>Cr-labelled red blood cells during the acute stage of illness (Conrad *et al*, 1965).

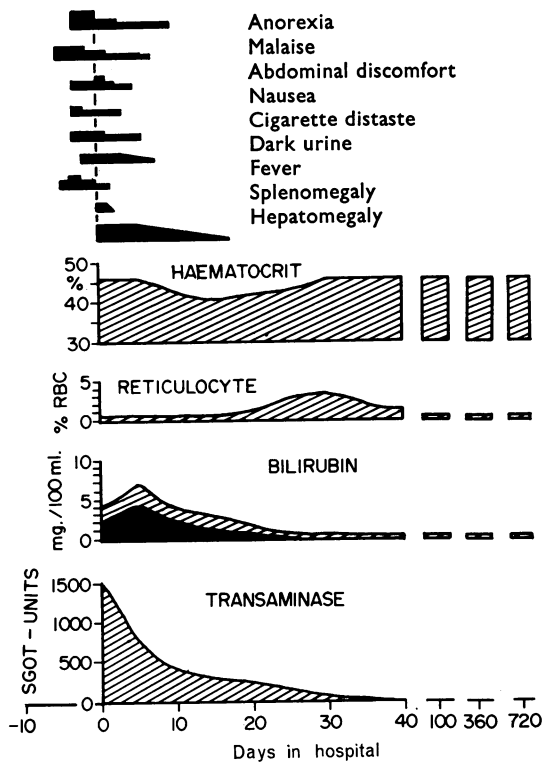


FIG. 1. Schematic representation of the median clinical and laboratory findings in 68 US soldiers with icteric viral hepatitis. The median patient admitted for study was ill for five days and jaundiced for one day. Usually the disease started with symptoms of fever and malaise which were believed to represent the prodromal symptoms of an upper respiratory infection. Subsequently the patients developed anorexia, nausea, abdominal discomfort, and a distaste for cigarettes. Most patients became asymptomatic during the second week in hospital. The liver was enlarged in all but one patient. The splenic tip was palpated during the first few days in hospital in more than half the subjects. Laboratory tests showed a significant decrease in the haematocrit during the first two weeks and reticulocytosis during the third week after admission. The maximal elevation in the serum transaminase was usually observed in the admission specimen. In contrast, the serum bilirubin increased during the first week after admission. Laboratory tests became normal during the fourth week.

In most patients with hepatitis, the serum bilirubin returned to normal values before the serum transaminase. However, 14 patients had both indirect bilirubinaemia and reticulocytosis two months after the clinical onset of jaundice and the serum transaminase values were abnormal in only two of these subjects. In 11 of these patients, the serum bilirubin values and reticulocyte count became normal during the next month. The remaining three patients had indirect bilirubinaemia and reticulocytosis six months and one year after the onset of jaundice (Figs. 2 to 5). Laboratory tests indicative of liver disease were normal at these intervals. Liver biopsy specimens obtained one year after the onset of jaundice showed no histological abnormalities. Follow-up laboratory studies at yearly intervals showed that two subjects had evidence of haemolysis two years after the onset of jaundice and their reticulocyte counts and serum bilirubin levels became normal during the next year (Figs. 2 to 4).

The survival of transfused <sup>51</sup>Cr-labelled autologous and homologous red blood cells was measured in each subject one year after the onset of jaundice (Table I). The rapid disappearance of both the patients' cells and donor cells indicated that haemolysis was caused by extracorporeal factors and not by the production of abnormal, defective erythrocytes.

Blood specimens obtained from the three patients with persistent posthepatitic haemolysis six months and one year after the onset of jaundice showed normal haematological studies. These included haematocrit, red blood cell indices, white blood count, differential smear of the peripheral blood, platelet count, direct antiglobulin (Coombs) test, studies for cold agglutinins and haemolysis, the acidified serum (Ham's) test, the Donath-Landsteiner test, incubated osmotic fragility studies, haemoglobin electrophoresis, measurements of A<sub>2</sub> and foetal haemoglobin, and assays for glucose-6-phosphate-dehydrogenase in red blood cell haemolysates.

DISCUSSION

Marked anaemia is an infrequent finding in patients with viral hepatitis (Havens, 1948; Neumann and Hommer, 1949; Bornemann and Michel, 1955;

TABLE I

LABORATORY STUDIES IN PATIENTS WITH HAEMOLYSIS ONE YEAR AFTER HEPATITIS

Case No.	White Blood Count (cells/cmm)	Platelet Count (cells/cmm)	Red Blood Count (million cells/cmm)	Haematocrit (%)	Haemoglobin (g/100 ml)	Reticulocytes (% Red Blood Count)	Serum Bilirubin (mg/100 ml)		<sup>51</sup> Cr-Red Blood Count T <sub>1/2</sub> days	
							Direct	Total	Autologous Cells	Homologous Cells
1	6,700	345,000	5.2	47	15.4	2.6	0.2	1.3	20	18
2	9,400	325,000	4.8	44	14.5	2.2	0.1	1.1	17	15
3	8,200	290,000	5.0	45	15.1	2.4	0.1	1.7	18	18

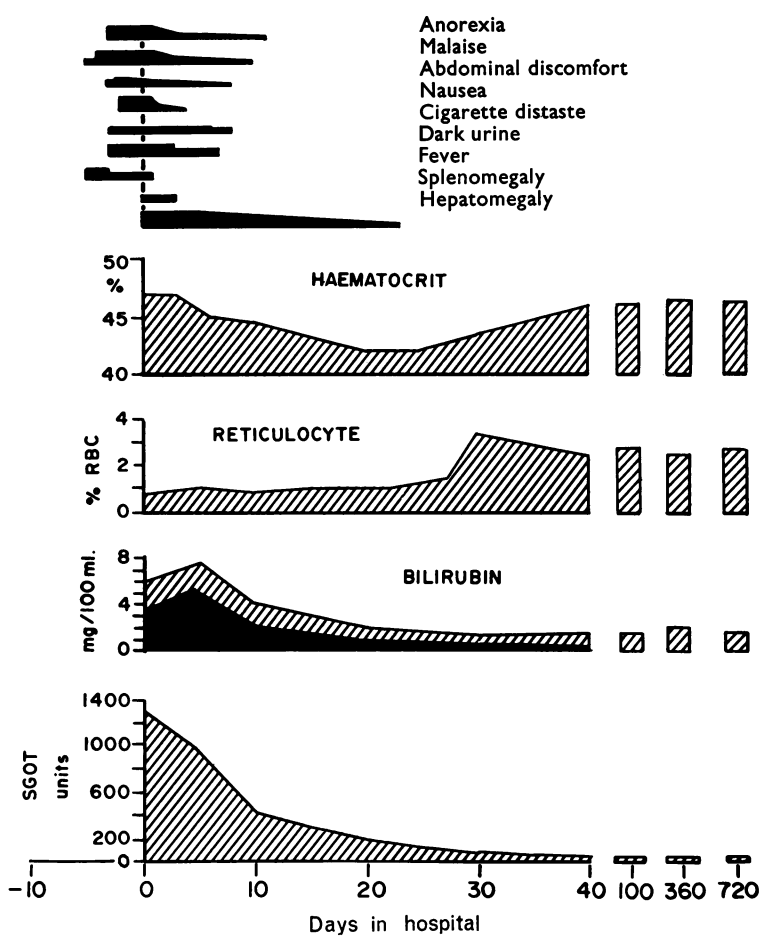


FIG. 2. Case 1 A 19-year-old soldier had a typical clinical course of viral hepatitis except for a persistent reticulocytosis and increased indirect serum bilirubin values for two years after the onset of jaundice.

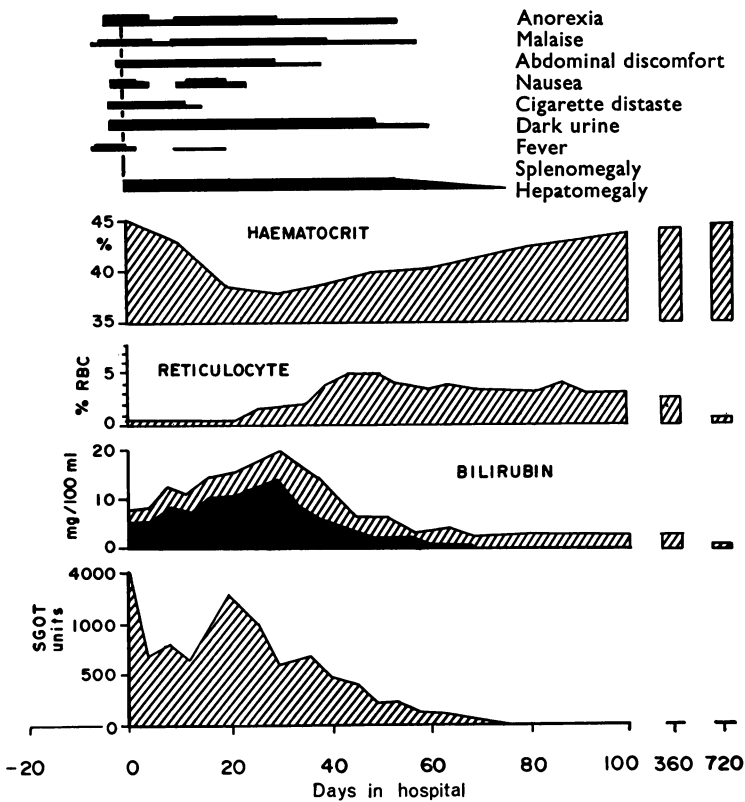


FIG. 3. Case 2 A 23-year-old man had a moderately prolonged acute illness. Symptoms, physical findings, and laboratory abnormalities indicative of liver disease lasted for two months. Indirect bilirubinaemia and reticulocytosis were found in blood specimens for one year after the onset of jaundice.

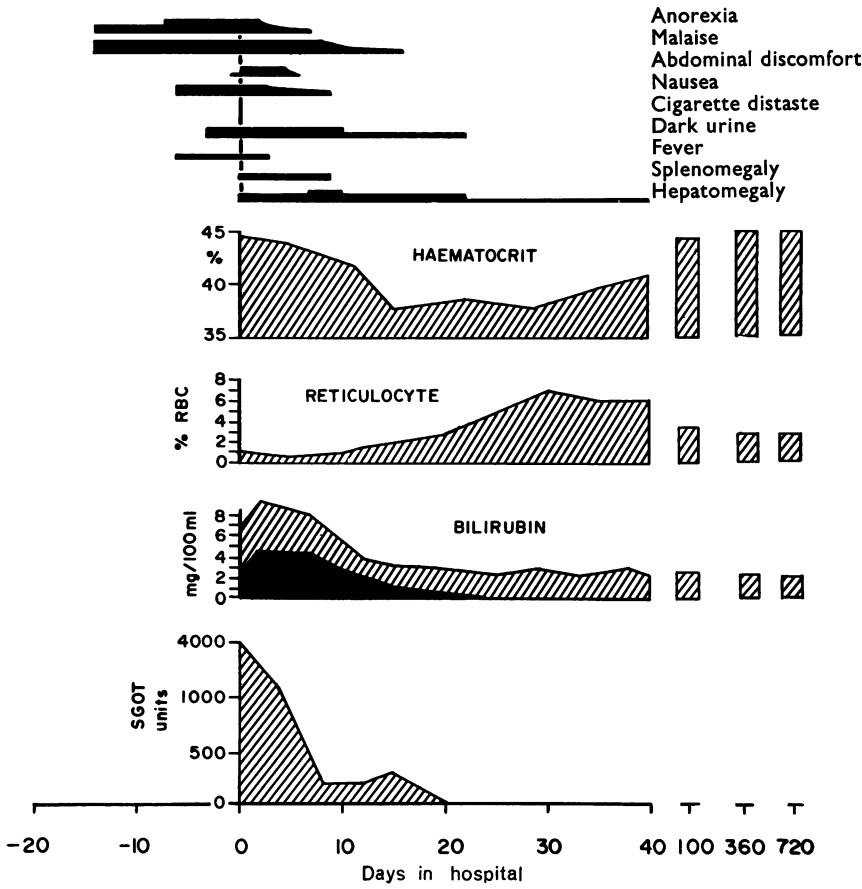


FIG. 4. Case 3 A 19-year-old soldier had anorexia and malaise for two weeks before he became icteric. Clinical symptoms and laboratory studies suggestive of liver disease became normal within a month after admission but evidence of haemolysis persisted for two years.

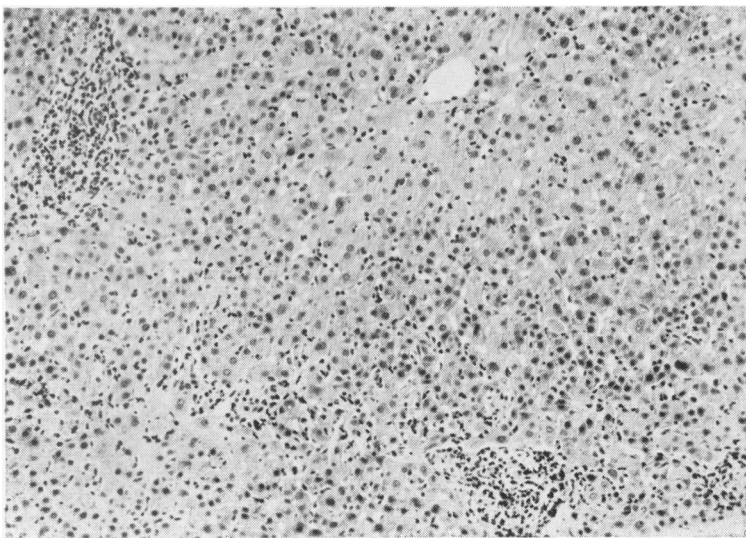


FIG. 5. Liver biopsy specimen obtained from case 1 on the second day after admission for hepatitis showing the characteristic changes observed in specimens from each patient during the acute phase of illness. There was a mononuclear infiltration of the portal areas and sinusoids with foci of hepatic cell necrosis. There was distortion of the hepatic architecture due to irregularity in the liver cells forming the parenchymal columns. B nucleated liver cells were more frequent than balloon cells and acidophilic bodies. Haematoxylin and eosin.

Kalk, 1955; Horváth and Iványi, 1959; Kivel, 1961; Fodor and Tănăsescu, 1962; Conrad *et al.*, 1965). However, in most patients the haematocrit decreases gradually during the first three weeks of clinical illness (Conrad *et al.*, 1964). Subsequently, a moderate reticulocytosis develops and the haematocrit returns to normal values. In part these changes may be attributed to a temporary suppression of bone marrow production which is manifested by a megaloblastoid maturation in about one-third of patients (Conrad *et al.*, 1965). The anaemia associated with a maturation arrest of the bone marrow develops more slowly than leucopenia because circulating red blood cells have a longer life span (Dacie and Lewis, 1963).

In approximately a quarter of patients with acute viral hepatitis the red blood cell survival time is slightly shortened ( $t_{1/2}$ , 15 to 23 days) (Bornemann and Michel, 1955; Kalk, 1955; Horváth and Iványi, 1959; Conrad *et al.*, 1965; Frick and Schmid, 1965). This rate of haemolysis is insufficient to cause anaemia without the simultaneous decrease in production of erythrocytes (Crosby, 1954). Although haemolysis can enhance bilirubinaemia, it does not cause reticulocytosis until patients recover from bone marrow hypofunction (Conrad *et al.*, 1965).

Measurements of red blood cell life span with autologous and homologous labelled erythrocytes indicated that haemolysis was caused by extracorporeal factors (Miescher, 1958; Conrad *et al.*, 1965; Frick and Schmid, 1965). Thus, we could not attribute excessive haemolysis to the production of defective erythrocytes or to a previously undetected hereditary haemolytic disorder. However, the co-existence of an additional cause for haemolysis might worsen the haematological manifestations of hepatitis and explain certain previously reported cases with a moderately severe anaemia (Sansone *et al.*, 1963).

The aetiology of the haemolytic disorder of viral hepatitis is unknown. It is difficult to attribute haemolysis to the liver disease because in most patients with viral hepatitis red blood cells have a normal survival time and some patients have persistent haemolysis long after the disappearance of all stigmata of liver disease (Flood and James, 1947; Kalk, 1955; Fodor and Tănăsescu, 1962; Conrad *et al.*, 1964; Conrad *et al.*, 1965; Frick and Schmid, 1965). It has been postulated that the haemolytic state is caused either by a circulating antibody or is the direct effect of a virus upon red blood cells. Failure to identify the aetiological virus and specific antibodies of hepatitis has made it impossible to prove this hypothesis (Flood and James, 1947; Kalk, 1955; Miescher, 1958; Horváth and Iványi, 1959; Wright and Gardner, 1960; Kivel, 1961;

Fodor and Tănăsescu, 1962; Conrad *et al.*, 1964 and 1965; Frick and Schmid, 1965).

#### SUMMARY

Serial clinical and laboratory studies in 68 soldiers with viral hepatitis revealed three patients with a compensated haemolytic disorder which lasted from one to three years. Each patient had clinical and laboratory studies and histological findings in a liver specimen which were compatible with a diagnosis of infectious hepatitis. One year after the clinical onset of hepatitis these three patients were asymptomatic but had reticulocytosis and indirect bilirubinaemia. Laboratory tests suggestive of liver damage had become normal. A shortened  $^{51}\text{Cr}$  survival of both the patients' red blood cells and labelled donor cells indicated that the haemolytic disorder was extracorporeal. Red blood cell antibodies were not demonstrated in blood specimens from these patients. That the haemolytic state was caused by hypersplenism seemed unlikely because the spleen did not remain palpable, and there were normal numbers of circulating white blood cells and platelets. The persistence of a haemolytic disorder could not be related either to the severity or duration of acute liver disease or relapsed hepatitis.

#### REFERENCES

- Bornemann, K., and Michel, Ç. (1955). Hepatitis epidemica und Hämolyse-Neigung. *Arztl. Wschr.*, 10, 813-817.
- Chalmers, T. C., Eckhardt, R. D., Reynolds, W. E., Cigarroa, J. G., Jr, Deane, N., Reifstein, R. W., Smith, C. W., and Davidson, C. S. (1955). The treatment of acute infectious hepatitis. Controlled studies of the effects of diet, rest, and physical reconditioning on the acute course of the disease and on the incidence of relapses and residual abnormalities. *J. clin. Invest.*, 34, 1163-1235.
- Conrad, M. E., Schwartz, F. D., and Young, A. A. (1964). Infectious hepatitis—a generalized disease. A study of renal, gastrointestinal and hematologic abnormalities. *Amer. J. Med.*, 37, 789-801.
- , Weintraub, L. R., Schwartz, F. D., and Young, A. A. (1965). Viral hepatitis in Korea: Clinical observations and studies performed during prospective studies to obtain specimens for virologic culture. *Progr. Liver Dis.*, 2, 395-415.
- Crosby, W. H. (1954). The hemolytic states. *Bull. N.Y. Acad. Med.*, 30, 27-42.
- Dacie, J. V., and Lewis, S. M. (1963). *Practical Haematology*, pp. 133-206. Grune and Stratton, New York.
- Ebaugh, F. G., Jr, Emerson, C. P., and Ross, J. F. (1953). The use of radioactive chromium $^{51}$  as an erythrocyte tagging agent for the determination of red cell survival *in vivo*. *J. clin. Invest.*, 32, 1260-1276.
- Flood, C. A., and James, E. M. (1947). Clinical and pathological findings in prolonged hepatitis. *Gastroenterology*, 8, 175-184.
- Fodor, O., and Tănăsescu, R. (1962). Post-hepatitis immunological haemolytic anaemia (In Rumanian). *Med. interna (Buc.)*, 14, 1469-1478.
- Frick, P. G., and Schmid, J. R. (1965). Das hämolytische Syndrom bei der akuten und chronischen Hepatitis. *Klin. Wschr.* 43, 305-309.
- Havens, W. P., Jr (1948). Infectious hepatitis. *Medicine (Baltimore)*, 27, 279-326.
- Hirscher, H. (1950). Erworbenne hämolytische Anämie bei Hepatitis. *Dtsch. Gesundh.-Wes.*, 5, 814-819.

- Horváth, G., and Iványi, J. (1959). Hämolyse bei der akuten Virus-hepatitis. *Wien. med. Wschr.*, **109**, 101-102.
- Kalk, H. (1955). Über die posthepatitische Hyperbilirubinämie. *Gastroenterologia (Basel)*, **84**, 207-225.
- Kivel, R. M. (1961). Hematologic aspects of acute viral hepatitis. *Amer. J. dig. Dis.*, **6**, 1017-1031.
- Kjellberg, K. (1941). Ein Fall von akuter hämolytischer Anämie bei akuter Hepatitis. *Kinderärztl. Prax.*, **12**, 296-299.
- Lorenz, E., and Quaiser, K. (1955). Panmyelopathie nach Hepatitis epidemica. *Wien. med. Wschr.*, **105**, 19-22.
- Lucké, B. (1944). The pathology of fatal epidemic hepatitis. *Amer. J. Path.*, **20**, 471-593.
- Menghini, G. (1958). One-second needle biopsy of the liver. *Gastroenterology*, **35**, 190-199.
- Miescher, P. (1958) cited by Keiderling, W., Lee, M., and Schmidt, H. A. E. Eisenstoffwechselstudien bei Leberzellschädigung. *Strahlentherapie*, suppl. **38**, 182-196.
- Neumann, H., and Hommer, E. (1949). Akute splenohepatische Hepatitiden von aussergewöhnlichem serohämatologischem Verhalten. *Klin. Wschr.*, **27**, 747-749.
- Rubin, E., Gottlieb, C., and Vogel, P. (1968). Syndrome of hepatitis and aplastic anemia. *Amer. J. Med.*, **45**, 88-97.
- Sansone, G., Rovei, S., and Rasore-Quartino, A. (1963). Anemia emolitica in glucosio-6-fosfato deidrogenasi erithrocitaria. *G. Mal. infett.*, **15**, 550-556.
- Smetana, H. F. (1963). Pathology of hepatitis. In *Disease of the Liver*, 2nd ed., edited by L. Schiff, pp. 369-424. Lippincott, Philadelphia. Pitman, London.
- Wright, C. S., and Gardner, E., Jr (1960). A study of the role of acute infections in precipitating crises in chronic hemolytic states. *Ann. intern. Med.*, **52**, 530-537.