

Ultrastructural study of two cases of α -chain disease

JACQUES SCOTTO¹, HÉLÈNE STRALIN, AND JACQUES CAROLI with the technical assistance of MONIQUE GEGOU

From the Unité de Recherches de Physio-pathologie Hépato-biliaire, Hôpital Saint-Antoine, Paris, France

SUMMARY Intestinal biopsies of two patients with α heavy-chain disease were examined by electron microscopy. Except for a few differences, cells involved by the malignant neoplasia of the small intestine were similar and belonged to the plasma cell line and were, in fact, more like the cells observed in typical multiple myeloma. It is not surprising to find such cells in a disease which is characterized by the presence of α heavy chain in the serum since plasma cells are considered to be the main source of immunoglobulins. Moreover, the association of an intestinal plasmacytic neoplasia with the heavy chain of the immunoglobulin A in the serum agree with what is known of the normal synthesis by most of the plasma cells of the digestive tract of this immunoglobulin. Since lymphocytes can synthesize immunoglobulins and plasma cells probably originate from lymphocytes, too great an importance should not be attributed to morphological classification. Only an obvious, functional characteristic seems really useful for differentiation.

α -Chain disease has recently been described by Seligmann and Rambaud and their co-workers (Rambaud, Bognel, Prost, Bernier, Le Quintrec, Lambling, Danon, Hurez, and Seligmann, 1968; Seligmann, Danon, Hurez, Mihaesco, Preud'homme, 1968; Seligmann and Rambaud, 1969). This disease, which was previously called the 'mediterranean' type of abdominal lymphoma by Israeli authors (Ramot, Shahin, and Bubis, 1965), is characterized by a severe malabsorption syndrome with malignant neoplasia involving the whole length of the small intestine. We report here the two first ultrastructural observations of the cell proliferation in this disease.

Materials and Methods

The two patients were young men under 30. The specimens of the small intestine were ob-

tained in the first case by biopsy, and during an operation for spontaneous perforation in the second case. A mesenteric lymph node was also taken in the course of the operation.

The tissue was either fixed by glutaraldehyde at 3% and postfixed by osmic acid at 1% or fixed by osmic acid only. The tissue was dehydrated in graded solutions of ethanol and embedded in Epon 812. A Reichert microtome and a glass knife were used for sectioning. Thin sections were stained with uranyl acetate and lead citrate according to the method of Reynolds (1963). In one instance they were also stained using Seligmann's method as modified by Thiery (1967). The examination was carried out with a Siemens Elmiscop IA electron microscope.

Results

CASE 1 (FIGS. 1, 2, AND 3)

The majority of the cells had much the same

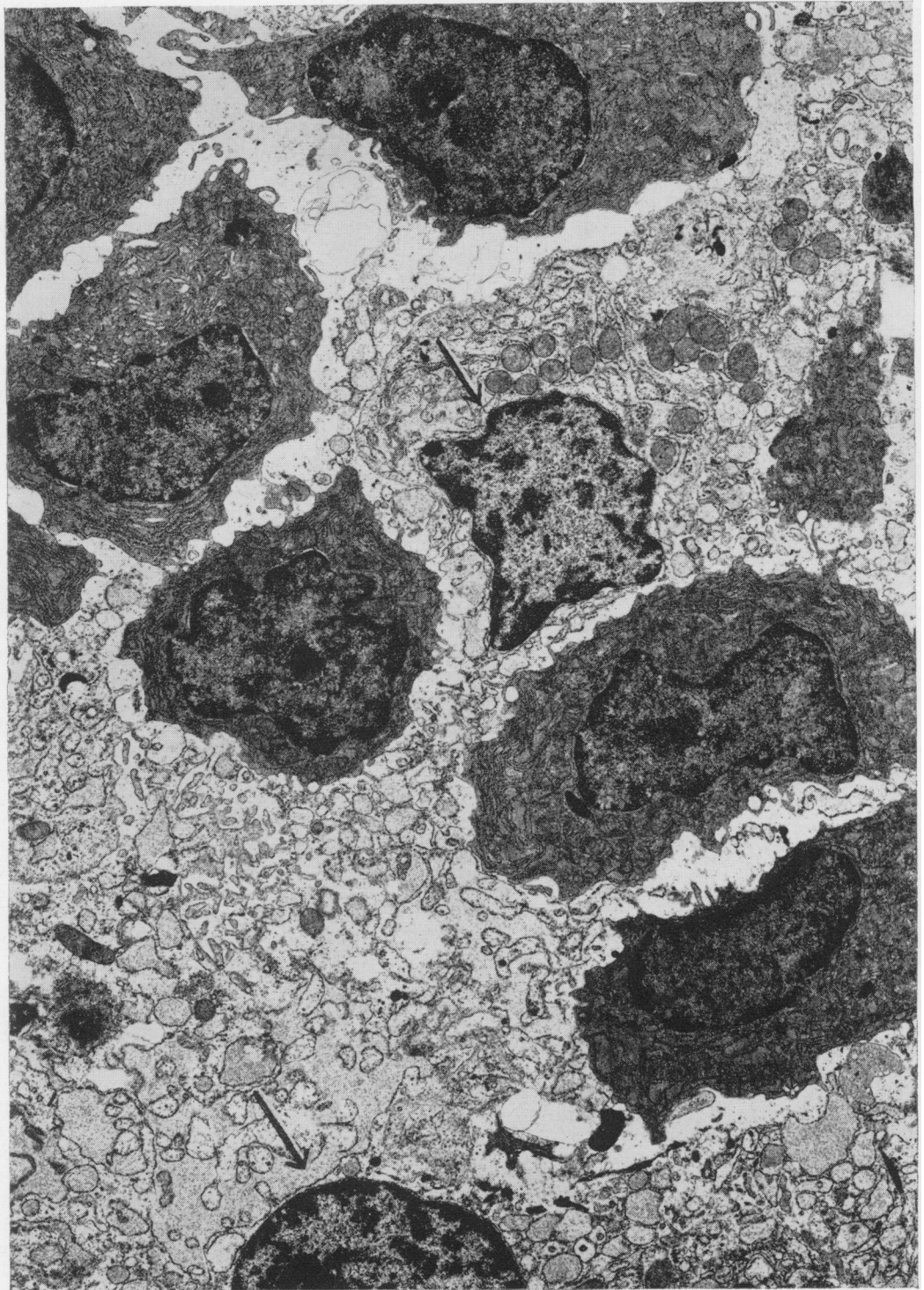


Fig. 1. Proliferating cells which look like plasma cells located in the small intestine. Note the naked nuclei surrounded by cytoplasmic remains (arrows). Double fixation, $\times 6,000$.

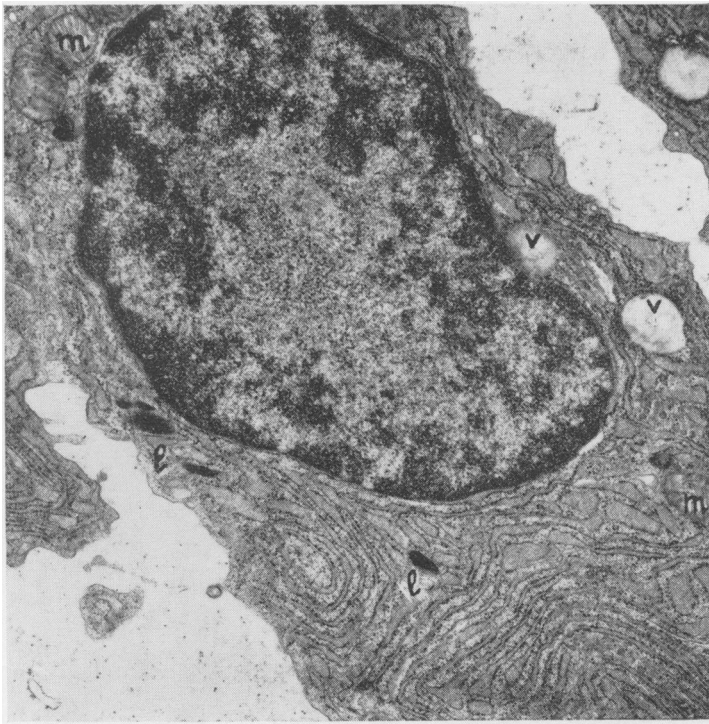


Fig. 2. Neoplastic cell with extensive development of rough-surfaced endoplasmic reticulum. Note the few lysosome-like organelles (l) and two lipid vacuoles (v). Mitochondria (m) are not numerous. Double fixation, $\times 13,600$.

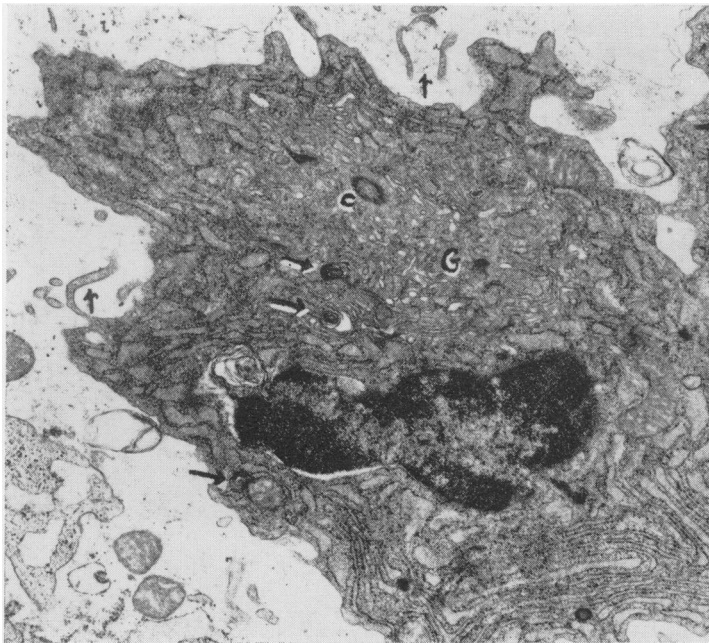


Fig. 3. Neoplastic cell. A large area is occupied by Golgi (G) material and there is a centriole (c). Note some myelin figures (arrows) and the pseudopoid processes of the plasma membrane. Double fixation, $\times 13,600$.

morphology as the plasma cells. Their shapes and those of their nuclei could be described as roughly oval. On central sections the nuclei measured about $5 \times 7 \mu$ and the cells were $13\text{-}15 \mu$ in the major axes and $7\text{-}10 \mu$ in the minor axes. The contours of the nuclei were sometimes irregular, and the plasma membrane formed fairly long pseudopoid processes. Nucleoli were frequently found and were sometimes quite sizeable. The chromatin, which is never clearly seen unless double fixation is performed, was mostly located on the edges of the nuclei, and occasionally clumps appeared though they were less often visible than under a light microscope. Nuclear bodies were normal.

A rough-surfaced endoplasmic reticulum could be seen and it was mostly well developed. Its profile was generally concentric and parallel to the plasma membrane although it was sometimes distended, and included more or less homogeneous material. Under favourable conditions the Golgi apparatus was well developed with occasionally one or more centrioles. The mitochondria were present in moderate numbers. In some cells they were more numerous and appeared abnormal with asymmetrical cristae which were larger than usual. There was also a moderate number of dense granular bodies. Some of these were homogeneous, and could have been lysosomes. Others, although fewer in number, were also homogeneous but rounder and corresponded to Russell bodies. The majority of them were myelin or fingerprint bodies, which were extracellular. A few cells contained one or more lipid vacuoles. The hyaloplasm was clear after osmic acid fixation and darker after double fixation.

An exceptional feature, which occurred only once, was a homogeneous, greyish, amorphous, bulky nuclear inclusion the contents of which were identical to that of the ergastoplasm. Mitoses were not frequent.

Cytochemical methods for characterizing polysaccharides showed the silver deposit on the dense bodies. The contents of the ergastoplasm were never contrasted; a few uniformly scattered glycogen particles were seen in the hyaloplasm.

As well as this cellular type we also found some small lymphocytes, neutrophilic and eosinophilic polymorphonuclear cells, mast or basophilic cells, reticular, and macrophagic cells. Fibrosis was not conspicuous. A relatively large number of naked nuclei, often with nucleoli, were present. These nuclei were often surrounded by cytoplasmic remnants and could be distinguished from plasma-cell nuclei only on the double-fixed specimens; the nucleoplasm was lighter than in the plasma cells and sharpened the chromatin contrast. The epithelium of bowel surface and crypts was sometimes atrophic with rarefaction and shortening of the microvilli.

CASE 2 (FIGS. 4, 5, AND 6)

The majority of the proliferating cells also

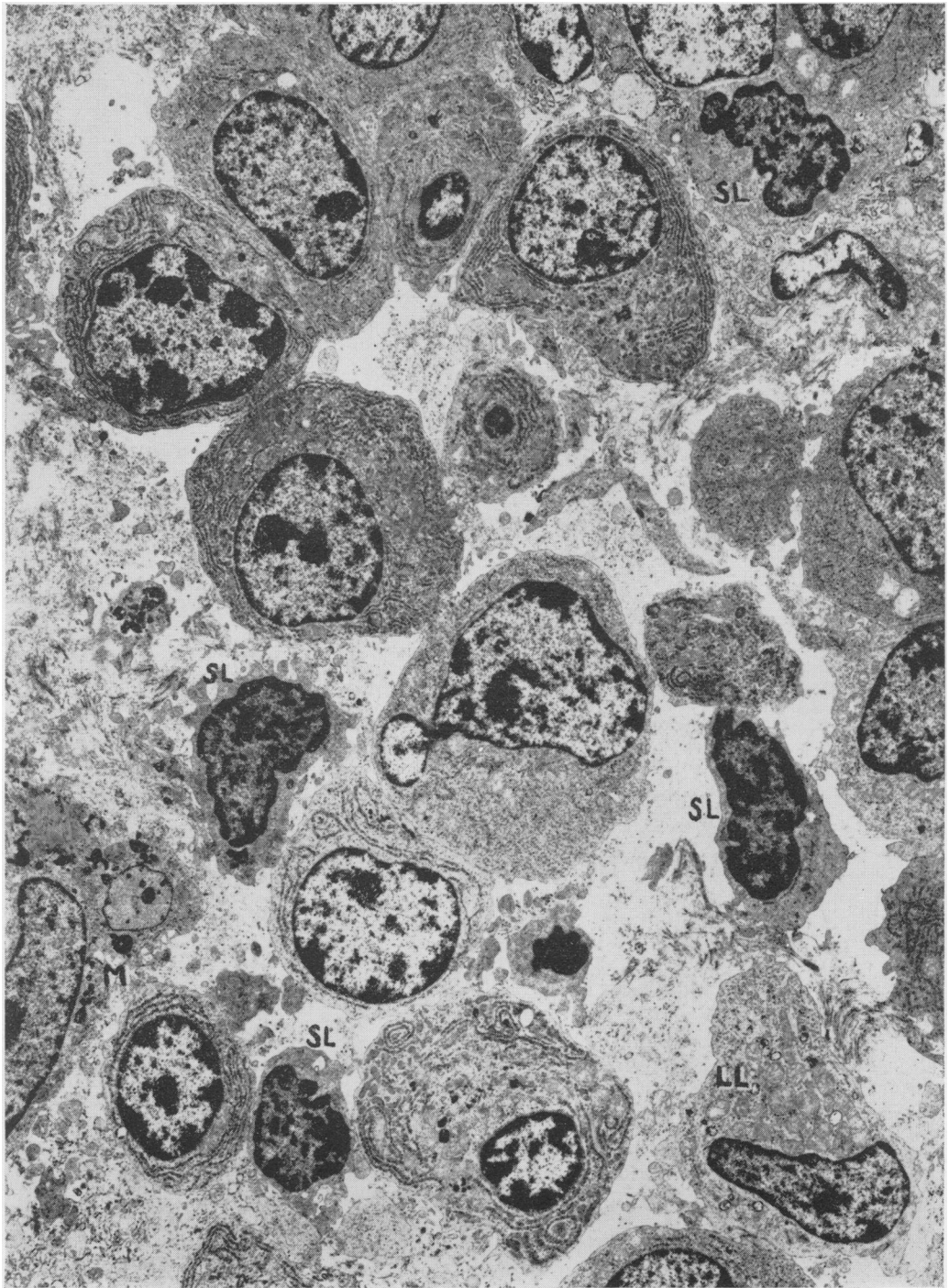


Fig. 4. Proliferating cells located in the small intestine. The majority of the cells has a plasma cell morphology with a variable rough-surfaced endoplasmic reticulum pattern. Note some small lymphocytes (SL), a large lymphocyte (LL) and a macrophagic cell (M). Double fixation, $\times 3,900$.

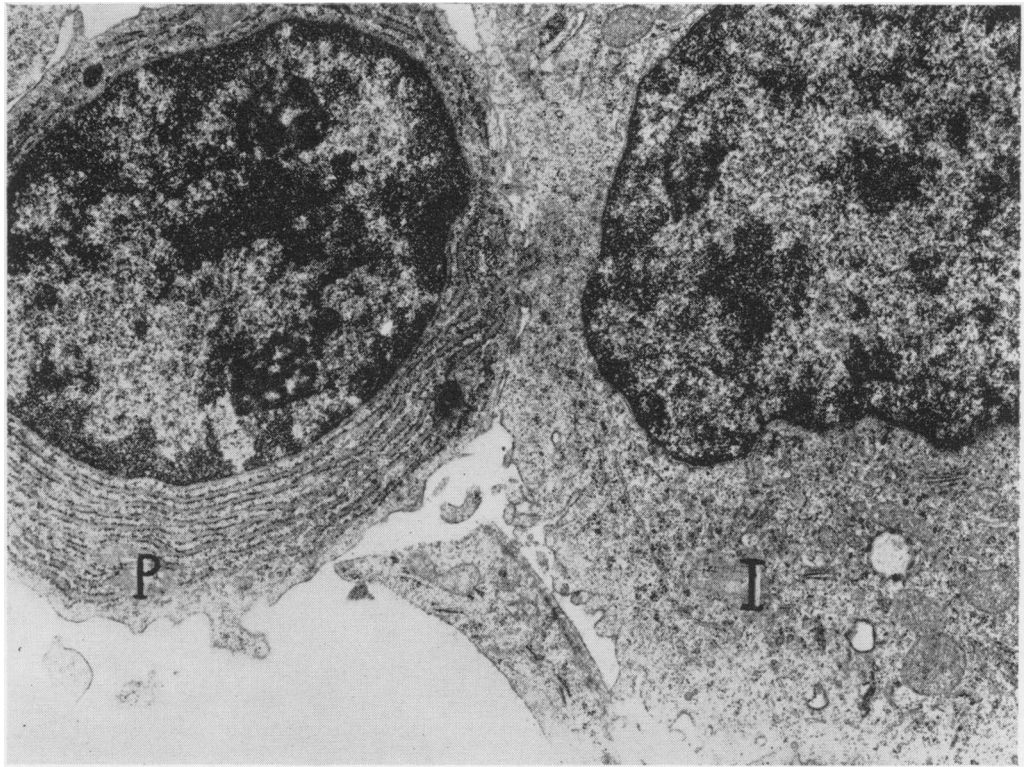


Fig. 5. One cell has the typical morphology of plasma cell (P). The other is a less mature cell or intermediate cell (I). Double fixation, $\times 12,000$.

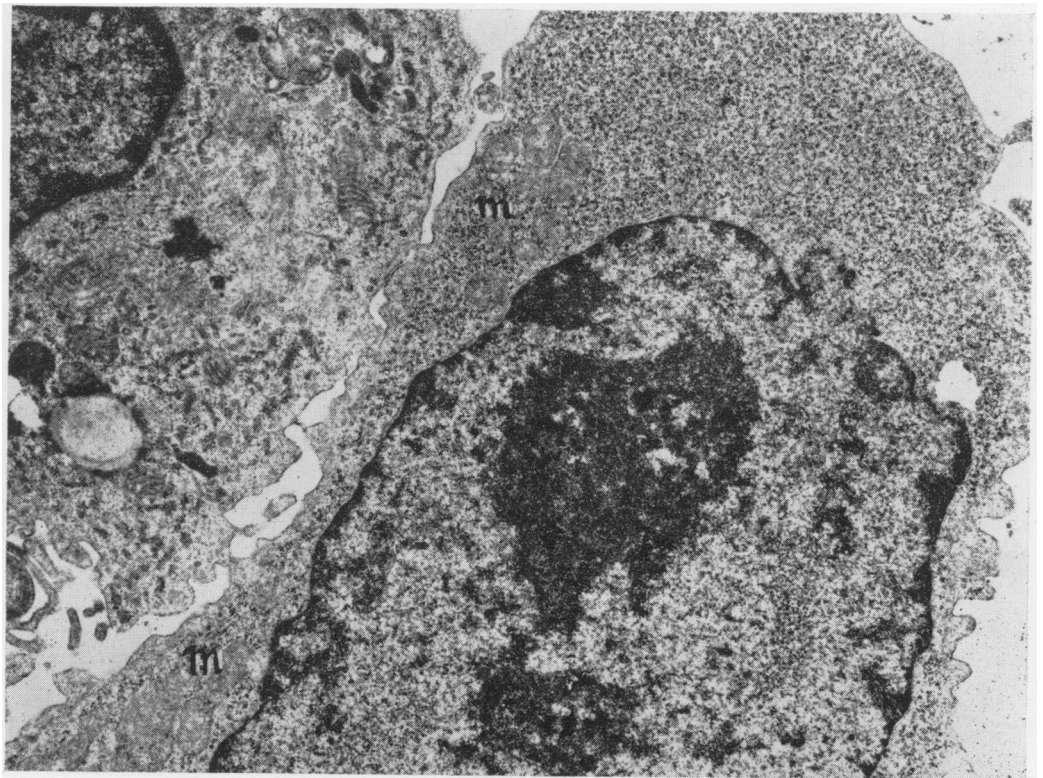


Fig. 6. Blast cell which is like an 'immunoblast'. The cytoplasm is filled with polysomes. The endoplasmic reticulum is absent and few mitochondria (m) are present. Double fixation, $\times 12,000$.

belonged to the plasma cell family. Their size was slightly smaller than in case 1, being 13-14 μ for the major axes and 8-9 μ for the minor axes. Cellular outlines were more regular with no pseudopoid processes. Cells were frequently packed together and therefore were often polyhedric. Nucleoli were larger than in the first case, about $8 \times 6 \mu$, so that nucleoplasmic ratio was raised. The granular endoplasmic reticulum had a variable development as shown by the cells. The reticulum often seemed thickened with many ribosomes. Dense granular bodies were rare and no fingerprint pattern was seen. The number of the mitochondria was never high and naked nuclei were not frequent.

Among the other cellular elements that were noted were a small percentage of great lymphocytes and a few cells which looked like 'immunoblasts'; a large multinucleolar nucleus, with marginal chromatin and irregular outlines; the cytoplasm was stuffed with polysomes clustered in rosettes or small chains; mitochondria were rare and endoplasmic reticulum was practically absent. Some cells seemed to be intermediate forms between these cells and the large lymphocytes or plasma cells. The observation of the lymph node displayed an invasion by many cells identical to those seen in the small intestine.

Comments

In these two cases of α -chain disease, the cell population which constituted the neoplastic growth in the small intestine belonged to the same type. The cells showed the usual morphologic characteristics of plasma cells (Bessis, 1961; Thiery, 1958; Zucker-Franklin, 1964). In one of the two cases, the high percentage of lymphocytes observed on histological sections under the light microscope has not been confirmed by electron microscopy. Some confusion may have resulted from the presence of the fairly numerous and relatively well preserved naked nuclei which, we believe, may have been produced by brittle or recently necrotized plasma cells.

In α -chain disease proliferating cells were in fact more like the cells observed in typical multiple myeloma (Bessis, Breton Gorius, and Binet, 1963; Sorenson, 1964), in some forms of Waldenström's disease (Dutcher and Fahey, 1959; Bessis *et al.*, 1963), and in a case of plasmacytic reticulum-cell sarcoma (Okano, Azar, and Osserman, 1966).

Among dense granular bodies, though they were smaller, a few had the morphology and situation of Russell bodies (Thiery, 1958; Bessis *et al.*, 1963; Zucker-Franklin, 1964; Sorenson, 1964; Maldonado, Brown, Bayrd, and Pease, 1966a). As to the others, which looked like myelin figures, we feel that they must correspond to a product of disintegration rather than to a con-

centrated material of secretion possessing the significance of Russell bodies. These cells were different from cells belonging to the myeloid, lymphoid, or reticular series found in some cases of sarcoma and of leukaemia (Braunsteiner, Fellinger, and Pakesch, 1957; Bessis and Thiery, 1961; de Harven, Clarkson, and Strife, 1967; Dmochowski, Yumoto, Grey, Hales, Langford, Taylor, Freireich, Shullenberger, Shively, and Howe, 1967).

A small number of cells corresponded to intermediate lymphocytoid plasma cells which were observed in greater numbers in most cases of Waldenström's disease (Dutcher and Fahey, 1959; Bessis *et al.*, 1963; Zucker-Franklin, 1964) and in the first case of γ heavy-chain disease (Zucker-Franklin, 1964; Franklin, Lowenstein, Bigelow, and Meltzer, 1964). Such cells have also been mentioned in some case of multiple myeloma (Maldonado, Kyle, Brown, and Bayrd, 1966b) and in a peculiar disorder associated with disturbance of IgG (Colman, Osterland, Dorfman, and Chaplin, 1968). In the present series the great number of cells agrees with the now classic idea of immunoglobulin synthesis by this cell type (Thiery, 1956; Matsuoka, Takahashi, Yagi, Moore, and Pressman, 1968). Moreover, since most plasma cells in the digestive tract secrete IgA, there is nothing surprising in the fact that a proliferation of malignant plasma cells occurring at the same level should secrete the heavy chain of this immunoglobulin. But the finding of the intermediate forms of the cells is a reminder of the danger of using morphological characters to classify cells. How useful is this classification now that we know that lymphocytes, even though they are immature without any ergastoplasm at all, can also synthesize immunoglobulins (Lobb, 1968; Bosman, Feldman, and Pick, 1969)? Moreover, this classification seems all the more futile given the new understanding of the origin of plasma cells which has shown their close relationship with lymphocytes. Indeed, the plasma cell probably originates either directly in the reticular cell like the lymphocyte, or in the lymphocyte itself with the blast cell, transformed lymphocyte, or immunoblast acting as the intermediary (Thiery, 1956; Rebeck and Lo Grippo, 1961; Binet, Mathé, Seman, Kinsky, and Amiel, 1961; Douglas and Fudenberg, 1969). Also, we have observed a number of cells of this type in one of our two cases. While such a cell would already have been able to synthesize immunoglobulin for some time after this stage of transformation it might be very difficult to distinguish morphologically a plasma cell from a lymphocyte.

We may conclude that most cases of paraproteinaemia are associated with a proliferation of cells which is easy and helpful to classify the condition in a well known category. But the obstacle found in classifying some cases reminds us that we should not attribute too much

importance to any such classification. It is in fact more and more evident that all these types of cell are able normally to synthesize the same kinds of Ig proteins.

We are indebted to Professor J. J. Bernier, Dr J. C. Rambaud, and Dr J. C. Bognel for supplying the specimens taken from these two cases. The immunological analyses were carried out by Professor M. Seligmann and his colleagues.

References

- Bessis, M. C. (1961). Ultrastructure of lymphoid and plasma cells in relation to globulin and antibody formation. *Lab. Invest.*, **10**, 1040-1067.
- Bessis, M. C., and Thiery, J. P. (1961). I. Les leucémies granulocytaires. Études au microscope électronique sur cellules les leucémies humaines. *Nouv. Rev. franc. Hémat.*, **1**, 703-728.
- Bessis, M. C., Breton-Gorius, J., and Binet, J. L. (1963). Étude comparée du plasmocytome et du syndrome de Waldenström. *Nouv. Rev. franc. Hémat.*, **3**, 159-183.
- Binet, J. P., Mathé, G., Seman, G., Kinsky, L., and Amiel, J. L. (1961). Aspects morphologiques des cellules 'immunologiquement compétentes' au cours des réactions de greffes allogéniques. *Nouv. Rev. franc. Hémat.*, **1**, 887-899.
- Bosman, C., Feldman, J. D., and Pick, E. (1969). Heterogeneity of antibody forming cells. An electron microscopic analysis. *J. exp. Med.*, **129**, 1029-1044.
- Braunsteiner, H., Fellingner, K., and Pakesch, F. (1957). Electron microscopic investigations on sections from lymph nodes and bone marrow in malignant blood diseases. *Blood*, **12**, 278-294.
- Colman, R. W., Osterland, C. K., Dorfman, R. F., and Chaplin, H. A. (1968). A unique lymphoproliferative disorder associated with an IgM platelet agglutinin, diffuse hypergammaglobulinemia, amyloid deposition and excessive urinary excretion of IgG fragments. *Amer. J. Med.*, **45**, 607-618.
- Dmochowski, L., Yumoto, T., Grey, C. E., Hales, R. L., Langford, P. L., Taylor, H. G., Freireich, E. J., Shullenberg, C. C., Shively, J. A., and Howe, C. D. (1967). Electron microscopic studies of human leukemia and lymphoma. *Cancer (Philad.)*, **20**, 760-777.
- Douglas, S. D., and Fudenberg, H. H. (1969). *In vitro* development of plasma cells from lymphocytes following pokeweed mitogen stimulation: a fine structural study. *Exp. Cell Res.*, **54**, 277-279.
- Dutcher, T. F., and Fahey, J. L. (1959). The histopathology of the macroglobulinemia of Waldenström. *J. nat. Cancer Inst.*, **22**, 887-917.
- Franklin, E. C., Lowenstein, J., Bigelow, B., and Meltzer, M. (1964). Heavy chain disease. A new disorder of serum γ globulins. Report of the first case. *Amer. J. Med.*, **37**, 332-350.
- Harven, E. de, Clarkson, B., and Strife, A. (1967). Electron microscopic study of human leukemic cells in tissue culture. *Cancer (Philad.)*, **20**, 911-925.
- Lobb, N. (1968). The synthesis of immunoglobulin-G by cultured human lymphocytes. *Aust. J. exp. Biol. méd. Sci.*, **46**, 397-405.
- Maldonado, J. E., Brown, A. L., Jr., Bayrd, E. D., and Pease, G. L. (1966a). Cytoplasmic and intranuclear electron dense bodies in the myeloma cell. Light and electron microscopy observations. *Arch. Path.*, **81**, 484-500.
- Maldonado, J. E., Kyle, R. A., Brown, A. L., Jr., and Bayrd, E. D. (1966b). 'Intermediate' cell types and mixed cell proliferation in multiple myeloma: electron microscopic observations. *Blood*, **27**, 212-226.
- Matsuoka, Y., Takahashi, M., Yagi, Y., Moore, G. E., and Pressman, D. (1968). Synthesis and secretion of immunoglobulins by established cell lines of human hematopoietic origin. *J. Immunol.*, **101**, 1111-1120.
- Okano, H., Azar, H. A., and Osserman, E. F. (1966). Plasmacytic reticulum cell sarcoma. Case report with electron microscopic studies. *Amer. J. clin. Path.*, **46**, 546-555.
- Rambaud, J. C., Bognel, C., Prost, A., Bernier, J. J., Le Quintrec, Y., Lambling, A., Danon, F., Hurez, D., and Seligmann, M. (1968). Clinico-pathological study of a patient with 'mediterranean' type of abdominal lymphoma and a new type of IgA abnormality (alpha chain disease). *Digestion*, **1**, 321-336.
- Ramot, B., Shahin, N., and Bubis, J. J. (1965). Malabsorption syndrome in lymphoma of small intestine. A study of 13 cases. *Israel J. med. Sci.*, **1**, 221-226.
- Rebuck, J. W., and Lo Grippo, G. A. (1961). Characteristics and interrelationships of the various cells in RE cell, macrophage, lymphocyte and plasma cell series in man. *Lab. Invest.*, **10**, 1068-1093.
- Reynolds, E. S. (1963). The use of lead citrate at high pH as an electron opaque stain in electron microscopy. *J. Cell Biol.*, **17**, 208-212.
- Seligmann, M., Danon, F., Hurez, D., Mihaesco, E., and Preud'homme J. L. (1968). Alpha chain disease: a new immunoglobulin abnormality. *Science*, **162**, 1396-1397.
- Seligmann, M., and Rambaud, J. C. (1969). IgA abnormalities in abdominal lymphoma (α chain disease). *Israel J. med. Sci.*, **5**, 151-157.
- Sorenson, G. D. (1964). Electron microscopic observations of bone marrow from patients with multiple myeloma. *Lab. Invest.*, **13**, 196-213.
- Thiery, J. P. (1956). Ultrastructure et fonction des cellule impliquées dans la réaction immunitaire. *Bull. Soc. chim. biol. (Paris)*, **50**, 1077-1099.
- Thiery, J. P. (1958). Étude sur le plasmocyte en contraste de phase en microscopie électronique. III. Plasmocytes à corps de Russell et à cristaux. *Rev. Hémat.*, **13**, 61-78.
- Thiery, J. P. (1967). Mise en évidence des polysaccharides sur coupes fines en microscopie électronique. *J. Microscopie*, **6**, 987-1018.
- Zucker-Franklin, D. (1964). Multiple myeloma. II Structural features of cells associated with the paraproteinemias. *Semin. Hematol.*, **1**, 165-198.