

# Intestinal pseudo-obstruction in systemic amyloidosis

DAVID A. LEGGE, ERIC E. WOLLAEGER, AND HARLEY C. CARLSON

*From the Sections of Internal Medicine and of Roentgenology, Mayo Clinic and Mayo Foundation and the Mayo Graduate School of Medicine, University of Minnesota, Rochester*

**SUMMARY** The occurrence of clinical manifestations of mechanical intestinal obstruction in eight cases of systemic amyloidosis is reported. Seven similar cases have been recorded in the literature and are briefly reviewed. Correct diagnosis is important in these cases if useless surgical treatment or prolonged diagnostic investigations are to be avoided. Gastrointestinal involvement by systemic amyloidosis should be considered in a patient presenting with clinical manifestations of mechanical obstruction but paralytic ileus seen on plain films. In these cases an attempt should be made, by means of a barium enema, to exclude an obstructing lesion of the colon or distal small bowel. Once amyloidosis is considered, it can be confirmed easily and safely by biopsy of the rectal or small-intestinal mucosa.

Intestinal pseudo-obstruction has been defined by Stephens (1962) as the occurrence of clinical manifestations of mechanical obstruction of the intestine with no organic occlusion of the lumen. This syndrome has seldom been reported as occurring secondarily to amyloid infiltration of the gastrointestinal tract, yet it not infrequently complicates the course of systemic amyloidosis. In a review of 121 proved cases of systemic amyloidosis at the Mayo Clinic, we encountered eight in which clinical manifestations of mechanical obstruction of the intestine developed during the illnesses. Recognition of this condition is important in order to avoid surgical treatment which would be ineffectual and which is associated with a high mortality and dangerous complications.

## Report of an Illustrative Case

A 55-year-old white man came to the Mayo Clinic complaining of shortness of breath and generalized weakness of five months' duration. A diagnosis of multiple myeloma had been made elsewhere at the onset of these symptoms. For

Received for publication 2 February 1970.

two months he complained of increasing constipation and intermittent, crampy, abdominal pain and distension, aggravated by the ingestion of food.

When he was admitted gaseous distension of the abdomen was noted. Four days later there was an increase in abdominal distension, associated with crampy abdominal pain; bowel sounds were noted to be high-pitched. A plain radiograph of the abdomen revealed gaseous distension of the colon as far as the splenic flexure but with no gas distal to this (Fig. 1). A barium enema study was not obtained. However, a presumptive diagnosis of carcinoma of the splenic flexure of the colon was made.

A brief attempt at decompression by enemas and nasogastric suction was not effective, so emergency surgery was undertaken. Transverse loop colostomy was performed, but the patient died the following day. At necropsy the diagnosis of multiple myeloma was confirmed, and amyloid was found deposited in the heart and in the entire gastrointestinal tract. The amyloid was scattered in the circular and longitudinal muscle layers of the intestines and was particularly heavy at the splenic flexure of the colon. The large bowel was distended up to this segment and collapsed distally. No mechanical obstruction was present.

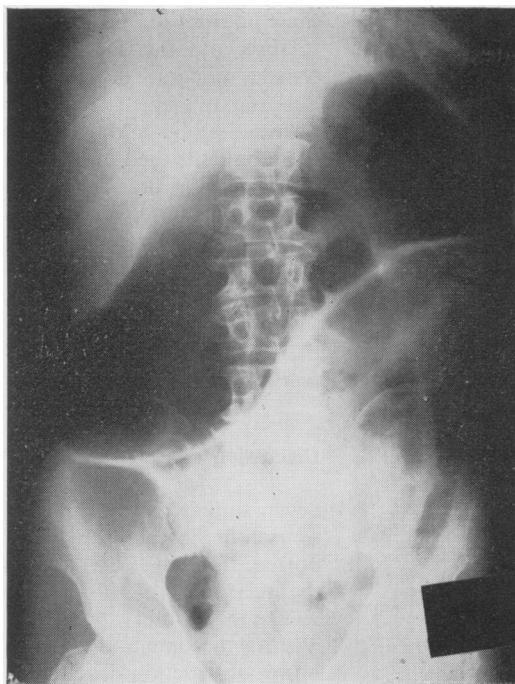


Fig. 1. Plain radiograph of the abdomen shows gaseous distension of the colon as far as the splenic flexure, suggesting mechanical obstruction at this site.

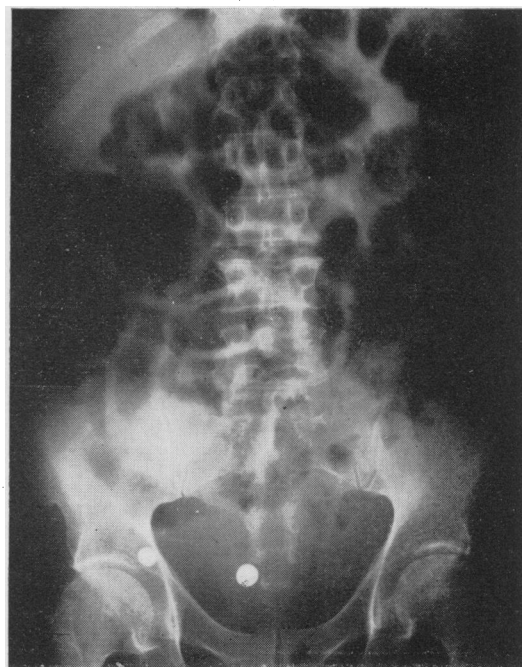


Fig. 2. Plain radiograph of the abdomen (case 3) shows gaseous distension of both the small and large intestine, suggesting paralytic ileus.

Case	Age (yr) and Sex	Predisposing Disease	Diagnosis Established	Treatment	Interval between Onset of Obstruction and Death
1	55 M	Multiple myeloma, 5 mth	Necropsy (see text)	Miller-Abbott tube and enemas; transverse loop colostomy	5 days
2	55 M	None	Necropsy: amyloid in jejunum, colon, heart, lungs, kidneys; rectal biopsy just before death	Miller-Abbott tube and enemas; surgery planned but not done	3 wk
3	55 M	Multiple myeloma, 4 mth	Rectal biopsy	Miller-Abbott tube and enemas	3 mth
4	53 M	Multiple myeloma, 4 yr	Biopsy of small bowel and colon during surgery	Transverse colostomy	11 mth
5	63 M	Multiple myeloma, 4 yr	Necropsy: amyloid in heart, lungs, liver, entire gastrointestinal tract; multiple myeloma involving all bones	Miller-Abbott tube and enemas; surgery considered but deferred because of congestive heart failure	3 mth
6	70 F	Rheumatoid arthritis, 16 yr	Necropsy: widespread involvement of all organs	Loop colostomy, proximal transverse colon	6 wk
7	67 F	Rheumatoid arthritis, 12 yr	Rectal biopsy; necropsy: diffuse amyloidosis	Miller-Abbott tube and enemas	5 wk
8	46 M	Quadriplegia, 13 yr	Gingival biopsy	Miller-Abbott tube and enemas	7 wk

Table Summary of the clinical data from patients with acute intestinal obstruction associated with systemic amyloidosis

### Review of Clinical Data

Some pertinent features of the remaining seven cases are summarized in the Table. These cases were selected because they too presented the usual signs of mechanical intestinal obstruction: constipation, crampy abdominal pain with associated abdominal distension, and high-pitched bowel sounds. In four cases the obstruction was so severe that the patients were unable to pass flatus; three of these four patients, and two others, had nausea and vomiting as well.

The clinical presentation of six of these cases was like that of the illustrative case: chronic, intermittent, obstructive symptoms which developed into an acute phase that necessitated hospitalization. The remaining patient (case 2) had no chronic obstructive symptoms until he presented in an acute condition with apparent intestinal obstruction.

Radiographs of the abdomen were available in five of these other cases. In one, they were identical to those of the illustrative case, with gaseous distension extending as far as the

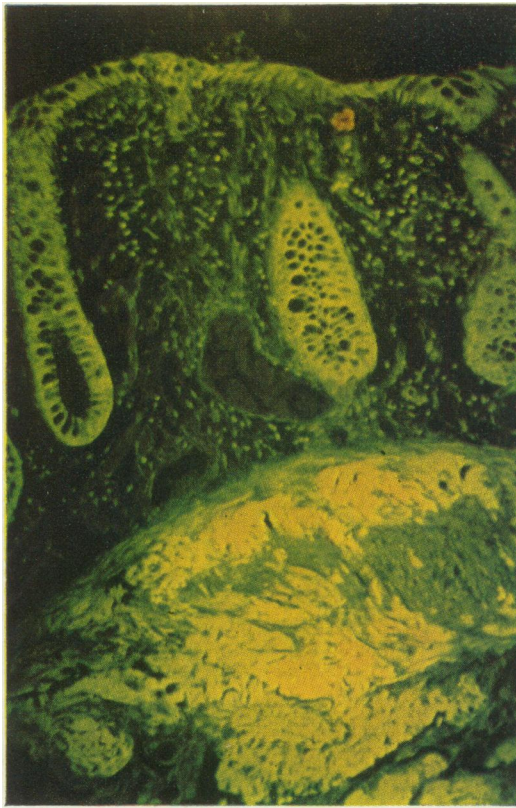


Fig. 3. Biopsy from colon in case 2. Approximately 75% of smooth muscle is replaced by amyloid, the yellow fluorescent material between the muscle bundles. Mucous glands also take up this stain. (Thioflavin T  $\times 100$ .)

splenic flexure; in the four others they showed gaseous distension of both small and large intestine suggestive of a paralytic type of obstruction (Fig. 2). In spite of this, in all our cases the other clinical manifestations were so characteristic of a mechanical obstruction that a lesion amenable to surgical treatment was thought to be present. However, in two cases one of us (E.E.W.) suggested the diagnosis of amyloidosis, and the patients were spared an operation when this diagnosis was established by biopsy of the rectal mucosa.

In three cases an operation was performed because of a presumptive preoperative diagnosis of mechanical large bowel obstruction. Two of these patients died in the immediate postoperative period. The third patient underwent transverse colostomy but, one month later, the bowel at the stoma prolapsed, became infarcted, and required excision. However, this patient survived for a further nine months, with increasing symptoms of obstruction and eventual obstipation.

The remaining patients were treated conservatively; acute phases of intestinal pseudo-obstruction were managed with decompression by Miller-Abbott intubation, intravenous fluids, and daily enemas. Once over the acute phase,

these patients survived for periods of three weeks to three months. During this time they experienced a moderate degree of abdominal distension but four managed to avoid recurrence of acute obstruction by taking regular enemas. Two of these patients died of heart failure, one of renal insufficiency, and one of a combination of pneumonia and chronic intestinal pseudo-obstruction. The remaining patient obtained a satisfactory result from conservative treatment during a phase of acute intestinal pseudo-obstruction but later died at home, apparently from a recurrence of this type of obstruction.

## Discussion

Seven similar cases of intestinal pseudo-obstruction complicating amyloidosis have been reported. Randall (1933) was the first to emphasize the occurrence of this complication. His patient was under observation for multiple myeloma when symptoms and signs of mechanical small bowel obstruction developed. Surgical treatment was undertaken, but the patient died immediately after the operation. At necropsy the entire small bowel was found to contain a large amount of amyloid, especially in the circular muscle layer. Six other cases have been reported in various series by A. Golden (1945), R. Golden (1954), Korelitz and Spindell (1956), Brown (1964), and Gilat and Spiro (1968). In all, the clinical manifestations were those of a mechanical type of bowel obstruction. Two of the six patients underwent operation and died soon thereafter: two apparently died from persistent intestinal pseudo-obstruction, one three months and the other several weeks after the onset of obstructive symptoms; one died of renal insufficiency; and one died of a pulmonary embolism which occurred while the patient was hospitalized for treatment of intestinal pseudo-obstruction.

In a careful necropsy study, Gilat, Revach, and Sohar (1968) found gastrointestinal deposition of amyloid material in 68 of 70 cases of systemic amyloidosis. Almost all of their cases of primary amyloidosis and amyloidosis associated with multiple myeloma and more than one third of their cases of secondary amyloidosis had deposits of amyloid within the muscle layers of the intestines. Thus, smooth muscle is replaced by amyloid material (Fig. 3). Interference with motor function probably depends on the amount of amyloid deposited within the bowel wall and, unless this substance almost totally replaces smooth muscle, some propulsive activity no doubt occurs. Korelitz and Spindell (1956) reported that radiological examination of patients in whom the small bowel was infiltrated by amyloid is likely to reveal a prolonged time of transit of barium from the stomach to the colon, with no localized obstructing lesion. In

four of our cases, plain films of the abdomen have shown gas to be scattered throughout the distended bowel with no localized site of obstruction, giving the appearance of paralytic ileus. However, the clinical picture presented by these patients is otherwise more characteristic of mechanical bowel obstruction and is associated with abdominal cramps and active bowel sounds. Such manifestations probably result from propulsive activity in portions of bowel less heavily infiltrated with amyloid than the more distal segments, since the deposition of amyloid usually is not uniform.

In two of our cases (cases 1 and 2) the plain radiograph showed the features of mechanical obstruction of the colon at the splenic flexure (Fig. 1). At necropsy in both these cases amyloid was present throughout the intestine but colonic deposition was particularly heavy. In one case, preoperative radiographs were not available to us and in another they were technically unsatisfactory. In the remaining four cases, as noted, clinical signs of mechanical obstruction were present, except that the appearance of radiographs on plain films was that of paralytic obstruction (Fig. 2). This paradoxical combination should alert the clinician to the fact that he is not dealing with the typical mechanical bowel obstruction. Such a combination would be expected to occur in a disease that diffusely affects smooth muscle of the bowel, such as amyloidosis. Barium enema studies should be obtained in these cases to rule out carcinoma or other causes of mechanical colonic obstruction. These were obtained in only one of our cases, probably because of the fear of barium impaction.

In scleroderma, intestinal obstruction may also occur due to a similar mechanism. Treacy, Bunting, Gambill, and Code (1962) reviewed the histories of 306 patients with generalized scleroderma and found manifestations of intestinal obstruction in four with small bowel involvement. Of help in the differential diagnosis is the fact that such patients are invariably found to have oesophageal involvement by scleroderma, with characteristic radiological changes. In addition, they usually exhibit vasospastic phenomena in the hands and the characteristic skin changes of scleroderma.

Gastric outlet obstruction is also known to occur in amyloidosis as a result of deposits about the pylorus. Cooley (1953) cited four such cases from the literature and added one of his own. Paralytic ileus has been reported by Akbarian and Fenton (1964) and by Brody, Wertlake, and Laster (1964) to be associated with infarction and perforation of the gut, resulting from deposition of amyloid in blood vessels, but in these cases there are associated signs of peritoneal irritation. Areas of infarction of the gut were not present in the four of our cases that were examined at necropsy nor in any of the seven cases reviewed from the literature.

Of the six patients who underwent operation

(including our own cases and those previously reported), five died in the postoperative period. The remaining patient (case 4 in our series) lived for nine months with a colostomy. Because of the diffuse involvement of the bowel, surgical treatment cannot be expected to benefit these patients. Furthermore, associated cardiac or renal involvement by amyloid greatly increases the risk of operation.

The importance of making a correct diagnosis is therefore apparent. Gastrointestinal involvement by amyloid should be considered in patients who have obscure cardiac or renal disease or a predisposing disease such as multiple myeloma, paraplegia, or rheumatoid arthritis, and who manifest gastrointestinal symptoms. These patients should have barium enema studies followed by barium studies of the small bowel when occlusion of the colon is ruled out. The diagnosis can be confirmed easily and safely by biopsy of mucosa of the rectum or small intestine as described by Green, Higgins, Brown, Hoffman, and Somerville (1961) and by Fentem, Turnberg, and Wormsley (1962). The problem may be particularly difficult in early cases of intestinal obstruction in which the nausea, vomiting, or intestinal cramps may be ascribed to associated uraemia, hypercalcaemia, or cytotoxic medications, such as alkeran (Melphalan), used in the treatment of multiple myeloma. In case 3 such symptoms were ascribed to the hypercalcaemia associated with multiple myeloma and for six weeks efforts were made to reduce the serum calcium before the correct diagnosis was established.

#### References

- Akbarian, M., and Fenton, J. (1964). Perforation of small bowel in amyloidosis: includes review of the literature. *Arch. intern. Med.*, **114**, 815-821.
- Brody, I. A., Wertlake, P. T., and Laster, L. (1964). Causes of intestinal symptoms in primary amyloidosis. *Arch. intern. Med.*, **113**, 512-518.
- Brown, J. (1964). Primary amyloidosis. *Clin. Radiol.*, **15**, 358-367.
- Cooley, R. N. (1953). Primary amyloidosis with involvement of the stomach. *Amer. J. Roentgenol.*, **70**, 428-436.
- Fentem, P. H., Turnberg, L. A., and Wormsley, K. G. (1962). Biopsy of the rectum as an aid to the diagnosis of amyloidosis. *Brit. med. J.*, **1**, 364-366.
- Gilat, T., Revach, M., and Sohar, E. (1968). Deposition of amyloid in the gastrointestinal tract. *Gut*, **10**, 98-104.
- Gilat, T., and Spiro, H. M. (1968). Amyloidosis and the gut. *Amer. J. dig. Dis.*, **13**, 619-633.
- Golden, A. (1945). Primary systemic amyloidosis of the alimentary tract. *Arch. intern. Med.*, **75**, 413-416.
- Golden, R. (1954). Amyloidosis of the small intestine. *Amer. J. Roentgenol.*, **72**, 401-411.
- Green, P. A., Higgins, J. A., Brown, A. L., Hoffman, H. N., and Somerville, R. L. (1961). Amyloidosis: Appraisal of intubation biopsy of the small intestine in diagnosis. *Gastroenterology*, **41**, 452-456.
- Korelitz, B. I., and Spindell, L. N. (1956). Gastrointestinal amyloidosis: Report of a case and review of the clinical and radiological aspects. *J. Mt Sinai Hosp.*, **23**, 683-696.
- Randall, O. S. (1933). Multiple myeloma complicated by intestinal obstruction due to amyloid infiltration of small intestine. *Amer. J. Cancer*, **19**, 838-846.
- Stephens, F. O. (1962). The syndrome of intestinal pseudo-obstruction. *Brit. med. J.*, **1**, 1248-1250.
- Treacy, W. L., Bunting, W. L., Gambill, E. E., and Code, C. F. (1962). Scleroderma presenting as obstruction of the small bowel. *Proc. Mayo Clin.*, **37**, 607-616.