

# Clinical review

## Acute appendicitis

DJ Humes, J Simpson

Division of  
Gastrointestinal  
Surgery, Section of  
Surgery, University  
Hospital, Queen's  
Medical Centre,  
Nottingham  
NG7 2UH

DJ Humes  
*Research into Ageing/  
Royal College of  
Surgeons of England  
research fellow*

J Simpson  
*lecturer in surgery*

Correspondence to:  
J Simpson  
j.simpson@  
nottingham.ac.uk

BMJ 2006;333:530-4

The diagnosis of acute appendicitis is predominantly a clinical one; many patients present with a typical history and examination findings. The cause of acute appendicitis is unknown but is probably multifactorial; luminal obstruction and dietary and familial factors have all been suggested.<sup>1</sup> Appendectomy is the treatment of choice and is increasingly done as a laparoscopic procedure. This article reviews the presentation, investigation, treatment, and complications of acute appendicitis and appendectomy.

### How common is appendicitis?

Appendicitis is the most common abdominal emergency and accounts for more than 40 000 hospital admissions in England every year.<sup>2</sup> Appendicitis is most common between the ages of 10 and 20 years, but no age is exempt.<sup>3</sup> A male preponderance exists, with a male to female ratio of 1.4:1; the overall lifetime risk is 8.6% for males and 6.7% for females in the United States.<sup>3</sup> Since the 1940s the incidence of hospital admission for acute appendicitis has been falling, but the reason for this decline is not clear.<sup>w1</sup>

### How do I diagnose it?

Diagnosis of acute appendicitis relies on a thorough history and examination.<sup>w2</sup>

### History

Abdominal pain is the primary presenting complaint of patients with acute appendicitis. The diagnostic sequence of colicky central abdominal pain followed by vomiting with migration of the pain to the right iliac fossa was first described by Murphy but may only be present in 50% of patients.<sup>4</sup> Typically, the patient describes a peri-umbilical colicky pain, which intensifies during the first 24 hours, becoming constant and sharp, and migrates to the right iliac fossa. The initial pain represents a referred pain resulting from the

### Sources and selection criteria

We reviewed the Cochrane database for articles relating to acute appendicitis. We searched Medline for the past two years (up to June 2006) to find any recent meta-analyses, systematic reviews, or randomised controlled trials relating to appendicitis that JS had not included in the latest *Clinical Evidence* review. We also included important historical articles

### Summary points

Appendicitis is the most common abdominal surgical emergency

Not all patients present in a typical manner

Patients at the extremes of age have increased mortality because of late presentation or subtle signs

Specialist investigations should not delay definitive treatment

Computed tomography scanning is more sensitive and specific than ultrasonography when diagnosing acute appendicitis

Laparoscopic appendectomy is becoming increasingly common, and clinical evidence suggests that it has some advantages over open surgery

Wound infections can be decreased with the use of perioperative antibiotics

visceral innervation of the midgut, and the localised pain is caused by involvement of the parietal peritoneum after progression of the inflammatory process. Loss of appetite is often a predominant feature, and constipation and nausea are often present. Profuse vomiting may indicate development of generalised peritonitis after perforation but is rarely a major feature in simple appendicitis. A meta-analysis of the symptoms and signs associated with a presentation of acute appendicitis was unable to identify any one diagnostic finding but showed that a migration of pain was associated with a diagnosis of acute appendicitis.<sup>5</sup>

This classic presentation can be influenced by the age of the patient and anatomical position of the appendix (box 1).<sup>w3</sup> Patients at the extremes of the age spectrum can present diagnostic difficulty because of non-specific presentation, often with subtle clinical signs. Infants and young children often seem withdrawn, and elderly people may present with



References w1-w25 are on [bmj.com](http://bmj.com)

**Box 1: Anatomical considerations in the presentation of acute appendicitis**

The vermiform appendix is a tubular structure attached to the base of the caecum at the confluence of the taeniae coli. It is approximately 8-10 cm long in adults and represents the underdeveloped distal end of the large caecum seen in other animals. In humans it is regarded as a vestigial organ, and acute inflammation of this structure is called acute appendicitis

*Retrocaecal/retrocolic (75%)*—Right loin pain is often present, with tenderness on examination. Muscular rigidity and tenderness to deep palpation are often absent because of protection from the overlying caecum. The psoas muscle may be irritated in this position, leading to hip flexion and exacerbation of the pain on hip extension (psoas stretch sign)

*Subcaecal and pelvic (20%)*—Suprapubic pain and urinary frequency may predominate. Diarrhoea may be present as a result of irritation of the rectum. Abdominal tenderness may be lacking, but rectal or vaginal tenderness may be present on the right. Microscopic haematuria and leucocytes may be present on urine analysis

*Pre-ileal and post-ileal (5%)*—Signs and symptoms may be lacking. Vomiting may be more prominent, and diarrhoea may result from irritation of the distal ileum

**Box 2: Investigation of acute appendicitis**

- Urine analysis—up to 40% can have abnormalities
- Pregnancy test—to exclude pregnancy
- Full blood count—neutrophil (> 75%) predominant leucocytosis is present in 80-90%
- C reactive protein—raised concentration may be present, but its absence should not exclude a diagnosis of appendicitis

the left iliac fossa causes pain in the right iliac fossa), psoas stretch sign, and the obturator sign.<sup>w4</sup>

**What investigations might help?**

Specialist investigations are rarely needed to confirm a diagnosis of acute appendicitis, and the diagnosis is predominantly a clinical one. No specific diagnostic test for appendicitis exists, but the judicious use of simple urine and blood tests, particularly inflammatory response variables, should allow exclusion of other pathologies and provide additional evidence to support a clinical diagnosis of appendicitis (box 2).<sup>5</sup> Scoring systems and algorithms have been proposed to aid the diagnosis of acute appendicitis but have not been widely used.<sup>w5-w7</sup>

Radiological tests can be used to aid the diagnosis of acute appendicitis. The table describes the role of these investigations, and we consider the use of ultrasonography and computed tomography scanning (fig 1) in more detail below.

One meta-analysis and one systematic review on the role of ultrasonography and computed tomography scanning in the diagnosis of acute appendicitis have concluded that these investigations should be done only in patients in whom a clinical and laboratory diagnosis of appendicitis cannot be made. As ultrasonography studies are operator dependent and need careful examination, these authors also recommend the use of computed tomography in preference to ultrasonography in this group of patients as it has a greater diagnostic accuracy.<sup>7,9</sup>

The impact of the introduction of imaging techniques on the negative appendectomy rate is unclear. A longitudinal study has suggested that despite the introduction of ultrasonography and computed tomography scanning the rates of negative appendectomy have remained unchanged.<sup>10</sup> The moderate diagnostic accuracy of ultrasonography in such studies was stated as a possible reason for this.<sup>7</sup>

confusion. A high index of suspicion for acute appendicitis is needed in such patients.

**Examination**

The patient is often flushed, with a dry tongue and an associated fetor oris. The presence of pyrexia (up to 38°C) with tachycardia is common. Abdominal examination reveals localised tenderness and muscular rigidity after localisation of the pain to the right iliac fossa. Rebound tenderness is present but should not be elicited to avoid distressing the patient. Patients often find that movement exacerbates the pain, and if they are asked to cough the pain will often be localised to the right iliac fossa. The site of maximal tenderness is often said to be over McBurney's point, which lies two thirds of the way along a line drawn from the umbilicus to the anterior superior iliac spine.<sup>6</sup> Findings on per rectal and vaginal examination may be normal, although tenderness to the right may be present particularly in a pelvic appendix. Tenderness on rectal examination may be suggestive but is not diagnostic of appendicitis.<sup>5</sup> Percussion tenderness, guarding, and rebound tenderness are the most reliable clinical findings indicating a diagnosis of acute appendicitis.<sup>5</sup>

Further examination techniques that may aid in the diagnosis of appendicitis are Rovsig's sign (palpation of

**Terminology**

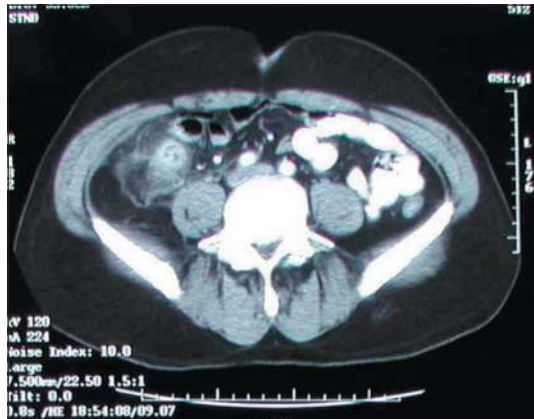*Simple appendicitis*—Inflamed appendix, in the absence of gangrene, perforation, or abscess around the appendix

*Complicated appendicitis*—Perforated or gangrenous appendicitis or the presence of periappendiceal abscess

*Negative appendectomy*—Term used for an operation done for suspected appendicitis, in which the appendix is found to be normal on histological evaluation

**Imaging and diagnosis of acute appendicitis**

Investigation	Diagnostic criteria	Evidence
Plain radiography	None	No role in diagnosis of acute appendicitis, <sup>w6</sup> although in some cases a faecolith may be shown
Ultrasonography	Aperistaltic and non-compressible structure with diameter >6 mm <sup>w6</sup>	Sensitivity of 86%; specificity of 81% <sup>7</sup>
Computed tomography scanning	Abnormal appendix identified or calcified appendicolith seen in association with periappendiceal inflammation or diameter >6 mm <sup>w6</sup>	Sensitivity of 94% and specificity of 95% in diagnosis of acute appendicitis <sup>7</sup>
Magnetic resonance imaging	Not confirmed	Restricted to cases in which radiation and diagnostic difficulties preclude use of other modalities (for example, pregnancy) <sup>8, w9</sup>



**Fig 1** Computed tomography scan showing inflammatory mass in right iliac fossa secondary to acute appendicitis

However, two prospective studies have evaluated the use of computed tomography, and both showed a decrease in the number of unnecessary admissions and appendicectomies.<sup>w10 w11</sup> Importantly, some authors have highlighted the risk of unnecessary exposure to ionising radiation caused by excessive use of computed tomography scans, and low dose protocols have been advocated.<sup>w12</sup>

### Differential diagnosis

The differential diagnosis of appendicitis is that of an acute abdomen (box 3). At the extremes of age, the threshold for referral for further assessment should be low because of the high mortality associated with delayed presentation or diagnosis.

### How do I treat it?

Herbert Fitz was the first author to publish on the need for early diagnosis and surgery for acute appendicitis.<sup>11</sup> Appropriate resuscitation followed by expedient appendicectomy is the treatment of choice. No good evidence exists to support the notion that analgesia should be withheld on the grounds that it may cloud the clinical picture.<sup>12 w13</sup> All patients should receive broad spectrum perioperative antibiotics (one to three doses), as they have been shown to decrease the incidence of postoperative wound infection and intra-abdominal abscess formation.<sup>13</sup>

### Timing of surgery

A recent retrospective study found no significant differences in complications between early (less than 12 hours after presentation) or later (12-24 hours) appendicectomy.<sup>14</sup> This does not, however, take into account the actual time from the onset of symptoms to presentation, which can have a bearing on the rate of perforation.<sup>15</sup> After the first 36 hours from the onset of symptoms the average rate of perforation is between 16% and 36%, and the risk of perforation is 5% for every subsequent 12 hour period.<sup>16 w14</sup> Once a diagnosis is made, appendicectomy should therefore be done without any unnecessary delays.

### Operative procedure

Traditionally, open appendicectomy has been done through a muscle splitting gridiron incision over

McBurney's point made perpendicular to a line joining the umbilicus and anterior superior iliac spine or through a more cosmetically acceptable Lanz's incision. The proportion of open procedures done has fallen with the increased use of laparoscopic techniques. Compared with open surgery, a systematic review found that laparoscopic appendicectomy in adults reduces wound infections, postoperative pain, length of hospital stay, and time taken to return to work, although the number of intra-abdominal abscesses was higher after the laparoscopic approach.<sup>17</sup> However, this view is not shared by a recent study, which found no significant differences between the two procedures except higher quality of life scores at two weeks in the laparoscopic group.<sup>18</sup> In children, laparoscopic appendicectomy reduced the number of wound infections and the length of hospital stay compared with open surgery, but no significant differences in postoperative pain, time to mobilisation, or proportion of intra-abdominal abscesses were seen.<sup>17</sup>

Although in the light of these findings laparoscopic appendicectomy is becoming more common, it is often technically more demanding and requires specialist equipment (fig 2). As a result, the method of approach for appendicectomy is dictated by the level of expertise of the operating surgeon and the facilities available. An added advantage of laparoscopic techniques is the ability to do diagnostic laparoscopy initially, which may show alternative pathology as the cause of the presentation.

#### Box 3: Differential diagnosis of acute appendicitis

##### Surgical

- Intestinal obstruction
- Intussusception
- Acute cholecystitis
- Perforated peptic ulcer
- Mesenteric adenitis
- Meckel's diverticulitis
- Colonic/appendicular diverticulitis
- Pancreatitis
- Rectus sheath haematoma

##### Urological

- Right ureteric colic
- Right pyelonephritis
- Urinary tract infection

##### Gynaecological

- Ectopic pregnancy
- Ruptured ovarian follicle
- Torted ovarian cyst
- Salpingitis/pelvic inflammatory disease

##### Medical

- Gastroenteritis
- Pneumonia
- Terminal ileitis
- Diabetic ketoacidosis
- Preherpetic pain on the right 10th and 11th dorsal nerves
- Porphyria

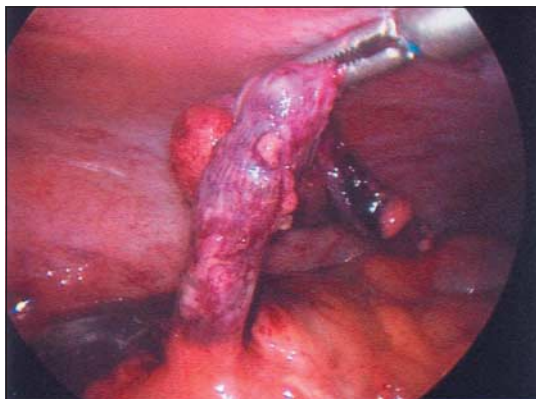


Fig 2 Laparoscopic appendectomy

Spontaneous resolution of early appendicitis can occur, and antibiotics alone can be used to treat appendicitis if no facilities for appendectomy are available.<sup>19 w15</sup> However, a 14-35% readmission rate was associated with antibiotic treatment, and because of the high recurrence rate and relatively low morbidity and mortality associated with appendectomy early operative intervention remains the treatment of choice. This study nevertheless does provide support for the immediate starting of intravenous antibiotics once a diagnosis of appendicitis is made and the patient is waiting for theatre.

### What are the complications?

Appendectomy is a relatively safe procedure with a mortality rate for non-perforated appendicitis of 0.8 per 1000.<sup>20</sup> The mortality and morbidity are related to the stage of disease and increase in cases of perforation; mortality after perforation is 5.1 per 1000.<sup>20</sup> As stated above, the average rate of perforation at presentation is between 16% and 30%,<sup>16 w14</sup> but this is significantly increased in elderly people and young children, in whom the rate can be up to 97%, usually because of a delay in diagnosis.<sup>w4 w16</sup>

The increased mortality and morbidity associated with perforation has been used as justification for high rates of negative appendectomy, quoted as between 20% and 25%.<sup>20</sup> Despite this, complications can occur after removal of a normal appendix, and the surgical community continues to strive to reduce the numbers of negative procedures.<sup>w17-w19</sup> According to a large historical cohort study, a perforated appendix during childhood does not seem to have a long term detrimental effect on subsequent female fertility.<sup>21</sup>

### Wound infection

The rate of postoperative wound infection is determined by the intraoperative wound contamination. Rates of infection vary from <5% in simple appendicitis to 20% in cases with perforation and gangrene. The use of perioperative antibiotics has been

#### Ongoing research

- Characterisation of the causes of the condition
- Adjuvants to the diagnosis of appendicitis

#### Tips for GPs

- History and findings on examination should form the mainstay of diagnosis of appendicitis
- Patients at risk of atypical presentation are those at the extremes of age and pregnant women

shown to decrease the rates of postoperative wound infections.<sup>13</sup>

#### Intra-abdominal abscess

Intra-abdominal or pelvic abscesses may form in the postoperative period after gross contamination of the peritoneal cavity. The patient presents with a swinging pyrexia, and the diagnosis can be confirmed by ultrasonography or computed tomography scanning. Abscesses can be treated radiologically with a pigtail drain, although open or per rectal drainage may be needed for a pelvic abscess. The use of perioperative antibiotics has been shown to decrease the incidence of abscesses.<sup>13</sup>

### Special considerations

#### Pregnancy

The most common non-obstetric emergency needing surgery in pregnancy is appendicitis, with an incidence of 0.15 to 2.10 per 1000 pregnancies.<sup>22</sup> Previous studies have suggested an equal incidence in pregnant and non-pregnant women, but a recent large scale case-control study has suggested a reduction in the incidence of appendicitis during pregnancy, particularly during the third trimester.<sup>23</sup>

Displacement of the appendix by the gravid uterus means that the presentation is often atypical or may be mistaken for the onset of labour. Nausea and vomiting are often present, with associated tenderness located anywhere on the right hand side of the abdomen.

Maternal mortality is negligible in cases of simple appendicitis but rises to 4% with advanced gestation and perforation. Fetal mortality ranges from 0-1.5% in

#### Additional educational resources

Sauerland S, Lefering R, Neugebauer EA. Laparoscopic versus open surgery for suspected appendicitis. *Cochrane Database Syst Rev* 2004;(4):CD001546

Simpson J, Speake W. Appendicitis. *Clin Evid* 2005;31:529-35

#### Information for patients

NHS Direct ([www.nhsdirect.nhs.uk/en.aspx?articleId=31&sectionId=5579](http://www.nhsdirect.nhs.uk/en.aspx?articleId=31&sectionId=5579))—Very informative summary that provides links to access health care

Prodigy Knowledge ([www.prodigy.nhs.uk/ProdigyKnowledge/PatientInformation/Content/pils/PL437.htm](http://www.prodigy.nhs.uk/ProdigyKnowledge/PatientInformation/Content/pils/PL437.htm))—Good patient information leaflet offering a brief summary of the condition

National Digestive Diseases Information Clearinghouse ([digestive.niddk.nih.gov/ddiseases/pubs/appendicitis/index.htm](http://digestive.niddk.nih.gov/ddiseases/pubs/appendicitis/index.htm))—American site with a more comprehensive patient focused explanation of the condition

### A patient's perspective

I am a 20 year old student at the University of Nottingham. In March this year I had appendicitis. I had been having stomach pains for a week before I sought medical help. The pains were vague, and the night before I was admitted to hospital they woke me from my sleep and became more prominent on the right lower side. For the entire week I had felt feverish and had been off my food. I had not noticed any other symptoms, and nothing had relieved the pain (not even beer!).

I went to my general practitioner, who promptly diagnosed appendicitis. On admission to hospital I was in considerable pain with a mild fever. The surgical team told me that I needed an operation. I was relieved that a diagnosis had been made and a treatment was available. I had a little discomfort from my scar after the operation and some vomiting, but within two days I was eating and drinking again.

Following my operation the pain resolved, and I am looking forward to returning to my studies.

(Account of a patient with appendicitis who was admitted under the general surgical take at Queen's Medical Centre, Nottingham)

cases of simple appendicitis to 20-35% in cases of perforation.<sup>22</sup>

### Appendix mass

In patients with a delayed presentation, a tender mass with overlying muscle rigidity may be felt in the right iliac fossa. The presence of a mass may be confirmed on ultrasonography or computed tomography scan; underlying neoplasia must be excluded, especially in elderly people. The initial treatment in a patient who is otherwise well is conservative, with initiation of appropriate resuscitation and intravenous broad spectrum antibiotics. In most cases the mass will decrease in size over the subsequent days as the inflammation resolves, although patients need careful observation to detect early signs of progress of the inflammatory process. As appendicitis can recur, management after resolution of the mass is usually an interval appendectomy; a conservative approach with outpatient follow-up has been suggested, but no definitive evidence exists to support this.<sup>w20</sup>

### Appendix abscess

Patients with an appendix abscess have a tender mass with a swinging pyrexia, tachycardia, and leucocytosis. The abscess is most often located in the lateral aspect of the right iliac fossa but may be pelvic; a rectal examination is useful to identify a pelvic collection. The abscess can be shown by ultrasonography or computed tomography scanning, and a percutaneous radiological drainage may be done. Open drainage has the added advantage of allowing an appendectomy to be done.<sup>w20</sup>

### Chronic (recurrent) appendicitis

Recently, with the advent of neurogastroenterology, the concept of neuroimmune appendicitis has evolved. After a previous minor bout of intestinal inflammation, subtle alterations in enteric neurotransmitters are seen, which may result in altered visceral perception from the gut; this process has been implicated in a wide range of gastrointestinal conditions.<sup>w21</sup> Further work is

needed to determine if the clinical entity of "neuro-immune appendicitis" truly exists, but it remains an interesting area.<sup>w22</sup>

### Inflammatory bowel disease

A history of appendectomy is associated with delayed onset of disease and a less severe disease phenotype in patients with ulcerative colitis.<sup>24 w23 w24</sup> The influence of appendectomy in Crohn's disease is not as clear; some evidence suggests a delayed onset of disease in patients after appendectomy,<sup>w23 w25</sup> although contradictory evidence also exists to suggest an increased risk of developing the condition depending on the patient's age, sex, and diagnosis at the time of operation.<sup>25</sup>

Contributors: Both authors reviewed the literature and wrote the article.

Competing interests: None declared.

- Larner AJ. The aetiology of appendicitis. *Br J Hosp Med* 1988;39:540-2.
- Hospital Episode Statistics. Primary diagnosis: summary. [www.hesonline.nhs.uk/Ease/servlet/ContentServer?siteID=1937&categoryID=202](http://www.hesonline.nhs.uk/Ease/servlet/ContentServer?siteID=1937&categoryID=202) (accessed 28 Aug 2006).
- Addiss DG, Shaffer N, Fowler BS, Tauxe RV. The epidemiology of appendicitis and appendectomy in the United States. *Am J Epidemiol* 1990;132:910-25.
- Murphy J. Two thousand operations for appendicitis, with deductions from his personal experience. *Am J Med Sci* 1904;128:187-211.
- Andersson R. Meta-analysis of the clinical and laboratory diagnosis of appendicitis. *Br J Surg* 2004;91:28-37.
- McBurney C. Experiences with early operative interference in cases of diseases of the vermiform appendix. *N Y Med J* 1889;50:676-84.
- Terasawa T, Blackmore CC, Bent S, Kohlwees RJ. Systematic review: computed tomography and ultrasonography to detect acute appendicitis in adults and adolescents. *Ann Intern Med* 2004;141:537-46.
- Cobben LP, Groot I, Haans L, Blickman JG, Puylaert J. MRI for clinically suspected appendicitis during pregnancy. *Am J Roentgenol* 2004;183:671-5.
- Weston A, Jackson T, Blamey S. Diagnosis of appendicitis in adults by ultrasonography or computed tomography: a systematic review and meta-analysis. *Int J Technol Assess Health Care* 2005;21:368-79.
- Flum DR, McClure TD, Morris A, Koepsell T. Misdiagnosis of appendicitis and the use of diagnostic imaging. *J Am Coll Surg* 2005;201:933.
- Fitz R. Perforating inflammation of the vermiform appendix, with special reference to its early diagnosis and treatment. *Trans Assoc Am Physicians* 1886;1:107-44.
- Thomas SH, Silen W. Effect on diagnostic efficiency of analgesia for undifferentiated abdominal pain. *Br J Surg* 2003;90:5-9.
- Andersen BR, Kallehave FL, Andersen HK. Antibiotics versus placebo for prevention of postoperative infection after appendectomy. *Cochrane Database Syst Rev* 2005;(3):CD001439.
- Abou-Nukta F, Bakhos C, Arroyo K, Koo Y, Martin J, Reinhold R, et al. Effects of delaying appendectomy for acute appendicitis for 12 to 24 hours. *Arch Surg* 2006;141:504-7.
- Temple CL, Huchcroft SA, Temple WJ. The natural history of appendicitis in adults: a prospective study. *Ann Surg* 1995;221:278-81.
- Bickell NA, Aufses JAH, Rojas M, Bodian C. How time affects the risk of rupture in appendicitis. *J Am Coll Surg* 2006;202:401-6.
- Sauerland S, Lefering R, Neugebauer EA. Laparoscopic versus open surgery for suspected appendicitis. *Cochrane Database Syst Rev* 2004;(4):CD001546.
- Kathouda N, Mason RJ, Towfigh S, Gevorgyan A, Essani R. Laparoscopic versus open appendectomy: a prospective randomized double-blind study. *Ann Surg* 2005;242:439-48, discussion 448-50.
- Styrud J, Eriksson S, Nilsson I, Ahlberg G, Haapaniemi S, Neovius G, et al. Appendectomy versus antibiotic treatment in acute appendicitis: a prospective multicenter randomized controlled trial. *World J Surg* 2006;30:1033.
- Blomqvist PG, Andersson RE, Granath F, Lambe MP, Ekblom AR. Mortality after appendectomy in Sweden, 1987-1996. *Ann Surg* 2001;233:455-60.
- Andersson R, Lambe M, Bergstrom R. Fertility patterns after appendectomy: historical cohort study. *BMJ* 1999;318:963-7.
- Guttman R, Goldman RD, Koren G. Appendicitis during pregnancy. *Can Fam Physician* 2004;50:355-7.
- Andersson REB, Lambe M. Incidence of appendicitis during pregnancy. *Int J Epidemiol* 2001;30:1281-5.
- Andersson RE, Olaison G, Tysk C, Ekblom A. Appendectomy and protection against ulcerative colitis. *N Engl J Med* 2001;344:808-14.
- Andersson RE, Olaison G, Tysk C, Ekblom A. Appendectomy is followed by increased risk of Crohn's disease. *Gastroenterology* 2003;124:40.

(Accepted 7 August 2006)

doi 10.1136/bmj.38940.664363.AE