

Case Report

Open Access

Unusual presentation of choriocarcinoma

PG Balagopal*¹, Manoj Pandey¹, K Chandramohan¹, Thara Somanathan²
and Ashwin Kumar³

Address: ¹Department of Surgical Oncology, Regional Cancer Centre, Thiruvananthapuram, Kerala, India, ²Department of Pathology, Regional Cancer Centre, Thiruvananthapuram, Kerala, India and ³Department of Radiation Oncology, Regional Cancer Centre, Thiruvananthapuram, Kerala, India

Email: PG Balagopal* - drbalagopal@yahoo.com; Manoj Pandey - cytology@rcctvm.org; K Chandramohan - cm@vsnl.com; Thara Somanathan - manojpandey@rcctvm.org; Ashwin Kumar - rcctvm@md2.vsnl.net.in

* Corresponding author

Published: 17 April 2003

Received: 5 February 2003

World Journal of Surgical Oncology 2003, 1:4

Accepted: 17 April 2003

This article is available from: <http://www.wjso.com/content/1/1/4>

© 2003 Balagopal et al; licensee BioMed Central Ltd. This is an Open Access article: verbatim copying and redistribution of this article are permitted in all media for any purpose, provided this notice is preserved along with the article's original URL.

Abstract

Background: Choriocarcinoma is an aggressive neoplasm arising in the body of the uterus. The disease normally spreads to lung and brain.

Case Report: A case of malignant trophoblastic disease with brain metastasis, raised intra cranial pressure and small bowel metastasis presenting with acute abdomen is reported.

Conclusions: Malignant transformation in a hydatidiform mole is rare event. Involvement of gastrointestinal tract is rarer even in presence of disseminated disease. Surgery is the treatment of choice for gastrointestinal complications.

Background

Trophoblastic diseases comprise a variety of biologically interrelated conditions which form a clinical spectrum consisting of four distinct clinical pathological entities like (1) molar pregnancy (2) invasive mole (3) placental site trophoblastic tumours and (4) choriocarcinoma [1].

Incidence of hydatidiform mole ranges from 1 in 500 in India to 1 in 3000 in USA. Like wise malignant potential of the disease is also higher in Southeast Asia reaching as high as 10–15% compared to 2–4% in west. Some of the hydatidiform moles erode the wall of uterus, burrow into myometrium and may even burst through the uterus into peritoneum and are called invasive mole. Even though locally aggressive, invasive mole does not metastasise. On the other hand choriocarcinoma is rare but one of the most malignant neoplasms arising in the body of uterus. choriocarcinoma metastasises readily. It is not uncommon to find secondary nodules in the cervix or vagina.

The lungs, brain and liver are the distant organs more often involved. Lymph nodes are rarely the site of metastasis [2]. We report here a case of hydatidiform mole metastasising to brain and later presenting with intestinal metastasis and perforation.

Case Report

A twenty-four-year old housewife underwent dilatation and curettage for vaginal bleeding in 1994. Pathological examination of curettage specimen showed hydatidiform mole. She later conceived and had two normal deliveries. She remained asymptomatic for eight years. In January 2002 she was brought to medical causality with features suggestive of raised intra cranial pressure. A computerised tomographic scan of the brain was taken which revealed brain metastasis (figure 1) and the patient was referred to our centre. After admission she was treated with six cycles of chemotherapy consisting of etoposide, methotrexate, actinomycin-D, cyclophosphamide and Vincristine

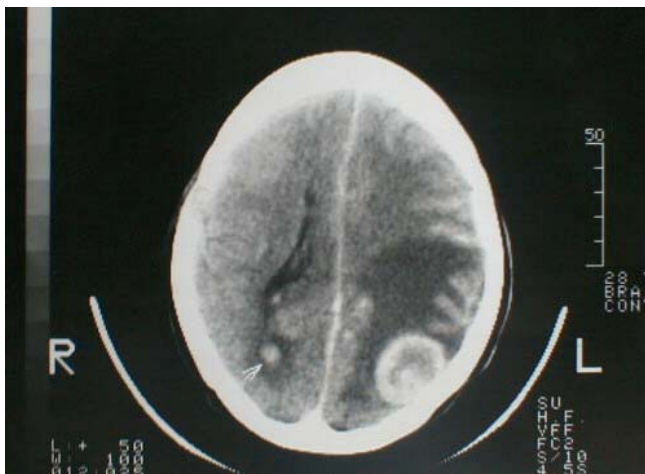

Figure 1
Computerized tomographic scan of the brain showing meta-
static lesion.

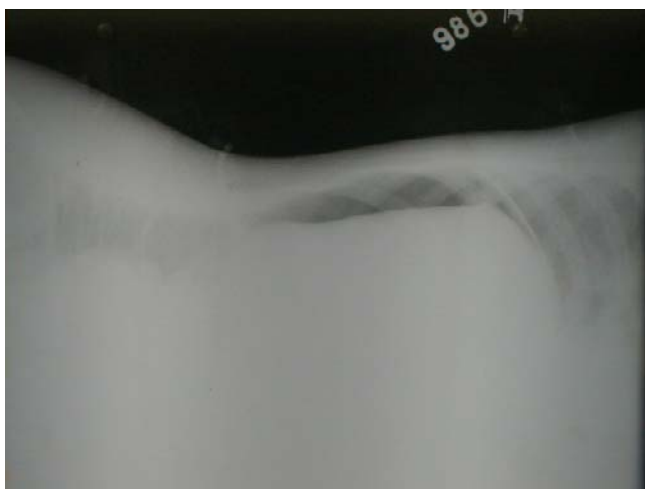


Figure 2
Left Lateral decubitus x-ray of the abdomen showing free
gas above the liver.

(EMA-CO regime). Ten days after completion of chemo-
therapy she developed abdomen pain and vomiting.

On examination she was febrile, with mild abdominal
distension and rebound tenderness was present. A plain
X-ray abdomen in left lateral decubitus posture showed
free gas above the liver (figure 2). X-ray chest was taken
which showed metastatic lesions in the lung. With diag-

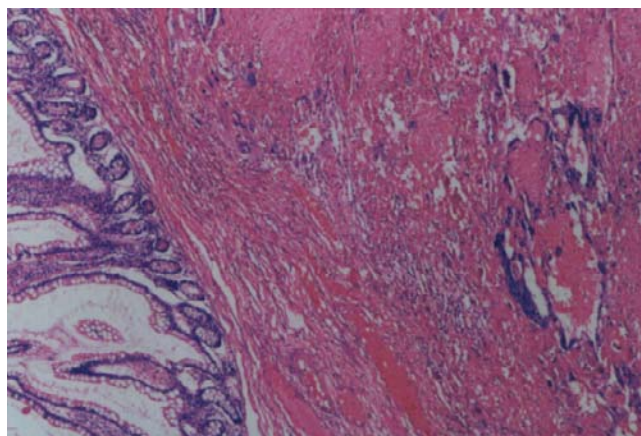


Figure 3
Sheets of neoplastic cells in a haemorrhagic background infil-
trating the wall of the intestine (H&E × 50).

nosis of perforative peritonitis the patient was taken up
for emergency laparotomy.

At laparotomy the stomach and duodenum were found to
be normal. A 1 × 1 cm perforation was found in the jeju-
num, 10 cm distal to the duodenojejunal junction. Another
area of impending perforation was found 5 cm distal to
the site of perforation. Multiple metastatic nodules were
noted on the serosal surface of the small intestine, colon,
and bowel mesentery. A 3 × 4 cm metastatic nodule was
present on the superior surface of right lobe of liver. Resec-
tion of the perforated segment of jejunum and end to end
anastomosis was carried out.

On gross examination the resected small intestine meas-
ured 14 cm in length. A small perforation measuring 1 ×
0.8 cm was seen on the serosa 6 cm from one of the resec-
ted ends. Adjacent to the perforation the serosa showed
two nodules, each measuring 1 × 1 cm. On opening the
intestine, multiple small mucosal nodules were noted.
The cut surface of the serosal nodules were haemorrhagic
and grey white. Similar nodules were seen involving the
full thickness of the intestinal wall.

Microscopic examination showed multiple nodules of a
neoplasm involving the mucosa, submucosa, muscle and
serosa of the small intestine (fig 3,4,5). Cytotrophoblasts
having eosinophilic cytoplasm and round, vesicular
nuclei with nucleoli were seen admixed with syncytiotro-
phoblasts, in a haemorrhagic background (fig 6). The me-
senteric fat showed tumour infiltration with a vascular
tumour emboli. These findings were consistent with met-
astatic choriocarcinoma.

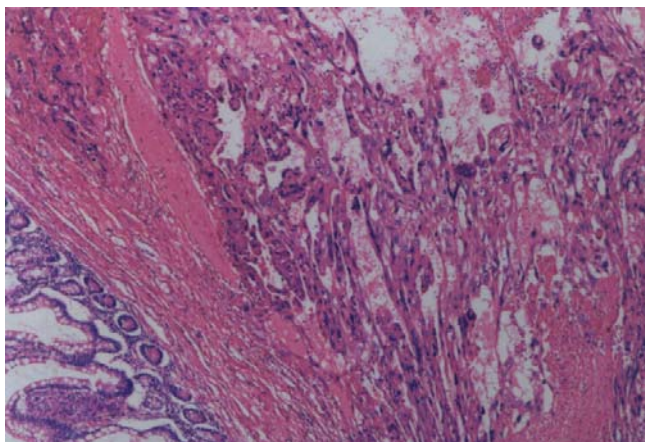


Figure 4
Neoplastic cells in a haemorrhagic background infiltrating the intestine (H&E x 50).

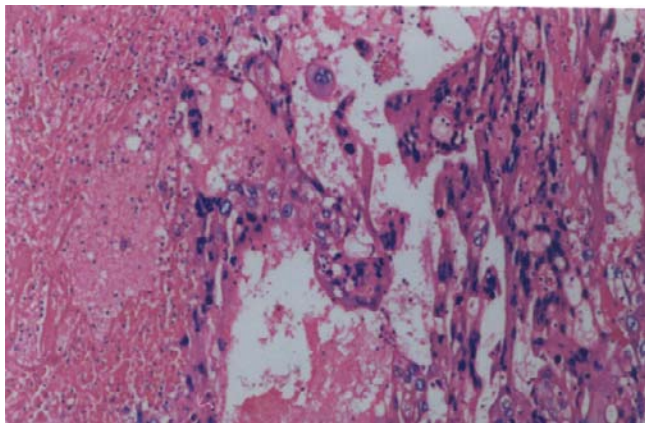


Figure 5
Higher magnification showing two population of cells in a haemorrhagic background (H&E x 100).

Postoperative period was uneventful. Patient was discharged on tenth day. As she was not responding to EMA-CO, she was switched over to BEP regimen (Bleomycin, Etoposide, and Prednisolone). She received eight cycles of BEP. Her β HCG fell to 12000 IU but then started to rise again to reach 20,000 IU, patient discontinued the chemotherapy at this stage and was lost to follow-up.

Discussion

Gestational trophoblastic disease most commonly follows molar pregnancy and may also occur following normal or ectopic pregnancies and spontaneous or

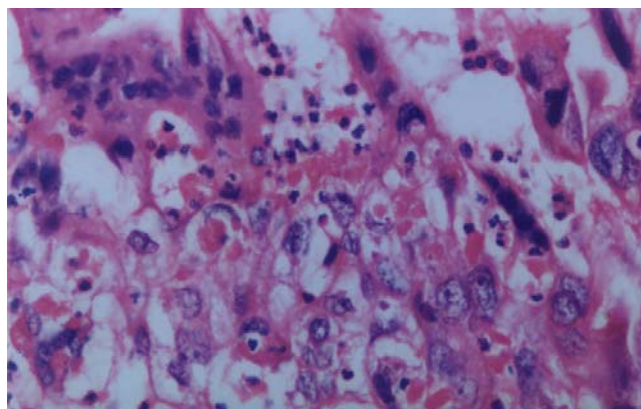


Figure 6
Cytotrophoblasts having eosinophilic cytoplasm, and vesicular nuclei admixed with syncytiotrophoblasts having single and multiple hyperchromatic nuclei (H&E x 400)

therapeutic abortions. Its incidence varies with figures as high as 1 in 120 pregnancies in some areas of Asia and South America, compared to 1 in 1200 in United States. Metastatic disease occurs in 4% patients after local management of Hydatidiform mole. The incidence of choriocarcinoma after complete hydatidiform mole is about 1000 times greater than after a normal pregnancy [2]. It may occur possibly *ab initio* [3]. Choriocarcinoma is a rare tumour. In western countries, the incidence is 1 in 45,000 pregnancies [4]. Higher incidence is reported from, Africa, Asia and South America [4]. Majority of cases occur in women aged less than 35 years of age [4].

Choriocarcinoma is suspected when there is persistent or irregular uterine haemorrhage, following abortion or hydatidiform mole. Rapid growth and haemorrhage make the tumour a medical emergency. Metastasis may occur in lung, pelvis and vagina. Rare sites include gastrointestinal tract, spleen, and kidney. The central nervous system is seldom involved in the absence of pulmonary metastasis [1]. Metastatic disease occurs in 4% of patients after local management of hydatidiform mole and very rarely after term pregnancies or abortions [1]. Some times they may be combined with malignant germ cells components, occasionally it may be difficult to differentiate a primary tumour from a metastasis. For females in non reproductive age group, the tumours may arise from ovarian germ cells which is histologically similar to gestational uterine choriocarcinoma [4].

Chemotherapy is highly effective for all forms of gestational trophoblastic disease. For stage I disease hysterectomy and single agent chemotherapy is effective. For

advanced diseases salvage regimes are available for management.

Malignant transformation in a hydatidiform mole is rare event. There are reports describing metastasis to large intestine from choriocarcinoma presenting as pseudoobstruction [5] and metastasis to stomach [6]. Metastasis to gastrointestinal tract and presentation as perforation of small intestine is very rare. The case is being reported for its rarity.

References

1. Muggia FM, Eifel PJ and Burke TW **Gestational trophoblastic diseases** In *Cancer Principles and Practice of Oncology* (Edited by: de Vita VJ Jr, Hellman S, Rosenberg SA) Lippincott-Raven, Philadelphia 1997, 1427-1539
2. Paradinas FJ **Pathology and classification of trophoblastic tumours** *Gynaecologic Oncology* (Edited by: Coppleson M) Churchill Livingstone, London 1992, 2:1013-1026
3. Acosta-Sison H **Ab initio choriocarcinoma: two unusual cases** *Obstet Gynaecol N Y* 1959, 13:350-352
4. Fox H and Buckley CH **The female genital tract and ovaries** In. *Oxford text Book of Pathology* (Edited by: McGee JOD, Isaacson PG, Wright NA) Oxford university press, New York 1992, 2a:1565-1639
5. Bandy LC, Clarke-Pearson DC and Hamment CB **Pseudoobstruction of the colon complicating choricocarcinoma** *Gynaecol Oncol* 1985, 20:402-407
6. Galloway SW, Yeung EC, Lan JY and Chung SC **Laparoscopic Gastric resection for bleeding meastatic choriocarcinoma** *Surg Endosc* 2001, 15:100

Publish with **BioMed Central** and every scientist can read your work free of charge

"BioMed Central will be the most significant development for disseminating the results of biomedical research in our lifetime."

Sir Paul Nurse, Cancer Research UK

Your research papers will be:

- available free of charge to the entire biomedical community
- peer reviewed and published immediately upon acceptance
- cited in PubMed and archived on PubMed Central
- yours — you keep the copyright

Submit your manuscript here:
http://www.biomedcentral.com/info/publishing_adv.asp

