

Effect of Neonatal Exposure to Estrogenic Compounds on Development of the Excurrent Ducts of the Rat Testis through Puberty to Adulthood

Jane S. Fisher,¹ Katie J. Turner,¹ Dennis Brown,² and Richard M. Sharpe¹

¹Medical Research Council Reproductive Biology Unit, Centre for Reproductive Biology, Edinburgh, Scotland EH3 9EW; ²Renal Unit, Massachusetts General Hospital, Charlestown, MA 02129 USA

Neonatal exposure to diethylstilbestrol (DES) can alter the structure of the testicular excurrent ducts in rats. We characterized these changes according to dose and time posttreatment and established whether potent estrogens (ethinyl estradiol), environmental estrogens (genistein, octylphenol, bisphenol A, parabens), and tamoxifen induce such changes. Rats were administered these compounds neonatally and assessed at several time points during (day 10, or day 18 for some treatments) and after (days 18, 25, 35, and 75) the treatment period to detect any changes in testis weight, distension of the rete testis and efferent ducts, epithelial cell height in the efferent ducts, and immunexpression of the water channel aquaporin-1 (AQP-1). Treatment with DES (10, 1, or 0.1 µg/injection; equivalent to 0.37, 0.037, or 0.0037 mg/kg/day, respectively) induced dose-dependent changes in testis weight and all parameters. These effects were most pronounced at days 18 and 25 and appeared to lessen with time, although some persisted into adulthood. Neonatal treatment with ethinyl estradiol (10 µg/injection; equivalent to 0.37 mg/kg/day) caused changes broadly similar to those induced by 10 µg DES. Administration of tamoxifen (2 mg/kg/day) caused changes at 18 days that were similar to those induced by 1 µg DES. Treatment with genistein (4 mg/kg/day), octylphenol (2 mg/injection; equivalent to 150 mg/kg/day), or bisphenol A (0.5 mg/injection; equivalent to 37 mg/kg/day) caused minor but significant ($p < 0.05$) decreases in epithelial cell height of the efferent ducts at days 18 and/or 25. In animals that were followed through to 35 days and/or adulthood, these changes were no longer obvious; other parameters were either unaffected or were affected only marginally and transiently. Administration of parabens (2 mg/kg/day) had no detectable effect on any parameter at day 18. To establish whether these effects of estrogens were direct or indirect (i.e., resulting from reduced follicle-stimulating hormone/luteinizing hormone secretion), the above end points were assessed in animals in which gonadotropin secretion was suppressed neonatally by administration of a gonadotropin-releasing hormone antagonist. This treatment permanently reduced testis weight, but did not affect any of the other end points, apart from a minor transient reduction in efferent duct epithelial cell height at 18 days. This study suggests that structural and functional (expression of AQP-1) development of the excurrent ducts is susceptible to impairment by neonatal estrogen exposure, probably as a consequence of direct effects. The magnitude and duration of adverse changes induced by treatment with a range of estrogenic compounds was broadly comparable to their estrogenic potencies reported from *in vitro* assays. **Key words:** aquaporin-1, bisphenol A, diethylstilbestrol, efferent ducts, ethinyl estradiol, genistein, octylphenol, rete testis, tamoxifen. *Environ Health Perspect* 107:397–405 (1999). [Online 6 April 1999] <http://ehpnet1.niehs.nih.gov/docs/1999/107p397-405fisher/abstract.html>

Estrogen, the classical female hormone, is now being investigated to determine its function in male fertility. This has become an increasingly important issue over the past 5 years because data suggest that there has been a progressive increase in disorders of male reproductive development and there is concern as to whether compounds in the environment could have contributed to these adverse changes. Studies have suggested that human sperm counts have declined in some countries according to later year of birth (1–4) and that the incidence of testicular cancer and some congenital abnormalities (hypospadias and cryptorchidism) have increased in many countries over the same time period (5–9). These changes coincide with major changes in lifestyle and with the mass production of synthetic chemicals

involved in the production of industrial and domestic commodities (such as pesticides and plastics), some of the ingredients of which have been shown to be weakly estrogenic (xenoestrogens) (10–16). As perinatal exposure of male animals and humans to synthetic estrogens can induce similar adverse changes in male reproductive health, it has been hypothesized that inappropriate exposure to estrogens (from inside or outside the body) during critical periods of development may interfere with mechanisms involved in the development of the reproductive system and in determining sperm numbers (17).

A major obstacle to tackling this issue and defining whether environmental hormone disruptors pose a risk to male reproductive health is the lack of relevant

estrogen-regulated end points within the male reproductive system. Recent studies, however, have highlighted the regions of the male reproductive tract that appear to be important sites of estrogen action. One such site is the efferent ducts that join the testis to the initial segment of the epididymis. The efferent ducts comprise a simple epithelium that is composed largely of two cell types (ciliated and nonciliated cells), which normally display a highly columnar appearance. Studies have shown that the efferent ducts express both forms of the estrogen receptor (ER- α and ER- β) (18) and that this region is an important site for the resorption of fluid which enters the efferent ducts along with spermatozoa from the rete testis. This fluid resorption is impaired in transgenic animals lacking a functional ER α receptor, suggesting that estrogens may play a role in fluid resorption (19).

The lack of relevant estrogen-regulated end points within the male reproductive tract prompted us to assess estrogen exposure using parameters that we have previously identified as being altered after neonatal administration of a high dose (10 µg/injection) of diethylstilbestrol (DES). Exposure to DES induces gross morphological alterations to the rete testis and efferent ducts (20). The rete testis becomes grossly enlarged and distended with the distension persisting throughout the efferent ducts. The epithelial cells of the efferent ducts decrease in height coincident with reduced expression of the water channel protein aquaporin-1 (AQP-1), which is normally located on the brush border of nonciliated cells. In the present study, we aimed to assess the effects of neonatal exposure to estrogens and estrogenic compounds in a more definitive manner by examining both dose- and time-dependent responses to neonatal administration of various doses of DES and comparing these to neonatal treatment with ethinyl estradiol and

Address correspondence to J.S. Fisher, Medical Research Council Reproductive Biology Unit, Centre for Reproductive Biology, 37 Chalmers Street, Edinburgh, Scotland, EH3 9EW.

We are grateful to Shelia Macpherson, Michelle Morley, and Stacey Reid for their technical assistance. This work was supported in part by the European Centre for Ecotoxicology of Chemicals and by Zeneca.

Received 30 November 1998; accepted 18 February 1999.

the estrogen receptor antagonist/agonist tamoxifen. To determine whether these are reliable end points with which to assess exposure to environmental estrogens, we examined the excurrent ducts of animals treated neonatally with some weakly estrogenic chemicals (octylphenol, bisphenol A, parabens) at concentrations approaching their maximum solubility in oil, and the phytoestrogen genistein at levels equivalent to total phytoestrogen intake by human infants consuming soy formula. For most of these chemicals, attention was focused on postnatal day 18, as this was the age when the most pronounced effects were observed in animals treated neonatally with DES.

Materials and Methods

Animals. Wistar rats bred in our own animal facility were maintained under standard conditions. Neonatal rats were subjected to subcutaneous injection with one of the treatments described below. All compounds other than genistein and gonadotropin-releasing hormone antagonist (GnRHa) were administered in corn oil to provide a subcutaneous depot that would ensure continuous exposure to the test compound throughout the day. Some treatments were administered on a kilogram per day basis, whereas others were administered in a constant dose/volume per injection. For the latter treatments, an approximate intake in milligrams per kilograms per day has been indicated based on the average weight and age for animals during the treatment period (i.e., 2–12 days of age). However, this value is only an average; also, in neonates 2–6 days of age, not all of the oil (and presumably, test compound) is absorbed from the injection site between consecutive injections.

Treatments. DES (Sigma, Poole, Dorset, UK) was administered at either 10, 1, or 0.1 µg in 20 µl corn oil on postnatal days 2, 4, 6, 8, 10, and 12 (day of birth = day 1), giving doses of approximately 0.37, 0.037, and 0.0037 mg/kg/day, respectively. GnRHa (Antarelix; Europeptides, Argenteuil, France), 10 mg/kg in 20 µl 5% mannitol, was administered on postnatal days 2 and 5. Ethinyl estradiol (Sigma) was given at 10 µg in 20 µl corn oil on postnatal days 2, 4, 6, 8, 10, and 12, equivalent to approximately 0.37 mg/kg/day. Bisphenol A (Aldrich Chemicals Limited, Dorset, UK) was administered at 0.5 mg in 20 µl corn oil on days 2–12 inclusive, equivalent to 37 mg/kg/day. Octylphenol (Aldrich), 2 mg in 20 µl corn oil, was given on days 2–12 inclusive, equivalent to 150 mg/kg. Butyl-parabens (a gift from John Ashby, Zeneca CTL, Macclesfield, Cheshire, UK) was injected at ~2 mg/kg/day in 2 ml/kg corn oil on days 2–18 inclusive; animals that were

sampled on day 18 were killed 4 hr after their daily injection.

Genistein (Sigma) was administered at ~4 mg/kg/day in 2 ml/kg vehicle [phosphate-buffered saline (PBS) + 2.5 mg/ml gelatin]. Genistein was first dissolved in 0.4M KOH and diluted 1:20 with PBS to give a dosing concentration of 800 µg/ml. The mothers of rats treated neonatally with genistein and their respective controls (treated with the appropriate vehicle) were fed on a casein-based, soy-free diet (B.S. & S., Edinburgh, Scotland). Rats killed on days 10 and 18, while they were still on treatment, were killed 4 hr after their daily injection. Tamoxifen (Sigma) was administered at ~2 mg/kg in 20 µl corn oil on days 2–16 inclusive. Controls for all of the treatments were injected with the equivalent volume of vehicle.

The selection of doses for the above compounds was based on the following considerations. The highest DES dose was based on our previous studies (20,21), and the single dose of ethinyl estradiol tested was selected to be equivalent to this DES dose. The dose and treatment regimen for GnRHa was based on previous studies (21,22) that showed complete suppression of follicle-stimulating hormone (FSH) levels through to day 18. The doses of bisphenol A and octylphenol were based on maximum solubility of the compounds in oil, and the dose of butyl-parabens was based on recent studies of its effects *in vivo* on uterine weight in the rat (10). The dose of genistein was based on figures calculated by Setchell et al. (23) that show the total isoflavanoid intake by human infants fed on a 100% soy formula milk diet.

Tissue fixation. Animals from control, bisphenol A-, and DES- (10 µg) treated groups were killed at 10, 18, 25, 35, and 75 days of age. Rats treated neonatally with GnRHa or lower doses of DES (1 or 0.1 µg) were sampled at days 18, 25, 35, and 75. Genistein-treated rats were killed at 10, 18, 25, and 75 days of age. Rats treated with ethinyl estradiol were sampled at 18, 25, and 75 days of age, whereas rats administered butyl-parabens or tamoxifen and their respective controls were all killed at just one time-point, 18 days of age.

Animals 10–25 days of age were killed by inhalation of carbon dioxide or halothane and subsequent cervical dislocation. In animals up to 25 days of age, the testes and epididymides were removed together and immersion fixed in Bouin's fixative for 5.5 hr at room temperature before being transferred into 70% ethanol. After 35 days of age, rats were anesthetized with halothane and perfusion fixed via the thoracic aorta with 0.9% saline containing

0.01% heparin until the testicular blood vessels cleared; tissues were then fixed with Bouin's fixative for 30 min, as described previously (24). Each testis and epididymis were then dissected apart to leave the efferent ducts attached to the testis. After being postfixed for a further 5.5 hr in Bouin's fixative, these tissues were then transferred into 70% ethanol. One testis from each animal was weighed. In animals under 35 days of age, the fresh weight was recorded, whereas weights in animals 35 or 75 days of age were recorded after perfusion fixation. Fixation in Bouin's fixative causes negligible tissue shrinkage, and data for fixed and unfixed testis weights from similarly treated animals do not differ significantly. Therefore, data for unfixed and fixed testis weights can be compared directly.

Tissue processing. Fixed tissue was processed for 17.5 hr in an automated Leica Tp-1050 processor (Leica UK Limited, Milton Keynes, UK) and embedded in paraffin wax. Sections were cut at 5 µm and floated onto coated slides (2% 3-aminopropyltriethoxy-saline; Sigma) and dried at 50°C overnight before immunocytochemistry was performed.

Immunocytochemistry. Immunolocalization of AQP-1 was determined using a polyclonal antibody raised to human erythrocyte AQP-1, the validation of which is described elsewhere (20,25). The antibody and preimmune serum were used at a dilution of 1:500. Slide-mounted sections were dewaxed in Histoclear (National Diagnostics, Fleet Business Park, Hull, UK), rehydrated through a graded series of ethanol, and washed in distilled water. To block endogenous peroxidase activity, the sections were pretreated with 3% hydrogen peroxide in methanol. Nonspecific binding sites were blocked by incubating the sections in normal swine serum (NSS) diluted 1:5 in Tris-buffered saline (TBS, pH 7.4, containing 50mM Tris-HCl, 150 mM NaCl). The immune and preimmune sera were diluted in the NSS block and 100 µl was added to each slide, which was then coverslipped and incubated overnight in a light-proof box at 4°C. After removing the coverslips, the slides were washed in TBS (two times at 5 min each) and then incubated with a linking antibody, biotinylated swine-antirabbit serum (DAKO Ltd., Cambridge, UK; diluted 1:500 in NSS) for 30 min. After two washes in TBS, avidin-biotin conjugated horseradish peroxidase (DAKO) was applied to the slides for 30 min. The slides were given two final rinses in TBS before the addition of a diaminobenzidine (DAB)-based chromogen, which left a brown precipitate at the sites of antibody localization. The slides

were developed until the color on control sections reached the required intensity before the reaction was stopped by immersing the slides in distilled water. The slides were then counterstained with hematoxylin, dehydrated by immersion in a graded series of ethanol, and cleared in xylene. A coverslip was fixed over the sections using Pertex mounting medium (Cell Path, Hemel Hempstead, UK).

Evaluation of immunostaining. Slides were examined and photographed using an Olympus Provis microscope (Olympus Optical, London, UK) fitted with a Kodak DCS420 camera (Eastman Kodak, Rochester, NY). Captured images were stored on an 8100 PowerPC computer (Apple Macintosh, Apple Computer, Cupertino, CA) and compiled using Photoshop 3.0 (Adobe Systems Inc., Mountain View, CA) before being printed using a Kodak XLS 8600 PS printer (Eastman Kodak). To enable accurate comparison of immunostaining between treated and control animals, immunocytochemistry was performed with sections from control and treated animals side by side on the same slide; thus, each control section acted as an internal control to compare the intensity of immunostaining. Tissue from at least three animals at each age and treatment were evaluated on at least three occasions to ensure the reproducibility of the results.

Rete testis and efferent duct morphology. Tissue sections were prepared as described above and were stained with hematoxylin and eosin. Sections were then viewed under a light microscope to examine the morphology of the efferent ducts and rete testis. Slides were used for analysis of epithelial cell height in the efferent ducts or, where a good cross section of the rete testis had been obtained, the slide was photographed using the system described above. To ensure consistency regarding the cross-section of the rete testis that was photographed, slides were chosen if the region of the rete testis which joins the efferent ducts could be viewed in the plane of section.

Efferent duct epithelial cell height. Our previous study (20) demonstrated that neonatal treatment with 10 µg DES altered the shape and height of epithelial cells in the efferent ducts. To evaluate whether similar changes were induced by the present treatments, cross-sections of efferent ducts were evaluated using image analysis from 3–20 rats from the control and treated cohorts at all time points collected. The height of the efferent duct epithelium was measured using an Olympus BH2 microscope fitted with a 40× plan achromat objective and a 3.3× phototube (Olympus Optical). The image was captured using a

Sony XC77CE video camera (Sony, Tokyo, Japan) linked to a personal computer with frame grabber and image pro image analyses software (Media Cybernetics, Silver Spring, MD). Using the length tool, we measured the height of the epithelium at right angles from the base of the cell adjacent to the basement membrane to the luminal surface of the cell. After measuring the length, the angle of the line was measured to ensure that it was at 90 degrees. For each animal, we measured at least 50 cells, with sampling from a number of different ducts, and calculated the mean value.

Statistics. We compared testis weights and efferent duct epithelial cell height for control and treated groups at each age point using analysis of variance; where significant differences between groups were indicated, subgroup comparisons utilized the same test, but the overall variance served as the measure of error.

Results

Testis weight after neonatal estrogen exposure. Testis weights were compared between control and treated cohorts at 18, 25, 35, and 75 days of age. Testicular size has previously been shown to be decreased after postnatal exposure to estrogenic compounds (26) and usually provides a gross indication of the total number of cells within each testis. Testis weights were significantly reduced at all ages after treatment with GnRH_a, ethinyl estradiol, and all three doses of DES (Fig. 1). As the soy-free control data did not differ significantly from

control animals in any parameter assessed at day 18 (except testis weight), for simplicity, at all other ages assessed, the data from soy-free control animals were pooled with “normal” control data.

Day 18. At day 18, neonatal exposure to high doses of potent estrogens (DES 10 µg, DES 1 µg, ethinyl estradiol 10 µg) all caused highly significant reductions in testis weight. A similar reduction was induced by administration of GnRH antagonist or tamoxifen (Fig. 1). Animals treated with weakly estrogenic compounds (bisphenol A and parabens) showed no alteration in testis weights when compared to control animals, but animals treated neonatally with octylphenol displayed a significant increase in testis weight. Rats that had been treated with genistein and their controls were born to mothers which had been fed a soy-free diet and were maintained on this diet postnatally. The testis weights of genistein-treated and soy-free controls did not differ significantly.

Day 25. The testis weights of animals killed on day 25 (Fig. 1) showed a similar pattern to those described for day 18. Animals treated neonatally with high doses of estrogen (DES 10, 1, 0.1 µg; ethinyl estradiol) demonstrated highly significant reductions in testis weights similar to the reduction obtained after administration of GnRH_a (Fig. 1). Administration of the weakly estrogenic compounds (octylphenol, bisphenol A, and genistein) had no detectable impact on testis weight.

Days 35 and 75. Testis weights at day 35 and in adults demonstrated similar

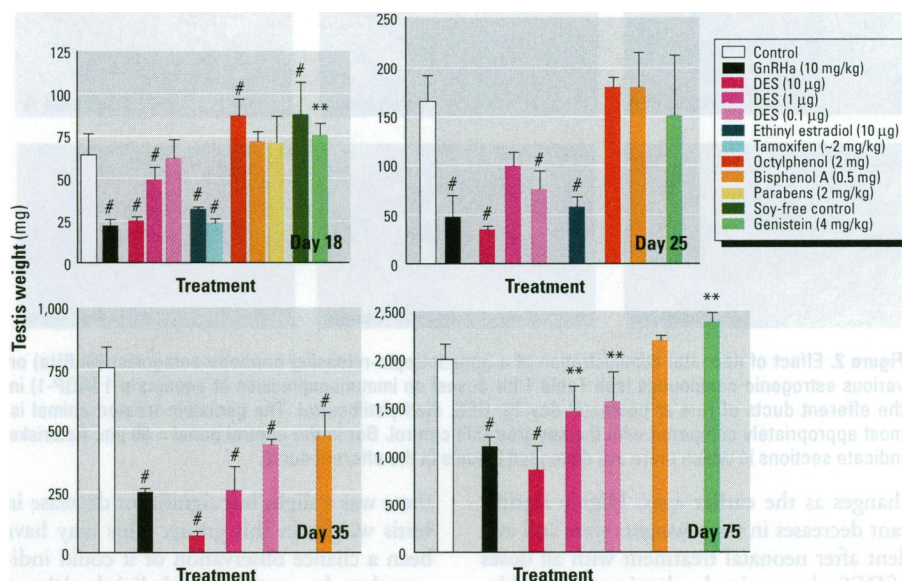


Figure 1. Effect of neonatal treatment with a gonadotropin-releasing hormone antagonist (GnRH_a) or various estrogenic compounds on testis weights of animals from 18 to 75 days of age. DES, diethylstilbestrol. The data shown are means ± standard deviations for 3–20 animals/group. The genistein-treated animals were compared with the soy-free control group on day 18.

** $p < 0.01$; # $p < 0.001$ in comparison with the respective control group.

Table 1. Subjective comparison of changes in aquaporin-1 (AQP-1) immunorexpression and rete testis distension in control and treated animals at 10, 18, 25, 35, and 75 days of age

Treatment	Day 10				Day 18				Day 25				Day 35				Day 75			
	AQP-1	n	Rete	n	AQP-1	n	Rete	n	AQP-1	n	Rete	n	AQP-1	n	Rete	n	AQP-1	n	Rete	n
Control	+++	5	P	3	+++	11	P	5	+++	20	P	8	+++	6	P	6	+++	6	P	6
Soy-free control	-	-	-	-	+++	13	P	3	-	-	-	-	-	-	-	-	-	-	-	-
GnRHa	-	-	-	-	+++	12	P	4	+++	8	P	6	+++	3	P	3	+++	5	P	4
DES (10 µg)	+	4	MG	3	±	14	MG	9	+	9	MG	3	++	6	FE	4	+++	6	FE	4
DES (1 µg)	-	-	-	-	+	10	MG	5	±±	4	P	3	+++	5	FE	4	+++	4	P	3
DES (0.1 µg)	-	-	-	-	+	10	MG	4	±±	4	P	4	+++	4	P	3	+++	4	P	3
Ethinyl estradiol (10 µg)	-	-	-	-	+	4	MG	4	±	7	P	5	-	-	-	-	-	-	FE	3
Genistein (4 mg/kg)	+++	5	P	4	+++	14	P	4	+++	7	P	3	-	-	-	-	+++	5	P	4
Bisphenol A (0.5 mg)	+++	4	P	4	+++	6	P	6	+++	5	P	4	+++	7	P	3	+++	3	P	3
Octylphenol (2 mg)	-	-	-	-	++	8	P	4	++	6	P	3	-	-	-	-	-	-	-	-
Parabens (2 mg/kg)	-	-	-	-	++	6	P	3	-	-	-	-	-	-	-	-	-	-	-	-
Tamoxifen (2 mg/kg)	-	-	-	-	++	5	-	-	-	-	-	-	-	-	-	-	-	-	-	-

Abbreviations: DES, diethylstilbestrol; GnRHa, gonadotropin-releasing hormone antagonist; +++, control level of AQP-1 immunostaining; ++, reduced level of immunostaining; +, major reduction in the level of immunostaining; ±, few cells with immunostaining; P, patent rete testis; FE, signs of fluid retention and enlargement of rete testis; MG, major fluid retention and gross enlargement of rete testis.

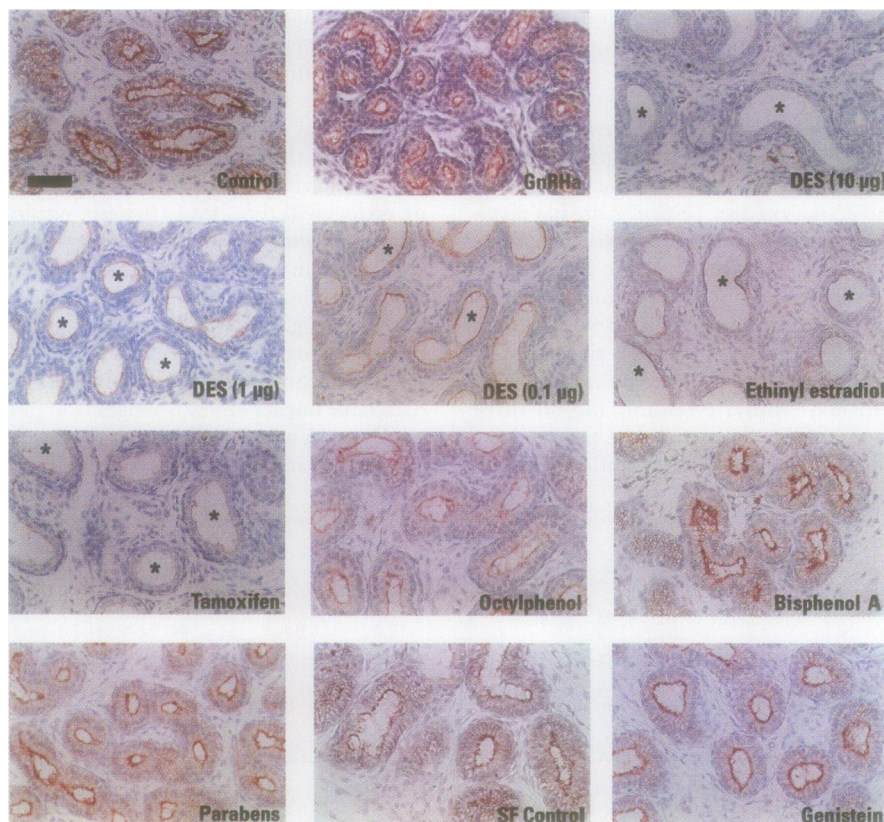


Figure 2. Effect of neonatal administration of a gonadotropin-releasing hormone antagonist (GnRHa) or various estrogenic compounds (see Table 1 for doses) on immunorexpression of aquaporin-1 (AQP-1) in the efferent ducts of rats at postnatal day 18. DES, diethylstilbestrol. The genistein-treated animal is most appropriately compared with the soy-free (SF) control. Bar in the control panel = 50 µm. Asterisks indicate sections in which there are distended lumens in the efferent ducts.

changes as the earlier ages. Highly significant decreases in testis weights were still evident after neonatal treatment with all doses of DES; the maximal reduction (induced by 10 µg DES) was similar to that produced by neonatal administration of GnRHa (Fig. 1). Neonatal administration of bisphenol A did not cause any reduction in adult testis weight, although at 35 days of age (Fig. 1)

there was a slight but significant decrease in testis weight in this group. This may have been a chance observation or it could indicate that these animals had slightly delayed puberty. Animals treated neonatally with genistein had marginally but significantly larger testes in adulthood (Fig. 1).

Immunorexpression of AQP-1 and efferent duct morphology. Immunorexpression of

AQP-1 was performed on a cohort of animals from all treatment groups at all ages. Due to the volume of data generated, the results were tabulated and photomicrographs were compiled for all treatment groups at postnatal day 18. This time point was selected because it was the age when the most pronounced changes occurred after DES administration; thus, we considered that milder treatment regimes would be most likely to induce detectable changes at this time point.

Day 10. Data for AQP-1 immunorexpression is tabulated in Table 1. At day 10 in control animals, AQP-1 formed a strong apical band of staining along the brush border of the efferent duct epithelium, as is shown for a control animal at day 18 in Figure 2. At day 10, when animals injected with 10 µg DES were still undergoing treatment, the efferent ducts had a greatly reduced level of AQP-1 immunorexpression (not shown). In the same group, the efferent duct epithelial cell height appeared noticeably reduced and the efferent duct lumens appeared distended. Treatment with weakly estrogenic compounds (genistein or bisphenol A) caused no detectable reduction in the intensity of AQP-1 immunorexpression or in efferent duct morphology (not shown).

Day 18. The results of AQP-1 immunostaining are described in Table 1, and representative photomicrographs for all treatment groups are shown in Figure 2. High power oil immersion images are also shown for some treatments in Figure 3 to illustrate more clearly the alterations to the efferent duct epithelium. At day 18 in control rats, AQP-1 immunostaining was clearly evident along the apical brush border of the efferent duct epithelium and along the basolateral surface of the epithelial cells. There was very little immunoreactive AQP-1 along the basal border of the efferent ducts. Similarly, in animals treated with GnRHa, there was strong, apical immunolocalization of AQP-1

to the efferent duct epithelium, the intensity of immunostaining being comparable to control levels. Epithelial cell height in GnRHa-treated rats appeared slightly reduced, but there was no evidence of distension of the efferent duct lumen; indeed, lumens appeared reduced in size in comparison to lumens from control animals (Fig. 2). In contrast, treatment with potent estrogens (DES 10 μ g, 1 μ g, and 0.1 μ g, and ethinyl estradiol 10 μ g) induced a gross and dose-dependent reduction in the level of immunoreactive AQP-1, such that animals treated neonatally with 10 μ g DES had almost no detectable AQP-1 immunostaining (Fig. 2, Table 1). All of these treatments also caused distension of the efferent duct lumen and an apparent reduction in height of the epithelial cells. Neonatal treatment with tamoxifen also caused marked changes in the level of AQP-1 immunoreactivity, distension of the efferent duct lumen, and apparent reduction in epithelial cell height. These changes were similar in magnitude to those induced after neonatal treatment with 1–10 μ g DES (Fig. 2, Table 1).

Administration of weakly estrogenic compounds (octylphenol, bisphenol A, and parabens) produced no gross changes in the level of AQP-1 immunostaining, although there was the suggestion of a minor but consistent reduction in immunoreactivity after octylphenol treatment (Fig. 2). The octylphenol group also appeared to have slightly, but consistently, larger lumens in their efferent ducts than did the controls; this was not observed in rats treated neonatally with bisphenol A or parabens. All parameters measured were comparable in genistein-treated and soy-free controls. Individual efferent ducts were examined and photographed under higher power magnification to highlight some of the changes described above.

In controls the efferent ducts were composed of a highly columnar, polarized epithelium, with a brush border evident on the apical membrane where AQP-1 immunolocalized. The nuclei of the nonciliated cells are in the basal region of the cell, with the nuclei of ciliated cells in a more central location. The lumen of the duct forms an irregular shape in cross-section. No consistent change to this appearance was evident after neonatal treatment with bisphenol A. In contrast, high dose estrogen treatment (DES or ethinyl estradiol, 10 μ g) resulted in alteration of the epithelial cells from a high columnar to a cuboidal shape (Fig. 3). These cells appeared to lack most of their apical cytoplasm as well as the brush border and its associated immunoreactivity of AQP-1. The lumens of the efferent ducts in these animals were much more regular and spheroidal in cross-section

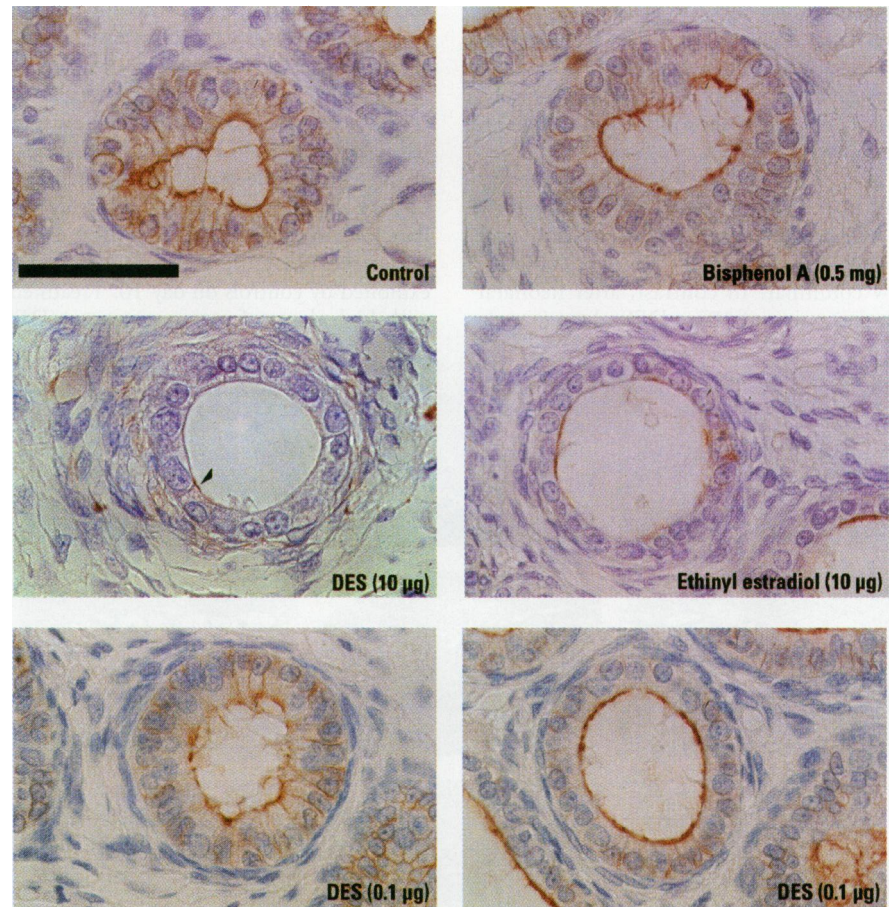


Figure 3. Oil immersion, high power photomicrographs of efferent duct epithelial cell morphology and immunoreactivity of aquaporin-1 (AQP-1) in animals treated neonatally with various estrogenic compounds to illustrate the coincidence of changes in AQP-1 immunoreactivity, luminal distension, and reduction in epithelial cell height. Bar in the control panel = 500 μ m. Note the heterogeneity of these end points in efferent ducts from animals treated with 0.1 μ g diethylstilbestrol (DES).

(as if turgid) when compared to controls. There was also thickening of the layer of peritubular cells that lie around the outside of the duct. The latter was confirmed by immunohistochemical staining of these cells using an antibody to smooth muscle actin (data not shown). In animals treated with the lowest dose of DES (0.1 μ g), we observed efferent ducts that contained epithelial cells with characteristics comparable to control animals, whereas other ducts, which were evident in the same cross-section, displayed morphological characteristics that were similar to those observed after high dose DES treatment (Fig. 3). This heterogeneity of ductal morphology was a consistent finding in animals from this group.

Days 25, 35, and 75. The results describing the level of AQP-1 immunoreactivity at 25, 35, and 75 days of age, after neonatal estrogen treatment, are shown in Table 1. Control animals displayed a similar pattern and intensity of immunoreactivity as shown for day 18 (Fig. 2). This was unaffected by treatment with GnRHa, similar to day

18, whereas treatment with potent estrogens (DES or ethinyl estradiol) caused reductions in the level of AQP-1 immunoreactivity coincident with alterations in the morphology of the efferent duct epithelial cells. These changes were still evident at day 35, but the level of immunoreactivity for AQP-1 had greatly increased in comparison with day 25, and by adulthood, was indistinguishable from controls. Animals treated neonatally with weakly estrogenic compounds again showed similar levels of AQP-1 to those described for day 18, with no gross change from control; one exception was octylphenol-treated animals at day 25 in which immunoreactivity may have been slightly reduced compared to control animals.

Rete testis morphology. In our initial study using high dose (10 μ g) DES, we observed abnormal distension and overgrowth of the rete testis. In the present report we have expanded these observations to encompass different ages and treatments to determine the effects on the rete testis of a range of potent and weakly estrogenic chemicals. Again due to the volume of data

generated from this comparison, the results have been tabulated in Table 1 and representative photomicrographs are shown to illustrate the results obtained for days 18 and 75, which are shown in Figures 4 and 5, respectively.

Day 10. At day 10 in control animals and in rats treated neonatally with weakly estrogenic compounds (genistein and bisphenol A), the epithelium was cuboidal-low columnar. In contrast, after neonatal administration of 10 μ g DES, the rete testis

was grossly distended and the epithelial cells of the rete testis had become flattened and almost squamous in appearance (not shown).

Day 18. In control animals at day 18 (Fig. 4) the epithelium of the rete testis was reduced in height in comparison to animals at day 10, but neonatal treatment with a GnRH antagonist appeared to delay this flattening of the epithelial cells because they still appeared cuboidal, similar to that exhibited by controls on day 10. Treatment with high doses of potent estrogens (DES

10 μ g and 1 μ g and 10 μ g ethinyl estradiol) induced gross distension of the rete testis (Fig. 4), a change that was not evident in animals treated with 0.1 μ g DES. The degree of distension of the rete testis after neonatal exposure to DES appeared to be dose dependent, and the more severe distension was accompanied by deeper invasion of the rete into the testicular parenchyma. Neonatal treatment with weakly estrogenic compounds, octylphenol, bisphenol A, genistein, and butyl-parabens (not shown), had no detectable effect on the morphology of the rete testis (Fig. 4).

Days 25 and 35. In animals assessed at day 25, the gross enlargement of the rete testis was still evident in animals exposed to 10 μ g DES (but not at lower doses) or ethinyl estradiol (Table 1). Similarly, at day 35 signs of fluid retention and distension of the rete testis were only evident in animals treated neonatally with 10 or 1 μ g DES (animals treated with ethinyl estradiol were not assessed at this time point).

Day 75. In adulthood there was no sign of abnormal fluid build up or rete testis distension in control (Fig. 5) or GnRH-treated animals (not shown). However, there were still signs of abnormal distension in animals treated neonatally with DES (10 μ g) or ethinyl estradiol, although the severity of these effects was much reduced (Fig. 5) when compared with earlier time points. These treatments also disrupted normal spermatogenesis, as many seminiferous tubules (particularly those lying underneath the rete testis) were largely depleted of germ cells or were Sertoli cell only and displayed

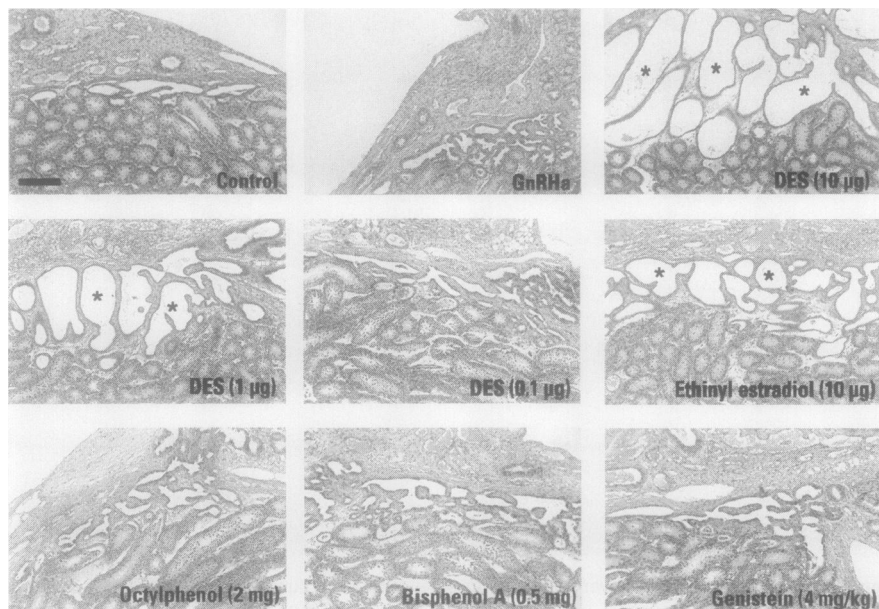


Figure 4. Effect of neonatal administration of a gonadotropin-releasing hormone antagonist (GnRH α) or various estrogenic compounds on the morphology of the rete testis at postnatal day 18. Asterisks indicate sections in which the rete testis is distended or overgrown. Bar in the control panel = 200 μ m.

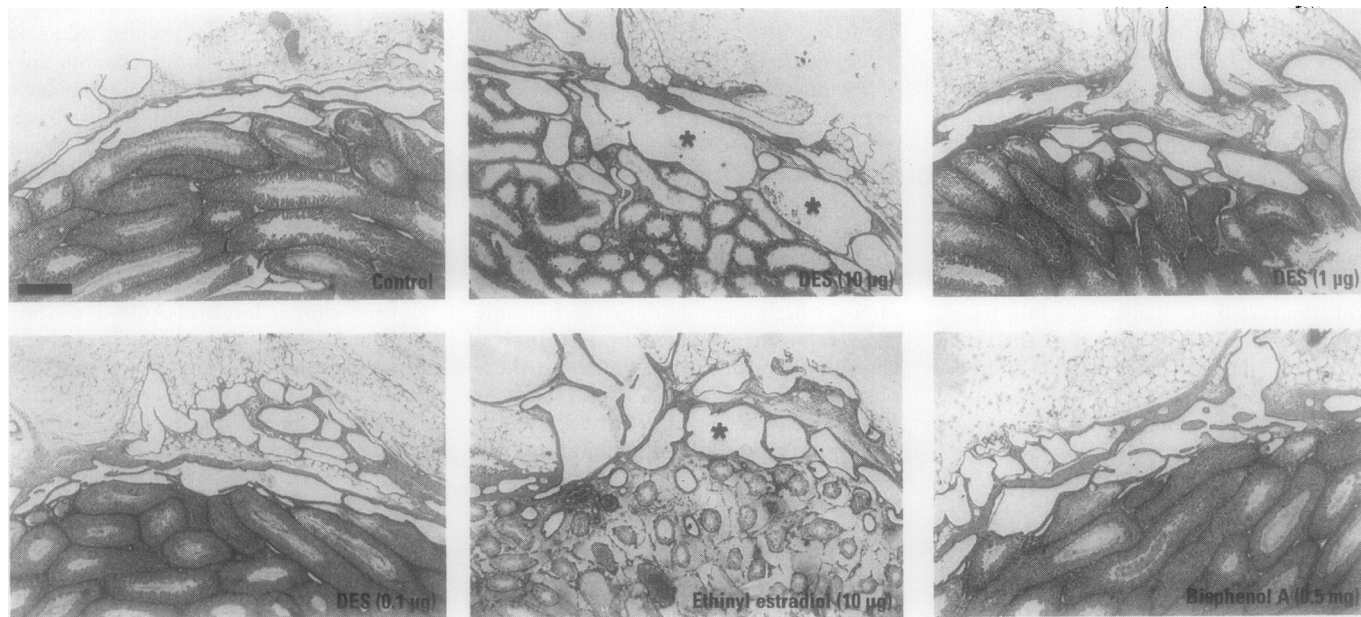


Figure 5. Effect of the neonatal administration of various estrogenic compounds on morphology of the rete testis in adulthood (day 75). Note the presence of germ-cell depleted seminiferous tubules in animals treated with 10 μ g diethylstilbestrol (DES) or ethinyl estradiol. Asterisks indicate sections in which the rete testis is distended. Bar in the control panel = 200 μ m.

distended lumens. There were no obvious changes within the rete testis of animals treated neonatally with lower doses of DES (1 or 0.1 μg) or bisphenol A.

Efferent duct epithelial cell height. The photomicrographs in Figure 3 demonstrate that neonatal estrogen treatment appeared to alter the height of the epithelial cells of the efferent ducts, thus, this was quantified for the various treatment groups at each time point. At day 10, the only time point assessed when rats were still on treatment, there was a significant reduction ($p < 0.05$) in epithelial cell height after administration of 10 μg DES [control = $12.9 \pm 1.8 \mu\text{m}$ ($n = 5$); DES = 8.6 ± 1.0 ($n = 4$); mean \pm standard deviation (SD)]. There was no change in epithelial cell height after the administration of bisphenol A or genistein on day 10 (data not shown). At day 18, all of the chemicals administered neonatally (except parabens) caused a significant reduction in epithelial cell height (Fig. 6). Soy-free control animals had epithelial cell heights that were comparable to the “normal” control population at day 18 (Fig. 6) and at later time points (data not shown). Treatment with GnRHa induced a small but significant reduction in efferent duct epithelial cell height at day 18, but was without effect beyond this time point. Administration of the highest dose of DES (10 μg) induced a highly significant reduction in epithelial cell height, which was most severe at postnatal days 18 and 25 postnatal (Fig. 6). In this group, cell height was still significantly reduced in comparison to control levels at day 35; although a small decrease was still evident in adulthood, this did not reach statistical significance. The reduction in epithelial cell height was not as severe after the administration of lower doses of DES (1 and 0.1 μg); by either day 75 (DES 1 μg) or day 35 (DES 0.1 μg), epithelial cell heights had recovered to control levels. Administration of ethinyl estradiol induced a reduction in epithelial cell height which was similar in magnitude to that induced by 10 μg DES at all ages assessed (Fig. 6). Administration of tamoxifen (assessed only on day 18) induced a significant reduction in epithelial cell height similar to that induced by 0.1–1 μg DES. Octylphenol, bisphenol A, and genistein all induced small but significant reductions in epithelial cell height. However, these changes were transient, and where appropriate time points were collected, no effects were detected beyond day 25 (Fig. 6).

Discussion

The efferent ducts are now recognized to be an important site for both fluid resorption and estrogen action within the male reproductive tract (27). It is also becoming clear that exposure to inappropriate levels of

estrogen can induce perturbations in normal fluid dynamics in this region and may have consequences for male fertility. Exposure to high levels of the synthetic estrogen DES in neonatal life has previously been shown to induce gross distension of the rete testis and efferent ducts, as well as reducing the level of AQP-1 protein expression (20). Male mice that are homozygous for a mutation in the gene encoding ER α are infertile and show similar changes in fluid dynamics postpubertally (27,28). In view of these developments, we assessed whether changes induced to the excurrent duct system of the male might serve as a biological indicator of inappropriate estrogen exposure during development.

In the absence of specific biochemical and molecular markers of estrogen function in the excurrent ducts, we assessed parameters that we previously showed to change after neonatal exposure to DES (20). We assessed the level of immunoreactive AQP-1 in the efferent duct epithelium and rete testis, we observed efferent duct morphology to assess any signs of distension, and we measured efferent duct epithelial cell height and testis weights from postnatal day 10 until adulthood in animals treated neonatally with estrogenic compounds. As a point of reference, rats were treated with various concentrations (10 μg , 1 μg , 0.1 μg /injection) of the potent synthetic estrogen DES. The effects of DES were compared to those of ethinyl estradiol (10 μg /injection) and tamoxifen and to the effects of weakly estrogenic compounds

(bisphenol A, octylphenol, parabens, and the phytoestrogen genistein).

At day 18, neonatal exposure to DES resulted in dose-dependent changes in all of the parameters measured. The greatest effects always occurred after the administration of 10 μg DES, and lesser effects were observed after the administration of the two lower doses (1 and 0.1 μg), although the differences between these two lower doses were sometimes marginal. At time points beyond day 25, dose-dependent effects of DES were still evident on testis weights, and epithelial cell height of the efferent ducts still exhibited dose-dependent changes at days 35 and 75 (testis weights only). Our study failed to determine a no observable effect level after neonatal administration of decreasing doses of DES; further studies using lower doses are in progress to address this issue. The distension of the rete testis and impairment of spermatogenesis observed in this study after administering 10 μg DES (equivalent to $\sim 0.37 \text{ mg/kg/day}$) to neonates are very similar to those published recently after administration of 0.5 or 1 mg estradiol benzoate/5 g bodyweight (100 or 200 mg/kg) on the day of birth (29).

The changes within the excurrent ducts after neonatal DES treatment appear to be a direct response to estrogen administration, as animals treated neonatally with GnRHa did not show any abnormalities except for a transient reduction in efferent duct epithelial cell height and a permanent reduction in testis weight due to an approximate halving in Sertoli cell numbers (21). Ethinyl estradiol induced effects similar to those observed

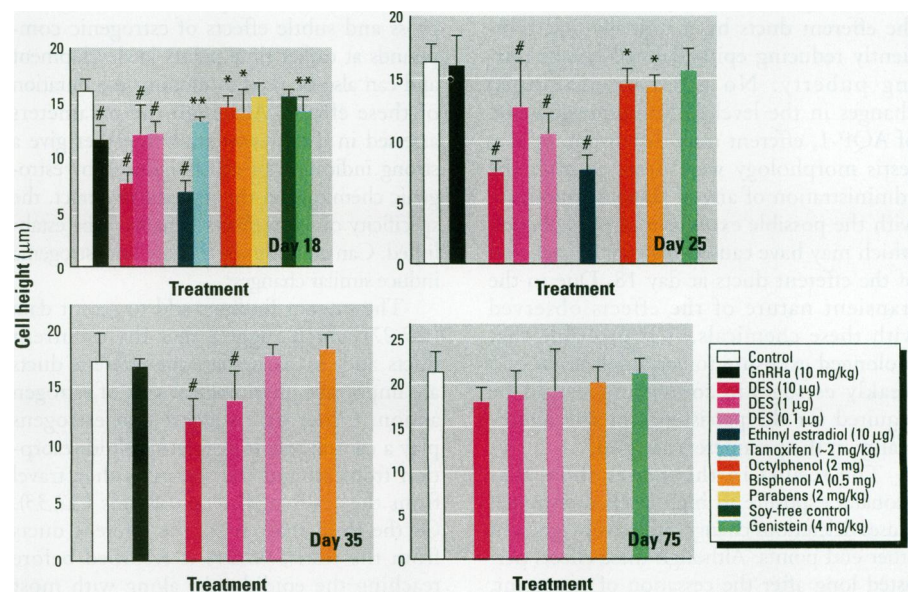


Figure 6. Effect of neonatal treatment with a gonadotropin-releasing hormone antagonist (GnRHa) or various estrogenic compounds on epithelial cell height in the efferent ducts at 18–75 days of age. The data shown are means \pm standard deviations for 3–20 animals/group. Genistein-treated animals were compared with the soy-free control group on day 18.

* $p < 0.05$; ** $p < 0.01$; # $p < 0.001$ in comparison with the respective control group.

after the administration of DES at the same concentration of 10 µg/injection. All the parameters measured showed a similar degree of change, with the exception of rete testis distension, which was not as severe as that observed after treatment with the equivalent dose of DES. The similarity in the effects observed between ethinyl estradiol and DES shows that these changes result from estrogenic effects of DES and not as the result of some other toxic effect of this compound. This conclusion is reinforced by the demonstration that neonatal exposure to tamoxifen caused similar changes to the efferent ducts (reduced immunorexpression of AQP-1, distension of efferent ducts, and reduction in epithelial cell height) at day 18 to those induced by ethinyl estradiol and DES; thus, these data show that this compound acts as an agonist in the male reproductive tract as it does at several other sites (e.g., bone). The only minor difference observed between the effect of 10 µg doses of DES and ethinyl estradiol regarded the more severe distension and overgrowth of the rete testis in the DES-treated cohorts. The overgrowth of the rete testis induced by these potent estrogens may be related to the increased incidence of rete testis adenocarcinoma (normally a rare neoplasm) that has been observed in both humans and mice exposed to DES *in utero* (30,31).

We also addressed the possibility that weakly estrogenic compounds such as phytoestrogens or other xenoestrogens could adversely affect development of the excurrent ducts. The results show that these weak estrogens exert only minor effects on the efferent ducts by marginally and transiently reducing epithelial cell height during puberty. No gross or prolonged changes in the level of immunorexpression of AQP-1, efferent duct distension, or rete testis morphology were detected after the administration of any of these compounds, with the possible exception of octylphenol, which may have caused marginal distension of the efferent ducts at day 18. Due to the transient nature of the effects observed with these chemicals, it is probable that prolonged exposure to very high levels of a weakly estrogenic compound would be required for the persistence of any abnormality in the parameters assessed.

The results in this paper show that neonatal exposure to high levels of estrogen causes deleterious changes in testis weight and other end points. Although these effects persisted long after the cessation of treatment, most of the parameters measured, except for testis weight and rete testis morphology, had largely normalized by 75 days of age. Rete testis morphology still showed signs of distension in both the ethinyl estradiol- and DES

(10 µg/injection)-treated animals by 75 days of age, although this parameter is difficult to assess in an objective or quantifiable way. It is also difficult to compare rete testis morphology between animals because cross-sections from identical regions of the tissue must be assessed and only gross changes can be detected easily. Any subtle effects that may have been induced by xenoestrogens therefore would not be detectable. Similarly, it is difficult to detect subtle changes in the level of AQP-1 immunostaining that may have arisen after treatment with weakly estrogenic compounds. Therefore, the most useful parameters measured were efferent duct epithelial cell height and testis weight. Changes in testis weight are very useful to gauge the overall effects of treatment and, in adult animals, testis weight has previously been shown to correlate with daily sperm production (26). Administration of other compounds, such as GnRH_a, produced a similar reduction in testis weight to DES exposure (10 µg/injection), demonstrating that this cannot be used as a specific end point of inappropriate estrogen exposure. The postnatal period is critical for normal testis growth and alterations in Sertoli cell numbers induced at this time point are permanent, whereas other regions of the male reproductive tract appear to be more plastic and showed signs of recovery from estrogenic effects. For example, at 75 days of age, rats treated neonatally with DES (all doses) showed significant reductions in testis weight, whereas efferent duct epithelial cell height was not significantly different from control values. However, efferent duct epithelial cell height is a useful, objective end point for assessing both gross and subtle effects of estrogenic compounds at earlier time points in development and can also be used to monitor the duration of these effects. Although the parameters assessed in the present study together give a strong indication of effects induced by estrogenic chemicals on the reproductive tract, the specificity of these effects remains to be established: Can compounds that are not estrogenic induce similar changes?

The present findings add to recent data (20,27) which suggest that the excurrent ducts and, in particular, the efferent ducts are important physiological sites of estrogen action. Other data suggest that estrogens play a central role in regulating fluid resorption from around the sperm as they travel from the testis to the epididymis (32,33). Of the fluid that enters the efferent ducts from the testis, 96.2% is resorbed before reaching the epididymis, along with most inorganic electrolytes and proteins (32). Many factors known to be involved in ion and water movement (e.g., Na⁺-K⁺ ATPase, Na⁺-H⁺, and Cl⁻-HCO₃⁻ exchangers and Na⁺-K⁺-2Cl⁻ symport) (34-36)

have been localized to the efferent ducts, but as yet there is no information as to which, if any, of these ion channels are estrogen regulated. A good candidate molecule is a member of the ABC transporter family, which is involved in the pathology that arises in individuals with inactivating mutations in the cystic fibrosis (CF) gene. The cystic fibrosis transmembrane regulator (CFTR) is a cAMP-activated Cl⁻ channel. It is well established that patients with CF are often infertile due to degeneration of the vas deferens, but some also suffer from obstructive azoospermia due to the deposition of thick mucous material in the epididymal lumen (37,38). There is evidence that a cAMP-activated Cl⁻ channel exists in the epididymal epithelium (39,40). Also, *in situ* hybridization studies on human tissue have localized the mRNA of this protein to the epididymis and vas deferens, with the highest expression in the head of the epididymis (41), raising the likelihood of its expression also in the efferent ducts. CFTR may be a good candidate for hormonal regulation because studies on female rats have shown that estrogen up regulates its expression in the uterine epithelium (42,43). In addition, both CF mutations and increased estradiol levels have been found in otherwise healthy men with reduced sperm quality (37,44).

It will be important in future studies to establish which components of the fluid endocytosis pathway in efferent ducts are estrogen regulated because this may provide a more direct and quantifiable end point of estrogen exposure that can be applied to studies of the effects of environmental and other estrogens on development and function of the male reproductive system.


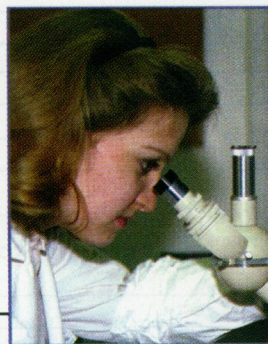
REFERENCES AND NOTES

- Irvine DS. Falling sperm quality. *Br Med J* 309:476 (1994).
- Auger J, Kunstmann JM, Czyglik F, Jouannet P. Decline in semen quality among fertile men in Paris during the past 20 years. *N Engl J Med* 332:281-285 (1995).
- DeMouzon J, Spira A, Thonneau P, Multigner L. Declining sperm count—semen quality has declined among men born in France since 1950. *Br Med J* 313:43 (1996).
- Miller W, Sharpe R. Environmental oestrogens and human reproductive cancers. *Endocr Rel Cancer* 5:69-96 (1998).
- Toppari J, Larsen JC, Christiansen P, Giwercman A, Grandjean P, Guillette LJ Jr, Jégou B, Jensen TK, Jouannet P, Keiding N, et al. Male reproductive health and environmental xenoestrogens. *Environ Health Perspect* 104(suppl 4):741-803 (1996).
- Carlsen E, Giwercman A, Keiding N, Skakkebaek NE. Evidence for decreasing quality of semen during past 50 years. *Br Med J* 305:609-613 (1992).
- Chilvers C, Pike MC, Forman D, Fogelman K, Wadsworth ME. Apparent doubling of frequency of undescended testis in England and Wales in 1962-1981. *Lancet* 2:330-332 (1984).
- Adami H, Bergstrom R, Mohner M, Zatonski W, Storm

- H, Ekblom A, Tretli S, Teppo L, Zeigler H, Rahu M, et al. Testicular cancer in nine northern European countries. *Int J Cancer* 59:33–38 (1996).
9. Paulozzi L, Erickson J, Jackson R. Hypospadias trends in two US surveillance systems. *Pediatrics* 100:831–834 (1997).
 10. Routledge E, Parker J, Odum J, Ashby J, Sumpter J. Some alkyl hydroxy benzoate preservatives (parabens) are estrogenic. *Toxicol Appl Pharmacol* 152:12–19 (1998).
 11. Colerangle J, Roy D. Profound effects of the weak environmental estrogen-like chemical bisphenol A on the growth of the mammary gland of Noble rats. *J Steroid Biochem Mol Biol* 60:153–160 (1997).
 12. Krishnan AV, Stathis P, Permuth SF, Tokes L, Feldman D. Bisphenol-A: an estrogenic substance is released from polycarbonate flasks during autoclaving. *Endocrinology* 132:2279–2286 (1993).
 13. Bicknell R, Herbison A, Sumpter J. Oestrogenic activity of an environmentally persistent alkylphenol in the reproductive tract but not the brains of rodents. *J Steroid Biochem Mol Biol* 54:7–9 (1995).
 14. Jobling S, Reynolds T, White R, Parker MG, Sumpter JP. A variety of environmentally persistent chemicals, including some phthalate plasticizers, are weakly estrogenic. *Environ Health Perspect* 103:582–587 (1995).
 15. Soto AM, Justicia H, Wray JW, Sonnenschein C. *p*-Nonyl-phenol: an estrogenic xenobiotic released from "modified" polystyrene. *Environ Health Perspect* 92:167–173 (1991).
 16. White R, Jobling S, Hoare S, Sumpter J, Parker M. Environmentally persistent alkylphenolic compounds are estrogenic. *Endocrinology* 135:175–182 (1994).
 17. Sharpe RM, Skakkebaek NE. Are oestrogens involved in falling sperm counts and disorders of the reproductive tract? *Lancet* 341:125–126 (1993).
 18. Rosenfeld CS, Ganjam VK, Taylor JA, Yuan X, Stiehr JR, Hardy MP, Lubahn DB. Transcription and translation of estrogen receptor- β in the male reproductive tract of estrogen receptor- α knock-out and wild-type mice. *Endocrinology* 139:2982–2987 (1996).
 19. Hess RA, Gist DH, Bunick D, Lubahn DB, Farrell A, Bahr J, Cooke PS, Greene GL. Estrogen receptor (α & β) expression in the excurrent ducts of the adult male rat reproductive tract. *J Androl* 18:602–611 (1997).
 20. Fisher JS, Turner KJ, Fraser HM, Saunders PTK, Brown D, Sharpe RM. Immunorexpression of aquaporin-1 in the efferent ducts of the rat and marmoset monkey during development, its modulation by estrogens, and its possible role in fluid resorption. *Endocrinology* 139:3935–3945 (1996).
 21. Sharpe R, Atanassova N, McKinnell C, Parte P, Turner KJ, Fisher JS, Kerr JB, Groome NP, Macpherson S, Millar MR, et al. Abnormalities in functional development of the Sertoli cell in rats treated neonatally with diethylstilbestrol: a possible role for estrogens in Sertoli cell development. *Biol Reprod* 59:1084–1094 (1998).
 22. Sharpe RM, Turner KJ, McKinnell C, Groome NP, Atanassova N, Millar MR, Buchanan DL, Cooke PS. Inhibin B levels in plasma of the male rat from birth to adulthood: effect of experimental manipulation of Sertoli cell number. *J Androl* 20:94–101 (1999).
 23. Setchell K, Zimmer-Nechemias L, Cai J, Heubi JE. Exposure of infants to phyto-oestrogens from soy-based infant formula. *Lancet* 350:23–27 (1997).
 24. Millar MR, Sharpe RM, Maguire SM, Saunders PTK. Cellular localisation of messenger RNAs in rat testis: application of digoxigenin-labelled ribonucleotide probes to embedded tissue. *Cell Tissue Res* 273:269–277 (1993).
 25. Sabolic I, Valenti V, Verbavatz J-M, Van Hoek AN, Verkman AS, Ausiello A, Brown D. Localization of the CHIP28 water channel in rat kidney. *Am J Physiol* 263:C1225–1233 (1992).
 26. Sharpe RM, Fisher JS, Millar MR, Jobling S, Sumpter JP. Gestational and lactational exposure of rats to xenoestrogens results in reduced testicular size and sperm production. *Environ Health Perspect* 103:1136–1143 (1995).
 27. Hess RA, Bunick D, Lee K-H, Bahr J, Taylor JA, Korach KS, Lubahn DB. A role for oestrogens in the male reproductive system. *Nature* 390:509–512 (1997).
 28. Eddy EM, Washburn TF, Bunch DO, Goulding EH, Gladen BC, Lubahn DB, Korach KS. Targeted disruption of the estrogen receptor gene in male mice causes alteration of spermatogenesis and infertility. *Endocrinology* 137:4796–4805 (1996).
 29. Aceitero J, Llanero M, Parrado R, Pena E, Lopez-Beltran A. Neonatal exposure of male rats to estradiol benzoate causes rete testis dilation and backflow impairment of spermatogenesis. *Anat Rec* 252:17–33 (1998).
 30. Newbold RR, Bullock BC, McLachlan JA. Adenocarcinoma of the rete testis. Diethylstilbestrol-induced lesions of the mouse rete testis. *Am J Pathol* 125:625–628 (1986).
 31. Newbold RR, Bullock BC, McLachlan JA. Lesions of the rete testis in mice exposed prenatally to diethylstilbestrol. *Cancer Res* 45:5145–5150 (1985).
 32. Ciulow J, Jones R, Hansen L. Micropuncture and cannulation studies of fluid composition and transport in the ductuli efferentes testis of the rat—comparisons with the homologous metanephric proximal tubule. *Exp Physiol* 79:915–928 (1994).
 33. Ciulow J, Hansen L, Jones R. In vivo microperfusion of the ductuli efferentes testis of the rat: flow dependence of fluid reabsorption. *Exp Physiol* 81:633–644 (1996).
 34. Byers S, Graham R. Distribution of sodium-potassium ATPase in the rat testis and epididymis. *Am J Anat* 188:31–43 (1990).
 35. Ilio KY, Hess RA. Localisation and activity of Na⁺,K⁺-ATPase in the ductuli efferentes of the rat. *Anat Rec* 234:190–200 (1992).
 36. Wong P. Electrolyte and fluid transport in the epididymis. In: *Epithelial Secretion of Water and Electrolytes*. Berlin:Springer-Verlag, 1990.
 37. van der Ven K, Messer L, van der Ven H, Jeyendran R, Ober C. Cystic fibrosis mutation screening in healthy men with reduced sperm quality. *Hum Reprod* 11:513–517 (1996).
 38. di Sant'Agnes P. Fertility and the young adult with cystic fibrosis [editorial]. *N Engl J Med* 279:103–105 (1968).
 39. Pollard C, Harris A, Coleman L, Argent B. Chloride channels on epithelial cells cultured from human fetal epididymis. *J Membrane Biol* 124:275–284 (1991).
 40. Huang SJ, Fu WD, Chung YW, Zhou TS, Wong PY. Properties of cAMP-dependent and Ca²⁺-dependent whole cell Cl⁻ conductances in rat epididymal cells. *Am J Physiol* 264:C794–C802 (1993).
 41. Tizzano E, Silver M, Chitayat D, Benichou J-C, Buchwald M. Differential cellular expression of cystic fibrosis transmembrane regulator in human reproductive tissues. *Am J Pathol* 144:906–914 (1994).
 42. Rochwerger L, Buchwald M. Stimulation of the cystic fibrosis transmembrane regulator expression by estrogen *in vivo*. *Endocrinology* 133:921–930 (1993).
 43. Rochwerger L, Dho S, Parker L, Foscett J, Buchwald M. Estrogen-dependent expression of the cystic fibrosis membrane regulator gene in a novel uterine epithelial cell line. *J Cell Sci* 107:2439–2448 (1994).
 44. Bujan L, Mieuisset R, Audran F, Lumbroso S, Sultan C. Increased oestradiol level in seminal plasma in infertile men. *Hum Reprod* 8:74–77 (1993).

Searching for job candidates with the right knowledge and experience?

We'll help you find them.



Advertise your position vacancy in ***Environmental Health Perspectives***.
For more information, call 919-541-5257.