

Past and Current Dermatological Status of Yusho Patients

by Harukuni Urabe* and Masakazu Asahi*

Skin symptoms of Yusho and their subsequent change were described. In the early stage, skin eruptions were the most prominent features of Yusho. Acneform eruptions and pigmentation were most conspicuous. With the passage of time, these symptoms have improved considerably and most patients have very slight eruptions now, except for the severely intoxicated group.

In the analysis of polychlorinated biphenyl (PCB) in the blood, the severely intoxicated group with intense skin symptoms showed pattern A—a typical Yusho-specific pattern. The blood PCB patterns of each patient were stable, with no alteration after many years; on the other hand, the blood PCB concentrations have diminished year by year.

Introduction

Yusho is the official English term for the mass polychlorinated biphenyl (PCB) poisoning that occurred in Japan in 1968 as the consequence of distributing a brand of cooking oil, Kanemi rice oil, which had been polluted with PCB during its manufacturing process.

Yusho patients showed quite conspicuous skin symptoms, especially in the initial period. The diagnosis of Yusho depended mainly on the skin symptoms.

In this article, skin symptoms of Yusho and their changes with time are described.

The Development of Yusho

On June 7, 1968, a 3-year-old girl came to our out-patient clinic, Department of Dermatology, Kyushu University, suffering from an acneform eruption. Her elder sister and parents also had almost same skin symptoms. This was the first case of Yusho. Soon afterwards, the number of such patients increased steadily and the disease was soon found to be widely distributed in the northern Kyushu district (1).

A large-scale collaboration team effort was organized by Kyushu University to track down the culpable substance and to develop an adequate treatment of the patients. After 3 weeks of laborious research, it was found that almost all affected families had used Kanemi rice oil—rice-bran oil—in preparing their meals. Analytical investigations showed that some specific lots

of the oil were contaminated with PCB. The concentration of the PCB in the oil was about 2000 ppm. The causative PCB, Kanechlor 400, was composed mainly of tetrachlorobiphenyl. The PCB had been employed as a heat conductor in the deodorization process and, unfortunately, accidental leakage of the PCB into the oil had occurred through pinholes of the heating coil.

At the beginning of Yusho, the polluted area was restricted mainly to northern Kyushu, where the contaminated rice oil was mainly marketed. At the end of 1982, the number of identified patients was 1788. They have been scattered throughout Japan during these 15 years, but are still centered in Kyushu. At present, 803 patients live in Fukuoka Prefecture and 737 in Nagasaki Prefecture.

Figure 1 shows the cumulative and newly identified number of patients in each year in Fukuoka Prefecture. In 1968, when Yusho first occurred, 320 patients were identified. This number increased year by year until the peak of 803 at the end of 1982. The sudden increase from 1973 to 1975 is due to the revision of the criteria for diagnosis based on more reliable means of determining blood PCB levels.

Skin Symptoms of Yusho: Initial Stage

Most Yusho patients showed eye discharge at first (1). Almost simultaneously, they showed various skin symptoms which were followed by quite variegated systemic symptoms and complaints. The skin symptoms were the most prominent and impressive features of Yusho in the outbreak days (2,3). The diagnosis (official

*Department of Dermatology, Faculty of Medicine, Kyushu University, Higashi-Ku, Fukuoka 812, Japan.

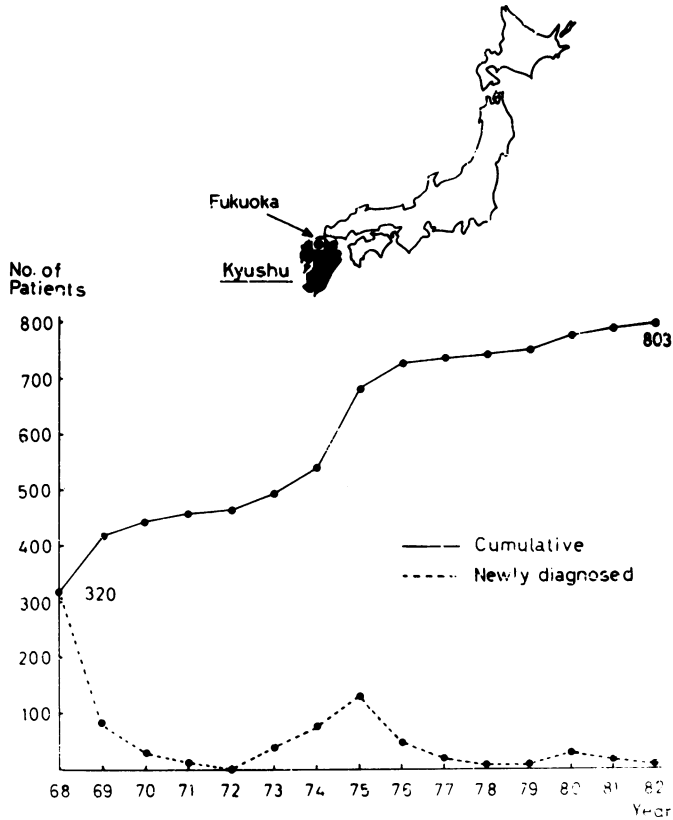


FIGURE 1. Number of Yusho patients in Fukuoka Prefecture.

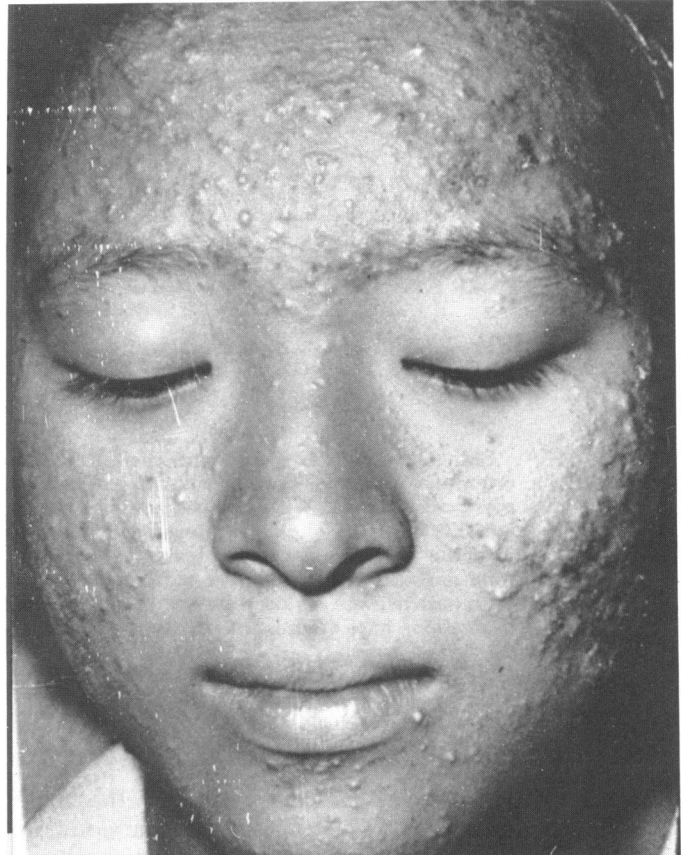


FIGURE 2. Acneiform eruptions on the face.

identification) of Yusho was made, in fact, mainly or solely upon these skin and mucous membrane symptoms.

Acneiform Eruptions

Closed comedones and cysts of various sizes up to finger-tip size were numerous.

Numerous open comedones with a relatively large black tip were conspicuous, especially in children.

These acneiform eruptions were noted mainly on face, especially cheeks, auricles and retroauricular areas, inguinal regions and external genitalia. They were quite stable and secondary infections were common (Figs. 2 and 3).

Follicular Dots

Black keratotic masses plugged the dilated follicles. These were found mainly in the armpit, groin, cubital fossa and popliteal space (Fig. 4).

Pigmentation

The pigmentation was usually observed on several circumscribed areas, and diffuse systemic pigmentation was never observed with the exception of the "black

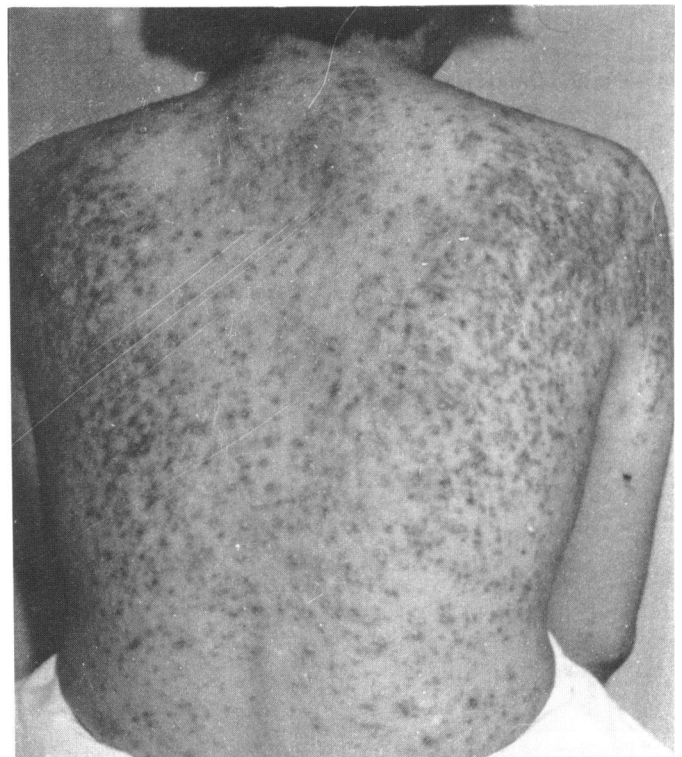


FIGURE 3. Acneiform eruptions on the back.

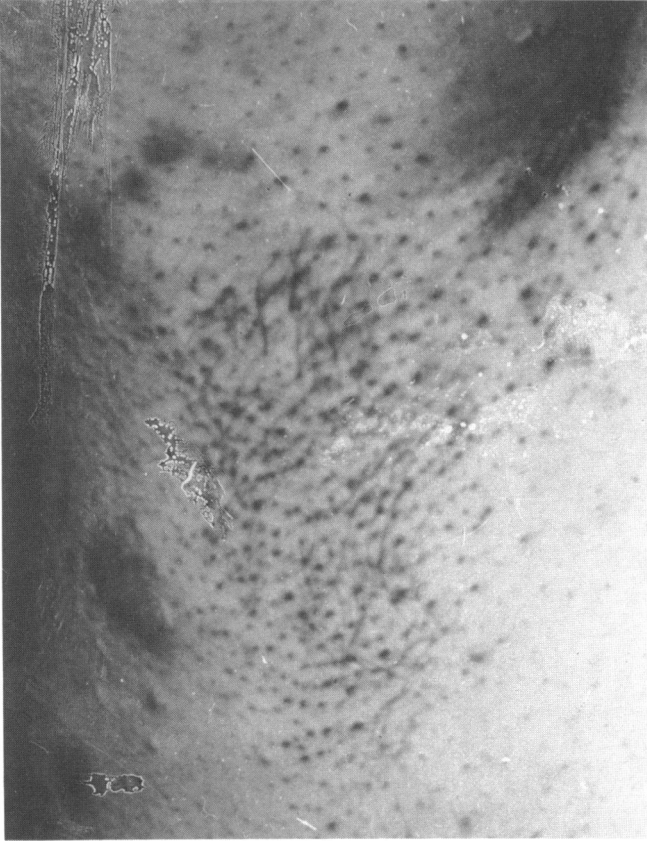


FIGURE 4. Follicular dots on the armpit.

baby" syndrome—the stillborn from a Yusho mother. The hyperpigmentation was noted mainly on nails of toes and fingers, gingivae, face, especially *ala nasi*, palpebral conjunctivae and lip (Figs. 5–7).

Hypertrophy of Meibomian Gland

Swelling of the Meibomian gland was visible, and eye discharge was conspicuous. Some cheeselike whitish mass could be squeezed out by the fingers.

Other skin symptoms noted in some patients were xerosis, hyperidrosis, flattening of the nail and hyperkeratoses mainly on the plantar surface. These were noted only in some patients.

Systemic Signs

In addition to these mucocutaneous manifestations, systemic signs such as general fatigue, loss of appetite, headache, numbness and swelling of the extremities, nausea, vomiting were also reported, but at that time these were regarded as complications of minor importance.

Laboratory findings of Yusho patients showed abnormally elevated serum triglyceride, anemia, lymphocytosis, hypoalbuminemia and reduction of sensory nerve conduction velocity. Adrenocortical dysfunction was not observed.

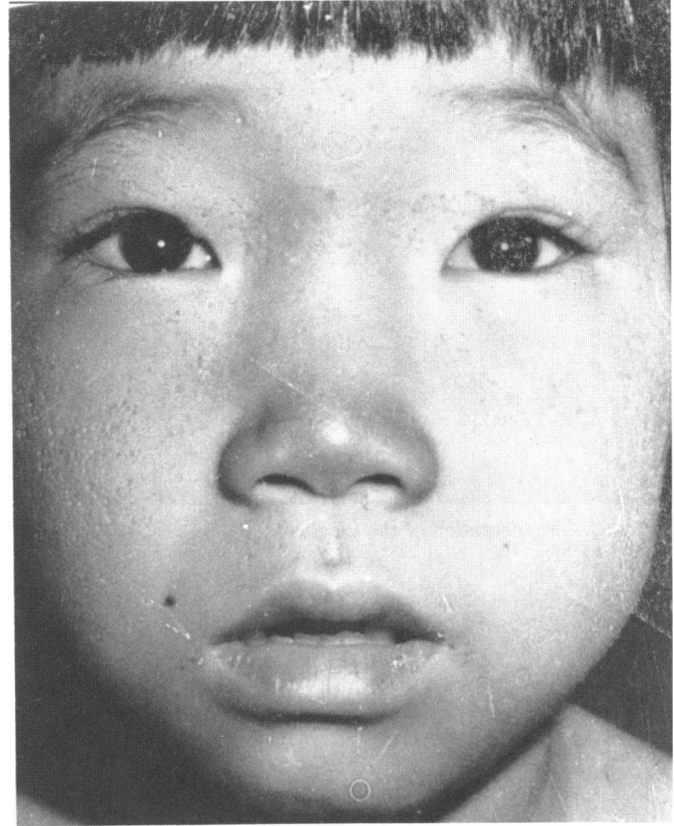


FIGURE 5. Pigmentation of the *ala nasi*.

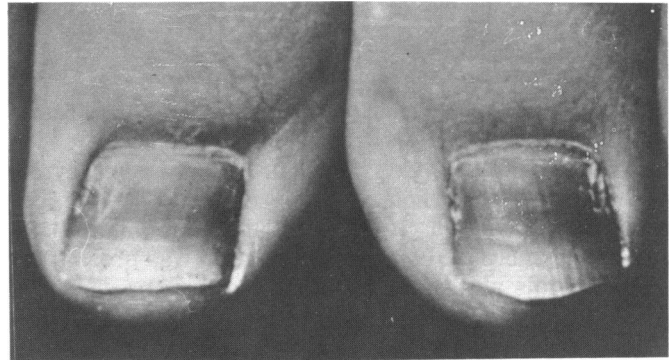


FIGURE 6. Pigmentation of toenails.

Histological Findings

Dilatation of the hair follicular orifice was frequently observed (4). The hair follicle showed a remarkable degree of hyperkeratosis. In the markedly hyperkeratotic cases, there was cystic dilatation of the follicle filled with layered keratinous material. Epithelial cells were displaced and flattened. The sebaceous glands were atrophic in cases with marked cystic dilatation of the follicles. Sweat gland changes were unremarkable.

In the epidermis, the horny layer was generally thin; the squamous cell layer was 3 to 5 cells thick (4). In the basal layer there was marked pigmentation (Fig. 8), and

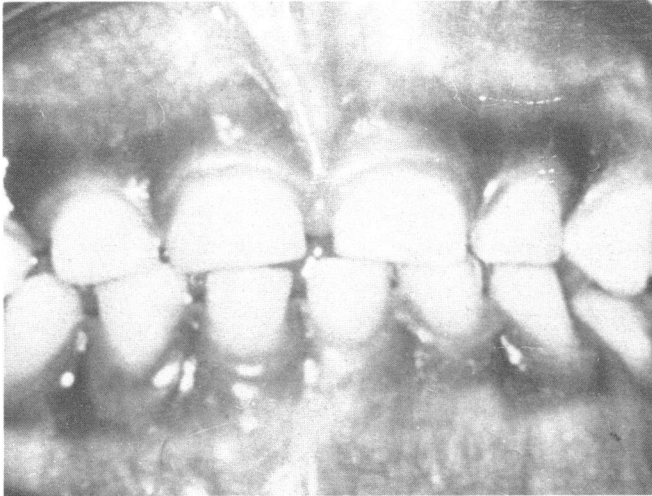

FIGURE 7. Pigmentation of the gingivae.

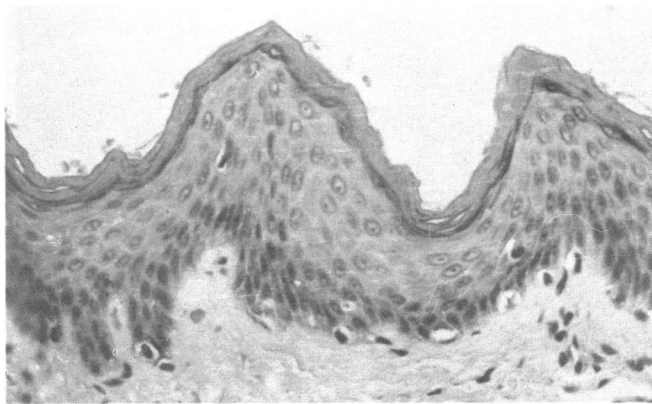


FIGURE 8. Histopathological hyperpigmentation of the basal layer.

coarse pigment granules were abundant in the cytoplasm. Occasional melanin was noted even in the squamous layer, but there was almost none in the dermis. An increased amount of melanin was present in the epidermis also on silver straining.

Changes in the Skin Symptoms with Time

With time, considerable improvement was noted in the severity and/or number of each eruption. The acneform eruptions decreased markedly within 3 or 4 years. Thereafter, a small number of cysts remained on auricles, retroauricular areas, external genitalia and gluteal region only in some cases. Black comedones usually disappeared within 5 or 6 years, and a very small number remain at present.

After these acneform eruptions had subsided, atrophic scarring with icepick scars remained in many patients and have disfigured the faces of these patients (Fig. 9). Follicular dots usually disappeared within 4 years. Pigmentation also diminished with time. In most cases,

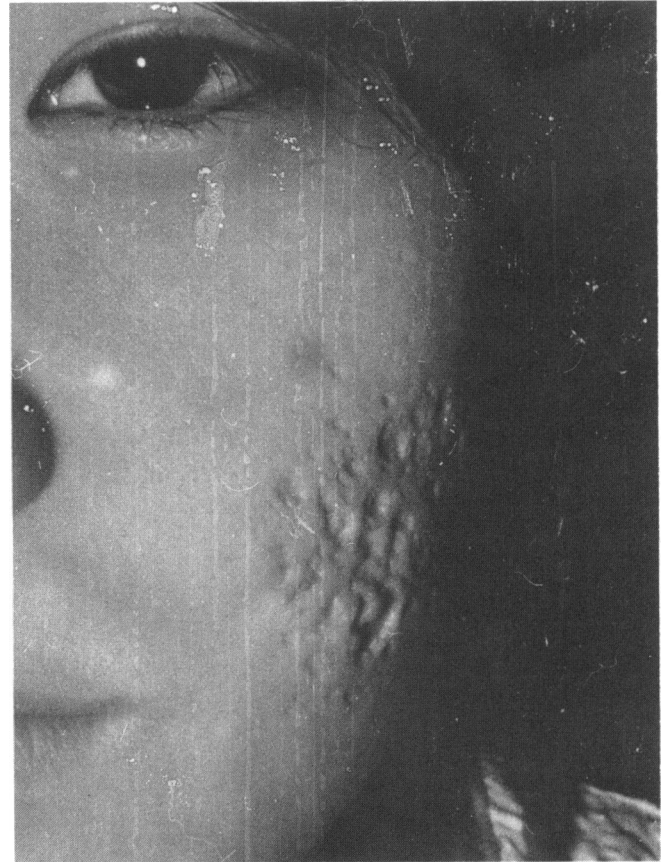


FIGURE 9. Pitlike scars after the acneform eruptions.

there was little pigmentation after 10 years. Only some patients have slight pigmentation now in the big toe nail, gingivae and *ala nasi*. Flattening of the nail improved within 2 or 3 years. Ingrown nail of the big toe and hyperkeratosis of the sole are still present in many patients.

The mucocutaneous lesions gradually gave way to systemic disorders such as dullness, headache or heavy headedness, indefinite stomachache, numbness or pain of the extremities, swelling and pain of joints, coughing, and bronchitislike symptoms. Skin symptoms are now slight in most patients; on the other hand, various systemic complaints above are still noted.

Evaluation of Skin Symptoms of Yusho by Skin Severity Grades

The following criteria were proposed for skin severity grading (5,6): Grade 0: no skin eruption; Grade I: circumscribed pigmentation; Grade II: black comedones; Grade III: acneform eruptions; Grade IV: extensive distribution of the acneform eruptions.

This standard aims at the grading of skin symptoms only. The overall severity of the PCB intoxication itself may differ from this grading.

The distribution of patients by skin severity grade

Table 1. Distribution of Yusho patients according to skin severity grades in 1971, 1976 and 1981.

Severity grade	Number of cases		
	1971	1976	1981
0	4	25	56
I	49	27	22
II	32	14	14
III	31	20	13
IV	13	4	2
Total	129	90	107

was investigated in 1971, 1976 and 1981 yearly general check-up records for Yusho in Fukuoka Prefecture (Table 1). Obviously the high severity grading group (III or IV) decreased and the low severity grading group (0 or I) increased with time.

Relationship Between Skin Symptom Grading and Blood PCB Analysis

Qualitative and quantitative examination of PCB in the sera of the patients was carried out soon after the outbreak of Yusho, and since 1973, the chromatographic patterns were classified into three types, namely pattern A, pattern B and pattern C. The A pattern refers to the typical Yusho pattern; the C pattern is a normal, non-Yusho pattern, and B is a pattern intermediate between A and C (7).

Yearly follow-up studies of the patients' blood PCB showed that the pattern of each patient remained fairly stable with little tendency toward improvement; the patient's pattern did not shift from A to C with clinical improvement (8). The pattern was unchanged while the concentration in the blood had decreased remarkably.

As to the relationship between the skin severity grading and blood PCB pattern of each patient, the following observations were made (9) (Fig. 10): (1) severely intoxicated patients—severity grades III or

IV—mostly show pattern A; (2) with time, the high severity grade group (III or IV) decreased within A, B and C, respectively; (3) the number of patients in the pattern A group did not decrease with time although there was considerable clinical improvement. This parallels the above-mentioned observation that the blood PCB patterns of each patient remained fairly stable.

Discussion

The most characteristic skin symptoms of Yusho are acneform eruptions and pigmentation. We speculate, although experimental evidence is still lacking, that these two symptoms are probably caused by direct stimulation of PCB on the skin. PCBs in the patient's serum are secreted into the serum since they are lipid-soluble and water-insoluble substances. Consequently, the orifices of the hair follicles get a comedogenic stimulus of PCB and form the acneform eruptions. Similar acneform eruptions have been reported many times as an occupational skin disease, chloracne, due to contact with the chlorinated chemicals (10).

On the other hand, we cannot find an analogous situation with respect to the pigmentation. Probably the PCBs stimulate the melanocyte system in some way. However, the reason for the characteristic circumscribed distribution of pigmented areas has not been elucidated. Some experimental approach would be necessary to ascertain the effect of various PCBs on the melanocyte system.

REFERENCES

- Higuchi, K. Outline. In: PCB Poisoning and Pollution, Kodansha, Academic Press, Tokyo-New York-San Francisco-London, 1976, pp. 3-7.
- Urabe, H., Koda, H., and Asahi, M. Present state of Yusho patients. *Ann. N. Y. Acad. Sci.* 320: 273-276 (1979).
- Asahi, M., Koda, H., Urabe, H., and Toshitani, S. Dermatological symptoms of Yusho—alterations in this decade. *Fukuoka Acta Med.* 70: 172-180 (1979).
- Urabe, H., Asahi, M., and Koda, H. Pigment disorder due to PCB poisoning (Yusho). In: *Biology and Diseases of Dermal Pigmentation*. University of Tokyo Press, Tokyo, 1981, pp. 127-132.
- Goto, M., and Higuchi, K. The symptomatology of Yusho in dermatology. *Fukuoka Acta Med.* 60: 409-431 (1969).
- Toshitani, S., and Kitamura, K. Clinical observation on Yusho, especially further study of its dermatological findings. *Fukuoka Acta Med.* 62: 132-138 (1971).
- Masuda, Y., Kagawa, N., Shimamura, K., Takeda, M., and Kuratsune, M. Polychlorinated biphenyls in the blood of Yusho patients and ordinary persons. *Fukuoka Acta Med.* 65: 25-27 (1974).
- Koda, H., and Masuda, Y. Relation between PCB levels in the blood and clinical symptoms of Yusho patients. *Fukuoka Acta Med.* 66: 624-628 (1975).
- Asahi, M., Toshitani, S., Hino, Y., and Koda, H. Dermatological findings and their analyses in the general examination of Yusho in 1976-1980. *Fukuoka Acta Med.* 72: 223-229 (1981).
- Pochi, P. E. Unit 10-3, Miscellaneous acne disorders. In: *Clinical Dermatology*. Harper & Row, Cambridge-New York, 1980, pp. 1-3.

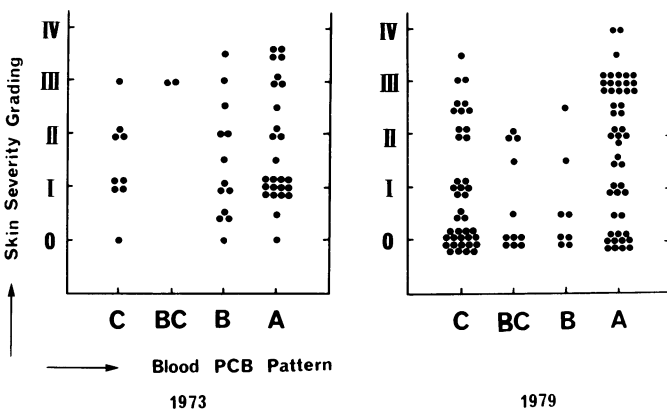


FIGURE 10. Relationship between severity grades of skin changes and blood PCB patterns in Yusho patients.