

Studies of Pancreatic Carcinogenesis in Different Animal Models

by Dante G. Scarpelli,* M. Sambasiva Rao* and Janardan K. Reddy*

Pancreatic carcinomas can be induced in rat, guinea pig and hamster by a variety of carcinogens. The types of neoplasms which arise vary with the species of rodent. In the rat, they consist exclusively of acinar cells, in the other species the lesions are adenocarcinomas resembling those derived from pancreatic ductules and ducts, those in hamster more so than in guinea pigs. Careful sequential studies in the guinea pig and hamster suggest that acinar cells together with ductular and duct cells are involved in the genesis of duct adenocarcinomas. In each rodent model, the acinar cell appears to be quite sensitive to continued exposure to carcinogen. In each instance, acini undergo modulation, and in the guinea pig and hamster, permanent metaplastic transformation to ductlike structures. Such cells assume an enhanced capacity for cell proliferation which persists following cessation of carcinogen treatment. Other studies suggest that adult pancreatic acinar cells possess a surprising degree of plasticity. Their involvement in the pathogenesis of neoplasms resembling pancreatic ducts is not unlike other carcinogenic sequences where extensive cell modulation and metaplasia precede and are an integral part of the neoplastic transformation.

Introduction

In recent years there has been considerable progress in experimental pancreatic carcinogenesis research involving basically three rodent animal models, the rat, guinea pig and Syrian golden hamster. Initial carcinogenesis studies involved implantation of 7,12-dimethylbenzanthracene (DMBA) crystals (1) or DMBA in dextrose pellets (2) into the pancreas of Sprague-Dawley rats. Pancreatic adenocarcinomas consisting of acinar cells developed, on the average, in about 200 days following implantation. Later workers administered carcinogenic substances such as 4-hydroxyaminoquinoline-1-oxide (4HAQO), a carcinogenic metabolite of 4-nitroquinoline-1-oxide (3), azaserine (4), and the hypolipidemic drugs, nafenopin (5) and clofibrate (6,7), and *N*δ-(*N*-methyl-*N*-nitrosocarbamoyl)-*L*-ornithine (MNCO), a methylnitrosourea amino acid (8), systemically, and induced both acinar cell adenomas and adenocarcinomas. Although the rat model has been quite useful, the pancreatic neoplasms they develop do not resemble those that constitute the most common type encountered in humans, namely ductal adenocarcinomas. In the case of the guinea pig, pancreatic adenocarcinomas were induced by the prolonged administration of *N*-methyl-*N*-nitrosourethane (MNUT) (9) in drinking water, or *N*-methyl-*N*-nitrosourea (MNU) by intra-

gastric gavage weekly for 28 weeks or more (10). A variety of *N*-nitrosamines derived from β-oxidation of *N,N*-dipropylnitrosamine induced pancreatic ductal adenocarcinomas in the Syrian golden hamster. Chemically induced pancreatic cancer in both species are morphologically and biologically quite similar to those of man (10-17). These various models are summarized in Table 1. The studies to be reviewed in this communication will detail certain aspects of the pathogenesis of pancreatic cancer in them.

Histogenesis of Chemically Induced Pancreatic Cancer in Various Rodent Species

Rat and Guinea Pig

In both the rat and guinea pig, the pancreatic acinar cell appears to be singularly susceptible to carcinogenesis regardless of the carcinogen employed. Three different carcinogens—4HAQO, (a hydroxylated metabolite of 4-nitroquinoline-1-oxide), DMBA (a polycyclic hydrocarbon), and azaserine (a diazoketone)—all induce acinar cell adenomas and carcinomas in rat pancreas. Since the lesions induced by these carcinogens appear to be strikingly similar (1,3-5), if not identical, the histogenetic sequence that follows may be considered as applying to all of them. The lesions begin as localized

*Department of Pathology and the Cancer Center, Northwestern University Medical School, 303 E. Chicago Ave., Chicago, IL 60611.

Table 1. Animal models of chemically induced pancreatic carcinoma.

Species	Carcinogen	Route of administration	Dosage of carcinogen	Carcinomas induced	Reference
Rat	DMBA	Intrapancreatic implant	2-10 mg(?) ^a	Acinar	(1,2)
	4HAQO	IV	6-13 mg/kg ^a	Acinar	(3)
	Azaserine	IP	5 mg/kg ^a	Acinar	(4)
	Nafenopin	Diet	0.1% (wt/wt) ^b	Acinar	(5)
	Clofibrate	Diet	0.1% (wt/wt) ^b	Acinar	(6,7)
	MNCO	IP	10-20 mg/kg ^c	Acinar	(8)
Guinea pig	MNUT	In drinking water	2.5 mg/kg ^d	Adenocarcinoma	(9)
	MNU	Gavage	10 mg/kg ^c	Adenocarcinoma	(10)
Hamster	BHP	SC	250-500 mg/kg ^c	Ductal	(11)
	BAP	SC	17.5-20 mg/kg ^c	Ductal	(12)
	BOP	SC	10-30 mg/kg ^c	Ductal, rare acinar	(13)
	HPOP	SC	9-40 mg/kg ^c	Ductal	(14)
	MOP	SC	1.75-3.5 mg/kg ^c	Ductal	(15)
	DMNM	Gavage	18-50 mg/kg ^c	Ductal	(16)

^a Single administration.

^b Administered continuously.

^c Administered weekly.

^d Daily administration.

nests of acini which undergo hyperplastic growth. When these are microscopic in size, they are described as "foci;" larger lesions which are grossly visible, measuring 1 to 10 mm in diameter, are referred to as "nodules." Acinar cells in foci and nodules, regardless of their size, are uniformly cytologically abnormal. Their nuclei are larger and more basophilic than those of normal acinar cells; except for this alteration, the cells appear normal in every other respect, including a full complement of zymogen granules. In larger nodules, acinar cells showed a somewhat greater degree of nuclear and nucleolar variability, as well as mitotic activity. Ultrastructurally, zymogen-rich cells in foci and nodules showed a normal complement of cell organelles and zymogen granules which were morphologically identical to those in normal acinar cells.

The classification of large nodules as adenomas is based more on their apparent potential for semiautonomous growth rather than objective cytologic criteria. Large nodules and adenomas are usually not encapsulated. The diagnosis of acinar cell adenocarcinoma and probable carcinomas is based on either decreased acinar cell differentiation (Fig. 1) or evidence of extrapancreatic spread or both. Metastases occur both in highly differentiated zymogen granule laden acinar cell tumors as well as poorly differentiated tumors that bear little to no resemblance to their cell of origin.

Recent findings (18) suggest that the histogenesis and pathogenetic sequence of acinar cell tumors may be more complex than previously thought. It turns out that a hitherto unidentified acinar cell variant appears during the pathogenesis of acinar cell tumors—the so-called basophilic cell. In contrast to zymogen-rich acinar cells which stain with the acidophilic component of hematoxylin eosin stain, the basophilic cells do not

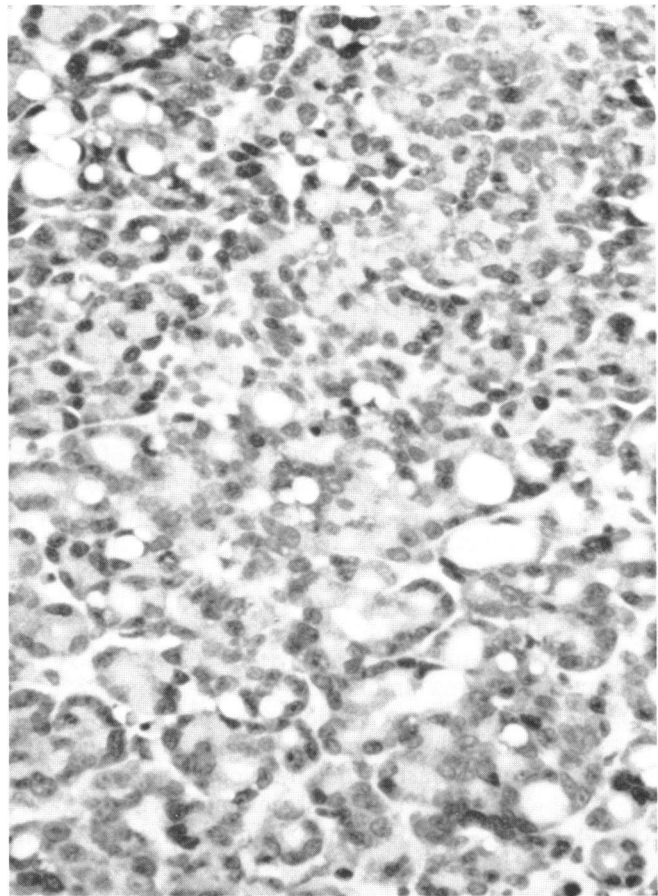


FIGURE 1. Transplantable rat pancreatic acinar cell carcinoma showing moderately differentiated acini containing zymogen granules. $\times 320$.

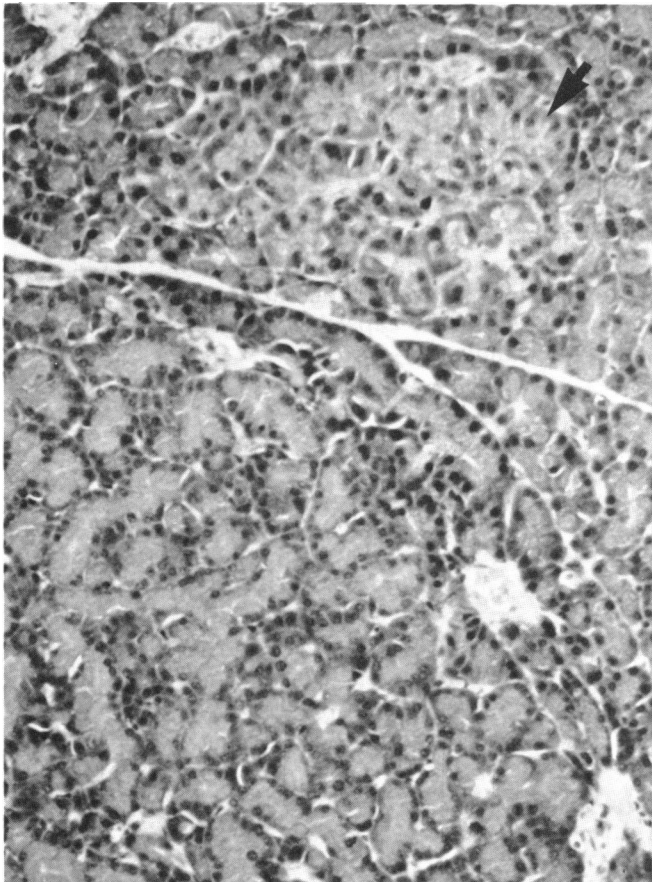


FIGURE 2. 4HAQO-induced basophilic focus (arrow) adjacent to an eosinophilic nodule. $\times 190$.

Table 2. Mitotic index and nuclear labeling of normal pancreas and acidophilic and basophilic foci following a single dose of 4-hydroxyaminoquinoline-1-oxide.

Tissue	Mitotic index	Labeled nuclei per 1000 cells
Normal pancreas	0	1 \pm 1
Acidophilic foci	2.75 \pm 1.27	23.2 \pm 3.15
Basophilic foci	0.125	1.2 \pm 1.2

bind eosin to a significant degree because they contain few, and more rarely moderate, numbers of zymogen granules (Fig. 2). At the level of ultrastructure, the remainder of cytoplasmic constituents are both morphologically as well as quantitatively indistinguishable from those in normal pancreatic acinar cells. The nucleus is parabasal, enlarged and irregular with a normal chromatin pattern and contains a large nucleolus. Mitoses are quite rare in acinar cells in basophilic foci. Studies to quantitate and compare cell replication in acidophilic and basophilic foci, and acidophilic nodules to adjacent normal pancreas established that there were significant

differences as documented in Table 2. Pilot unpublished experiments aimed at elucidating the sequence of their development suggest that between 8 and 12 weeks after IV injection of 4HAQO there is a marked proliferation of basophilic acinar cells which leads to the formation of foci which then appear to lose their capacity for growth and become quiescent. By contrast, 4HAQO-induced acidophilic cells show a capacity for increased growth which apparently persists as these evolve from foci to nodules and, finally, to adenocarcinomas. Our preliminary results suggest that the cells which comprise basophilic foci may be endstage cells which may not

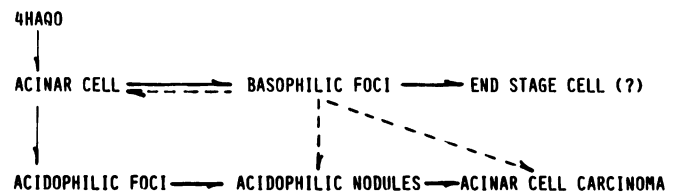


FIGURE 3. Developmental sequence of acinar cell carcinoma showing (—) established and (---) possible pathways and relationships.

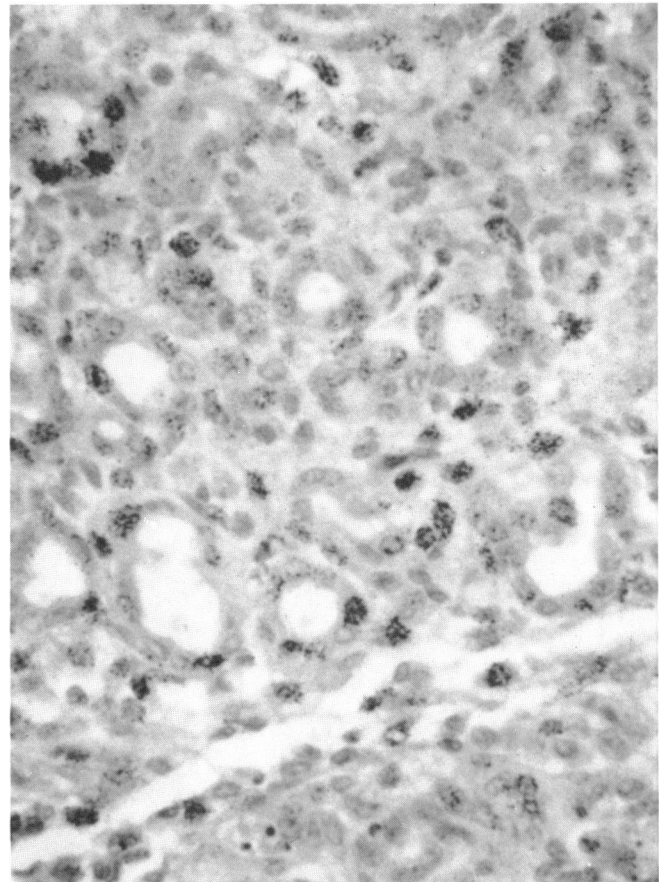


FIGURE 4. Pseudoductular change involving acinar cells in the pancreas of a guinea pig treated with the carcinogen 4HAQO. Numerous nuclei labeled with $[^3\text{H}]$ -thymidine indicate increased DNA synthesis in altered acinar cells. $\times 190$.

participate in acinar cell carcinogenesis (Fig. 3). Other alternatives are that they represent a quiescent acinar cell pool which may, under proper conditions, enter the proliferating pool and become involved in the development of tumor. The precise significance of basophilic acinar cell foci and their relation to acinar cell cancer remains unknown.

A second feature of acinar cell carcinogenesis which is both unexpected and interesting is a modulation of acinar cells to phenotypes that morphologically closely resemble ductular elements of the pancreas. Such changes have been encountered in the rat with DMBA (1,2), azaserine (4), and in the guinea pig with 4HAQO and MNU (10). 4HAQO, nafenopin, clofibrate and MNCO apparently do not induce the development of the ductular phenotype from acinar cells in the rat. The changes consist of dilatation of acini which progresses with continued exposure to carcinogen and is accompanied by shedding of apical cytoplasm and variable loss of zymogen granules (Fig. 4). These alterations begin early and persist throughout tumorigenesis. They may be sufficiently pronounced so that definitive diagnosis of the neoplasms as acinar in origin may be difficult, leading some investigators to comment and speculate on their histogenesis (1,2,4,). The changes which have been variously referred to as pseudoductular or dediffer-

entiation clearly represent a stable cell modulation in response to carcinogen. In the guinea pig, ductular morphology of the carcinomas is more consistent and marked than in the rat, and in this respect, closely resembles true ductular and ductal adenocarcinomas (Fig. 5). However, their acinar cell derivation is apparent by the presence of zymogen granules in precursor lesions including severely atypical ones (10,19). Their involvement and ultimate fate in pancreatic carcinogenesis in the guinea pig is not entirely established because the chemically induced pancreatic carcinomas do not appear to retain the capacity to synthesize and store zymogen granules.

Hamster

In the hamster, exposure to pancreaticotropic *N*-nitrosamines leads to the development of ductal adenocarcinomas almost exclusively. Their histogenesis appear to be somewhat more complex than pancreatic cancer in the rat and guinea pig and have been the subject of much study and controversy. Before beginning on the details of the development of chemically induced ductal carcinomas in the hamster, it should be noted that in contrast to the situation with the carcinogens which induce pancreatic cancer in the rat, much is known

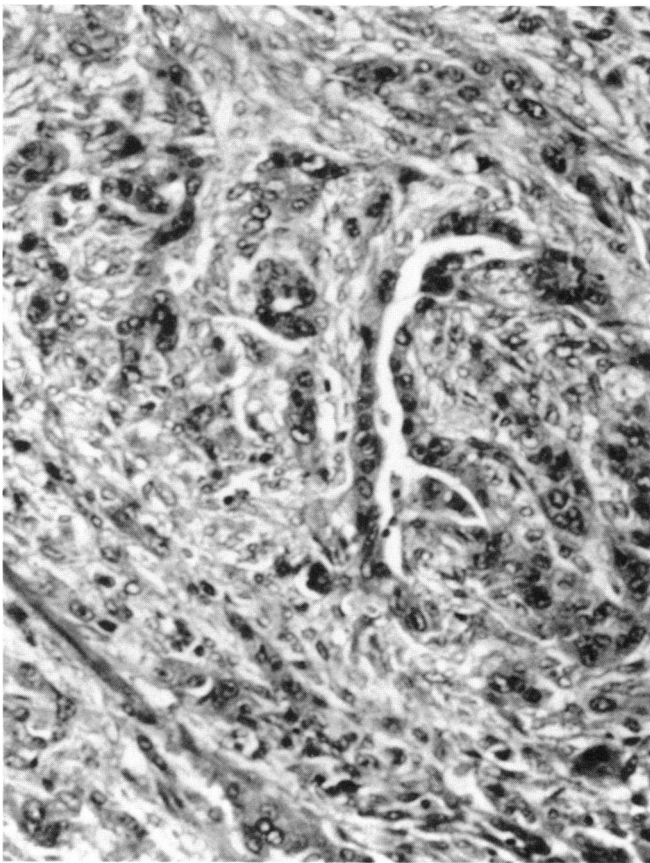


FIGURE 5. Moderately well-differentiated adenocarcinoma induced by MNU in guinea pig pancreas. $\times 180$.

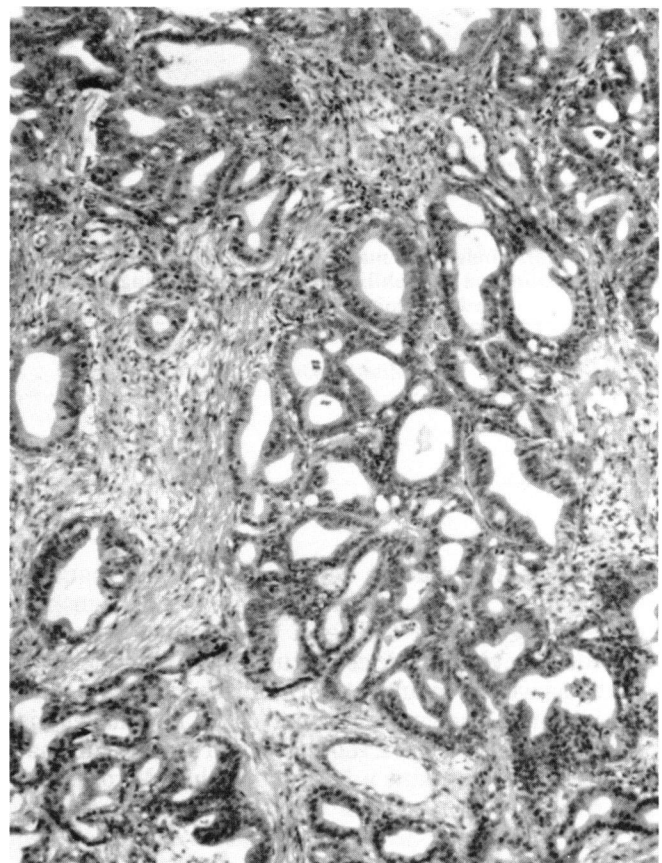


FIGURE 6. Well-differentiated ductal adenocarcinoma of hamster pancreas. $\times 140$.

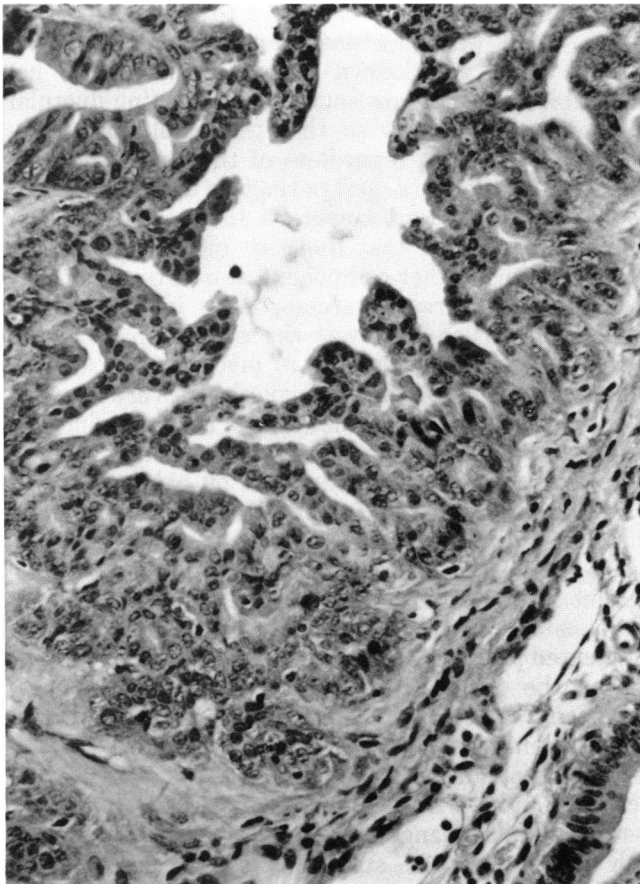


FIGURE 7. Intraductal adenocarcinoma of a medium-size duct in hamster pancreas showing cribriform pattern of epithelial proliferation. $\times 270$.

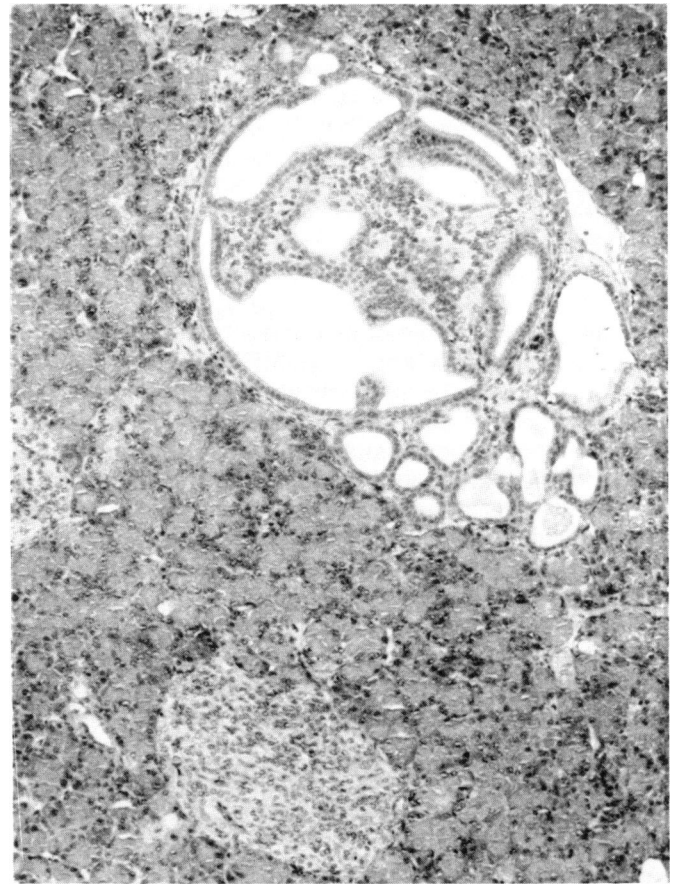


FIGURE 8. Intra and perinsular cystadenomatous ductal proliferation in hamster pancreas following chronic administration of BOP $\times 110$.

about the metabolism of those that are carcinogenic for hamster pancreas (20-31). The initial and most detailed histologic descriptions of *N*-nitrosamine induced pancreatic carcinomas in hamsters document that they are adenocarcinomas (Fig. 6) that closely resemble the ductular and ductal pancreatic cancers of humans (32-35). Sequential studies of histogenesis (35,36), which are essentially in agreement, identified a number of early lesions which appeared first in common duct epithelium consisting of hypertrophy, hyperplasia and metaplasia. As these progress, the lesions become papillary, often filling the lumen. Eventually, such epithelial lesions evolve into *in situ*, and invasive adenocarcinomas. A similar sequence is also observed in the main and secondary pancreatic ducts (Fig. 7). Ductular lesions consist of proliferative epithelium which undergo increasing atypia and finally neoplastic transformation with coalescence into malignant multiductular complexes. In one study (35), proliferation of islets, and the consistent appearance of ductules within and around them were identified (Fig. 8). These ductules eventually underwent malignant change. In a subsequent communication (37) considerable emphasis is placed on the role of islets in the genesis of pancreatic

Table 3. Uptake of ^{14}C -HPOP by isolated islets and acinar cells of hamster pancreas and its competitive inhibition by ^3H -3-OMG.

Compound	Concentration, mM	Uptake, pmole ^{14}C -HPOP/mg protein/30 min ^a			
		Islets	% Inhibition	Acinar cells	% Inhibition
^{14}C HPOP	5	966.99		987.90	
^{14}C HPOP + ^3H 3-OMG	5	787.38	18.57	679.18	31.25
^{14}C HPOP + ^3H 3-OMG	10	553.62	42.7	311.77	68.44

^a Each value is the mean of two separate experiments.

ductal adenocarcinoma in the hamster. It has been suggested that the response of islets to the pancreatic carcinogens BOP, BHP and DMNM is through the common metabolite HPOP' (21,22). This is presumably because HPOP exists in two tautomeric forms, one of which is cyclic, closely resembling the pyranose form of hexose sugars (22), which is thought to be preferentially bound and taken up by islets in contrast to other pancreatic cells. Recent studies in our laboratory investigated this possibility. A comparison of ^{14}C -HPOP

uptake by isolated islets with that of acinar cells from hamster pancreas, and the competitive effect of ^3H -3-O-methyl glucose (^3H -3-OMG), an analog of glucose which is not metabolized, are shown in Table 3. The results show that the uptake of HPOP by islet cells is equal to that by acinar cells. HPOP uptake by acinar cells is inhibited about 1.6 times more by 3-OMG than its uptake by islet cells. Although competitive inhibition by 3-OMG supports the notion that HPOP probably enters both islet and acinar cells by the same transport mechanism as does glucose, there appears to be no evidence for its preferential uptake by islet cells. An elegant study (38) in which ^3H DMNM was localized in hamster pancreas by ultrastructural autoradiography has shown label in both acinar and duct epithelial cells. In subsequent experiments (30) we corroborated and extended these findings by demonstrating that all the component cells of pancreas can metabolize DMNM, and that acinar and islet cells do not differ quantitatively in their capacity to do so. The following, when coupled to the fact that islet cells represent only about 1.7% of the total cell population of rodent pancreas as contrasted with 82% for acinar cells (39), tends to lessen the probability that islet cells are important in pancreatic carcinogenesis. An attempt (40) to establish that

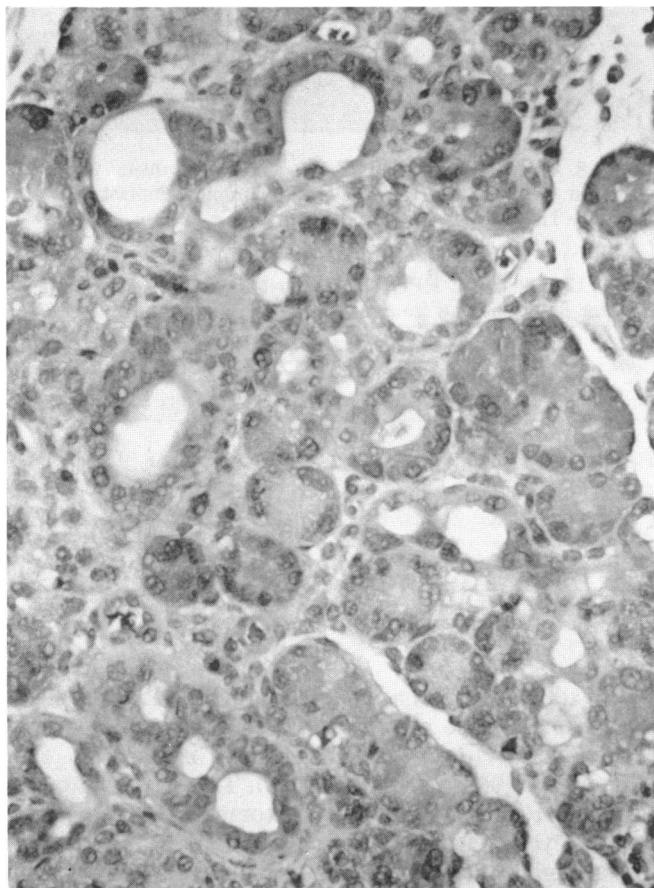


FIGURE 9. Pseudoductules arising from acini in hamster pancreas 3 weeks after administration of 50 mg/kg of DMNM. $\times 270$.

ductular cells are highly sensitive to the carcinogenic effects of BOP was unfortunately not entirely successful because as is well known (35) it is difficult, if not impossible, to clearly distinguish proliferating ductular cells from ductal cells so that the resulting tumors appear to be ductal regardless of their cell of origin. Therefore, while intra- and perinsular ductules may be involved in ductal carcinogenesis there is no clear or compelling evidence that they are more important in this regard than other component cells of the pancreas.

A facet of pancreatic carcinogenesis in the hamster which has intrigued us was the early appearance of pseudoductular change (Fig. 9) involving acinar cells (36). The sequence of morphologic changes are identical to those encountered in acinar cells of rat and guinea pig pancreas. As has been shown in the guinea pig (19), these alterations are accompanied by enhanced DNA synthesis and acinar cell replication. Although, some acinar cell proliferation may be in response to cell death due to the toxic effects of the carcinogen (42), it cannot account for the sustained proliferation that is seen in the hamster model during carcinogenesis (36,41). Their augmented proliferation is probably due to their adaptation to the toxic and growth suppressive effects of carcinogen, a phenomenon that has been well established when cells are chronically exposed to carcinogenic compounds (43,44). It is also noteworthy that increased growth of acinar cells that have undergone pseudoductular change continues long after treatment with BOP has been stopped (36), suggesting that although they are not yet neoplastic cells, they have been significantly and perhaps irreversibly altered. Further, their enhanced sustained replication renders them much more sensitive to the effects of carcinogens than more quiescent cells of the pancreas. Attempts in our laboratory to unequivocally establish by morphologic means that pseudoductules derived from acini undergo malignant change and become ductal adenocarcinoma cells have not been unequivocally convincing. However, recently a series of detailed and systematic studies utilizing electron microscopy have clearly documented that acinar cell-derived pseudoductules do ultimately become malignant (45-47).

The histogenesis of pancreatic cancer, as noted earlier, involves not only pseudoductules derived from acinar cells which coalesce into adenocystic complexes that subsequently undergo malignant change, but also the epithelium lining the major pancreatic duct and its

Table 4. Peak [^3H]-thymidine incorporation and mitotic index of acinar, islet and ductal cells in regenerating hamster pancreas.

	Acinar ^a	Islet ^a	Ductal ^a
[^3H]-thymidine labeled nuclei/100 cells ^b	224 \pm 25	23 \pm 9.2	19 \pm 7.5
Mitotic index mitoses/100 cells	16.8 \pm 5.0	1.8 \pm 0.86	1.4 \pm 0.6

^a Values are means \pm SE.

^b [^3H]-Thymidine incorporation 60 hr after initiation of regeneration.

branches. Thus, several somewhat different developmental pathways appear to be operative in the genesis of ductal adenocarcinoma in the hamster pancreas. One pathway involves modulation of the highly differentiated acinar cell to the less specialized ductular cell. In the second, the duct cell is the direct target of the carcinogen. In this regard, it should be noted that carcinogen not only enters duct cells from the blood but that they are also exposed to active forms of the carcinogen present in the pancreatic juice (21), presumably released from acinar cells. Recently we decided to approach the question of histogenesis by exploiting an interesting characteristic of pancreatic regeneration in the hamster, namely that the bulk of the regenerative response appears to be due to the proliferation of acinar cells (48). A comparison of DNA synthesis as measured by incorporation of ^3H -thymidine in the various cells of the pancreas during regeneration is shown in Table 4. This is an excellent model with which to test whether acinar cells are involved in the genesis of pancreatic ductal cancer since the replicating acinar cells are much more sensitive to the effects of a carcinogen. Accordingly, BOP was injected 60 hr after regeneration was initiated, when 22% of acinar cells are in S phase of the cell cycle, representing an almost synchronous wave of DNA synthesis. Such treatment led to more than a 50% increase in tumor incidence over that in a control group in which an identical dose of BOP was administered to animals in which pancreatic injury and subsequent regeneration were not induced (49). Even more significant is the fact that the most common lesions encountered in the animals exposed to carcinogen during pancreatic regeneration were acinar-derived pseudoductules and cystadenomatous complexes, and that the neoplasms induced were exclusively ductal adenocarcinomas. It is noteworthy that these cancers developed in animals in whom the cell at greatest risk for carcinogenesis in the regenerating pancreas model was the acinar cell.

Plasticity of Pancreatic Acinar Cells

In the foregoing brief review of chemical carcinogenesis of the pancreas, the acinar cell has emerged as a common denominator. In each of the rodent species considered, the highly specialized acinar cell responds to the injurious effects of carcinogen by changing to a phenotype closely resembling the less differentiated ductular cell. In the hamster, pseudoductules form quite readily following even relatively minor damage such as mild crush injury, and therefore may represent a nonspecific reaction to sublethal damage. Although, the long-term stability of the change remains to be unequivocally established, experimental evidence to date suggests that it may be protracted. Pseudoductules induced by crush injury have been found to persist for as long as 3 months (Rao and Scarpelli, unpublished

observations). Conversions of one cell type to another in the adult organism are well documented and frequently encountered in a variety of pathologic conditions. Such an alteration in differentiation is referred to as metaplasia, and almost always involves the conversion of a highly specialized cell to a less specialized one. For example, the change of mucus-secreting goblet cells in bronchial epithelium to less specialized squamous epithelial cells in the lungs of heavy smokers. Thus, the conversion of an acinar cell to a ductular one should not be surprising. It seems appropriate, therefore, to consider pseudoductular formation as a metaplastic change. However, acceptance of this possibility has been slow because such a conversion goes counter to the sequence that appears to be operative during embryological development of pancreas, namely that acini and islets develop from pre-existing ducts.

An even more marked change in differentiation can be induced by a single exposure of regenerating hamster pancreatic acinar cells to BOP. In this instance, acinar cells undergo transformation to liver cells which are stable and, once induced, remain for the lifetime of the animal (50). These cells possess many of the characteristics of adult hepatocytes such as light and ultrastructural morphology, synthesis of glycogen and albumin, peroxisome proliferation and synthesis of associated enzymes following exposure to hypolipidemic agents, induction of aryl hydrocarbon hydroxylase by phenobarbital, cell proliferation following subtotal hepatectomy and iron accumulation with the administration of excessive iron dextran (51,52). In an effort to establish the pancreatic cell from which hepatocytes originate, acinar cell atrophy was induced by ligation of one of three segments of the hamster pancreas. In this model, ducts and islets in the ligated segment remain relatively unchanged. Animals prepared in this way were subjected to the protocol for induction of hepatocytes in pancreas. Liver cells were induced in the normal segments of the pancreas but were absent in the atrophic one—strong support that the hepatocytes are derived by redirected differentiation of acinar cells (unpublished observations, Scarpelli and Rao.)

The induction of hepatocytes from adult acinar cells raises some interesting questions about gene stability and expression in the adult state. Current dogma holds that in embryonic development, cells lose their extensive potentialities and become fixed to a specific pathway of differentiation known as determination (53–55). Although determination occurs at different times during development, it is generally considered to be fixed relatively early. How then can an adult acinar cell, presumably determined early in its developmental history, undergo a complete switch of differentiation and assume many of the structural and functional characteristics of an apparently differentiated liver cell? Since it apparently requires cell replication for the change to occur, it may mean that switching off pancreas specific genes and activation of liver specific ones can only occur when DNA is less condensed and

exposed as it is in S phase of the cell cycle. Is it possible that given the proper stimulus, any fully differentiated cell can be induced to redirect its differentiation along a new pathway? Finally, is the surprising plasticity and ease with which adult acinar cells in hamster and guinea pig undergo pseudoductular formation related to the absence of pancreatic acinar cell carcinomas in both species? Since carcinogenesis results in a defect of differentiation, it seems reasonable to study initiation and regulation of differentiation in acinar cells which appear to be an important target cell in pancreatic carcinogenesis.

This work was supported by the Marie A. Fleming and Edith Patterson Cancer Research Funds, USPHS Grants CA 34051, CA 16954, and Contract NCI-E-72-3271. The authors gratefully acknowledge the excellent technical assistance of Matthew Connors and thank Nancy Schwank for preparing the manuscript.

REFERENCES

- Dissin, J., Mills, L. R., Mains, D. L., Black, O., Jr., and Webster, P. D., III. Experimental induction of pancreatic adenocarcinoma in rats. *J. Natl. Cancer Inst.* 55: 857-864 (1975).
- Bockman, D. E., Black, O., Jr., Mills, L. R., and Webster, P. D. Origin of tubular complexes developing during induction of pancreatic adenocarcinoma by 7,12-dimethylbenz(a)anthracene. *Am. J. Pathol.* 90: 645-651 (1978).
- Hayashi, Y., and Hasegawa, T. Experimental pancreatic tumor in rats after intravenous injection of 4-hydroxyaminoquinoline 1-oxide. *Gann* 62: 329 (1971).
- Longnecker, D. S., and Curphey, T. J. Adenocarcinoma of the pancreas in azaserine-treated rats. *Cancer Res.* 35: 2249-2258 (1975).
- Reddy, J. K., and Rao, M. S. Malignant tumors in rats fed nafenopin, a hepatic peroxisome proliferator. *J. Natl. Cancer Inst.* 59: 1645-1650 (1977).
- Svoboda, D. J., and Azarnoff, D. L. Tumors in male rats fed ethylchlorophenoxyisobutyrate, a hypolipidemic drug. *Cancer Res.* 39: 3419-3428 (1979).
- Reddy, J. K., and Qureshi, S. A. Tumorigenicity of the hypolipidaemic peroxisome proliferator ethyl- α -p-chlorophenoxyisobutyrate (clofibrate) in rats. *Brit. J. Cancer* 40: 476-482 (1979).
- Longnecker, D. S., Curphey, T. J., Lilja, H. S., French, J. I., and Daniel, D. S. Carcinogenicity of a methylnitrosourea amino acid in rats. *Fed. Proc.* 37: 231 (1978).
- Druckery, H., Ivankovic, S., Bucheler, J., Preussmann, R., and Thomas, C. Erzeugung von Magen-und Pankreas-Krebs beim Meerschweinchen durch Methylnitroso-harnstoff und -urethan. *Z. Krebsforsch.* 71: 167-182 (1968).
- Reddy, J. K., and Rao, M. S. Pancreatic adenocarcinoma in inbred guinea pigs induced by *N*-methyl-*N*-nitrosourea. *Cancer Res.* 35: 2269-2276 (1975).
- Pour, P., Kruger, F. W., Althoff, J., Cardesa, A., and Mohr, U. Cancer of the pancreas induced in the Syrian golden hamster. *Am. J. Pathol.* 76: 349-354 (1974).
- Pour, P., Althoff, J., Gingell, R., Kupper, R., Kruger, F., and Mohr, U. *N*-Nitroso-bis(2-acetoxypropyl)amine as a further pancreatic carcinogen in Syrian golden hamsters. *Cancer Res.* 36: 2877-2884 (1976).
- Pour, P., Althoff, J., Kruger, F. W., and Mohr, U. A potent pancreatic carcinogen in Syrian hamsters: *N*-nitroso-bis(2-oxopropyl)amine. *J. Natl. Cancer Inst.* 58: 1449-1452 (1977).
- Pour, P., Wallcave, L., Gingell, R., Nagel, D., Lawson, T., Salmasi, S., and Tines, S. Carcinogenic effect of *N*-nitroso(2-hydroxypropyl) (2-oxopropyl)amine, a postulated proximate pancreatic carcinogen in Syrian hamsters. *Cancer Res.* 39: 3828-3833 (1979).
- Pour, P., Gingell, R., Langenbach, R., Nagel, D., Grandjean, C., Lawson, T., and Salmasi, S. Carcinogenicity of *N*-nitrosomethyl(2-oxopropyl)amine in Syrian hamsters. *Cancer Res.* 40: 3585-3590 (1980).
- Mohr, U., Reznik, G., Emminger, E., and Lijinsky, W. Induction of pancreatic duct carcinomas in the Syrian hamster with 2,6-dimethylnitrosomorpholine. *J. Natl. Cancer Inst.* 58: 429-432 (1977).
- Longnecker, D. S., Curphey, T. J., French, J. I., and Lilja, H. S. Response of the Syrian hamster to a nitrosourea amino acid carcinogen. *Cancer Letters* 8: 163-168 (1979).
- Rao, M. S., Upton, M. P., Subbarao, V., and Scarpelli, D. G. Two populations of cells with differing proliferative capacities in atypical acinar cell foci induced by 4-hydroxyaminoquinoline-1-oxide in the rat pancreas. *Lab. Invest.* 46: 527-534 (1982).
- Rao, M. S., and Reddy, J. K. Histogenesis of pseudo-ductular changes induced in the pancreas of guinea pigs treated with *N*-methyl-*N*-nitrosourea. *Carcinogenesis* 1: 1027-1037 (1980).
- Gingell, R., Wallcave, L., Nagel, D., Kupper, R., and Pour, P. Common metabolites of *N*-nitroso-2,6-dimethylmorpholine and *N*-nitrosobis(2-oxo-propyl)amine in Syrian hamster. *Cancer Letters* 2: 47-52 (1976).
- Gingell, R., and Pour, P. Metabolism of the pancreatic carcinogen *N*-nitrosobis(2-oxopropyl)amine after oral and intraperitoneal administration to Syrian golden hamsters. *J. Natl. Cancer Inst.* 60: 911-913 (1978).
- Gingell, R., Wallcave, L., Nagel, D., Kupper, R., and Pour, P. Metabolism of the pancreatic carcinogens *N*-nitrosobis(2-oxopropyl)amine and *N*-nitrosobis(2-hydroxypropyl)amine in Syrian hamster. *J. Natl. Cancer Inst.* 57: 1175-1178 (1976).
- Gingell, R., Nagel, D., and Kupper, R. Differential metabolism of geometrical isomers of *N*-nitroso-2,6-dimethylmorpholine in the hamster. *Xenobiotica* 8: 439-443 (1978).
- Gingell, R., Brunk, G., Nagel, D., and Pour, P. Metabolism of three radiolabeled pancreatic carcinogenic nitrosamines in hamsters and rats. *Cancer Res.* 39: 4579-4583 (1979).
- Gingell, R., Brunk, G., Nagel, D., Wallcave, L., Walker, B., and Pour, P. Metabolism and mutagenicity of *N*-nitroso-2-methoxy-2,6-dimethylmorpholine in hamsters. *J. Natl. Cancer Inst.* 64: 157-161 (1980).
- Scarpelli, D. G., Rao, M. S., Subbarao, V., Beversluis, M., Gurka, D. P., and Hollenberg, P. F. Activation of nitrosamines to mutagens by postmitochondrial fraction of hamster pancreas. *Cancer Res.* 40: 67-74 (1980).
- Whalley, C. E., Iqbal, Z. M., and Epstein, S. S. *In vivo* and microsomal metabolism of the pancreatic carcinogen *N*-nitrosobis(2-oxopropyl)amine by the Syrian golden hamster. *Cancer Res.* 41: 482-486 (1980).
- Lawson, T. A., Hegelson, A. S., Grandjean, C. J., Wallcave, L., and Nagel, D. The formation of *N*-nitrosomethyl(2-oxopropyl)amine from *N*-nitrosobis(2-oxopropyl)amine *in vivo*. *Carcinogenesis* 2: 845-849 (1981).
- Rao, M. S., Scarpelli, D. G., and Lijinsky, W. Carcinogenesis in Syrian hamsters by *N*-nitroso-2,6-dimethylmorpholine, its *cis* and *trans* isomers, and the effect of deuterium labeling. *Carcinogenesis* 2: 731-735 (1981).
- Scarpelli, D. G., Kokkinakis, D. M., Rao, M. S., Subbarao, V., Luettke, N., and Hollenberg, P. F. Metabolism of the pancreatic carcinogen *N*-nitroso-2,6-dimethylmorpholine by hamster liver and component cells of pancreas. *Cancer Res.* 42: 5089-5095 (1982).
- Underwood, B., and Lijinsky, W. Comparative metabolism of 2,6-dimethylnitrosomorpholine in rats, hamsters, and guinea pigs. *Cancer Res.* 42: 54-58 (1982).
- Pour, P., Kruger, F. W., Althoff, J., Cardesa, A., and Mohr, U. Cancer of the pancreas induced in the Syrian golden hamster. *Am. J. Pathol.* 76: 349-358 (1974).
- Pour, P., Mohr, U., Cardesa, A., Althoff, J., and Kruger, F. W. Pancreatic neoplasms in an animal model: morphological, biological and comparative studies. *Cancer* 36: 379-389 (1975).

34. Pour, P., Althoff, J., Kruger, F. W., and Mohr, U. A potent pancreatic carcinogen in Syrian hamsters *N*-nitrosobis(2-oxopropyl)amine. *J. Natl. Cancer Inst.* 58: 1449-1453 (1977).
35. Pour, P., Althoff, J., and Takahasi, M. Early lesions of pancreatic ductal carcinoma in the hamster model. *Am. J. Pathol.* 88: 291-308 (1977).
36. Scarpelli, D. G., and Rao, M. S. Pathogenesis of pancreatic carcinoma in hamsters induced by *N*-nitrosobis(2-oxopropyl)amine (BOP). *Fed. Proc.* 37: 232 (1978).
37. Pour, P. Islet cells, a component of pancreatic ductal neoplasms. *Am. J. Pathol.* 90: 295-310 (1978).
38. Reznick-Schuller, H. M., Lijinsky, W., and Hogue, B. F., Jr. Electron microscopic autoradiography of the pancreas in the hamster treated with tritiated *N*-nitroso-2,6-dimethylmorpholine. *Cancer Res.* 40: 2245-2251 (1980).
39. Bolender, R. P. Stereological analysis of the guinea pig pancreas 1. Analytical model and quantitative description of nonstimulated pancreatic exocrine cells. *J. Cell Biol.* 61: 269-287 (1974).
40. Takahasi, M., Pour, P., Althoff, J., and Donnelly, T. Sequential alteration of the pancreas during carcinogenesis in Syrian hamsters by *N*-nitrosobis(2-oxopropyl)amine. *Cancer Res.* 37: 4602-4607 (1977).
41. Levitt, M. H., Harris, C. C., Squire, R., Springer, S., Wenk, M., Mollo, C., Thomas, D., Kingsbury, E., and Newkirk, C. Experimental pancreatic carcinogenesis 1. Morphogenesis of pancreatic adenocarcinoma in the Syrian golden hamster induced by *N*-nitroso-bis(2-hydroxypropyl)amine. *Am. J. Pathol.* 88: 5-15 (1977).
42. Farber, E., Parker, S., and Gruenstein, M. The resistance of putative pre-malignant liver cell populations, hyperplastic nodules to the acute cytotoxic effects of some hepatocarcinogens. *Cancer Res.* 36: 3879-3887 (1976).
43. Laishes, B. A., Roberts, E., and Farber, E. *In vitro* measurement of carcinogen-resistant liver cells during hepatocarcinogenesis. *Int. J. Cancer* 21: 186-193 (1978).
44. Solt, D., Medline, A., and Farber, E. Rapid emergence of carcinogen-induced hyperplastic lesions in a new model for the sequential analysis of liver carcinogenesis. *Am. J. Pathol.* 88: 595-610 (1977).
45. Flaks, B., Moore, M. A., and Flaks, A. Ultrastructural analysis of pancreatic carcinogenesis: morphological characterization of *N*-nitrosobis(2-hydroxypropyl)amine-induced neoplasms in the Syrian hamster. *Carcinogenesis* 1: 423-437 (1980).
46. Flaks, B., Moore, M. A., and Flaks, A. Ultrastructural analysis of pancreatic carcinogenesis. III. Multifocal cystic lesions induced by *N*-nitrosobis(2-hydroxypropyl)amine in the hamster exocrine pancreas. *Carcinogenesis* 1: 693-705 (1980).
47. Flaks, B., Moore, M. A., and Flaks, A. Ultrastructural analysis of pancreatic carcinogenesis. IV. Pseudoductular transformation of acini in the hamster pancreas during *N*-nitrosobis(2-hydroxypropyl)amine carcinogenesis. *Carcinogenesis* 2: 1241-1253 (1980).
48. Scarpelli, D. G., Rao, M. S., Subbarao, V., and Beversluis, M. Regeneration of Syrian golden hamster pancreas and covalent binding of *N*-nitroso-2,6-³H-dimethylmorpholine. *Cancer Res.* 41: 1051-1057 (1981).
49. Scarpelli, D. G., Rao, M. S., and Subbarao, V. Augmentation of carcinogenesis by *N*-nitrosobis(2-oxopropyl)amine administered during S phase of the cell cycle in regenerating hamster pancreas. *Cancer Res.* 43: 611-616 (1983).
50. Scarpelli, D. G., and Rao, M. S. Differentiation of regenerating pancreatic cells into hepatocyte-like cells. *Proc. Natl. Acad. Sci. (U.S.)* 78: 2577-2581 (1981).
51. Rao, M. S., Reddy, M. K., Reddy, J. K., and Scarpelli, D. G. Response of chemically-induced hepatocyte-like cells in hamster pancreas to methyl clofenapate, a peroxisome proliferator. *J. Cell Biol.* 95: 50-56 (1982).
52. Rao, M. S., Subbarao, V., Luetteke, N., and Scarpelli, D. G. Further characterization of carcinogen-induced hepatocyte-like cells in hamster pancreas. *Am. J. Pathol.* 110: 89-94 (1983).
53. Lewis, W. H. Transplantation of the lips of the blastopore in *Rana palustris*. *Am. J. Anat.* 7: 137-143 (1907).
54. Spemann, H. Über die Determination der ersten Organanlagen des Amphibienembryo. I-IV. *Arch. Entwicklungsmech. Organismen* 43: 448-555 (1918).
55. Grobstein, C. Differentiation of vertebrate cells. In: *The Cell: Biochemistry, Physiology, Morphology* (J. Brachet and A. E. Mirsky, Eds.), Vol. 1, Academic Press, New York, 1959, pp. 437-496.