

Cellular Structure, Function and Organization in the Lower Respiratory Tract

by Roger Breeze* and Margaret Turk*

First and foremost, the lung is considered an organ of gas exchange. The earliest electron microscopical studies concentrated on features related to this function, notably the nature, origin and organization of the alveolar lining epithelium, contentious issues that had not been answered with the limited resolution of the light microscope. More recently, the perspective of relationships between the various pulmonary cell populations has changed rapidly, with wider recognition of the lung as a hemodynamic, immunologic and metabolic organ, necessarily equipped with complex systems for the maintenance, protection and repair of normal structures in the face of constant exposure to pollutants or infectious agents derived from the external or interval environment.

Cells of the Pulmonary Airways

The tracheobronchial lining is a tall-columnar, pseudostratified epithelium in which at least 13 cell types, 11 epithelial and 2 mesenchymal, have been identified by electron microscopy (1). Not all of these cells are found in every species, and most of the epithelium consists of ciliated and mucus-secreting cells, those which move or elaborate the surface mucous layer. Scattered along the length of the conducting airways, from the trachea to the bronchioles, are intraepithelial corpuscles known as neuroepithelial bodies.

An important function of the membrane lining larger airways is the production of mucus, which covers the luminal surface. The mucus-secreting apparatus consists of the epithelial serous and goblet cells and the submucosal mucous glands, which are largely lined by serous and mucous cells. Glands are sparse in small bronchi and absent from the bronchioles. Only six cell types, the ciliated, brush, basal, K (Kultschitsky-like), nonciliated bronchiolar epithelial (Clara) cells and the globule leukocyte have been recorded in the bronchioles, where the epithelium is a simple, single layer. Mucus-secreting cells are sparse in the bronchioles of most species, except the cat, in health.

*Department of Microbiology and Pathology, Washington State University, Pullman, WA 99164.

Ciliated Cell

Ciliated cells are roughly columnar and have a relatively electronlucent cytoplasm containing scattered ribosomes, profiles of rough endoplasmic reticulum (RER) and many apical mitochondria (Figs. 1-3). About 250 cilia are found on the luminal surface of each cell; interspersed among these are approximately one-half as many microvilli and fine cytoplasmic processes. Cilia decrease in length progressively with succeeding airway generations in the peripheral lung. The structure of the cilia, basal bodies and rootlets is basically the same as that of other ciliated epithelia of plants and animals. Very fine, clawlike projections, 20 nm long, have recently been observed on the apical tip of the cilium in the rat, mouse and man. Atypical cilia of various types are found in apparently normal lungs and in disease states. Microvilli are particularly numerous on the surface of immature ciliated cells undergoing ciliogenesis. Only a few short cilia may project from the surface of such cells.

Cilia beat about 1000 times per minute. The effective beat in the upper and lower respiratory tract is always toward the pharynx. Most of the cilium shaft is bathed in a watery fluid, or sol, of low viscosity in which the cilia beat. Only the tips, including the "claws," actually penetrate the overlying mucus layer. The main function of ciliated cells is to propel the tracheobronchial secretions toward the pharynx. The mechanics of this process are well described elsewhere (2). It has also been suggested that the surface microvilli are important in regulating the volume of the tracheobronchial secretions, but whether this need is real remains to be determined.

Goblet Cell

Goblet cells are abundant in the trachea and bronchi of man, ruminants, horse, guinea pig, cat and dog but relatively sparse in the rat, mouse, hamster and rabbit. As the name implies, the mature cell has a characteristic goblet shape, caused by the content of mucous granules (Figs. 3 and 4). Immature or discharged goblet cells do not have this typical appearance. Many mucous granules of differing size are present in the apical cell cytoplasm. Their content is homogeneous, low density

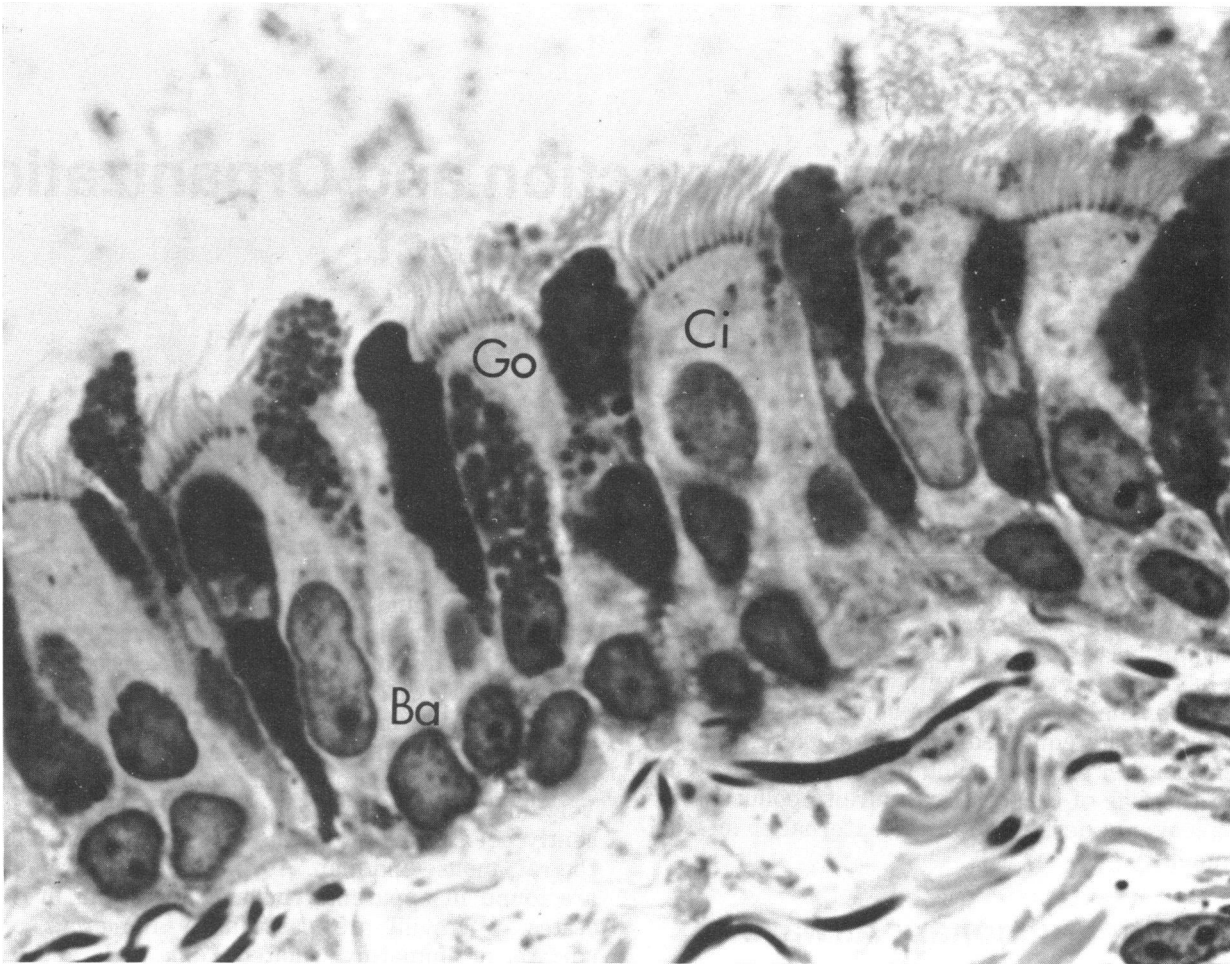


FIGURE 1. Canine bronchus in which ciliated (Ci), goblet (Go) and basal (Ba) cells can be seen. Toluidine Blue; $\times 1200$.

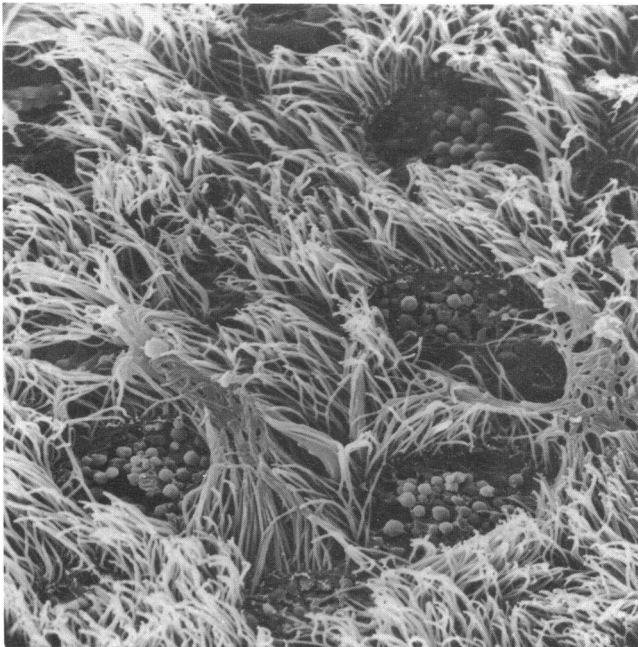


FIGURE 2. Equine bronchus showing ciliated cells and mucous secretion granules. Field of view $50 \mu\text{m}$.

material. The granules often have an incomplete limiting membrane. An electron-dense core has been found in the mucous granules of rats; a similar appearance has been noted in the mucous cells of the submucosal nasal glands in cattle and other animals.

Epithelial Serous Cell

The epithelial serous cell has only recently been distinguished as a specific and numerous cell type in the trachea and extrapulmonary bronchi of the rat (3). It is also found during fetal life in man. The epithelial serous cell was only identified in tissue fixed in both glutaraldehyde and osmium tetroxide, and this may account for its omission from electron microscopic studies of other species.

Epithelial serous cells have electron-dense cytoplasm containing abundant RER and a variable number of apical homogeneous electron-dense granules. The granules are smaller than those of goblet cells and are not osmiophilic when stained with osmium tetroxide alone. Epithelial serous cell granules contain neutral glycoproteins and thus resemble those of the serous cells of the submucosal glands.

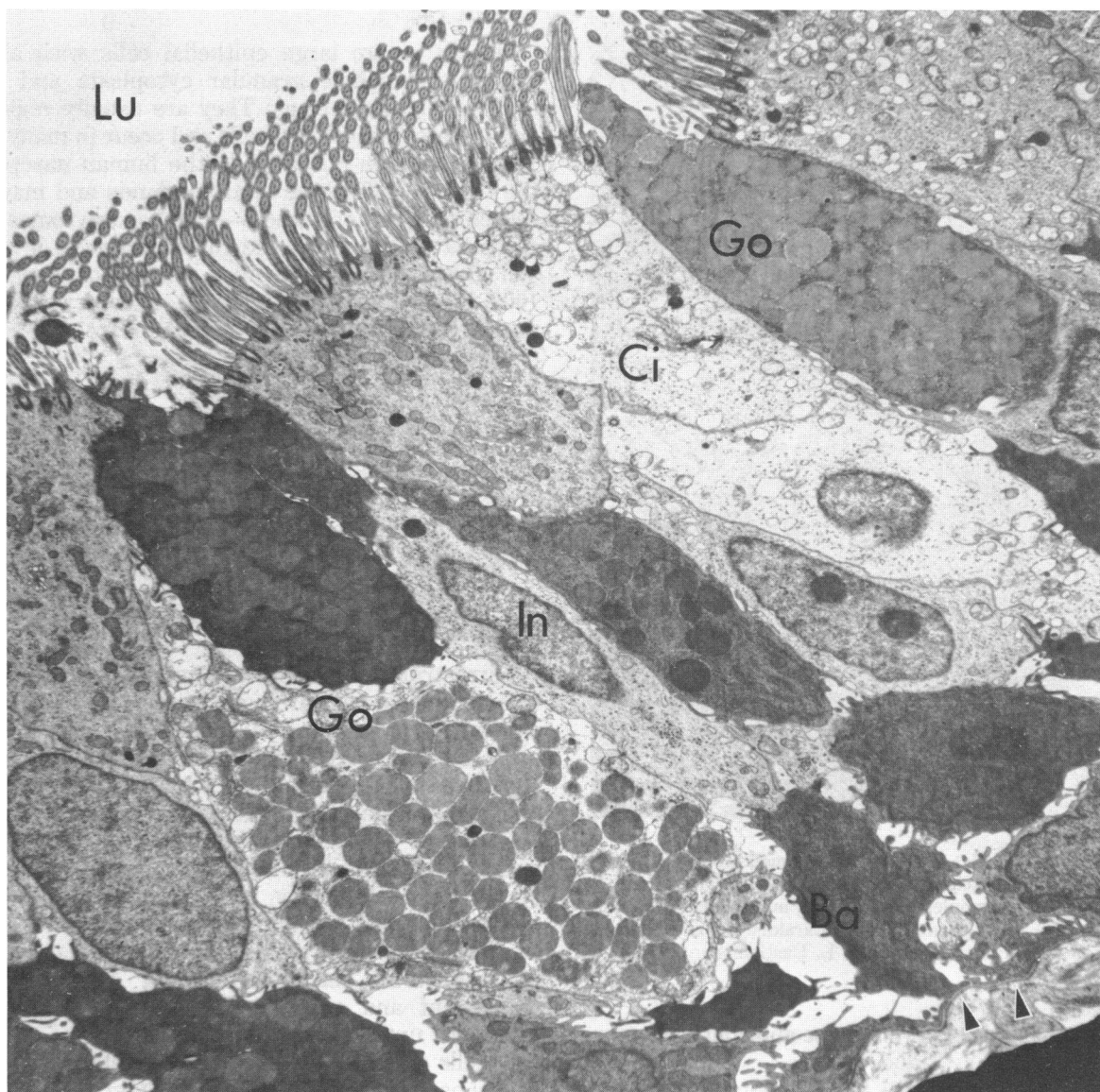


FIGURE 3. Canine bronchus: ciliated (Ci), goblet (Go), intermediate (In), and basal (Ba) cells are present. Note the variation in cytoplasmic electron density and the abundant secretory granules in goblet cells. The lumen (Lu) and basement membrane (arrows) are also marked. Glutaraldehyde and osmium tetroxide; $\times 11,400$.

The function of the epithelial serous cell is not known, although it has been suggested that they may contribute to the periciliary fluid layer beneath the mucus. Cells of this general type are known to contain lysozyme and are believed to be the site of production of secretory component, involved in the molecular completion and epithelial transfer of secretory IgA.

Brush Cell

Scattered along the airway epithelium are cells with a prominent tuft of microvilli on the luminal surface. Some of these are brush cells; others may be differentiating cells or exhausted goblet cells, which should not be included in the same category. The characteristic fea-

tures of brush cells are the content of small vacuoles and vesicles, the cytoplasmic filament bundles and the dense population of stubby microvilli (each $2\ \mu\text{m}$ long and $0.17\ \mu\text{m}$ diameter) on the luminal surface (Fig. 5). The function of brush cells is unknown. An absorptive role is postulated by some; others favor a stretch receptor action.

Basal Cells

Scattered basal cells are found in the epithelium as far as the bronchioles, although they are most numerous in the trachea and extrapulmonary bronchi where they are responsible for the pseudostratified appearance of the epithelium. The nucleus is large and fills most of the

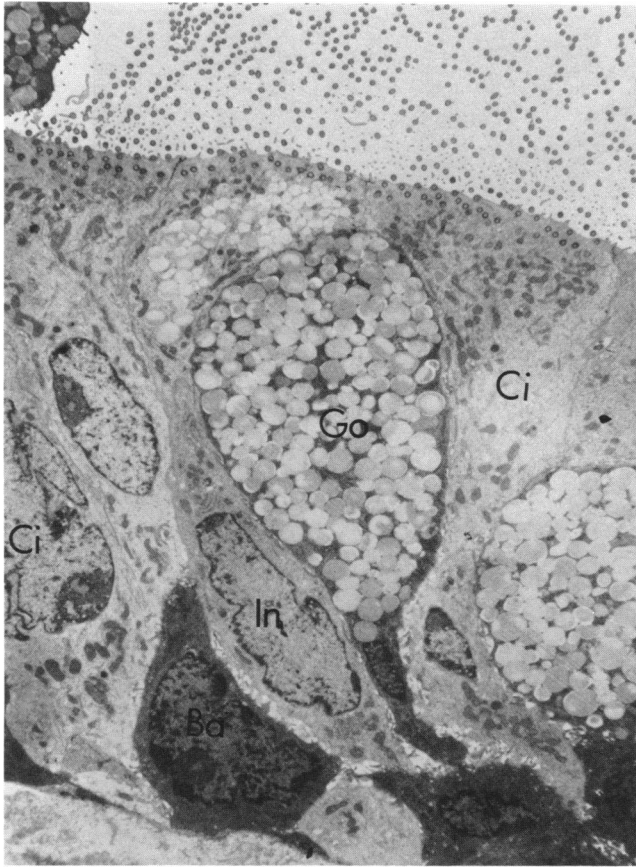


FIGURE 4. Goblet cell (Go) in epithelium of small bronchus of dog. Note classical goblet shape and nucleus pushed to base of cell by accumulated mucus granules. Ciliated (Ci), intermediate (In), and basal cells (Ba) are also marked. Glutaraldehyde and osmium tetroxide; $\times 4560$. Preparation by W. L. Castleman.

cell. The cytoplasm is electron-dense and contains many tonofilaments (Figs. 1, 3 and 4).

The basal cell apparently is the stem cell in the trachea and bronchi. Specialized cells (with the exception of the K cells) develop from basal cells by division and maturation via intermediate cells.

Intermediate Cell

Intermediate cells are found in proximal and distal airways. They form a poorly defined layer just above the basal cells. The name "intermediate" derives from the absence of secretory granules or cilia and the belief that they represent a stage in the development of ciliated or mucus-secreting cells. As the intermediate cell matures it becomes more electron-dense as it starts to accumulate mucin granules or more electronlucent with the onset of ciliogenesis (Figs. 6 and 7). Intermediate cells are roughly spindle-shaped and usually, but not always, reach the airway lumen. It is possible that intermediate cells also play a part in protein transport across the epithelium.

Oncocyte

Oncocytes are large epithelial cells with abundant deeply eosinophilic granular cytoplasm and a small hyperchromatic nucleus. They are usually regarded as degenerate or involuted cells and occur in many organs. They have been observed in the human nasopharynx, the trachea and in the mucous glands and may be the source of cysts or tumors—the "oncocytoomas." Oncocytes have been produced in the bronchi, bronchioles and alveoli of newborn mice continuously exposed to 100% O_2 for 2 weeks or more (4). Mature oncocytes are packed with many round mitochondria and abundant free ribosomes.

Special Type Cell

These have been found in the dog and man (5). Somewhat like basal cells in size and position, these cells contain numerous disc- or rod-shaped cytoplasmic inclusions. The function of these cells is unknown.

K Cell

Ultrastructural studies of human bronchial carcinoid tumors and oat cell carcinomas revealed the presence of a granule-containing cell that closely resembled the gastrointestinal Kultschitzky cell. Subsequently these Kultschitzky-like cells were found at all levels of the tracheobronchial and bronchiolar epithelium, including the mucous glands and their ducts in man and such animals as the rat, rabbit, sheep and chicken (6–8). They occur more frequently in the lungs of fetuses and newborn infants than in adults. The name K cell is adopted here but many synonyms exist, including neuroendocrine cell, Feyrter cell, AFG (argyrophil, fluorescent and granulated) and APUD cell (amine precursor uptake and decarboxylation).

K cells occur singly or in small clusters as neuroepithelial bodies (NEBs) in the epithelium. The cells have a pyramidal shape and their apical cytoplasm may or may not reach the lumen. Characteristic granules are found in the cytoplasm; these range from 80 to 170 nm in diameter and have a small electron-dense core that is separated by a clear halo from the limiting membrane. Subtypes of cell have been distinguished on the basis of differences in granule morphology and cell ultrastructure. The granules are now known to contain peptides, including bombesin, as well as vasoactive amines such as serotonin (9).

K cells are commonly demonstrated in the airways by three methods: (1) by electron microscopy and identification of the specific granules; (2) by the localization of intracytoplasmic fluorogenic monoamines using the Falck technique; and (3) by their argyrophilic properties after Bodian silver protargol or Grimelius' silver nitrate stain.

K cells have a capacity for amine precursor uptake, decarboxylation and storage, a process that takes place

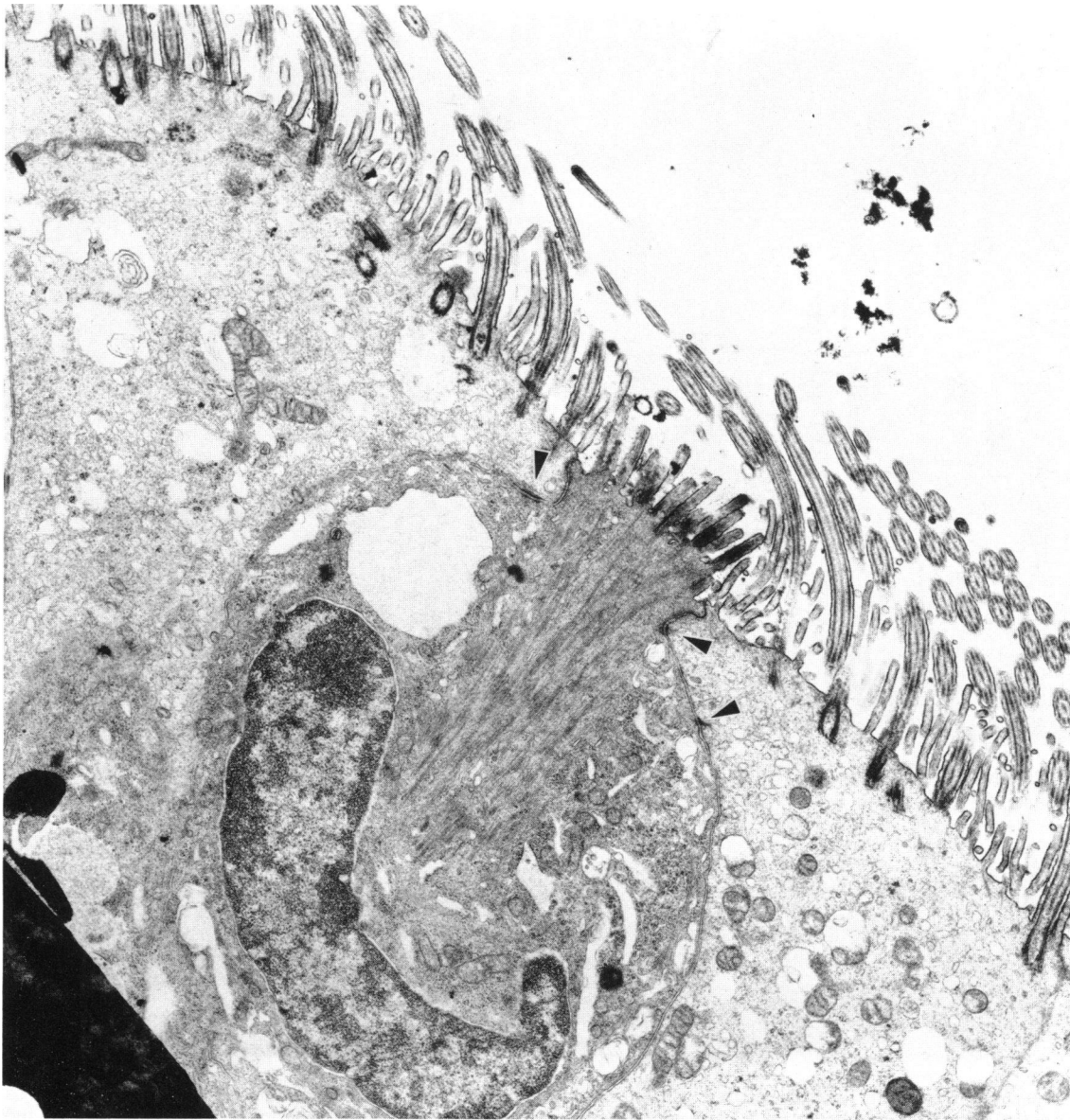


FIGURE 5. Brush cell in bovine bronchus. The regular, stubby surface microvilli, apical cell junctions (arrows), cytoplasmic filament bundles and irregular, dilated cisterns and vesicles are illustrated. Glutaraldehyde and osmium tetroxide; $\times 15,000$. Preparation by E. M. Allan.

in the secretory granules. Formaldehyde-induced fluorescence of the Falck technique sometimes demonstrates serotonin in K cells without prior amine precursor administration. In most species, however, administration of L-5-hydroxytryptophan (5HTP) or L-dihydroxyphenylalanine (L-dopa) *in vivo*, or *in vitro* incubation of tissue samples with the same precursors, increases the cellular amine stores so that the number of K cells and the intensity of their fluorescence are enhanced. After 5HTP, K cells have yellow or yellow-green fluorescence indicative of 5-hydroxytryptamine and are more green after L-dopa (probably indicating the presence of dopamine). The amine handling capacity of the K cell

places it in a group of neuroendocrine cells specialized for production of polypeptides and amines, some of which are hormones, together known as the APUD cell system. Other members include A, B and D cells of the pancreatic islets (producing glucagon, insulin and gastrin, respectively) and thyroid C cells (synthesizing calcitonin). Neuroectodermal cells of the neural crest are believed to be the antecedents of all cells of the APUD series. This view has recently been challenged by evidence that digestive tract, and perhaps pulmonary, APUD cells are of endodermal origin (10). The function and cytokinetics of K cells occurring singly or in NEBs are not known. Suggested roles include stretch receptor,

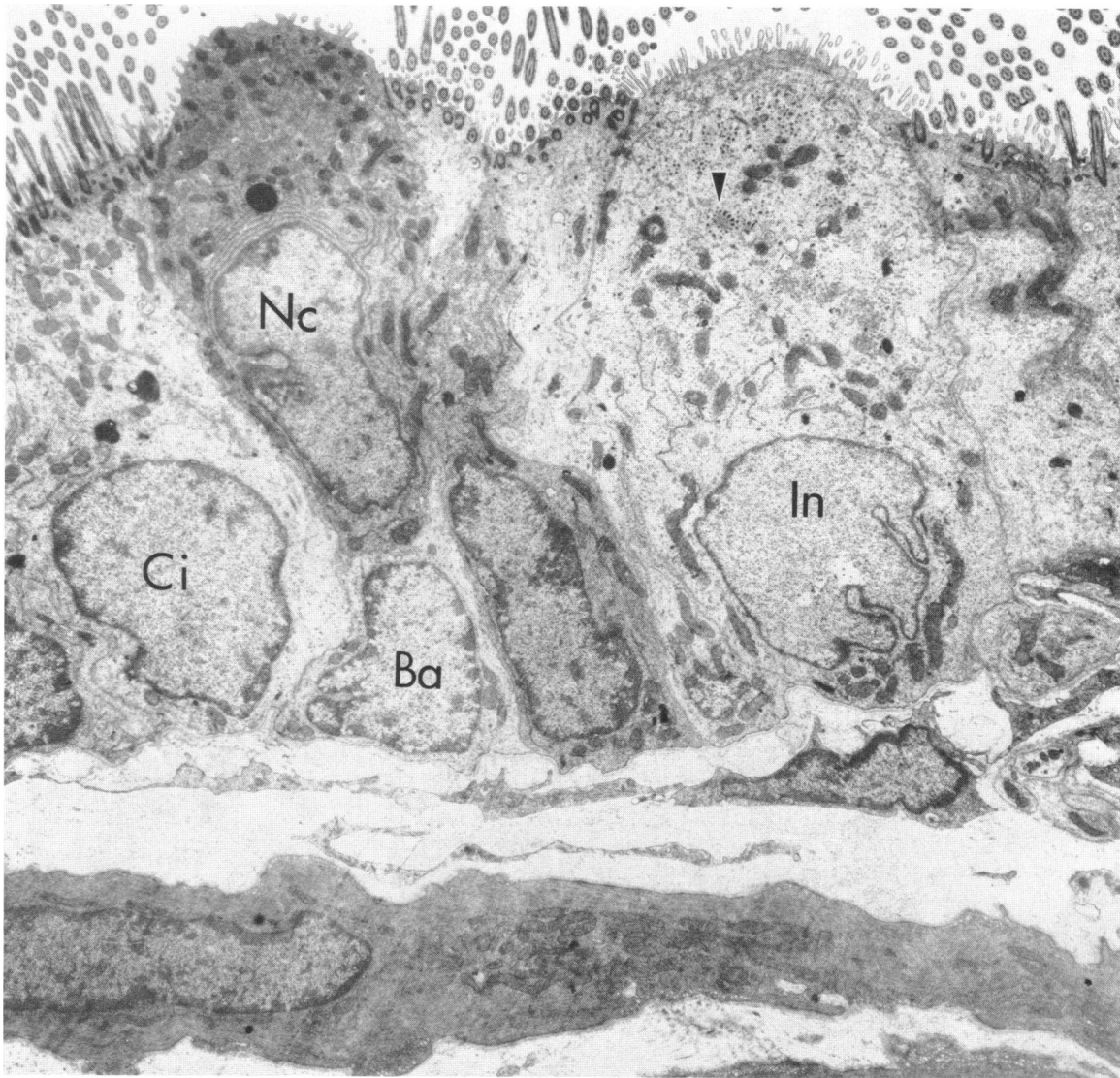


FIGURE 6. Bronchus of rat lung lined by ciliated (Ci) (containing dense bodies), nonciliated bronchiolar epithelial (Nc), basal (Ba) and intermediate (In) cells. The intermediate cell has numerous microvilli on the luminal surface and is undergoing ciliogenesis, indicated by the accumulation of fibrogranular material in the apical cytoplasm (arrow). Glutaraldehyde and osmium tetroxide; $\times 5000$.

chemoreceptor of CO_2 receptor with involvement in regulation of the pulmonary circulation in the neonatal period or under hypoxic conditions.

Nonciliated Bronchiolar Epithelial (Clara) Cell

The epithelium of bronchioles is composed largely of low ciliated and taller nonciliated cells. The latter are usually referred to as Clara cells, but this eponym is confusing in view of the varied ultrastructural features, and probable diverse functions, of nonciliated bronchiolar epithelium in different species.

In the light microscope, nonciliated bronchiolar epithelial cells have dome-shaped apical cytoplasm, also

well shown in scanning electron micrographs (Figs. 6–10). Abundant smooth endoplasmic reticulum (SER) and many electron-dense homogeneous inclusion granules are found in the apical cytoplasm of many species (Figs. 7 and 11). RER, rather than SER, predominates in nonciliated bronchiolar epithelial cells of man and some primate species. Few granules, little SER or RER, and abundant cytoplasmic glycogen characterize these cells in the steer (Fig. 9), dog, cat and ferret (11).

There is general agreement that the cytoplasmic granules reflect a secretory function for nonciliated bronchiolar epithelial cells. The granules contain a protein or lipoprotein which is thought to contribute to a surface-active lining layer in the bronchioles, which are not covered by the mucus layer typical of tracheobron-

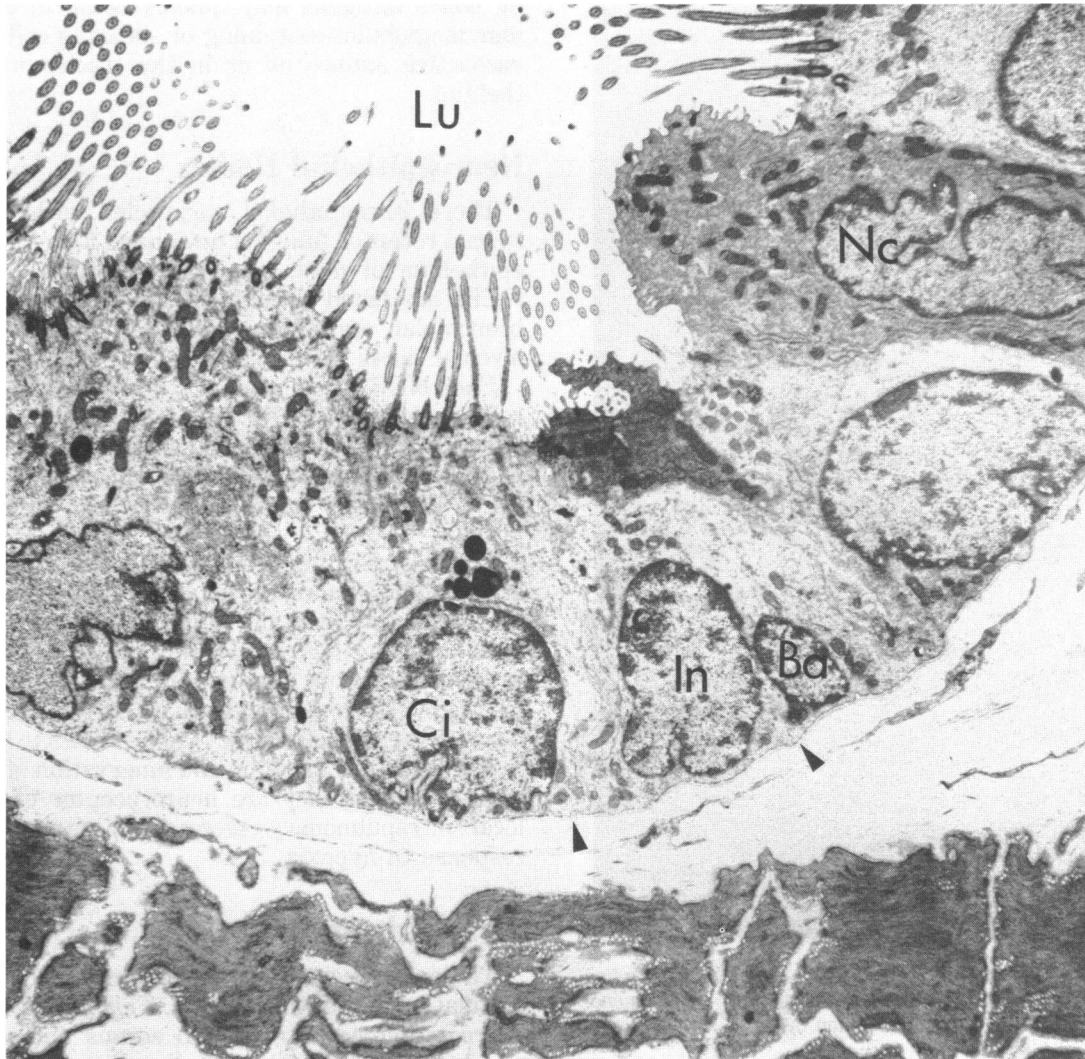


FIGURE 7. Distal airway of rat lung containing ciliated (Ci), intermediate (In), and basal (Ba) cells. A nonciliated bronchiolar epithelial cell (Nc) with bulging apical cytoplasm is also present. Lumen (Lu) and basement membrane (arrows) are also marked. Glutaraldehyde and osmium tetroxide; $\times 3000$.

chial epithelium. The available evidence supports the view that the alveolar Type II pneumocyte and not the nonciliated bronchiolar epithelial cell is responsible for production of alveolar surfactant.

The abundant SER characteristic of many species is believed to be the site of cytochrome P-450-dependent mixed function oxidase (MFO) metabolism of xenobiotics reaching the lung via the air or blood (12). Nonciliated bronchiolar epithelial cells in many species are thus "target cells" for environmental pneumotoxic, mutagenic or carcinogenic chemicals requiring metabolic activation (Fig. 12).

Basal cells are sparse in the bronchioles. The nonciliated bronchiolar epithelial cells form a stem cell population (Fig. 12) capable of division and differentiation to replace ciliated, nonciliated and brush cells (13). Nonciliated bronchiolar epithelial cells apparently in

various stages of maturation and differentiation can thus be found in a single animal.

Lymphocyte

Lymphocytes are regularly found in the tracheobronchial epithelium, especially in extrapulmonary airways. Little is known of the origin, traffic and life history of lymphocytes in this location; it is assumed they are migratory.

Globule Leukocyte

The globule leukocyte is an intraepithelial mononuclear cell filled with large, highly refractile, acidophilic granules (Fig. 13). The granules take up eosin and are metachromatic with proper fixation and staining. Glob-

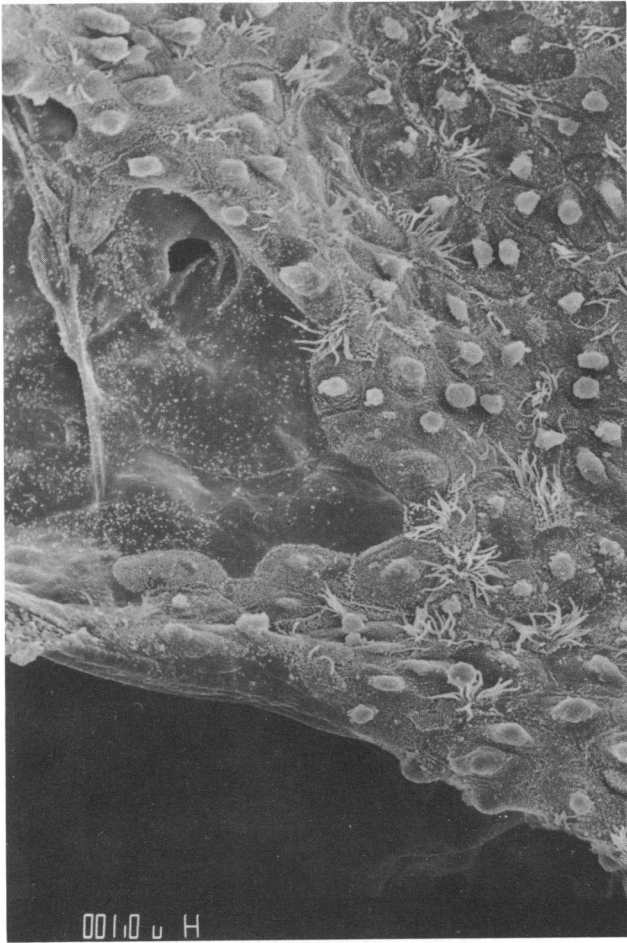

FIGURE 8. Junction of bronchiolar and alveolar epithelium showing ciliated and nonciliated bronchiolar cells and Type I pneumocytes. Field of view 60 μm . Preparation by A. T. Mariassy.

ule leukocytes are found in many mucous membranes throughout the body, particularly in association with parasitic infections. In the tracheobronchial epithelium they have been observed in rats, deer, cats, cattle and dogs, although not apparently in man (1).

Globule leukocytes are derived from subepithelial mast cells by migration through the basement membrane, during which some of the granule contents are lost and the histochemical properties slightly altered. Globule leukocytes contain a catecholamine (probably dopamine) and fluoresce with the Falck technique. The granules also contain a basic protein which binds acid dyes at high pH. The demonstration of subepithelial mast cells and globule leukocytes depends upon proper fixation to avoid loss of water-soluble granule contents in some species.

The function of globule leukocytes in airways is not known. In the gut, subepithelial mast cells have a postulated role in "self-cure" of parasitic infections such as *Nippostrongylus brasiliensis* by increasing the permeability of gut wall to circulating or locally produced antibodies. Such a mechanism might have wider biologic implications in respiratory allergies as a means

by which antigens may quickly come in contact with immunoglobulin-containing or -bearing cells filled with vasoactive amines on or in the tracheobronchial epithelium.

Neuroepithelial Bodies

These intraepithelial corpuscles with a presumed special receptor function have been found in the airway epithelium of man, cat, mouse, rabbit and rat (14). NEBs are found throughout the tracheobronchial and bronchiolar epithelium and even in the alveoli and alveolar ducts (15).

Each NEB is composed of a number of tall nonciliated cells forming a cone or spherical corpuscle within the epithelium. Fenestrated capillaries are observed beneath the basement membrane, closely associated with the NEB. Many nerve fibers ramify within the corpuscle.

The cells forming the NEB are like K cells; they are argyrophilic, fluoresce for serotonin with the Falck technique and contain dense-cored inclusions. It is possible that NEBs are merely grouped K cells, but to avoid confusion at present it is useful to distinguish between NEBs and individual or clustered K cells, because their functions may yet be shown to be separate.

The structure, position and innervation of NEBs have suggested that they are neuroreceptor organs with a local intrapulmonary secretory activity, perhaps in response to hypoxia.

The Submucosa

There is a continuous secretion of mucus onto the luminal surface of the airways. This is derived from two sources: individual epithelial serous and goblet cells, which are scattered through the epithelium down to the small airways, and the mucous glands, which are embedded in the airway wall and open into the lumen by a duct.

The comparative anatomy of the mucus-secreting structures of the respiratory tract in the different species is poorly documented; available knowledge suggests that the distribution of secreting elements is very variable and does not always resemble that of man, particularly in small mammals. As well as anatomic differences in distribution there are histochemical variations in composition of mucus in different species and even at different sites in the airways of a single species. Thus, the mouse tracheobronchial system has mucosubstances that are neuraminidase-sensitive, whereas in the rat this form is only present in the epithelium of the peripheral airways, with neuraminidase-resistant mucosubstances in proximal airways. The significance of the variation in distribution of goblet cells and mucous glands in the different species is also unknown. In the rat, for example, mucous glands are confined to the cranial end of the trachea. Bronchial glands are fairly abundant in the sheep and cow and very numerous in the cat. Glands are sparse in the horse.

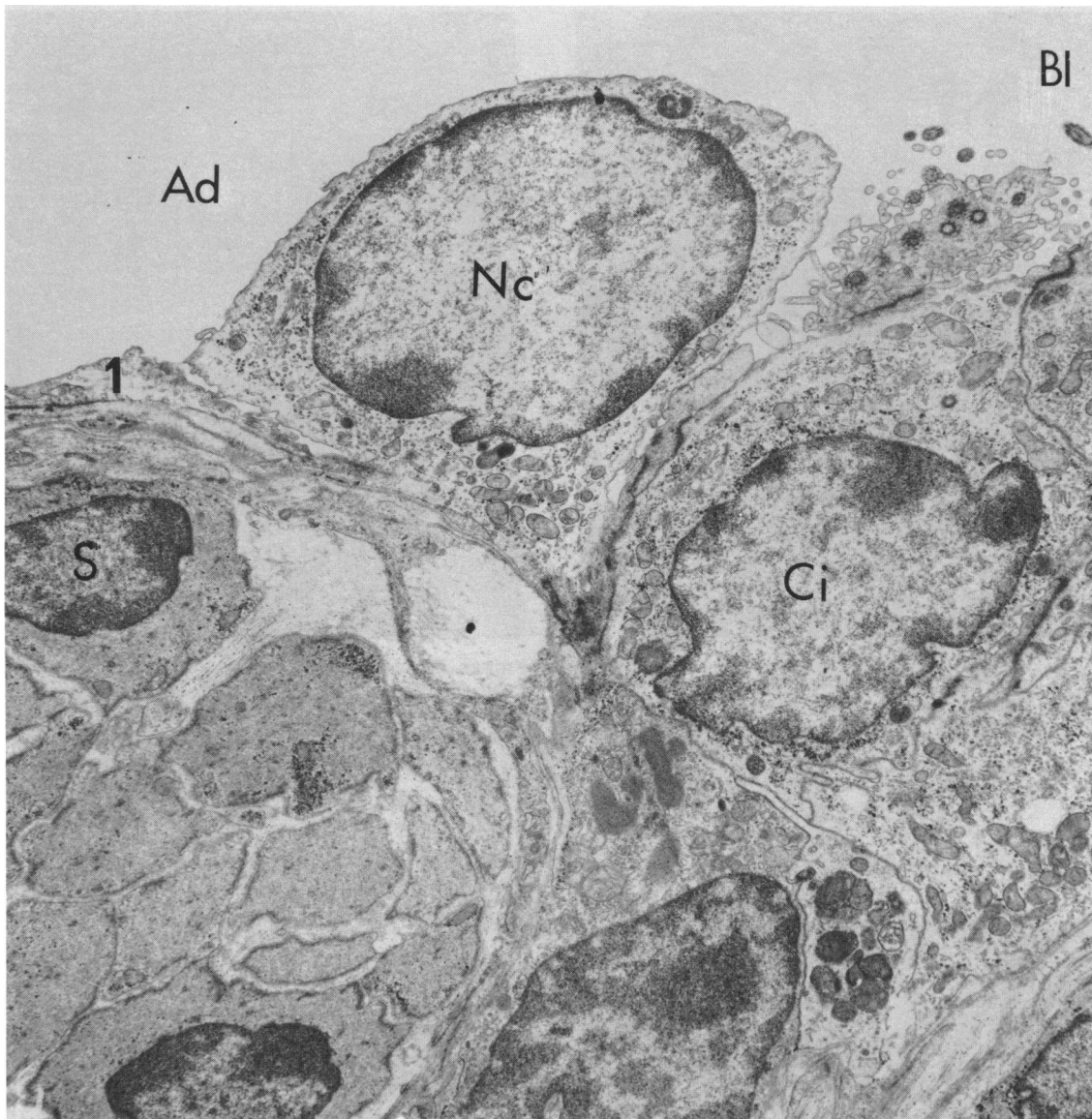


FIGURE 9. Junction of bronchiolar (Bl) and alveolar lumina (Ad) in bovine lung. Note abrupt transition from ciliated (Ci) and nonciliated (Nc) bronchiolar cells to squamous alveolar epithelium (17). Smooth muscle in airway wall is also marked (S). Osmium tetroxide; $\times 10,000$.

It is not known why there are two components to the mucus-secreting apparatus. Knowledge of the contribution to the total amount of mucus made by each of the two components is based on an estimate that the mucous glands in man have a volume 40 times greater than that of the goblet cells. This has led to the assumption that the secretion of goblet (and serous) cells is relatively unimportant in large airways.

Mucous Glands

Three regions, the ciliated duct, the collecting duct, and the secretory tubules, were identified in the human bronchial mucous gland (16).

The ciliated duct is lined by airway surface epithelium and gives way to a larger collecting duct. Here there is

an abrupt change to a lining of tall columnar cells packed with mitochondria. These resemble oncocytes, and it has been suggested that in this position such cells exert a controlling function on water and ion content of secreted mucus.

The collecting duct gives rise to several blind-ending branched secretory tubules. Mucous cells line each secretory tubule and its main branches. Individual secretory tubules end in a cluster of shorter tubules, and these are lined by serous cells. The product of serous cells must thus pass through tubules lined by mucous cells before reaching the collecting duct. Myoepithelial cells are found beneath the serous, mucous and collecting duct cells.

Mucous cells are packed with variable-sized secretion granules of moderate electron density. Serous cells have

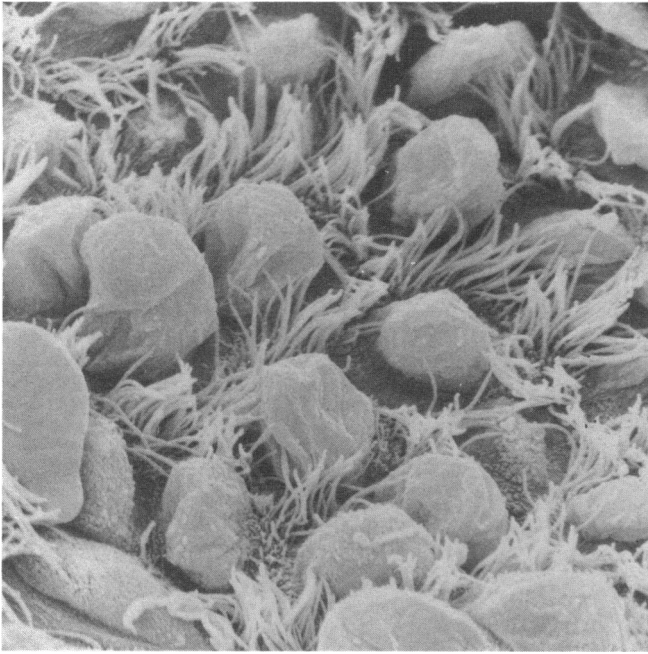


FIGURE 10. Ciliated and nonciliated epithelial cells in equine terminal bronchiole. Note the bulging apical cytoplasm of nonciliated cells. Field of view 30 μm .

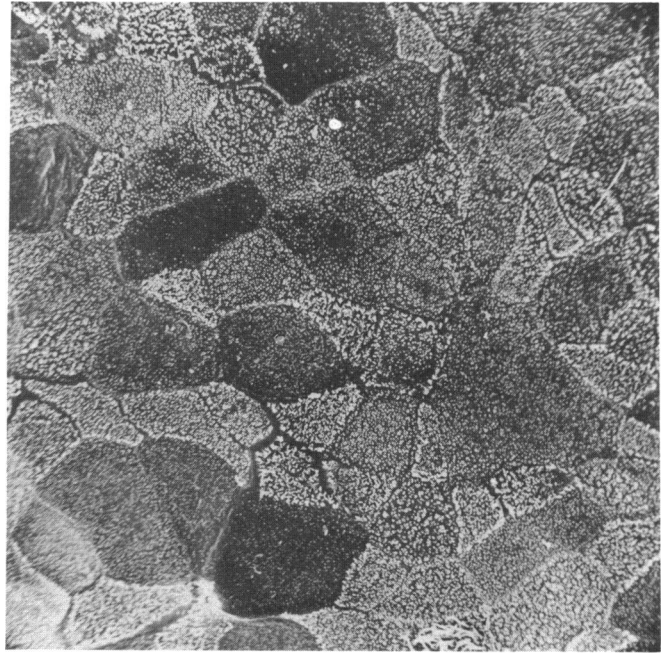


FIGURE 12. Surface of equine terminal bronchiole 144 hr after destruction of nonciliated epithelial cells by 3-methylindole. A ciliated cell is present, but the epithelium is made up mainly of regenerating nonciliated cells covered with surface microvilli and without projecting apical caps. Field of view 60 μm .

fairly uniform granules. Serous cells appear to be involved in the transport of IgA across the epithelium and in the production of lysozyme.

Tracheobronchial Secretions

Respiratory tract secretion consists of mucosubstances from the mucous glands and epithelial serous and goblet cells, together with variable amounts of serum transudate. Mucosubstances govern the physical properties of the secretion. Biochemically, the recoverable secretion is 95% water together with 1% each of protein, carbohydrate, lipid (including surfactant) and inorganic material. The principal components of the proteins are albumin, secretory IgA (IgA is also found in much smaller amounts as a monomer), IgG and, in trace amounts, a variety of proteins such as lysozyme, lactoferrin, α -1-antitrypsin, haptoglobin, transferrin and members of the complement system.

The bronchial mucosubstances are glycoproteins, conjugated proteins with a polypeptide core covalently linked to repeating oligosaccharide side chains with sugar residues. Different oligosaccharide side chains containing sialic acid and sulfate can be identified and characterized by histochemical techniques applied *in situ*. Two staining sequences are basic to differentiation: alcian blue (pH 2.6)-periodic acid Schiff (AB-PAS) and alcian blue (pH 1.0)-PAS before and after neuramini-

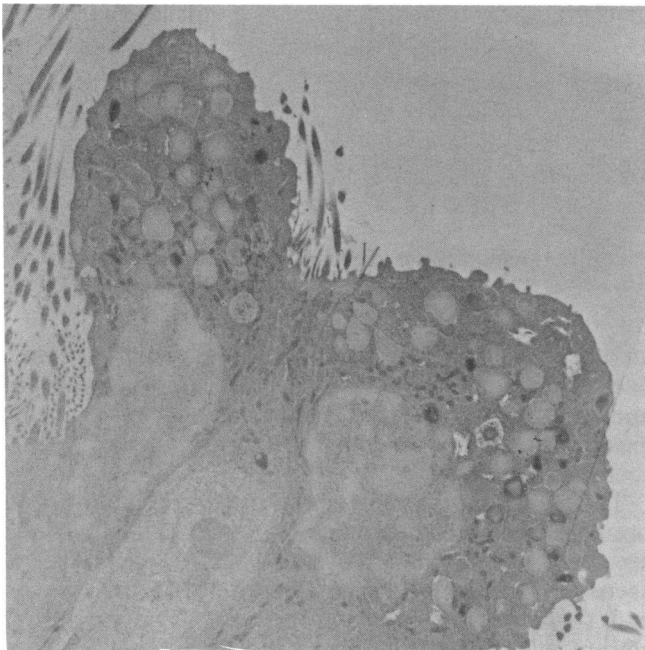


FIGURE 11. A ciliated cell is bracketed by two nonciliated epithelial cells filled with membrane-bound granules in an equine terminal bronchiole. Formaldehyde-glutaraldehyde; $\times 4860$.

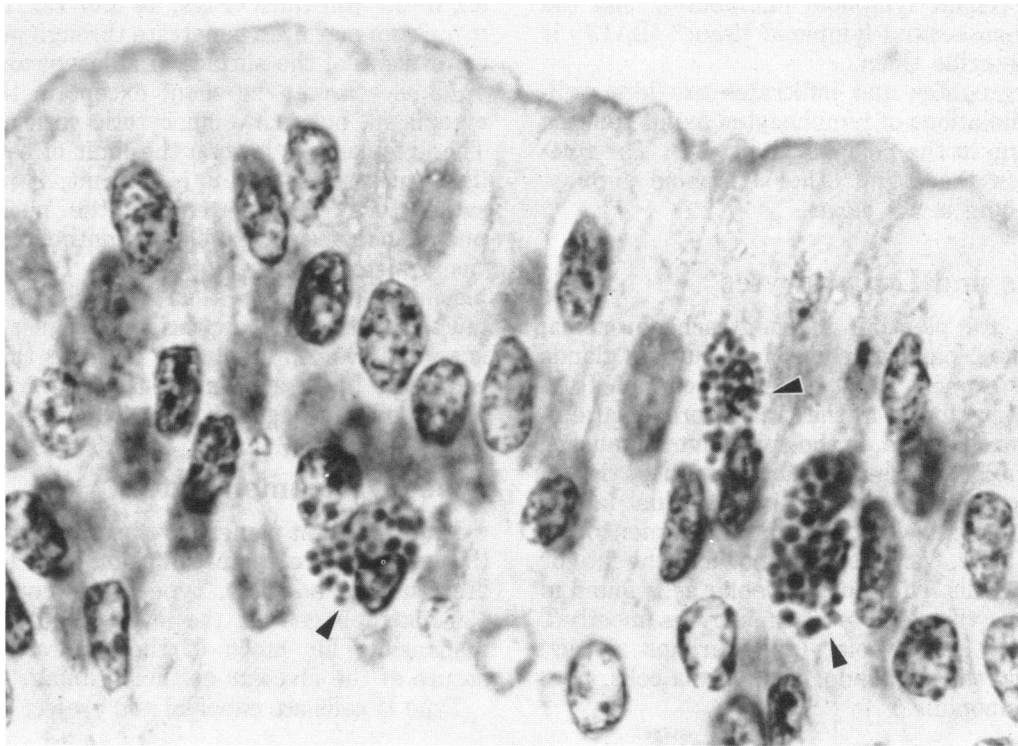


FIGURE 13. Globule leukocytes (arrows) in bovine bronchial epithelium. Hematoxylin and eosin; $\times 1500$.

dase (sialidase). PAS stains the sugar portion of the glycoprotein, AB the acid radicals. After AB (pH 2.6)–PAS, cells staining blue are considered to contain acid mucosubstances (sialomucins or sulfomucins), and those staining red predominantly neutral mucosubstances. After AB (pH 1.0)–PAS, only sulfomucin stains blue. Neuraminidase digestion removes sialidase-sensitive mucosubstances, leaving resistant forms. Characterization of mucosubstances can thus be accomplished by staining serial sections with these sequences. The proportion of cells staining with each technique is not the same in all species, between sexes, in different airway generations, or in health and disease.

Subepithelial Mast Cells

There appear to be histochemical differences between subepithelial and connective tissue mast cells in the lung and alimentary tract and care must be taken in fixation and staining to illustrate these. There may also be functional differences. In the lungs of rats infected with *N. brasiliensis*, IgE appeared intracellularly in the granules of subepithelial mast cells in the small intestine, tracheobronchial mucosa and interalveolar septa, but only on the surface of connective tissue mast cells. It is suggested that subepithelial mast cells and globule leukocytes might be responsible for transfer of IgE to the luminal surface secretions.

Free mast cells can be found among cells recovered by

bronchial lavage. Other “basophiloid” cells are also present. These are probably globule leukocytes. It is important to realize that IgE-containing or -bearing cells capable of responding to specific antigen by release of biogenic amines are present on or in the respiratory epithelium.

Bronchus-Associated Lymphoid Tissue

The contribution of the lungs to the output of antibodies and immunocytes in the systemic immunologic response is frequently underestimated. Lymphoid tissue is found in the walls of conducting airways from the nasopharynx to the alveolar ducts. This lymphoid tissue exists at three main levels of organization: lymph nodes; lymphoid nodules; and lymphoid aggregates and infiltrates. The tracheobronchial lymph nodes will not be discussed here.

Multiple nodules of lymphoid tissue are scattered within the bronchial mucosa down to the level of the small bronchioles and are particularly numerous about points of bifurcation (17). The overlying epithelium is modified and consists of flattened, nonciliated, cuboidal cells. Nodules are made up of follicles of small and medium-sized lymphocytes without germinal centers. About 20% of these lymphocytes are T cells, about 50% are B cells and the remainder bear no detectable marker. These nodules are probably the pulmonary analog of gut-associated lymphoid tissue such as Peyer’s

patches or the colonic lymphoid microbursa, and the term "bronchus-associated lymphoid tissue" (BALT) is often used to describe them.

Lymphoid aggregates and infiltrates are less well-organized accumulations of lymphocytes found beneath lymphoepithelium in the peripheral airways. The relationship between these and other lymphoid subpopulations in the lung is not clear.

Plasma Cells and Lymphocytes

Plasma cells are plentiful in the tracheobronchial mucous membrane, particularly around mucous glands and in the main bronchi. Most appear to contain IgA.

Lymphocytes are found in the tracheobronchial epithelium and lamina propria, in the epithelium of mucous glands and in the bronchus-associated lymphoid tissue. Many lymphocytes are recovered by bronchial lavage and it is clear that extensive traffic into the lumen of the airspaces must exist. Very little is known of the fate or kinetics of these cells. Of bronchoalveolar cells found in lavage fluid, fewer than 20% are lymphocytes (mostly T cells), 60 to 70% are alveolar (and perhaps airway) macrophages and the remainder are plasma cells, neutrophils and eosinophils.

Structure of the Inter-alveolar Septa

The alveolar spaces contain many free cells—the alveolar macrophages. Alveoli are lined by a continuous layer of epithelial cells which are mostly squamous or Type I pneumonocytes and cuboidal granular or Type II pneumonocytes. A few brush cells and NEBs may be found. These epithelial cells are believed covered by an acellular duplex layer composed of a surface film (surfactant) of highly surface-active phospholipids over a hypophase containing phospholipids, proteins and carbohydrates. The lining layer is poorly preserved in routine fixation procedures. Pores of Kohn, openings in the inter-alveolar septa 10–15 μm in diameter, allow communication between adjacent alveoli. The numbers and sizes of such pores in alveoli of normal lungs in the different species and under normal conditions of alveolar inflation and deflation are poorly documented. There are also bronchiolar–alveolar communications (Lambert's canals) lined by bronchiolar epithelium between distal bronchioles and adjacent alveoli. These permit collateral ventilation of many alveoli in species in which they occur.

Three distinct tissue layers make up the air–blood barrier: the alveolar surface epithelium; the alveolar interstitial space bounded by the basement membranes of the epithelium and endothelium; and the alveolar capillary endothelium. To these might be added the surface-active alveolar lining.

Type I Pneumonocytes

These highly specialized squamous cells cover most of the alveolar surface with a thin cytoplasmic layer some

0.2 to 0.5 μm thick (Figs. 14 and 15). Portions of the cytoplasm may even penetrate through pores of Kohn to cover some of the surface of adjacent alveoli (18). Few organelles are to be seen, except in the perinuclear cytoplasm, but many pinocytotic vesicles are present. The cytoplasm is beyond the limit of resolution of the light microscope and it is difficult, if not impossible, satisfactorily to differentiate the nuclei of Type I pneumonocytes and capillary endothelial cells in conventional histological sections. Type I cells have a cytoplasmic volume twice that of Type II pneumonocytes, but this is not easily appreciated because this cytoplasm is spread over an area some 50 times that of a Type II cell. Type I cells are very sensitive to injury by inhaled and bloodborne agents.

Type II Pneumonocytes

Many different names have been given to this cell and this may lead to some confusion in reading the older literature. In addition, Type II pneumonocytes resemble macrophages in the light microscope, a factor responsible for much of the controversy about the nature of the alveolar epithelial lining.

Type II cells are cuboidal and project into the lumen,

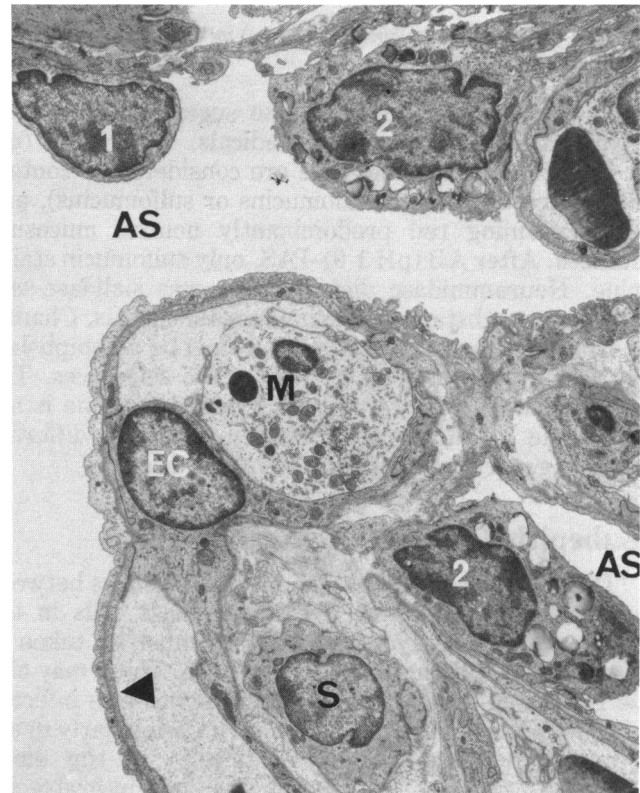


FIGURE 14. Bovine lung with alveolar spaces (As) lined by Type I (1) or Type II (4) pneumonocytes. A capillary, lined by endothelial cells (Ec) bulges into the alveolus creating an extensive area of minimal blood: air barrier formed by cytoplasm and basement membranes of Type I pneumonocytes and endothelial cells (arrow). Smooth muscle is visible in the interstitium. A monocyte (M) is present in the capillary. Osmium tetroxide; $\times 4020$.

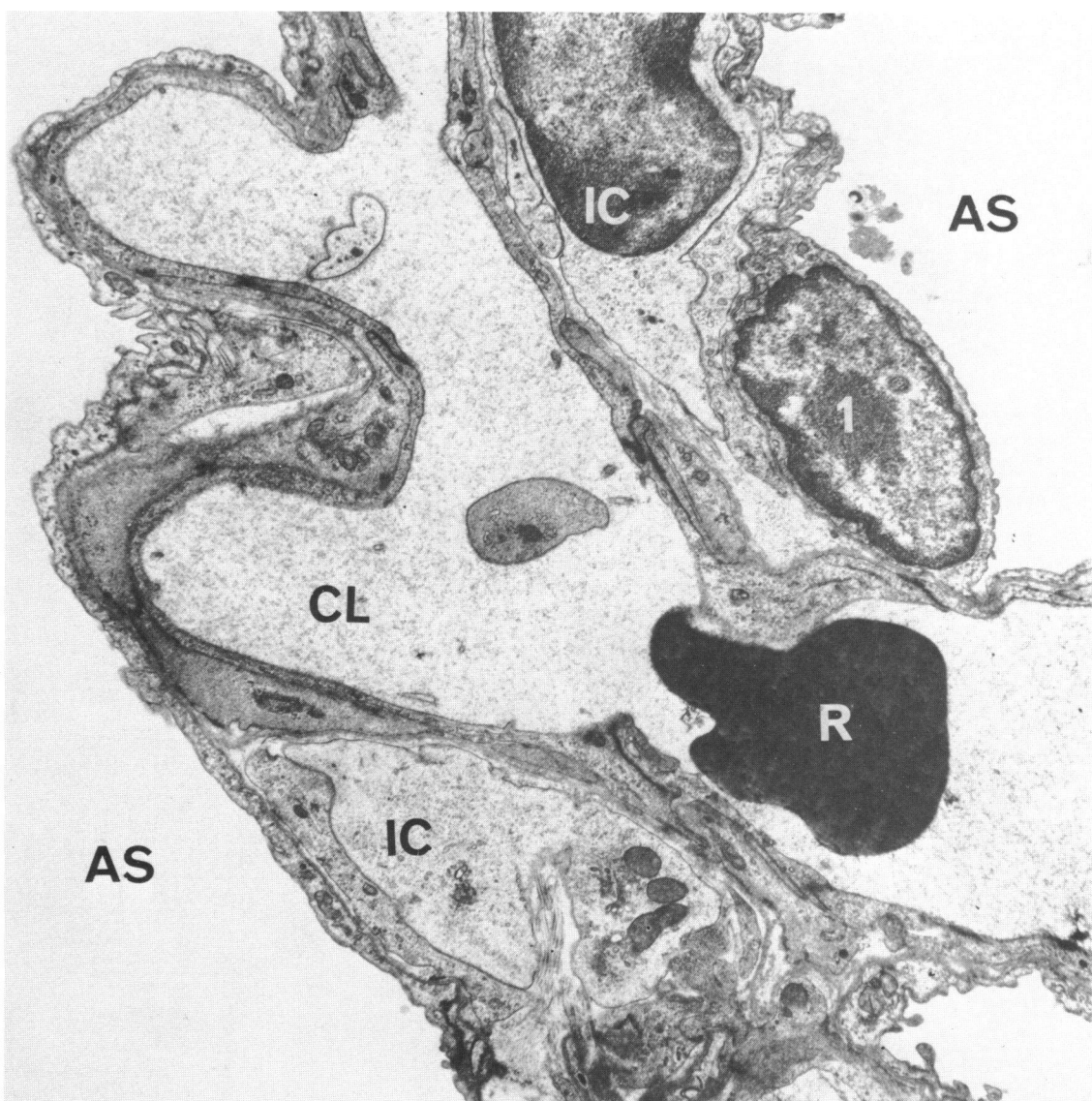


FIGURE 15. A capillary (CL) containing red blood corpuscles (R) transverse an interalveolar septum between alveolar spaces (AS) in bovine lung. The nucleus of a Type I pneumocyte (1) is visible. Cytoplasm and a nucleus of interstitial cells (IC) are visible between the epithelial basement membrane and the capillary endothelium. Osmium tetroxide; $\times 10,000$.

often from niches in the interalveolar septum (19). Their lower lateral borders are often covered by cytoplasmic extensions of Type I cells, to which they are joined by tight cell junctions. The free cell surface is covered with short microvilli, particularly laterally, and coated by a thick glycocalyx. Type II cells are very active metabolically and their cytoplasm contains mitochondria, peroxisomes, RER, many free ribosomes and multivesicular bodies. Characteristically, lamellar cytoplasmic inclusions are present in the apical part of the cell, from where they may be extruded into the lumen (Figs. 14 and 16). The appearance of the lamellar inclusion varies with species and fixation. The lamellar inclusions contain phospholipids similar to those present in surface-active fractions recovered from alveolar washings, par-

ticularly phosphatidyl choline and phosphatidyl glycerol (20).

Type II pneumonocytes are the cells which synthesize and secrete the surface-active phospholipids in the alveolar lining. Type II cells are also stem cells capable of proliferation and differentiation into Type I pneumonocytes in response to certain forms of alveolar injury (Figs. 17 and 18). Type II cells are not very active in phagocytosis and do not desquamate to become alveolar macrophages.

Brush Cells

In the alveoli, the sparse brush cells, which are morphologically no different from their airway counter-

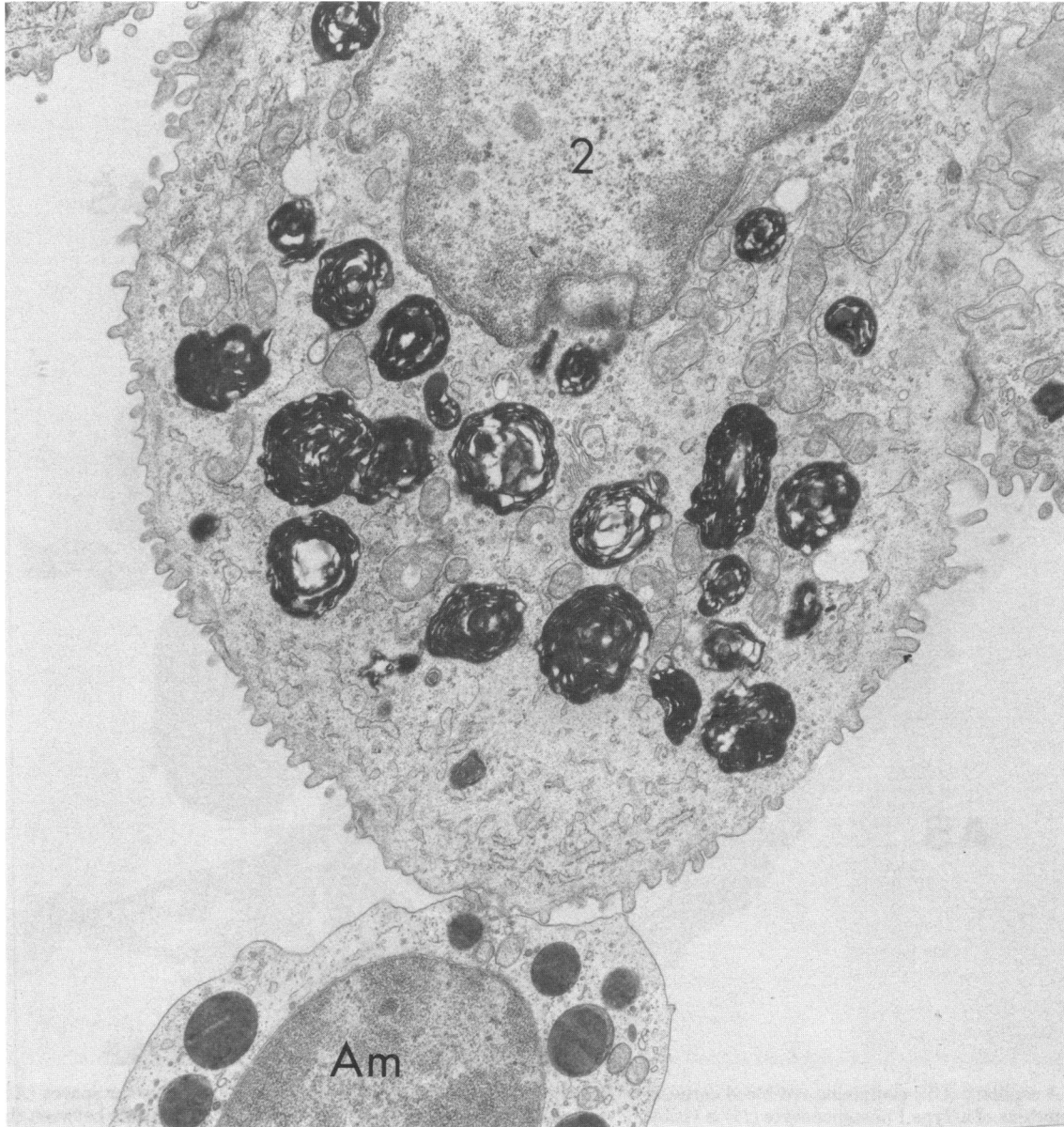

FIGURE 16. Type II pneumonocyte (2) and part of an adjacent alveolar macrophage (Am) in bovine lung. Note prominent Golgi, lamellated inclusions and surface microvilli of Type II cell and dense granules of the macrophage. Osmium tetroxide; $\times 20,000$.

parts, are sometimes known as Type III pneumonocytes (19).

The Alveolar Interstitium

The "interstitium of the lung" may refer to two sites in animals—the interlobular connective tissue septa surrounding secondary lobules, as in the cow, or the interstitial tissue of the interalveolar septa. In this context the latter is implied.

Over much of the interalveolar septum, the interstitial space is only potential and is made up of the fused basement membranes of epithelial and endothelial cells;

these areas are optimal for gas exchange. Elsewhere the basement membranes are separated by a narrow space in which amorphous ground substance, a few connective tissue fibrils and cytoplasmic processes of intramural cells may be apparent. Finally, wider spaces occur, often between adjacent capillaries, and in these there may be interstitial macrophages, fibroblasts, contractile cells and occasional mast cells, embedded in ground substance with collagen and elastic fibers. Smooth muscle cells are found around the alveolar ducts in large animals. The connective tissue framework of the interalveolar septa is arranged as a central mesh covered on each side by a capillary network with

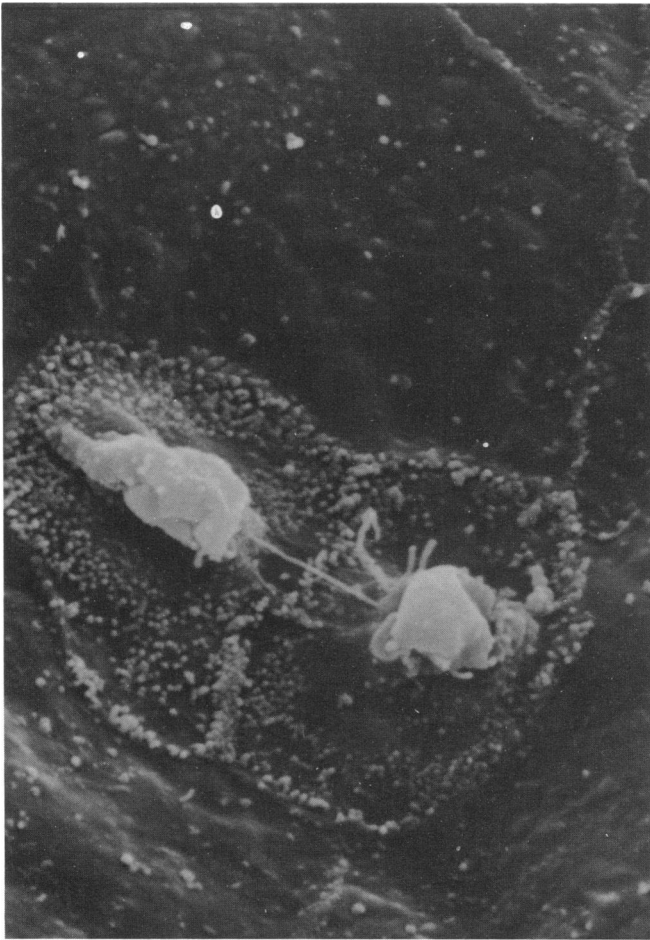


FIGURE 17. Division of Type II pneumocyte. Field of view 18 μm . Preparation by A. T. Mariassy.

frequent anastomoses across the wall. This gives maximal area for gas diffusion, minimal air-blood barrier and a pathway for extracellular fluid transport.

The amorphous ground substance consists largely of proteoglycans, with tissue and serum proteins, electrolytes, cell metabolites and other substances involved in any cellular milieu. The proteoglycans include: hyaluronic acid, chondroitin 4-sulfate and chondroitin 6-sulfate, dermatan sulfate, heparan sulfate and heparin.

Collagen is the most abundant protein in the lung (21). Large amounts are present in and around the walls of bronchi, perivascularly, and in the interalveolar septa. In the interstitium, Type I collagen predominates, making up some 65% of the total, Type III collagen (reticulin) forms about 35% and Type IV collagen in the basement membrane accounts for less than 1%.

Elastic fibers occur throughout the lung and airways, in the tracheobronchial lamina propria and in the interalveolar septa. Elastic fibers in the interstitium occur as elastin and microfibrils.

The connective tissues of the interstitium are vitally important in elastic recoil and in maintaining structural relationships within the acini and within the lobule. They form a framework for maintenance and repair of alveoli, control the movement of water, ions and cells between capillaries and alveolar surfaces, and anchor fibers around conducting airways and blood vessels to those extending into the lung from the pleura and interlobular septa.

Fibroblasts, mast cells and smooth muscle cells, when present in the interstitium, do not differ ultrastructurally from similar cells elsewhere in the body.

Interstitial Macrophages

Alveolar macrophages are largely derived from the bone marrow via blood monocytes, and some may also come from the liver or spleen. Under inflammatory or other stimuli, blood monocytes may go rapidly into the alveolar spaces. Usually, however, the macrophage precursor goes through a "maturation" phase in the alveolar interstitium; there is a change in metabolic pattern and enzyme content in this period, and cell division may take place. Macrophage precursors may be seen in the interstitium and are best referred to as interstitial macrophages. The terms "interstitial cell" and "septal cell" have also been used. However, not all interstitial cells are macrophage precursors and the name 'septal cell' has been applied to Type II pneumocytes.

Interstitial macrophages are often irregularly shaped, sending out long sinuous processes (Figs. 15 and 18). A few ribosomes, short profiles of RER, small mitochondria and variably sized membrane-bound lysosomes may be seen in the cytoplasm. These cells are found throughout connective tissue compartments of the lung.

Contractile Interstitial Cells

These cells have long cytoplasmic processes which sometimes partially surround capillaries and pre- or post-capillary vessels (Fig. 19). Typically there are small bundles of myofibrils attached or near to the plasma membrane, particularly adjacent to elastin or collagen fibers in the interstitial space. A few profiles of RER and lipid droplets are found in the cytoplasm. Actin has been demonstrated within the cells by immunofluorescence (22,23).

Contractile interstitial cells have only recently been identified but it is estimated that they make up about 50% of cells in the interstitium. Their function may involve regulation of ventilation-perfusion relationships.

Alveolar Capillaries

Pulmonary capillary endothelium is complete and nonfenestrated; individual squamous endothelial cells resemble those in similar capillaries in other parts of the body (Figs. 14 and 20). Fenestrated capillary endothelium permeable to macromolecules is found

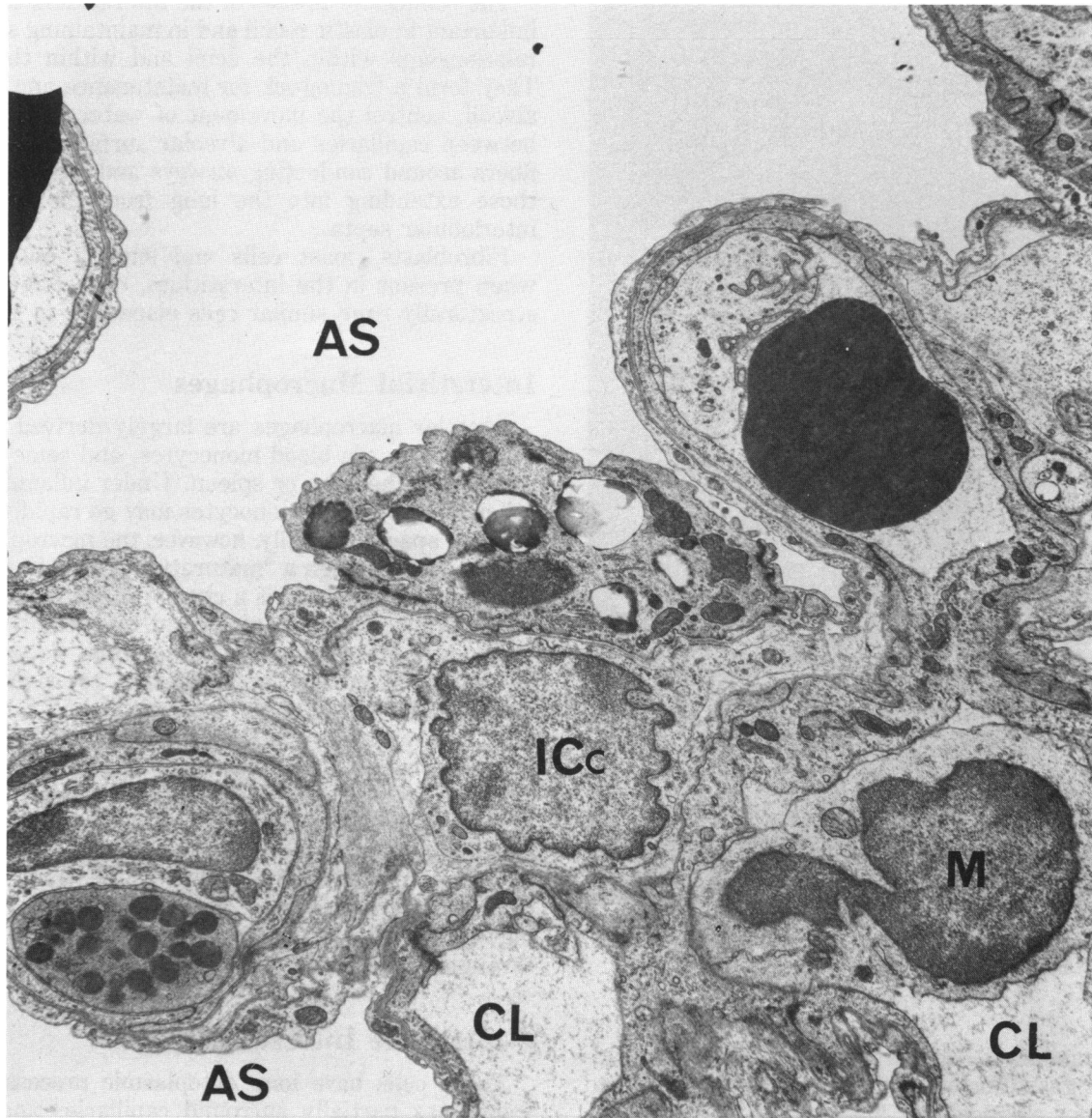


FIGURE 18. Alveolar space (As) is lined by cuboidal Type II pneumonocytes (4). These have surface microvilli, rest on a basement membrane (arrow) and form junctional complexes (J) with adjacent cells. Basement membranes of epithelium and endothelium (arrow) border edematous interstitial connective tissue in which an interstitial macrophage (Ic) is visible. A capillary endothelial cell (Ec) is marked. The Type II pneumonocytes are proliferating to repair the alveolar injury of bovine fog fever. Osmium tetroxide; $\times 6000$.

adjacent to mucous glands and NEBs. Pericytes, contractile cells surrounded by basement membrane, are found in the walls of alveolar capillaries in a number of species (Fig. 21).

Recent investigations have shown that pulmonary endothelial cells are metabolically active and serve a number of important functions in the body. Pulmonary capillary endothelial cells contain many surface caveolae and pinocytotic vesicles and it seems that their surfaces are the site of metabolism of certain adenine nucleotides, vasoactive amines, peptides and prostaglandins, including serotonin, bradykinin and angiotensin 1 (24).

The pulmonary capillary bed has two filtering func-

tions. The first is to act as a trap for emboli, which are subsequently removed by fibrinolysis and phagocytosis by monocytes and endothelial cells. The second is to sequester lymphocytes, granulocytes, megakaryocytes and perhaps circulating macrophages so as to regulate the numbers of circulating leukocytes and platelets.

The intercellular junctions of pulmonary endothelial cells are discontinuous. In parts adjacent cells are held together by zonulae occludentes but there are also intercellular pores approximately 4 nm wide. Small water-soluble molecules can pass freely through these spaces but normally the endothelium is impervious to macromolecules, which are transported across the endo-

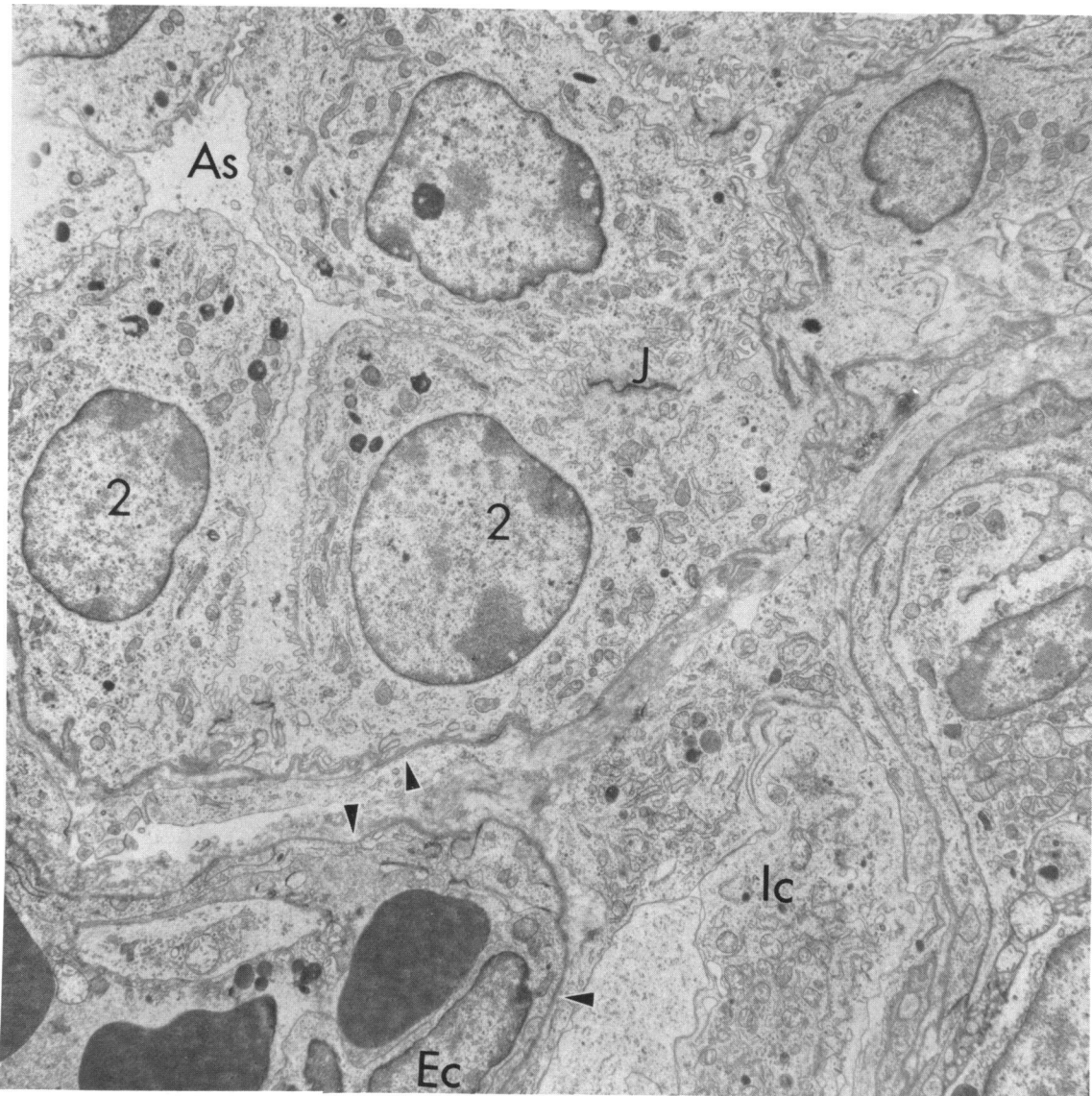


FIGURE 19. An interstitial contractile cell (ICc) lies in the interalveolar septum between two alveolar spaces (AS). This cell has long processes penetrating between the basement membranes of epithelial and endothelial cells. Part of a Type II pneumonocyte is visible and a monocyte (M) is present in the capillary lumen (CL). Osmium tetroxide; $\times 6000$.

thelium and epithelium (in either direction) in pinocytotic vesicles. The tight cell junctions between adjacent epithelial cells serve as a barrier to molecules entering the alveolus (such molecules may nevertheless be transported by epithelial cell pinocytosis). When capillary hydrostatic pressure rises, the endothelial pores may stretch allowing macromolecules to enter the interstitial space.

The endothelial cells of pulmonary arteries and veins have many organelles; pinocytotic vesicles, mitochondria, myofibrils and ribosomes. Weibel-Palade bodies, cylindrical membrane-bound tubules in a fibrillar matrix may be frequently seen in the cytoplasm.

Alveolar Spaces

The alveolar epithelial surface is coated by a layer of pulmonary surfactant and fluid in which lie many free alveolar macrophages.

Pulmonary Surfactant

The extracellular lining layer is poorly preserved after routine fixation through the airways or by immersion. Perfusion via the vasculature or fixing by freeze-substitution demonstrates a duplex layer covering the free luminal cells and the surface epithelium,

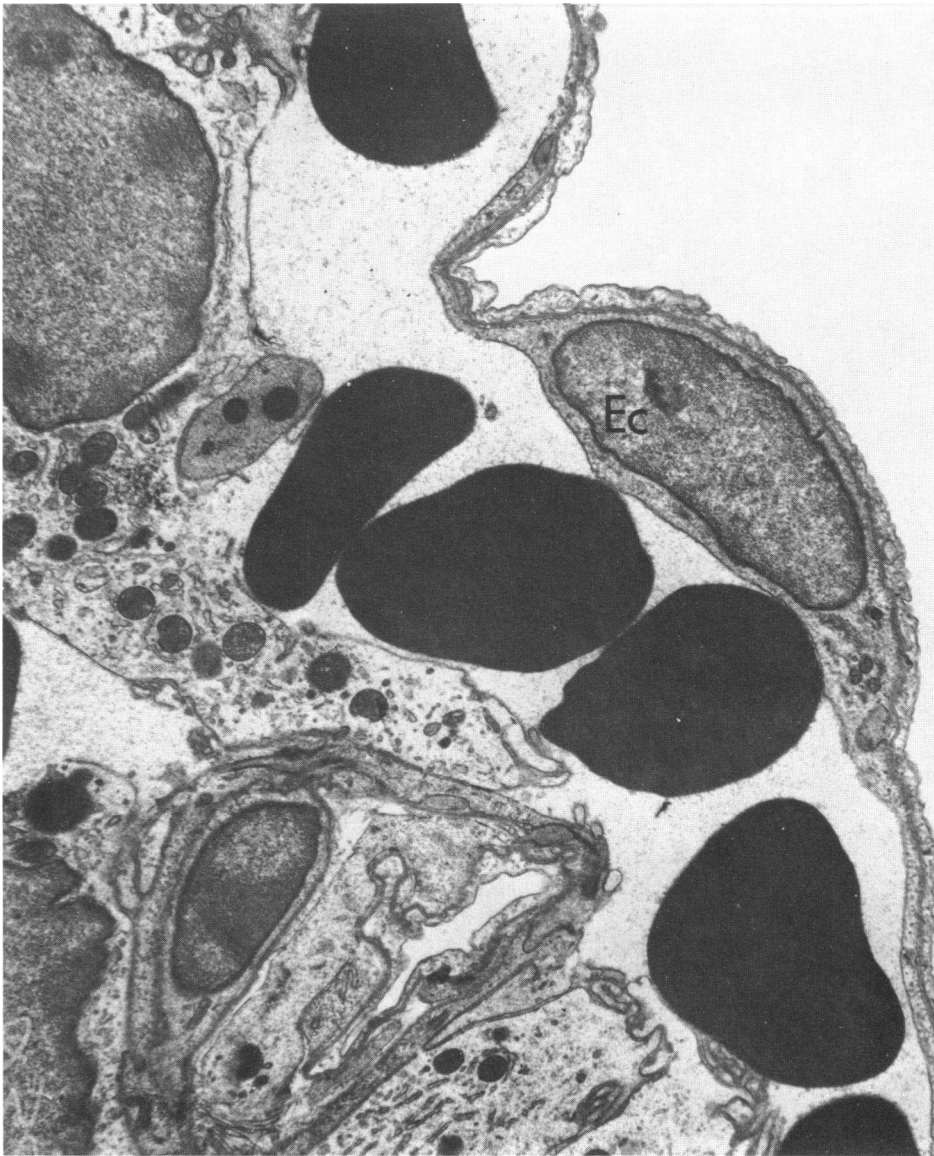

FIGURE 20. Note similarity of endothelial cell (Ec) to that of Type I pneumocyte in Fig. 15 and difficulty of distinguishing between these cells with light microscopy. Osmium tetroxide; $\times 10,000$.

effectively smoothing out the inner contours of the alveolus. The innermost layer, at the air: fluid interface is a mono- or multilamellar film of surfactant phospholipids which reduce surface tension in the alveolus to zero at end expiration. Beneath this, and surrounding projecting cells, is a hypophase containing surface-active and nonsurface-active phospholipids, neutral lipids, serum proteins, such as albumin and α -1-antitrypsin, and carbohydrates (25).

The lamellar bodies of Type II pneumocytes are released into the alveolar spaces, when their phospholipid contents disperse into the hypophase. In doing this, phospholipid-protein complexes are formed. These make up a regular lattice of tubules known as tubular myelin (Fig. 22).

The mechanism of surfactant removal is as yet unclear. Some could be removed via the bronchioles, and some by uptake into epithelial cells or alveolar macrophages.

Alveolar Macrophages

Alveolar macrophages play a major role in phagocytosis and removal of inhaled particles and microorganisms, and in the processing of antigens for humoral and cell-mediated immune responses (26).

Resting macrophages are oval in shape and have a bean-shaped nucleus. Irregular cytoplasmic processes are present; these become more elongated and folded when the cell becomes motile and phagocytic (Figs. 22

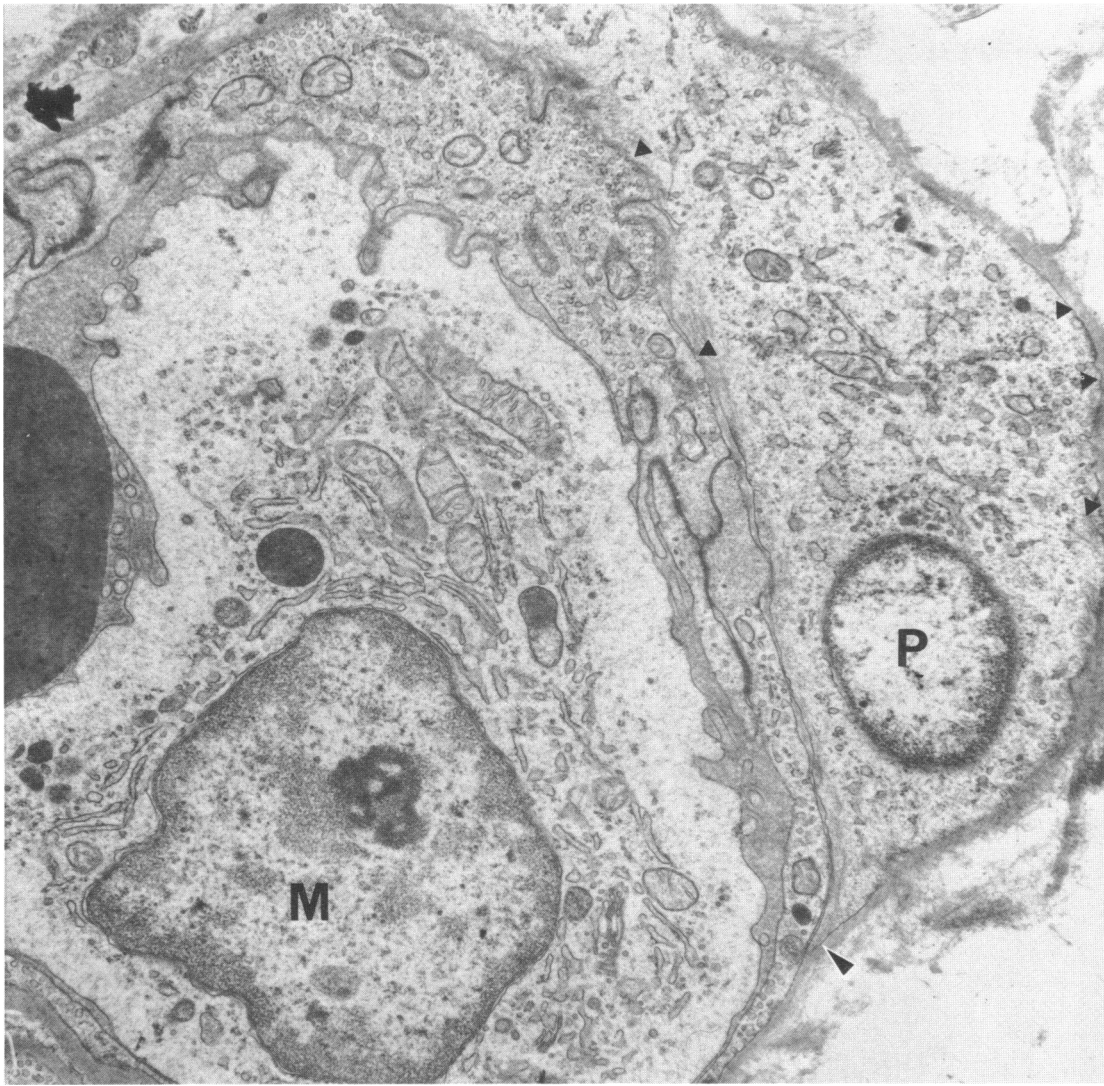


FIGURE 21. A bovine lung pericyte (P) is enveloped by basement membrane on all sides. The basement membrane splits to surround the cell (arrow). The capillary lumen is filled by a monocyte (M). Osmium tetroxide; $\times 15,000$.

and 23). A large perinuclear Golgi zone, ribosomes, and many vesicles and irregularly sized lysosomes and phagosomes are found in the cytoplasm. Some lysosomal granules have a whorled lamellated appearance somewhat similar to the inclusions of Type II pneumocytes. Bundles of fine fibrils and filaments may be seen in the cytoplasm. The lysosomes are rich in hydrolytic enzymes, including proteases, deoxyribonuclease, ribonuclease, β -glucuronidase and acid phosphatase. Release of activated proteases from damaged alveolar macrophages (and leukocytes) may cause connective tissue breakdown leading to the development of emphysema.

Alveolar macrophages are derived from blood monocytes, via interstitial macrophages. Free macrophages are continuously cleared from the alveoli, mostly via the

airways. Few, if any, appear to retrace their paths to carry phagocytosed particles into the interstitium. Interstitial macrophages are responsible for phagocytosis and removal, or storage, of particles that have reached the interstitium across the alveolar epithelium. Interstitial macrophages with their ingested particles presumably migrate through interstitial compartments to reach lymphatics at the periphery of the acini, and thence submucosal lymphoid aggregates and the tracheobronchial lymph nodes.

Free cells may be recovered from bronchoalveolar airspaces by lavage. About 70% of these are macrophages. Most of the rest are lymphocytes. Not all the macrophages are of alveolar origin, some are airway macrophages that may have crossed the tracheobronchial epithelium to lie below the mucus layer.

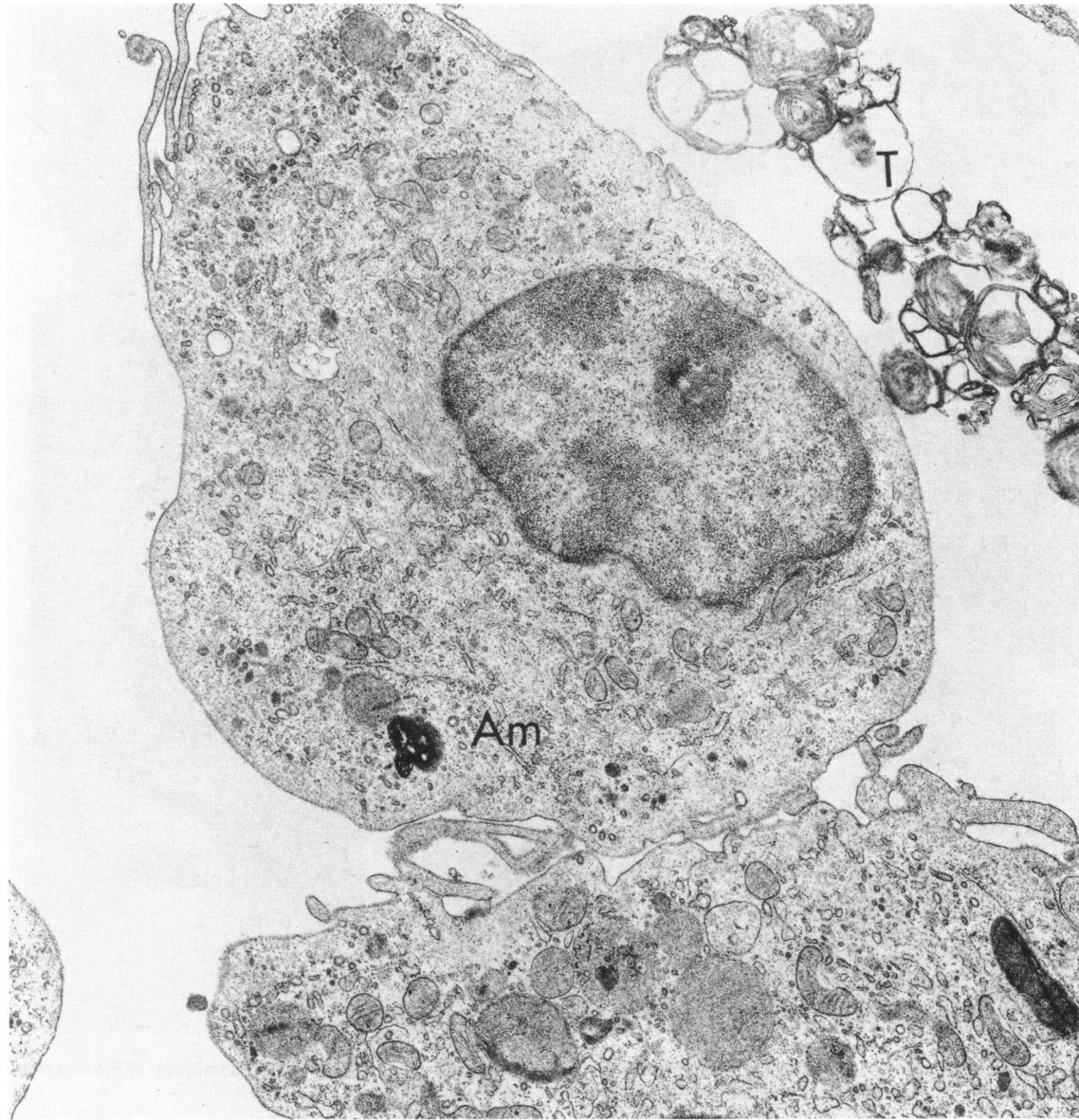


FIGURE 22. Alveolar macrophages (Am) lie in the alveolar space. Note long surface cytoplasmic filopodia, fine cytoplasmic filament bundles and dense phagosomes. Tubular myelin (T) is free in the lumen. Osmium tetroxide; $\times 15,000$.

Lymph Drainage of the Lung

The lungs have two extensive lymph drainage systems (27). The deep lymphatics begin at the level of the alveolar ducts; they do not reach to the interveolar septa except for those "juxta-alveolar lymphatics" found adjacent to the walls of alveoli which are located next to bronchioles, blood vessels, interlobular septa or visceral pleura. Deep lymphatic capillaries run with the conducting airways and arteries toward the hilar lymph nodes and through the BALT. Small capillaries are lined by continuous endothelium without a basement membrane and with few plasmalemmal junctional attachments. Collecting lymphatics have monocuspid valves with smooth muscle and connective tissue in their walls. Like

smaller capillaries, they are anchored by filaments to connective tissue fibers in the interstitium.

The superficial lymphatics drain the visceral pleura through a plexus converging on the hilum.

Respiratory Receptors

The lung is innervated by autonomic parasympathetic fibers from the vagi and by sympathetic fibers from the cranial (upper) thoracic and cervical ganglia. Fibers extend with the airways and blood vessels to the center and periphery of the acinus and to the pleura. Few fibers are found in interalveolar septa.

Nervous reflexes are essential in maintaining control

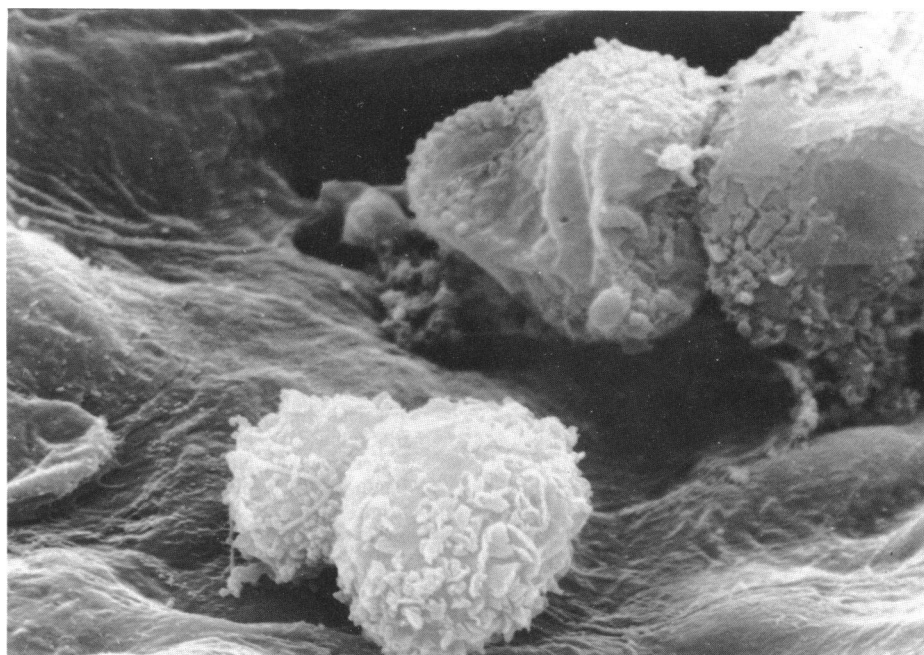


FIGURE 23. Alveolar macrophages in bovine lung. Note the ruffle-like surface folds. Field of view 15 μm .

of breathing and in defending the respiratory system against inhaled irritants. Receptors for many of these reflexes are believed to lie in or below the airway epithelium and in the interalveolar septa (28). The smooth muscle tone of airways and blood vessels and the secretory functions of the mucus-secreting apparatus, Type II pneumocytes, and perhaps K cells and NEBs, are also at least partly under nervous control.

Pulmonary Stretch Receptors

These receptors, located in the smooth muscle of the trachea and large bronchi, respond to airway transmural pressure changes and are involved in the Hering-Breuer reflex. Stimulation produces airway dilatation and lowered inspiratory airway resistance.

Irritant Receptors

Irritant receptors are found in the epithelium of conducting airways and are supplied by smaller myelinated fibers than stretch receptors. These receptors are excited by inhaled dusts and aerosols and mechanical stimulation. Irritant receptors are involved in coughing and usually act to constrict airways. They may also stimulate augmented breaths which open closed airways adjacent to collapsed acini.

Juxtacapillary (J) Receptors

Nonmyelinated vagal fibers are associated with juxtacapillary or J receptors in the interstitium of the interalveolar septa. J receptors are stimulated by irri-

tant gases and congestion and edema of the interstitial space. They appear to cause tachypnea or rapid shallow breathing.

The authors wish to thank Dr. E. M. Allan, University of Glasgow, and Dr. W. L. Castleman and Dr. A. T. Mariassy, University of California, for original electron micrographs.

REFERENCES

1. Breeze, R. G., and Wheeldon, E. B. The cells of the pulmonary airways. *Am. Rev. Resp. Dis.* 116: 705-777 (1977).
2. Sleigh, M. A. The nature and action of respiratory tract cilia. In: *Respiratory Defense Mechanisms, Part I* (J. D. Brain, D. F. Proctor and L. M. Reid, Eds.), Marcel Dekker, New York, 1977, pp. 247-288.
3. Jeffery, P. K., and Reid, L. New observations of rat airway epithelium: a quantitative and electron microscopic study. *J. Anat.* 120: 295-320 (1975).
4. Bonikos, D. S., Bensch, K. G., Watt, T., and Northway, W. H., Jr. Pulmonary oncocytes in prolonged hypoxia. *Exptl. Mol. Pathol.* 26: 92-98 (1977).
5. Frasca, J. M., Auerbach, D., Parks, V. R., and Jamieson, J. D. Electron microscopic observations of the bronchial epithelium of dogs. I. control dogs. *Exptl. Mol. Pathol.* 9: 363-379 (1968).
6. Cutz, E., Chan, W., Wang, V., and Conen, P. E. Ultrastructure and fluorescence histochemistry of endocrine (APUD-type) cells in tracheal mucosa of human and various animal species. *Cell Tissue Res.* 158: 425-437 (1975).
7. Hage, E. Histochemistry and fine structure of endocrine cells in foetal lungs of the rabbit, mouse and guinea-pig. *Cell Tissue Res.* 149: 513-530 (1974).
8. Lauweryns, J. M., and Peuskens, J. C. Argyrophil (kinin and amine producing?) cells in human infant airway epithelium. *Life Sci.* 8: 577-585 (1969).
9. Wharton, J., Polak, J. M., Bloom, S. R., Ghatei, M. A., Solcia, E., Brown, B. R., and Pearse, A. G. E. Bombesin-like immunoreactivity in the lung. *Nature* 273: 769-770 (1978).

10. Sidhu, G. S. The endodermal origin of digestive and respiratory tract APUD cells. *Am. J. Pathol.* 96: 5-20 (1979).
11. Plopper, C. G., Hill, L. H., and Mariassy, A. T. Ultrastructure of the nonciliated bronchiolar epithelial (Clara) cell of mammalian lung. III. A study of man with comparison of 15 mammalian species. *Exptl. Lung Res.* 1: 171-180 (1980).
12. Boyd, M. R. Evidence for the Clara cell as a site of cytochrome P450-dependent mixed function oxidase activity in lung. *Nature* 269: 713-715 (1977).
13. Evans, M. J., Cabral-Anderson, L. J., and Freeman, G. Role of the Clara cell in the renewal of the bronchiolar epithelium. *Lab. Invest.* 38: 648-655 (1978).
14. Lauweryns, J. M., Cokelaere, M., and Theunynck, P. Neuroepithelial bodies in the respiratory mucosa of various mammals. A light optical, histochemical and ultrastructural investigation. *Z. Zellforsch.* 135: 569-592 (1972).
15. Hung, K. -S., Chapman, A. L., and Mestemacher, M. A. Scanning electron microscopy of bronchiolar neuroepithelial bodies in neonatal mouse lungs. *Anat. Rec.* 193: 913-926 (1979).
16. Meyrick, B., Sturgess, J. M., and Reid, L. A reconstruction of the duct system and secretory tubules of the human bronchial submucosal gland. *Thorax* 24: 729-736 (1969).
17. Bienenstock, J., and Johnston, N. A morphologic study of rabbit bronchial lymphoid aggregates and lymphoepithelium. *Lab. Invest.* 35: 343-348 (1976).
18. Kuhn, C. The cells of the lungs and their organelles. In: *The Biochemical Basis of Pulmonary Function* (R. G. Crystal, Ed.), Marcel Dekker, New York, 1976, pp. 3-48.
19. Meyrick, B., and Reid, L. The alveolar wall. *Brit. J. Dis. Chest* 64: 121-140 (1970).
20. Kikkawa, Y., Yoneda, K., Smith, F., Packard, B., and Suzuki, K. The type II epithelial cells of the lung. II. Chemical composition and phospholipid synthesis. *Lab. Invest.* 32: 295-302 (1975).
21. Hance, A. J., and Crystal, R. G. The connective tissue of lung. *Am. Rev. Resp. Dis.* 112: 657-711 (1975).
22. Kapanci, Y., Assimacopoulos, A., Irle, C., Zwahlen, A., and Gabbiani, G. "Contractile interstitial cells" in pulmonary alveolar septa. A possible regulator of ventilation-perfusion ratio? Ultrastructural, immunofluorescence and *in vitro* studies. *J. Cell Biol.* 60: 375-392 (1974).
23. Kapanci, Y., Costabella, P. M., and Gabbiani, G. Location and function of contractile interstitial cells of the lungs. In: *Lung Cells in Disease* (A. Bouhuys, Ed.), Elsevier-North Holland, Amsterdam, 1976, pp. 69-82.
24. Junod, A. F. Metabolic activity of the pulmonary endothelium. In: *Lung Cells in Disease* (A. Bouhuys, Ed.), Elsevier-North Holland, Amsterdam, 1976, pp. 285-288.
25. Clements, J. A., and King, R. J. Composition of the surface active material. In: *Lung Biology in Health and Disease, Vol. 2, The Biochemical Basis of Pulmonary Function* (R. G. Crystal, Ed.), Marcel Dekker, New York, 1976, pp. 363-388.
26. Brain, J. D., Godleski, J. J., and Sorokin, S. P. Quantification of origin and fate of pulmonary macrophages. In: *Respiratory Defense Mechanisms, Part 2* (J. D. Brain, D. F. Proctor and L. M. Reid, Eds.), Marcel Dekker, New York, 1977, pp. 849-892.
27. Lauweryns, J. M., and Baert, J. H. Alveolar clearance and the role of the pulmonary lymphatics. *Am. Rev. Resp. Dis.* 115: 625-683 (1977).
28. Widdicombe, J. G. Respiratory reflexes and defense. In: *Respiratory Defense Mechanisms, Part 2* (J. D. Brain, D. F. Proctor and L. M. Reid, Eds.), Marcel Dekker, New York, 1977, pp. 593-630.