

Anatomy of the lactating human breast redefined with ultrasound imaging

D. T. Ramsay, J. C. Kent, R. A. Hartmann and P. E. Hartmann

Biochemistry and Molecular Biology, School of Biomedical and Chemical Sciences, Faculty of Life and Physical Sciences, The University of Western Australia, Crawley, Australia

Abstract

The aim of this study was to use ultrasound imaging to re-investigate the anatomy of the lactating breast. The breasts of 21 fully lactating women (1–6 months post partum) were scanned using an ACUSON XP10 (5–10 MHz linear array probe). The number of main ducts was measured, ductal morphology was determined, and the distribution of glandular and adipose tissue was recorded. Milk ducts appeared as hypoechoic tubular structures with echogenic walls that often contained echoes. Ducts were easily compressed and did not display typical sinuses. All ducts branched within the areolar radius, the first branch occurring 8.0 ± 5.5 mm from the nipple. Duct diameter was 1.9 ± 0.6 mm, 2.0 ± 90.7 mm and the number of main ducts was 9.6 ± 2.9 , 9.2 ± 2.9 , for left and right breast, respectively. Milk ducts are superficial, easily compressible and echoes within the duct represent fat globules in breastmilk. The low number and size of the ducts, the rapid branching under the areola and the absence of sinuses suggest that ducts transport breastmilk, rather than store it. The distribution of adipose and glandular tissue showed wide variation between women but not between breasts within women. The proportion of glandular and fat tissue and the number and size of ducts were not related to milk production. This study highlights inconsistencies in anatomical literature that impact on breast physiology, breastfeeding management and ultrasound assessment.

Key words anatomy; breast; lactation; ultrasound

Introduction

Anatomical diagrams and descriptions of the gross anatomy of the lactating human breast have changed little over the last 160 years and are based on meticulous dissections of the breasts of lactating cadavers (Fig. 1) by Sir Astley Cooper (Cooper, 1840). Furthermore, many of the descriptions and illustrations do not correspond with Cooper's original work. For example, the glandular tissue is depicted as 15–20 lobes radiating out from the nipple (Bannister et al. 1995), whereas Cooper stated that he observed up to 22 ducts leading to the nipple in some women but considered that many of these ducts were not functional and that there were normally fewer than 12 patent ducts opening at the nipple.

Currently, the lactating breast is described in Gray's Anatomy (Bannister et al. 1995) as being composed of glandular and adipose tissue held together by a loose framework of fibres called Cooper's ligaments. There is a wide variation in the distribution of breast tissues between women (Chersevani et al. 1995; Sohn et al. 1999) but not between breasts within women (Bomalaski et al. 2001). Histological studies show that the lobes are composed of lobules, which consist of clusters of alveoli containing lactocytes (mammary secretory epithelial cells) that synthesize breastmilk (Tobon & Salazar, 1975; Fawcett, 1986). The alveoli are connected to very small ducts that join to form larger ducts draining the lobules. These larger ducts finally merge into one milk duct for each lobe. Then under the areola this single milk duct is depicted as widening into a lactiferous sinus (Bannister et al. 1995; Vorherr, 1974) before narrowing at the base of the nipple and terminating at its orifice on the surface of the nipple. The adipose tissue of the breast is typically situated between lobes rather than within lobules.

Correspondence

Dr D. T. Ramsay, The University of Western Australia, M310, 35 Stirling Highway, Crawley WA 6009, Australia. T: +61 (8) 6488 3327; F: +61 (8) 6488 1148; E: donna@cylle.uwa.edu.au

Accepted for publication 24 March 2005



Fig. 1 Artist's impression of the lobes of the breast. The ducts were injected with coloured wax prior to dissection (from Cooper, 1840).

In developed countries, successful positioning and attachment of the baby to the breast is considered a major factor for the establishment and success of lactation (Righard & Alade, 1992). The rationale for correct attachment of the infant to the breast is based on the assumption that it is important that the infant should accept a significant proportion of the areola so that milk can be stripped from the lactiferous sinuses (Righard & Alade, 1992; Jensen et al. 1994).

Apart from dissections performed by Cooper (1840), there has been little investigation into the distribution of ductal structures and duct diameter in the lactating breast since diagnostic methods such as mammography, galactography (the injection of radio-opaque contrast media and subsequent radiography), ductoscopy (the insertion of a small telescopic camera through a nipple orifice) are normally contraindicated in the healthy lactating woman.

Ultrasound is used extensively to investigate the nonlactating breast to distinguish between abnormalities (e.g. cysts, fibroadenomas and malignant changes) and normal structures (e.g. milk ducts, Cooper's ligaments, lymph nodes, glandular and adipose tissue) (Stavros et al. 1995; Sohn et al. 1999). In addition, recent technological advances have increased the ability of ultrasound to resolve very fine structures such as ducts as small as 0.5 mm (Chung & Chun, 1994). Therefore, we have used ultrasound as a noninvasive approach to re-examining the gross anatomy of the lactating breast. This study

has aimed to measure and describe the characteristics of the main portion of the ductal system of the breast such as duct diameter, branching of the ducts and their location in the breast. We also focused upon developing a method using ultrasound imaging to describe and quantify the distribution of the two major tissues of the breast (glandular and adipose tissue) and hence to determine if the quantity of tissues was related to either milk production or calculated storage capacity of the breast.

Materials and methods

Subjects

Twenty-one Caucasian mothers of healthy term infants were recruited from the Western Australian Branch of the Australian Breastfeeding Association. These mothers were participants in a study of the stimulation of milk ejection using an electric breast pump (Kent et al. 2002). The mothers were exclusively breastfeeding (1–6 months lactation), were between the ages of 22 and 38 and had a parity of 1–4 (Table 1). Prior to each scan, the procedure was explained to the mother and a written explanation was provided. The study was approved by the Human Research Ethics Committee; The University of Western Australia and each mother supplied written consent.

Measurement of production and storage capacity

Twenty-four hour milk production was determined for each breast by the test weigh method (Arthur et al. 1987). The babies were briefly weighed using Medela Electronic Baby Weigh Scale (Medela AG, Barr, Switzerland) prior to and after breastfeeding, and milk intake was calculated by subtracting the initial weight of the baby from the final weight of the baby. In addition, milk samples (< 1 mL) were collected from each breast before and after each breastfeed and stored frozen. This procedure was carried out for a 24–28 h period and a corrected 24-h production determined (Arthur et al. 1987).

An estimate of the fat content of each milk sample was made using the creatocrit method (Fleet & Linzell, 1964) as follows. The milk samples were warmed to 37 °C, gently mixed, a subsample taken up into a microhaematocrit tube (Chase Scientific Glass, Inc., Rockwood, TN, USA) and centrifuged (Mikro 12–24, Hettich centrifuge, HD Scientific, Blacktown, NSW, Australia, 15 700 g, 6 min).

Table 1 Mothers' characteristics

Mother	Mother's age (yr)	Parity	Infant's age (wk)	24-h milk production (g)		Mean breastfeed (g)		Storage capacity (g)		Frequency of breastfeeds 24-h	
				Left	Right	Left	Right	Left	Right	Left	Right
1	38	1	23	236	299	53	56	184	223	5	5
2	36	1	20	419	430	106	113	212	232	4	4
3	23	1	22	340	553	78	98	150	174	5	6
4	26	1	17	446	556	80	98	192	177	6	6
5	26	3	22	196	176	25	23	64	56	7	6
6	25	2	12	455	488	90	113	245	192	5	5
7	32	1	22	426	408	93	74	236	223	4	5
8	28	1	20	239	159	62	34	157	86	4	5
9	32	1	18	566	309	83	43	307	187	6	6
10	26	2	12	199	338	67	108	113	182	4	3
11	33	4	12	417	318	91	115	137	199	4	4
12	–	2	13	401	410	59	53	102	121	7	8
13	26	2	16	377	436	111	119	209	195	4	4
14	30	1	23	371	586	75	121	135	202	5	5
15	28	2	7	321	368	57	48	195	142	7	7
16	32	2	7	383	598	64	98	132	355	5	5
17	22	1	23	420	472	46	49	149	171	8	9
18	30	1	19	418	341	61	44	155	136	7	8
19	26	3	22	497	358	116	99	180	154	5	4
20	32	2	6	502	379	54	43	199	161	7	7
21	32	1	15	531	570	110	91	193	197	4	4
22	37	2	26	297	319	84	84	167	118	4	4

The creatocrit was calculated as the length of the column of cream in the tube divided by the total length of the column of milk (Fleet & Linzell, 1964).

The fat content of the milk is related to the degree of emptying of the breast. For example, a full breast would provide a milk sample with a low fat content and a breast drained of milk would provide a milk sample with a high fat content. Daly et al. (1993) have described the equation relating the fat content of the milk to the degree of emptying of the breast, and the degree of fullness is calculated as $1 - \text{degree of emptying}$. Thus, the creatocrit was used to determine the degree of fullness of the breast at the particular time the sample was collected (Daly et al. 1993; Cox et al. 1996). From these data, it was determined when the breast was full and when it was most drained of milk over the course of the day. The storage capacity (the amount of milk available to the infant when the breast is full) was determined using a regression line relating change in degree of fullness at each feed to the amount of milk removed from the breast at that feed. Assuming that a change in degree of fullness of zero corresponds to a feed amount of zero, the regression line was forced to pass through the origin. Storage capacity could then

be calculated as the amount of milk corresponding to a change in degree of fullness of 1.

Ultrasound equipment

The mothers' breasts were scanned with an Acuson XP10 (Siemens, Mountain View, CA, USA) ultrasound machine with a linear array transducer (5–10 MHz). The superficial organ preset was utilized and adjustments were made to optimise the image. Average setting values were a gain of 7 db and a dynamic range of 57 db, with three foci for anatomical scans and a single focus for lactiferous ducts. Tests determining the performance of the ultrasound system were verified using a multi-purpose phantom (model 539, 1992, ATS Laboratories, Inc, CT, USA). Parker Ultrasonic Gel (Fairfield, NJ, USA) was used for the scans.

Ultrasound imaging of the anatomy of the breast

Ultrasound scans were performed on both breasts for each mother and the scans were recorded on video for later analysis. The ultrasound images were annotated using the clock method, which divides the breast into

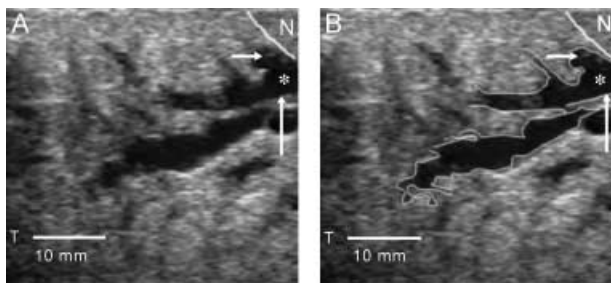


Fig. 2 (A) Ultrasound image of milk duct in the lactating breast. The duct appears as branching hypoechoic structure within echogenic glandular tissue. (B) The ducts focused on in this scan are outlined in white. The duct is traced from the nipple (N) to the periphery of the breast. The walls are echogenic (↑) and the lumen hypoechoic (asterisk). The first branch of this duct (→) is imaged almost directly under the nipple.

sectors according to the face of the clock as the observer is looking at the breast (Mendelson, 1998).

Milk ducts were identified as tubular structures with echogenic walls (bright echoes, white; hypoechoic lumen; fewer echoes, dark grey) (Fig. 2) and were easily compressible. Small echoes within the duct corresponding to fat globules in breastmilk were also observed. Milk ducts were identified at the base of the nipple and then traced back into the parenchyma of breast to the limits of detection of the ultrasound equipment. Milk ducts above 0.5 mm in diameter were readily imaged. When scanning ductal systems, care was taken to apply minimum pressure with the transducer so as not to compress the milk ducts, and when necessary colour Doppler flow imaging was used to discriminate between milk ducts and blood vessels. The number of main ducts in each breast was counted and duct diameters measured at the base of the nipple in 17 women. In addition, 62 ducts were traced into the periphery of the breast. Measurements were made of the depth of the main duct and the distance of the first branch from the base of the nipple. The diameter and depth from the skin of the branches of the ducts were also measured (Fig. 3). In 14 women the nipple diameter and areola radius was measured for each breast.

A real-time scan was performed of the whole breast. Using the clock face method, images of the breast tissue were documented along eight radii (12:00, 1:30, 3:00, 4:30, 6:00, 7:30, 9:00 and 10:30 o'clock) of the breast. The images were taken sequentially along the particular axis from the base of the nipple to the outer portion of the breast until the glandular tissue was no longer visualised (Fig. 4). Three to four images were

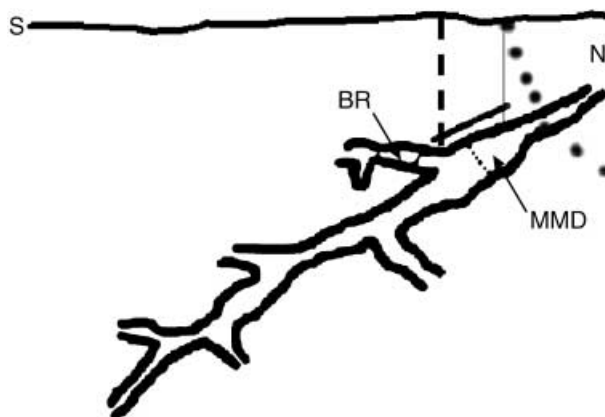


Fig. 3 Diagram of the milk duct coursing deep into the breast from the nipple (N). Measurements were made of the depth (thin solid line) and diameter (dotted line) of the main milk duct (MMD) and the distance of the first branch (BR, thick solid line) from the base of the nipple. The diameter (double line) and depth from the skin (dashed line) of the first branch (BR) of the duct were also measured.

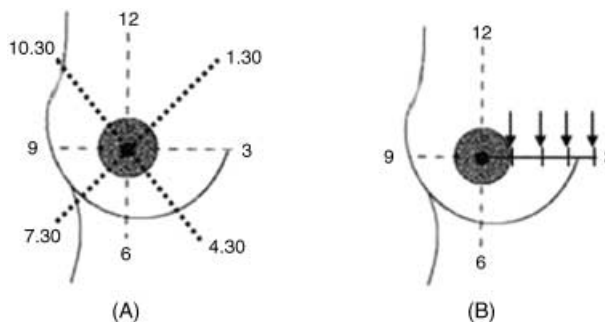


Fig. 4 (A) The right breast divided into sectors according to the face of the clock. (B) The arrows show the four images documented along the 3 o'clock axis. The number of images was dependent on the size of the breast, the axis measured and the extent of the glandular tissue.

documented along the radius, which corresponds with scans measuring up to 120–150 mm from the base of the nipple, depending on the degree of the extension of the glandular tissue. Each image included all of the breast tissue from the skin to the chest wall (pectoral muscles overlying the ribs) and the full extent of glandular tissue from the nipple to the periphery of the breast. On ultrasound, the skin appears as an echogenic line at the top of the image, whereas the adipose tissue appears as hypoechoic tissue. The adipose tissue is located directly under the skin (subcutaneous fat), within the glandular tissue (intraglandular fat) and behind the glandular tissue in front of the pectoral muscle (retromammary fat). The glandular tissue appears as echogenic tissue (Fig. 5) within the breast and its intensity may vary slightly according to how

much milk is in the breast. Measurements were made of the depth of glandular tissue, subcutaneous, intra-glandular and retromammary fat at 30-mm intervals from the base of the nipple for 90–150 mm. The sum of these measurements was taken to be representative of the amount of tissue within the breast. To describe the distribution of tissues within the breast, cumulative totals of each tissue were calculated by summing all of the measurements made in the breast at distances of 0, 30, 60, 90, 120 and 150 mm from the base of the nipple, depending on the size of the breast, the axis measured and the extent of the glandular tissue.

The results were expressed as totals of the tissue in mm and as a percentage of the total tissue of the breast.

Statistical analysis

Results are presented as mean and standard deviation (mean \pm SD) unless stated. Paired *t*-tests were used to show differences between breasts. Correlation coefficients were used to determine relationships among the breast tissues, external anatomy, milk production and storage capacity, and were calculated using the statistical software package SPSS (Windows Standard Version, Release 10.0.1, 27 October 1999; SPSS Inc., Chicago, IL, USA). *P*-values of less than 0.05 were taken to be significant.

Results

Subject characteristics

The 24-h milk production was 387 ± 101 g for the left breast and 407 ± 121 g for the right breast, and there was no significant difference in production between breasts. The storage capacity of the left breast was 169 ± 51 g and 175 ± 54 g for the right breast, and there was no significant difference between breasts. The mean areola radius was 27.8 ± 5.5 mm and 25.6 ± 5.5 mm for the left and right breasts ($n = 14$), respectively. Nipple diameter for the left breast was 15.7 ± 1.8 mm and 15.8 ± 2.4 mm for the right breast ($n = 14$) (Table 1).

Milk duct system

The mean number of main ducts (> 0.5 mm diameter) at the base of the nipple was 9.6 ± 2.9 (range 6–18) and 9.2 ± 2.9 (range 4–14) for the left breast and right breast, respectively, and was not significantly different. The mean diameter of the main ducts at the base of the nipple

was 1.9 ± 0.6 mm (range 1.0–4.4 mm) and 2.1 ± 0.7 mm (range 1.0–4.0 mm) for the left and right breast, respectively, and was not significantly different. Although there was usually an increase in duct diameter at multiple branch points, the 'typical' sac-like appearance of lactiferous sinuses under the areola was not observed during scanning. Both the mean number of ducts and the diameter of the main ducts were not related to nipple diameter, areola radius or milk production for individual breasts. Furthermore, there was no relationship between the number and diameter of the milk ducts in each breast.

The depth of the main collecting branch at the base of the nipple for the left and right breasts was 4.50 ± 1.98 mm and 4.74 ± 1.59 mm, respectively. The distance of the first branch of the main duct from the nipple base was 8.20 ± 6.27 mm in the left breast and 7.00 ± 3.98 mm in the right breast, and the mean diameter of first milk duct branch was 1.35 ± 0.58 mm and 1.25 ± 0.68 mm, respectively. The depth of the first branch was 8.21 ± 3.96 mm in the left breast and 7.20 ± 2.43 mm in the right breast. Of the mothers with areola radius measurements ($n = 14$), the first branch of all of the ducts imaged ($n = 33$) occurred beneath the areola (Fig. 2). There was no significant difference between left and right breasts for any of these measurements.

Breast tissues

The distribution of tissues within the breast is shown in Table 2. There were no significant differences between the amount of glandular tissue, subcutaneous, intra-glandular, retromammary, total fatty tissue or total tissue in the left and right breast for each mother. When the glandular and fatty tissues were expressed as percentages of the total amount of tissue measured, the glandular tissue represented $63 \pm 9\%$ (range 46–83%) of the breast tissue and the fatty tissue represented $37 \pm 9\%$ (range 16–51%) for the left breast.

For the right breast, the glandular tissue represented $65 \pm 11\%$ (range 45–83%) of the breast tissue and the fatty tissue represented $35 \pm 12\%$ (range 9–54%). The subcutaneous fat represented $24 \pm 7\%$, the intra-glandular fat $7 \pm 5\%$ and the retromammary fat $7 \pm 3\%$ of the breast tissue in the left breast. The subcutaneous fat represented $22 \pm 7\%$, the intraglandular fat $6 \pm 4\%$ and the retromammary fat $9 \pm 3\%$ of the breast tissue in the right breast. In addition, in 10 women glandular tissue was identified, extending more than 120 mm from the nipple to the axilla. Of these women, this was

Table 2 The sum of the depths of each of the different tissues (mm) from all points of measurement for left and right breasts for each mother

Mother	Subcutaneous fat		Glandular tissue		Intraglandular fat		Retromammary fat		Total fat		Total tissue	
	Left	Right	Left	Right	Left	Right	Left	Right	Left	Right	Left	Right
1	386	523	782	669	94	88	191	185	672	796	1453	1465
2	285	275	823	721	154	52	80	92	518	419	1342	1140
3	196	62	745	912	14	12	119	128	329	99	1074	1114
4	166	257	654	893	23	46	91	187	281	491	934	1383
5	244	283	866	865	142	138	63	75	450	496	1315	1361
6	173	157	385	293	183	89	49	69	405	315	790	608
7	374	421	605	722	60	69	128	152	562	643	1167	1364
8	150	134	982	663	0	13	46	34	196	182	1178	845
9	595	552	730	942	93	196	58	93	746	842	1476	1783
10	296	230	634	567	38	63	73	55	406	347	1041	915
11	198	323	712	969	22	23	53	79	273	346	985	1394
12	374	330	784	815	109	120	79	106	562	556	1346	1371
13	276	210	727	735	20	22	78	87	376	318	1101	1054
14	208	215	1000	890	268	146	57	89	532	449	1533	1340
15	283	237	643	661	57	76	115	157	455	471	1098	1131
16	250	158	638	687	76	47	141	85	466	290	1105	977
17	418	292	762	666	63	111	108	214	590	617	1351	1283
18	332	122	675	968	0	0	41	68	372	190	1048	1158
19	410	338	742	740	47	103	79	79	535	519	1278	1260
20	246	180	785	844	76	87	63	117	385	384	1170	1228
21	175	171	700	883	0	0	54	96	178	267	929	1150
Mean	287	261	732	767	77	72	84	107	442	430	1176	1206
SD	107	122	128	157	72	52	37	46	143	187	193	244
Mean percentage	24	22	62	64	7	6	7	9	38	36		
CV percentage	37	47	17	20	94	72	44	43	32	43		

observed to be bilateral in six women and unilateral in the remaining four women.

The subcutaneous fat was minimal at the base of the nipple (left: $5.5 \pm 3.4\%$; right: $6.3 \pm 4.2\%$ of the total depth of tissue) and increased gradually to a 30-mm radius of the base of the nipple (left: $17.0 \pm 5.3\%$; right: $18.0 \pm 7.6\%$ of the total depth of tissue), whereas the retromammary fat changed little and was displayed as a relatively uniform fat pad (left: $59.7 \pm 14.7\%$; right: $55.7 \pm 11.0\%$ of the total depth of tissue) under the glandular tissue and was indistinguishable from the subcutaneous fat peripherally. A large proportion of the glandular tissue was located within a 30-mm radius of the base of the nipple (left: $72 \pm 9\%$; right: $70 \pm 8\%$ of the total depth of tissue), whereas approximately half the intraglandular fat was situated amongst the glandular tissue within a 30-mm radius of the base of the nipple (left: $60 \pm 17\%$; right: $53 \pm 24\%$ of the total tissue; Fig. 6). These estimates were consistent with subjective observations of the proportional distribution of glandular and fatty tissue during real-time scanning.

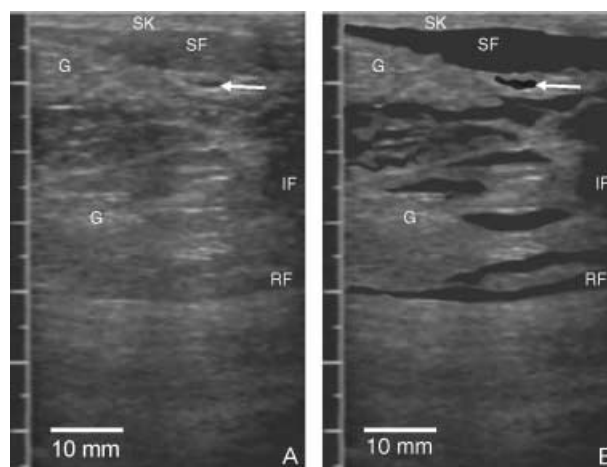


Fig. 5 (A) Ultrasound image of tissues of the lactating breast. (B) The skin (SK) is shown as an echogenic (bright) line at the top of the image. The subcutaneous fat (SF) is less echogenic and situated below the skin. The intraglandular fat (IF) is of similar echogenicity to the subcutaneous fat. The glandular tissue is echogenic (G) while the milk duct (arrow) appears as a hypoechoic (low echo) tubular structure. The retromammary fat (RF) is a thin hypoechoic band along the chest wall.

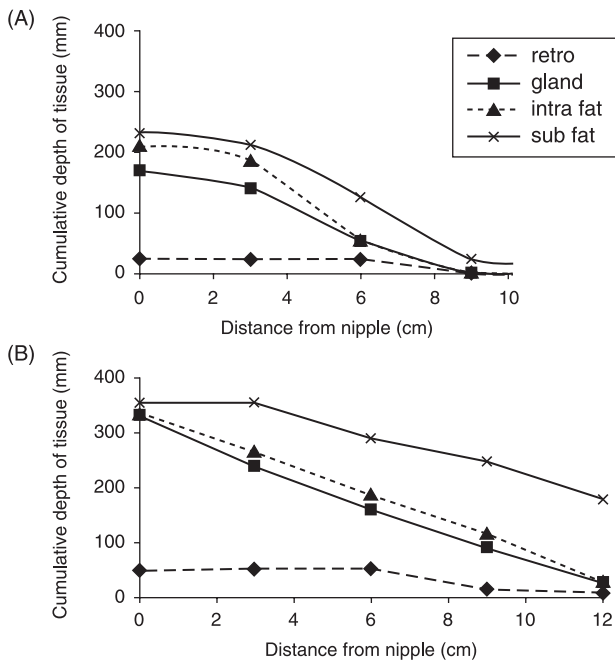


Fig. 6 Distribution of different tissues through the right breast of two different lactating mothers. Cumulative totals of each tissue were calculated by summing all of the measurements made in the breast at 0, 3, 6, 9 and 12 cm distances from the base of the nipple. (A) Mother 1 had a total tissue sum of 1465 mm and a 24-h milk production of 299 g. (B) Mother 9 had a total tissue sum of 790 mm and a 24-h milk production of 176 g.

The amount of glandular tissue was not related to either the amount of subcutaneous, intraglandular, retromammary fat or total fat content in either breast. However, the amount of glandular tissue was related to the total amount of tissue in both breasts (left: $r = 0.69$, $P = 0.001$; right: $r = 0.68$, $P = 0.001$), as was the subcutaneous fat (left: $r = 0.60$, $P < 0.01$; right: $r = 0.75$, $P = 0.001$), intraglandular fat (left: $r = 0.48$, $P < 0.05$; right: $r = 0.519$, $P = 0.016$) and total fatty tissue (left: $r = 0.53$, $P < 0.05$; right: $r = 0.73$, $P < 0.01$). The retromammary fat in both breasts was not related to the total tissue in each breast.

There was no correlation between milk production and the amount of glandular tissue, the number of ducts or the mean diameter of the milk ducts, nor was there a correlation between the amount of glandular tissue and the storage capacity of the breast.

Discussion

Based on the ultrasound findings of this study, we have created an artist's impression of the gross anatomy of the lactating breast (Fig. 7).

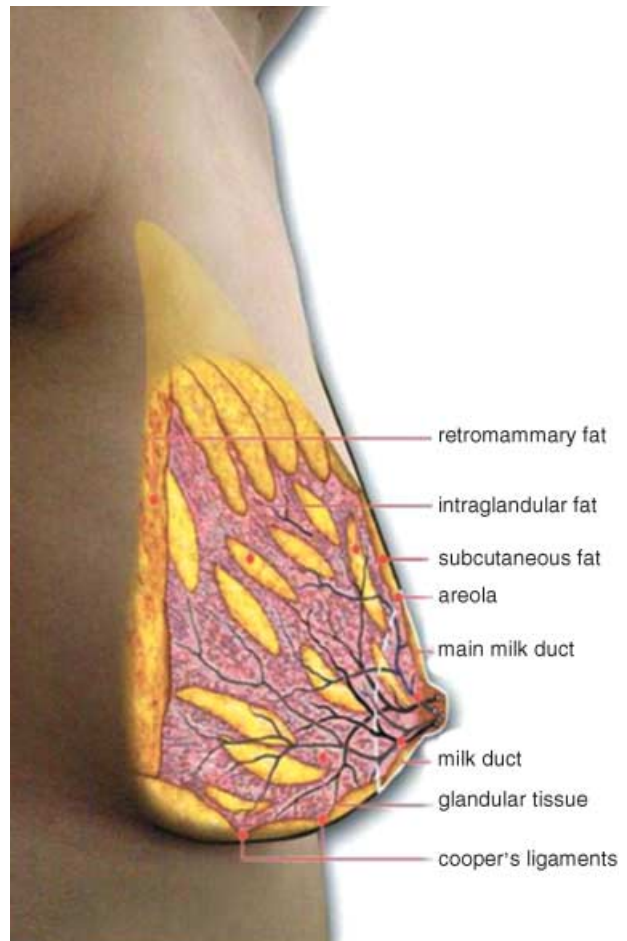


Fig. 7 Drawing of the gross anatomy of the lactating breast based on ultrasound observations made of the milk duct system and distribution of different tissues within the breast.

Ultrasound imaging identified approximately nine milk ducts (range 4–18) in each lactating breast, whereas Gray's Anatomy (Bannister et al. 1995) and many other texts describe 15–20 lobes and milk ducts in the female breast. However, there are some recent studies that are in agreement with our results. Love & Barsky (2004) observed an average of five ducts conveying milk (range 1–17) in lactating women during milk expression with a breast pump. Going & Moffat (2004) identified up to 27 ducts in the mastectomy nipple of a nonlactating breast with only seven having a patent lumen right up to the surface of the nipple. Similarly Love & Barsky (2004) described 5–9 patent ducts within 10 mastectomy nipples. In addition, Teboul & Halliwell (1995) state 5–8 main ducts are observed on ultrasound under the nipple. However, they do not give any detailed statistics nor do they comment on the stage of breast development of the women scanned. In the one lactating nipple that

Going & Moffatt (2004) investigated, they found only four patent ducts. Interestingly, Cooper (1840) injected wax into a maximum of 12 ducts in a lactating cadaver and more often into 7–10 ducts. On one occasion, he observed up to 22 openings on the nipple but not all opened into milk ducts. Our observation of an average of nine milk ducts corresponds with two descriptions in the literature that appear to be based on observation (Kopans, 1989; Love & Lindsey, 1990). In addition, we found no difference in either the number of milk ducts or milk duct diameter between the right and left breast within individual mothers, suggesting that the ductal anatomy is similar in both breasts. However, there was a wide range of mean diameters of milk ducts between mothers (1.0–4.4 mm). Furthermore, as the number and mean diameter of milk ducts were not related to either nipple diameter or areola radius, it was evident that the breast morphology was not predictive of the internal anatomy of the breast.

The milk ducts measured by ultrasound for both breasts had a mean diameter of 2.0 ± 0.8 mm (range 1.0–4.4 mm), which is similar to that observed for nonlactating women (Chersevani et al. 1995; Mendelson, 1998). However, the ducts we observed were in a resting state and are capable of increasing in diameter temporarily to accommodate the increase in milk volume at milk ejection (Ramsay et al. 2004). It is of note that we have occasionally observed milk ducts as large as 10 mm in diameter in mothers not involved in this study. Numerous reports state that the milk ducts increase in size during lactation (Cooper, 1840; Chersevani et al. 1995; Sohn et al. 1999). In contrast, our results imply that during lactation the milk ducts are not enlarged compared with the nonlactating state. In this connection, it should be noted that Cooper injected coloured wax to visualize the ductal system and thus was observing forcibly expanded milk ducts.

The milk ducts at the base of the nipple were superficial (Fig. 2; mean depth 4.6 ± 1.8 mm; range 0.7–7.9 mm), small (2.0 ± 0.8 mm) and easily compressed (Ramsay et al. 2004). These features make them easy to occlude and difficult to palpate. Because the milk ducts were easily occluded by gentle pressure, anecdotal evidence, suggesting that prolonged compression of the milk ducts may cause milk stasis leading to blocked ducts, is plausible (Brodrribb, 1997; Riordan, 2004). In addition, some mothers have milk ducts that are immediately below the areola and, at milk ejection, duct dilation is visible (in the unsuckled breast) for a period of 2–3 min, that is, until milk flow subsides and the dilation reverses (Ramsay et al. 2004).

All of the ducts imaged on ultrasound branched under the areola, very close to the nipple, and did not display the typical sac-like appearance commonly referred to as the 'lactiferous sinus' (Fig. 2). The branches appeared to emanate from the glandular tissue located directly beneath the nipple. Enlargement of the ducts also occurred at points where multiple branches merged, and at these points ducts in the periphery of the breast were sometimes the same size as those near the nipple. Currently it is assumed that the milk ducts near the nipple act as reservoirs for milk and that this milk is available to the infant before and during suckling (Woolridge, 1986; Spangler, 2000). However, recent studies have shown that only small amounts of milk (1–10 mL) can be expressed prior to milk ejection when using an electric breast pump (Mitoulas et al. 2002; Kent et al. 2002) and that the breastfeeding infant consumes little milk prior to milk ejection (Ramsay et al. 2004). After milk is ejected into the main milk ducts, duct dilation occurs. When milk is not removed from the breast, the diameter decreases back to a resting level within approximately 2 min due to the backward flow of milk (Ramsay et al. 2004). The smaller number, size and shape of the ducts observed in this study suggest that the main function of the ducts is the transport rather than storage of milk.

The course of the ducts imaged by ultrasound from the nipple into the breast was diverse and complicated. The ducts were not always arranged systematically in a radial pattern and often the main ducts lay under one another. Cooper (1840) had already noted the erratic course of the ducts in his dissections and likened the milk ducts to the intertwined roots of a tree. In order to illustrate the ducts, however, he separated them and laid them out in an ordered, radial manner for the artist to draw, and it is this image of the ducts that is presented in current illustrations. Our observations are in accordance with Bannister et al. (1995), who describes the lobes to be merged and difficult to separate surgically, and this is reflected in Fig. 7.

We are unaware of any attempts to quantify the amount of glandular and adipose tissue in the lactating breast. Ultrasound is a noninvasive and relatively inexpensive method of assessing the breast. Clinically, only subjective estimates are made of the proportion of glandular and adipose tissue in the scanned breast. Quantitative measurements are not provided because two-dimensional real-time ultrasound imaging produces images that are essentially very thin 'slices' of the breast.

These physical properties of ultrasound make it difficult to determine whether all of the tissue has been scanned or if some areas have been scanned more than once. Therefore, in our attempt to quantify and describe the distribution of tissues we chose consistently reproducible planes to perform measurements.

We found no difference in the amounts of glandular and adipose tissue in either breast for each woman indicating relative symmetry of the breasts. Many texts state that the lactating breast is composed predominantly of glandular tissue (Vorherr, 1974; Cowie et al. 1980; Lawrence, 1994). In addition, histological studies show that during lactation the proportion of glandular tissue increases relative to the adipose tissue (Tobon & Salazar, 1975). The calculated ratio of glandular tissue to adipose tissue is almost 2 : 1 for the lactating women in this study compared with 1 : 1 for nonlactating women (as determined by mammography) (Klein et al. 1995; Heggie, 1996; Jamal et al. 2004), supporting a two-fold increase in glandular tissue during lactation. However, our results suggest that in some women there is an abundance of adipose tissue and it may constitute up to half of the breast tissue. This is in contrast to other species such as the cow and the goat, for which the adipose tissue of the mammary gland is situated predominantly in the subcutaneous and abdominal regions, with very little interspersed between the alveoli (Patton & Jensen, 1976). Also, we have observed that the fat located within the glandular tissue shows the greatest variation between women (coefficient of variation (CV) 94% and 72% for the left and right breast, respectively). It is of interest that within a 30-mm radius of the base of the nipple there is a large amount of glandular tissue relative to adipose tissue (approximately 2.5 times as much). The predominance of glandular tissue, the minimal subcutaneous fat and absence of lactiferous sinuses in this area obviously does not impede the infant's ability to remove milk successfully from the breast. Although we have not demonstrated a relationship between the amount of glandular tissue and milk production, in four out of five women that had a difference of more than 200 g in milk production between breasts there was a trend towards the more productive breast having more glandular tissue. Furthermore, the absence of a relationship between milk production and storage capacity with the amount of glandular tissue, number of milk ducts and size of the milk ducts is consistent with milk production being controlled by the infant's appetite (Daly et al. 1993).

The findings of this study have important clinical implications. Our failure to observe 'lactiferous sinuses' in the lactating breast suggests that the current explanation for the importance of the positioning and attachment of the baby to the breast requires revision. In this connection, further investigation of the importance of positioning of the nipple in the baby's mouth in relation to the suck/breathe/swallow reflex would be of interest. Because the milk ducts are readily occluded by light pressure, a blockage of the duct should be able to be detected readily by visualisation of a noncompressible duct. This is similar to the diagnosis of deep vein thrombosis by ultrasound detection of a noncompressible vein (Fraser & Anderson, 1999). Although the assessment of the amount of glandular tissue in the breast on ultrasound is qualitative rather than quantitative and is often subjective, it is a noninvasive method of assessing the amount of glandular tissue in the breasts of mothers with either very low milk productions or those demonstrating asymmetry of the breasts associated with unilateral lactational failure, which is assumed to be due to a lack of glandular tissue (Neifert et al. 1985). Furthermore, our results are important in relation to breast surgery. The codistribution of glandular and fatty tissue within the breast suggests that it would be difficult to preferentially remove fatty tissue and that retention of tissue within the first 30 mm of the nipple would conserve potential lactating (glandular) tissue in women undergoing reduction mammoplasty. Almost all women had less than the assumed 15–20 ducts and one woman only had four milk ducts leading to the nipple. Therefore, ablation of as few as four ducts could completely impair the subsequent lactation potential of a breast.

Competing interests

Donna Ramsay, Jacqueline Kent and Peter Hartmann have been reimbursed by Medela AG, the manufacturer of breast pumps, for attending several conferences. Funds for research and staff salaries have been provided to Donna Ramsay, Jacqueline Kent and Peter Hartmann by Medela AG.

Acknowledgements

The study was supported by Medela AG (Baar, Switzerland). We thank the late Dr A.T. Cowie for his generous gift of Cooper's books. Ultrasound support was provided

by Acuson (Siemens, Mountainview, CA, USA). Furthermore, research advice from Dr Leon Mitoulas was greatly appreciated.

References

- Arthur PG, Hartmann PE, Smith M (1987) Measurement of milk intake of breastfed infants. *J. Pediatr. Gastroenterol. Nutr.* **6**, 758–763.
- Bannister LH, Berry MM, Collins P, Dyson M, Dussek JE (1995) *Gray's Anatomy*, 38th edn. New York, USA: Churchill Livingstone, pp. 417–424.
- Bomalaski JJ, Tabano M, Hooper L, Fiorica J (2001) Mammography. *Current Opinion Obstetrics Gynecol.* **13**, 15–23.
- Brodribb W (1997) Breastfeeding Management in Australia. Australian Breastfeeding Association, Victoria, Australia: New Lithographics.
- Chersevani R (1995) Tsynoda-Shimizutt, Giuseppetti GM, Rizzalto G Breast. In *Ultrasound of Superficial Structures, High Frequencies, Doppler and Interventional Procedures* (eds Solbiati L, Rizzalto S). New York, USA: Churchill Livingstone.
- Chung SY, Chun BK (1994) Sonographic evaluation of breast tumors associated with nipple discharge. In *Breast Ultrasound Update* (eds Teubner MH, Hackeloer BJ). Basel, Switzerland: Karger, pp. 194–200.
- Cooper AP (1840) *Anatomy of the Breast*. London, UK: Longman, Orme, Green, Browne and Longmans.
- Cowie AT, Forsyth IA, Hart IC (1980) *Hormonal Control of Lactation*. New York, UK: Springer-Verlag.
- Cox DB, Owens RA, Hartmann PE (1996) Blood and milk prolactin and the rate of milk synthesis in women. *Exp. Physiol.* **81**, 1007–1020.
- Daly SEJ, Di Rosso A, Owens RA, Hartmann PE (1993) Degree of breast emptying explains changes in the fat content, but not fatty acid composition, of human milk. *Exp. Physiol.* **78**, 741–755.
- Fawcett DW (1986) Mammary Gland. In: *A Textbook of Histology*, 11th edn (ed. Fawcett, DW). Philadelphia, PA, USA: W.B. Saunders, pp. 901–912.
- Fleet IR, Linzell JL (1964) A rapid method of estimating fat in very small quantities of milk. *J. Physiol.* **175**, 15–17.
- Fraser JD, Anderson DR (1999) Deep venous thrombosis: Recent advances and optimal investigation with ultrasound. *Radiology* **221**, 9–24.
- Going JJ, Moffat D (2004) Escaping from Flatland: clinical and biological aspects of human mammary duct anatomy in three dimensions. *J. Pathol.* **203**, 538–544.
- Heggie JCP (1996) Survey of doses in screening mammography. *Austral. Phys. Eng. Sci. Medical* **19**, 207–216.
- Jamal N, Ng KH, McLean D, Looi LM, Moosa F (2004) Mammographic breast glandularity in Malaysian women: data derived from radiography. *AJR* **182**, 713–717.
- Jensen DJ, Wallace S, Kelsay P (1994) LATCH: a breastfeeding charting system and documentation tool. *J. Obstet., Gynaecol. Neo. Nurs* **23**, 27–32.
- Kent JC, Ramsay DT, Doherty D, Larsson M, Hartmann PE (2002) Response of breasts to different stimulation patterns of an electric breast pump. *J. Hum. Lact.* **19** (2), 179–187.
- Klein DF, Skrobola AM, Garfinkel RS (1995) Preliminary look at the effects of pregnancy on the course of panic disorder. *Anxiety* **1**, 227–232.
- Kopans DB (1989) *Breast Imaging. Anatomy, Histology and Physiology*. Philadelphia, PA, USA: JB Lippincott Co.
- Lawrence R (1994) *Breastfeeding. A Guide for the Medical Profession*, 4th edn. St Louis, MO, USA: Mosby Year Book, pp. 1–57.
- Love SM, Barsky SH (2004) Anatomy of the nipple and breast ducts revisited. *Cancer* **101**, 1947–1957.
- Love SM, Lindsey K (1990) *Dr Susan Love's Breast Book Reading*. USA: Addison-Wesley Co, p. 6.
- Mendelson EB (1998) The Breast. In: *Diagnostic Ultrasound*, 2nd edn (eds Rumack CM, Wilson SR, Charboneau JW), St Louis, USA: p. 755.
- Mitoulas LR, Lai CT, Gurrin L, Larsson M, Hartmann PE (2002) Effect of vacuum profile on breastmilk expression using an electric breast pump. *J. Hum. Lact.* **18**, 353–360.
- Neifert MR, Seacat JM, Jobe WE (1985) Lactation failure due to insufficient glandular development of the breast. *Pediatrics* **76** (5), 823–828.
- Patton S, Jensen RG (1976) Structure and function of mammary epithelium. In: *Biomedical Aspects of Lactation* (eds Patton S, Jensen RG). Oxford, UK: Pergamon Press, pp. 23–24.
- Ramsay DT, Kent JC, Owens RA, Hartmann PE (2004) Ultrasound Imaging of Milk Ejection in the Breast of Lactating Women. *Pediatrics* **113** (2), 361–367.
- Righard L, Alade MO (1992) Sucking technique and its effect on success of breastfeeding. *Birth* **19** (4), 185–189.
- Riordan J (2004) Anatomy and Psychophysiology of Lactation and Breast Related Problems. In: *Breastfeeding and Human Lactation* (ed. Riordan J) 3rd edn. Boston, MA, USA: Jones and Bartlett Publishers, pp. 81–103, 248–249.
- Sohn CS, Blohmer J, Hamper UM (1999) *Breast Ultrasound. A Systematic Approach to Technique and Image Interpretation*. New York, USA: Thieme, pp. 34–35.
- Spangler A (2000) *Breastfeeding. A parent's guide*. 7th edn. Atlanta, USA: Abby Drue Inc, p. 31.
- Stavros AT, Thickman D, Rapp CL, Dennis MA, Parker SH, Sismaney GA (1995) Solid breast nodules: use of sonography to distinguish between benign and malignant lesions. *Radiology*. **196**, 123–124.
- Teboul M, Halliwell M (1995) *Atlas of Ultrasound and Ductal Echography of the Breast*. London, UK: Blackwell Science Ltd, p. 65.
- Tobon H, Salazar H (1975) Ultrastructure of the Human mammary gland. II. Postpartum Lactogenesis. *JCE M.* **40** (5), 834–843.
- Vorherr H (1974) *The Breast: Morphology, Physiology and Lactation*. London, UK: Academic Press, pp. 27–30.
- Woolridge MW (1986) The 'anatomy' of infant sucking. *Midwifery* **2** (4), 164–171.