

Epidural abscess and discospondylitis in a dog after administration of a lumbosacral epidural analgesic

Audrey M. Remedios, Robert Wagner, Nigel A. Caulkett, Tanya Duke

A 5-year-old, neutered male, German shepherd, weighing 35 kg, was presented to the Western College of Veterinary Medicine (WCVM) for tail necrosis. The distal third of the tail was necrotic after being placed inside a bottle in an effort to keep the dog from exacerbating a lick granuloma. Initial physical examination was normal, other than the tail lesion. A complete blood count was within normal range. After premedication with oxymorphone (Numorphan, DuPont Canada, Calgary, Alberta), 0.1 mg/kg/BW, IM, and acetylpromazine maleate (Acepromazine, Ayerst Laboratories, Montreal, Quebec), 0.05 mg/kg/BW, IM, general anesthesia was induced with thiamylal (Thialean, MTC Pharmaceuticals, Cambridge, Ontario), 10 mg/kg/BW, IV, and maintained on halothane (MTC Pharmaceuticals, Cambridge, Ontario). Following standard surgical preparation with chlorhexidine gluconate (Hibitane 4% w/v, Ayerst Laboratories, Montreal, Quebec) and isopropyl alcohol (Isopropyl Rubbing Alcohol 70% USP, Rougier, Chambley, Quebec), spinal needle placement into the epidural space was attempted at the lumbosacral junction. With the needle held perpendicular to the skin and on the dorsal midline, multiple skin penetrations and subcutaneous needle redirections were performed prior to achieving correct epidural placement. A preoperative epidural analgesic of oxymorphone (0.05 mg/kg/BW in 1 mL/10 kg/BW sterile saline) was administered using a 20 gauge, 3.5 inch spinal needle (BD Spinal Needle, Becton Dickinson, Rutherford, New Jersey). The spinal needle, which had a Quincke-Babcock type point, was inadvertently seated to the level of the hub at the skin surface. Tail amputation was performed and healing of the surgical site was uncomplicated.

One week after tail amputation, the dog returned to the WCVM with a 2 d history of inappetence, weight loss, lethargy, depression, reluctance to rise, and stiffness in the hind limbs. On examination, the rectal temperature was 41.1°C. The dog's back was hunched up and severe pain was localized to the lumbosacral region.

A complete blood count, serum chemistry profile, urine culture, radiography, and ultrasonography were performed. Results of the complete blood count included an increase in band neutrophils of $0.931 \times 10^9/L$ (normal, 0 to $0.3 \times 10^9/L$), a lymphopenia of $0.798 \times 10^9/L$ (normal, 1.0 to $4.8 \times 10^9/L$), and a mild increase in protein of 79 g/L (normal, 51 to 72 g/L). The serum biochemistry profile, urine culture, lumbosacral radiographs, and ultrasonography of the dorsal sacral region were normal. The dog was then sedated with acetylpromazine maleate (0.03 mg/kg/BW, IV). Anesthesia was induced with methohexital (Brietal, Eli Lilly, Toronto, Ontario),

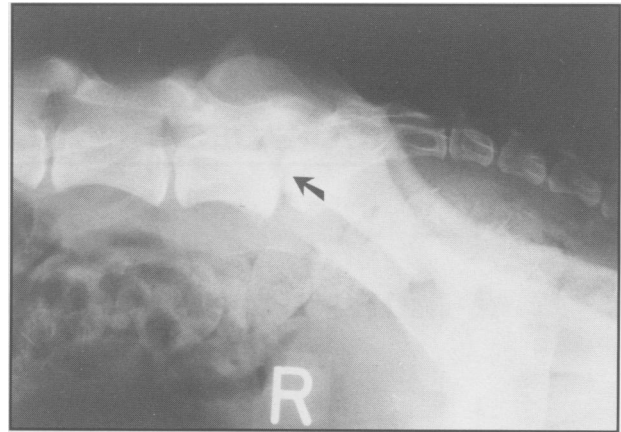


Figure 1. Radiographic changes consistent with discospondylitis, including vertebral endplate lysis and proliferative bony change of the lumbosacral joint (arrow).

5 mg/kg/BW, IV, and maintained on isoflurane (Aerrane, Anaquest, Mississauga, Ontario). Following standard surgical preparation, an aspirate was obtained from the lumbosacral epidural space. An opaque fluid was collected and submitted for cytological analysis, and aerobic and anaerobic bacterial culture and sensitivity testing. Cytological analysis of the epidural fluid did not show any white blood cells but a few gram-positive cocci were observed. Microbiological culture of the sample yielded growth of 2+ *Enterococcus fecalis* and 2+ *Escherichia coli*. The history and epidural culture results indicated a diagnosis of an epidural abscess probably originating from colonic perforation or fecal contamination during administration of epidural analgesia.

The dog was treated initially with trimethoprim-sulfa (Apo-Sulfatrim, Apotex, Toronto, Ontario), 15 mg/kg/BW, PO, q12h, and ampicillin (Penbritin, Ayerst Laboratories, Montreal, Quebec), 20 mg/kg/BW, PO, q12h. Upon receiving results of microbiological sensitivity tests, the protocol was changed to trimethoprim-sulfa, 20 mg/kg/BW, PO, q12h, for 4 wk, and amoxicillin/clavulonic acid (Novo-Cloxin, Novopharm, Toronto, Ontario), 13.73 mg/kg/BW, PO, q12h, for 4 wk. Over the following week, the dog improved slowly. His body temperature, appetite, and hind limb gait returned to normal. He also began rising without encouragement or vocalization of pain. Although signs of lumbosacral pain were diminished, palpation of the lumbosacral region was still uncomfortable.

Four d after cessation of antibiotic treatment, the dog returned to WCVM because of mild signs of lumbosacral pain. No other abnormalities were found on physical and neurological examination. A complete blood count was normal. Radiographs were taken and abnormalities, including vertebral endplate lysis and proliferative bony change, were consistent with a diagnosis of discospondylitis of the lumbosacral region (Figure 1). Under general anesthesia, a fluoroscopic-guided aspirate

of the lumbosacral epidural space was done. Cytological analysis of the aspirate did not show any abnormalities and bacterial culture was negative. The dog improved during the hospital stay and was discharged. The dog continued to recover and did not show any clinical signs at follow-up, 2 y later.

Epidural administration of opioids, alpha2-adrenergic agonists, or local anesthetics is an effective method of controlling postoperative pain, particularly after surgery involving the hind limb, pelvis, or perineal regions (1). The primary advantage of epidural analgesics, particularly opioids, is that prolonged segmental analgesia can be achieved without the sedative effects of parenteral opioid administration. Complications associated with the use of epidural analgesia in humans include delayed respiratory depression, urinary retention, pruritis, nausea, vomiting, and clotting abnormalities (1,2-4). In animals, the frequency of side effects of epidural analgesia is not well defined but appears minimal compared to that in humans (4).

In human patients, epidural catheters are often placed to facilitate long-term administration of analgesics. Although a rare condition, epidural abscess, with or without vertebral osteomyelitis, has been reported in people, even with catheter placement of only 1 to 4 d (5-7). Patients who are immunocompromised, because of preexisting disease or concomitant steroid administration, appear to be more susceptible. Other factors that could contribute to development of epidural abscesses include poor aseptic technique or antecedent trauma at the site of catheter placement, or the use of multiple epidural catheters.

Epidural abscess and lumbosacral discospondylitis associated with the administration of epidural analgesia have not been previously reported in the veterinary literature. In this case, iatrogenic contamination of the intervertebral disc and epidural space probably occurred during spinal needle placement. Both bacterial isolates, *E. fecalis* and *E. coli*, obtained by subsequent epidural aspiration, are common fecal and colonic flora (8). Although standard surgical preparation was performed, fecal contamination and poor aseptic technique may have caused abscess formation. The use of a 3.5 inch spinal needle at the time of epidural administration could have also caused inadvertent penetration of the colon and subsequent bacterial inoculation into the lumbosacral disc, epidural space, and overlying subcutaneous tissues. Upon reviewing the lumbosacral radiographs of this dog, a 3.5 inch needle when seated to the hub at the skin surface could easily have penetrated the lumbosacral disc space and the underlying colon. In addition, the Quincke-Babcock needle has a bevel with sharp edges and a sharp tip. This configuration could have facilitated colonic perforation.

Common causes of discospondylitis are integumentary and urinary tract infections, bacterial endocarditis, and orchitis (9). Bacteria spread hematogenously from these sites and colonize vertebral epiphysis in the lumbosacral, caudal cervical, and midthoracic areas. In this dog, bacterial emboli originating from the necrotic tail could have been a possible focus of infection. However, several factors in this case rendered this scenario unlikely. First, the dog was normal on initial examination, except for the necrotic tail. The absence of clinical signs and normal blood parameters were inconsistent with existing

sepsis and bacterial embolization. Second, the time duration between epidural administration and occurrence of clinical signs strongly favoured a postoperative complication. Third, the isolation of both *E. fecalis* and *E. coli* from the epidural fluid suggests a common site of infection. These bacteria are normal and abundant inhabitants of the lower gastrointestinal tract. Fourth, sepsis stemming from *E. fecalis* infection has been reported in dogs and cats, but the bacteria usually migrate from the urinary tract or lower bowel (10). Fifth, *E. coli* has been identified as an infrequent vertebral pathogen, but an association between *E. fecalis* and discospondylitis has not been established in the veterinary literature. Lastly, discospondylitis is primarily an osteomyelitis and, as such, rarely reflects cerebrospinal fluid abnormalities, except for mild protein elevation (9). In this case, the opaque contaminated fluid aspirated from the epidural space indicated an epidural abscess in addition to discospondylitis.

To avoid complications, such as epidural abscess and discospondylitis, the skin above the lumbosacral space should be surgically prepared and strict aseptic technique utilized. Long spinal needles, such as 3.0 and 3.5 in, should not be used routinely to administer epidural analgesia in the lumbosacral space. Except in the extremely obese animal, 1.5 to 2.5 in spinal needles can be used in most large breed dogs. In the obese large dog where identifiable anatomic landmarks are obscure, use of the long spinal needle can be justified but only when placed by an experienced operator. In these animals, use of a blunt, needle such as the Whitacre needle, which has a rounded bevel and no cutting edges, may decrease iatrogenic trauma. Spinal needles should also be advanced slowly and cautiously to detect the loss of resistance as the needle passes through the interarcuate ligament and enters the epidural space. A test injection with a small amount of saline can be administered to be sure the needle tip is not seated in a venous sinus or subarachnoid space. Administration of other materials in this region, such as contrast agents, should also follow similar guidelines.

CVJ

References

1. Bromage PR, Camporesi E, Chestnut D. Epidural narcotics for postoperative analgesia. *Anesth Analg* 1980; 59: 473-480.
2. Davies GK, Tolhurst-Cleaver CL, James TL. Respiratory depression after intrathecal narcotics. *Anaesthesia* 1980; 35: 1080-1083.
3. Magumi T, Doni S. Spinal subarachnoid hematoma after lumbar puncture in a patient receiving antiplatelet therapy. *Anesth Analg* 1983; 62: 777-779.
4. McMurphy RM. Postoperative epidural analgesia. *Vet Clin North Am Small Anim Pract* 1993; 23: 703-716.
5. Strong WE. Epidural abscess associated with epidural catheterization: a rare event? Report of two cases with markedly delayed presentation. *Anesthesiology* 1991; 74: 943-946.
6. Bromage PR. Spinal extradural abscess: pursuit of vigilance. *Br J Anaesth* 1993; 70: 471-473.
7. Strafford MA, Wilder RT, Berde CB. The risk of infection from epidural analgesia in children: A review of 1620 cases. *Anesth Analg* 1995; 80: 234-238.
8. Falkow S, Mekalanos J. Enteric bacilli. In: Davis BD, Dulbecco R, Eisen HN, Ginsberg HS, eds. *Microbiology*. 4th ed. Philadelphia: WB Saunders, 1990: 561-588.
9. Kornegay JN. Discospondylitis. In: Slatter D, ed. *Textbook of Small Animal Surgery*. 2nd ed. Philadelphia: WB Saunders, 1993: 1087-1094.
10. Greene CE. Streptococcal and other gram-positive bacterial infections. In: Greene CE, ed. *Infectious Diseases of the Dog and Cat*. Philadelphia: WB Saunders, 1990: 599-609.