

## EXPERIMENTAL THYROIDITIS IN THE RHESUS MONKEY

### IV. THE ROLE OF THYROGLOBULIN AND CELLULAR ANTIGENS

J. A. ANDRADA, N. R. ROSE AND J. H. KITE, JR\*

*Department of Bacteriology and Immunology, State University of New York at Buffalo, School of Medicine, Buffalo, New York*

(Received 29 August 1967)

#### SUMMARY

Nine normal rhesus monkeys were injected with homologous thyroid preparations, consisting either of a crude extract, partially purified thyroglobulin, or enzymatically dispersed viable cells. One monkey was injected with a preparation of heterologous human thyroid microsomes. The course of the disease was followed by periodic biopsies of the thyroid gland and by circulating antibodies. The latter were detected by tanned cell haemagglutination, complement fixation and cytotoxicity. The serum was also examined for levels of complement and for thyroid hormones.

Injection of partially purified monkey thyroglobulin resulted in the production of antibody both to thyroglobulin and to the cellular antigen. Inoculation of enzymatically dispersed viable thyroid cells led to a greater production of cytoplasmic antibody with a small and delayed production of antibody to thyroglobulin. Heterologous immunization of a monkey with human thyroid microsomes resulted in the production of autoantibodies to thyroid and minimal thyroid damage. There was considerable variation in antibody response and degree of tissue injury in different monkeys although injected with a similar antigen. There was no consistent association between circulating antibodies and pathological changes in the thyroid gland. Levels of complement varied but showed a definitive decrease in some animals with thyroiditis. There was no correspondence between tissue damage and protein bound iodine or thyroxine iodine.

#### INTRODUCTION

Experimental thyroiditis has been produced in the rhesus monkey *Macaca mulatta* by repeated injections of a crude extract of monkey thyroid gland together with complete Freund's adjuvant (Rose *et al.*, 1965; Kite, Argue & Rose, 1966; Doebbler & Rose, 1966; Rose *et al.*, 1966). The disease differed from that developed by rabbits, guinea-pigs and other experimental animals in several respects. The degree of thyroidal inflammation was

Correspondence: Dr N. R. Rose, Department of Bacteriology and Immunology, State University of New York at Buffalo, School of Medicine, 321 Sherman Hall, Buffalo, New York 14214.

\* This work was done during the tenure of the Otto G. Storm Fellowship of the American Heart Association.

generally greater, although considerable variation was encountered from animal to animal both in the extent and the sequence of pathological alterations. Like the rabbit and the guinea-pig, immunized monkeys manifested circulating autoantibodies to homologous thyroglobulin demonstrable by tanned cell haemagglutination or precipitation-in-gel. In contrast to these experimental animals, thyroglobulin autoantibodies of monkey origin failed to give complement fixation reactions with homologous thyroglobulin preparations. However, a second and, perhaps, third type of autoantibody were present in monkey serum directed toward constituents of the monkey thyroid epithelial cell. These latter antibodies were revealed using complement fixation and cytotoxic tests, as well as mixed agglutination and immunofluorescence. The cytoplasmic antigen or antigens sediment in the ultracentrifuge in the microsomal fraction and are distinguishable by absorption tests with soluble thyroglobulin (Roitt *et al.*, 1964). In these respects, therefore, monkey thyroiditis more closely parallels the human disease, chronic thyroiditis, than do the analogous experimental disorders of rabbits and guinea-pigs.

The present report provides further data on the production of experimental thyroiditis in monkeys. Emphasis is placed on the fluctuation in antibody response, complement levels, thyroid function, and histological changes. The role of soluble thyroglobulin *versus* cellular constituents as stimulating antigens is explored. Finally the use of a cross-reacting microsomal preparation of human origin is tested.

## MATERIALS AND METHODS

The procedures for preparing monkey thyroid crude extracts for immunizing rhesus monkeys (*Macaca mulatta*) and for carrying out histological and pathological examinations have all been described in detail in previous publications in this series (Kite *et al.*, 1966; Doebbler & Rose, 1966; Rose *et al.*, 1966).

### *Thyroid cell suspension*

Preparation of a washed viable suspension of monkey thyroid cells by enzymatic treatment of minced tissue with collagenase and trypsin employed the same method used in the cytotoxic antibody test. Details of this procedure have been given (Kite *et al.*, 1965). Freshly prepared cells from both lobes of one monkey thyroid were divided and used for each injection of two monkeys.

### *Thyroglobulin*

A saline extract of pooled monkey thyroid tissue was adjusted to 1% total protein concentration by the biuret method. A half volume of a saturated solution of neutralized ammonium sulphate was added and mixing allowed to proceed for 30 min at room temperature. The precipitate formed was discarded. To the supernatant was added additional ammonium sulphate to bring the final concentration to half saturation. The precipitate was washed twice with half saturated ammonium sulphate, redissolved in buffered saline solution at pH 7.2 and the protein concentration adjusted to 1%.

### *Complement levels*

The procedure described by Kabat & Mayer (1961) was employed, and the levels of complement (C') expressed as C'<sub>50</sub> units.

*Serum iodine levels*

Samples of monkey serum were submitted to Bio-Science Laboratories, Van Nuys, California for determination of protein-bound iodine (PBI) and butanol extractable 'thyroxine' iodine (BEI) levels. Examination of twelve normal monkeys revealed the usual range of these biochemical parameters in the monkey as: PBI, 3.5-4.5 mg/100 ml; BEI, 2.5-3.5 mg/100 ml.

RESULTS

In order to explore the variation involved in autosensitization of monkeys to monkey thyroid crude extract, four animals were immunized using the methods described previously. A summary of the injection schedules and of the immunological response is presented in the first four tables. Monkey 'Olive' (Table 1) died 20 days after a single injection of monkey

TABLE 1. Serum titres obtained following the injection of monkey 'Olive' (female)

Day	Tanned cell haemagglutination	Complement fixation	Cytotoxic antibody	Complement levels (C <sub>50</sub> units)
0	0	0		30
0	Injected with 1.0 ml monkey thyroid crude extract plus Freund's complete adjuvant			
7	0	0	100	49
14	128	4	100	46
20	Autopsy: severe generalized infiltration (Fig. 1)			

thyroid extract. Even in this short period of time antibodies to thyroid developed. Cytotoxic antibodies were especially prominent, being detectable after 7 days in a titre as high as has been found in other monkeys receiving many injections. Positive reactions in tanned cell haemagglutination and complement fixation were found on the 14th day. When the animal died suddenly, the thyroid gland was markedly infiltrated by many large mononuclear and polymorphonuclear leucocytes superimposed on a preserved thyroid follicular structure (Fig. 1).

Monkey 'Pete' (Table 2) was observed over a period of 108 days while receiving three injections of monkey thyroid crude extract plus complete Freund's adjuvant. After two injections it developed a modest titre in the tanned cell haemagglutination test. The titre was not raised by a booster injection. In fact, it decreased towards the end of the observation period. Complement-fixing antibodies were never found in this animal, but cytotoxic antibodies in low titre were detected in three examinations carried out near the end of immunization. Complement levels decreased to a low value of 17 C<sub>50</sub> units on the 87th day. The level soon returned to the normal range (37 ± 7.5). A biopsy performed 37 days after the first injection revealed that the thyroid gland was largely replaced by chronic inflammatory elements (Fig. 2). Only a few traces of shrunken thyroid follicles were seen. This examination was carried out at a time when circulating antibodies were not measurable in the serum of this animal and complement levels were essentially normal. Histological examination of the thyroid at autopsy presented essentially the same picture as the earlier biopsy (Fig. 3). The thyroidal structure was almost completely obscured by inflammatory

cells. Largely unorganized sheets of cuboidal epithelial cells were seen in the background. Tests for serum iodine performed before immunization revealed a PBI of 4.8 and a BEI of 4.5. Examinations performed at the time of the first biopsy (37 days) yielded a PBI of 1.5 and a BEI of 1.0. These findings were interpreted as indicating significant hypothyroidism in this animal.

Monkey 'Cathy' (Table 3) was injected on approximately the same schedule as 'Pete'. Antibodies measurable by the tanned cell haemagglutination test did not appear before the 67th day. Following a booster injection they rose rapidly to a titre of 512 and remained at a relatively high level throughout the course of study. Complement-fixing antibodies were

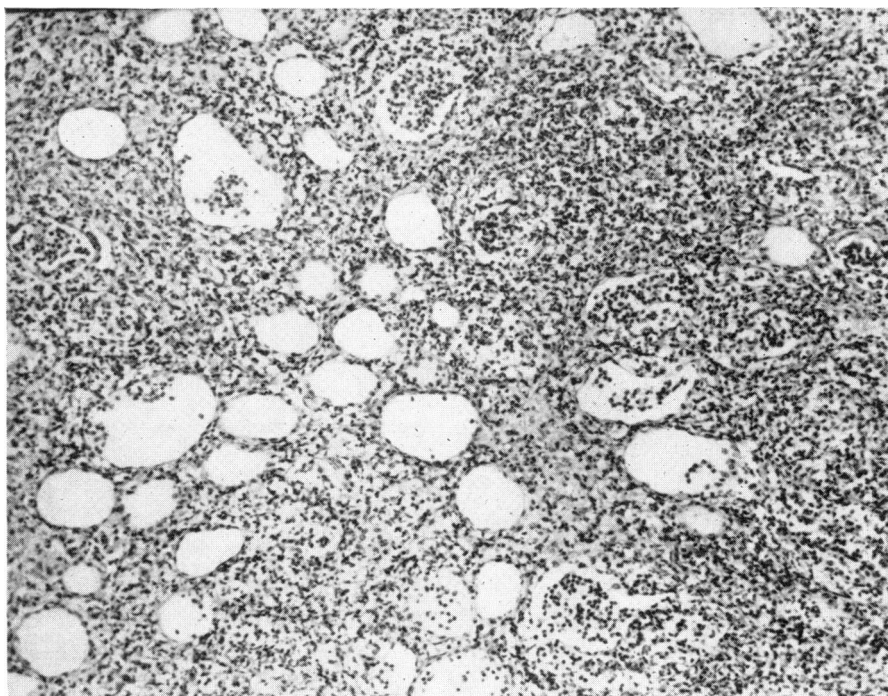


FIG. 1. Biopsy of the thyroid gland of monkey 'Olive' taken 20 days after the first injection. There is a marked infiltration of many large mononuclear and polymorphonuclear leucocytes superimposed on a preserved thyroid follicular structure. H & E,  $\times 100$ .

first encountered on the 19th day and remained at a low level throughout the disease. Cytotoxic antibodies were also present, especially toward the end of the experiment. At about the same time complement levels also showed significant decreases. Histologically, the biopsy taken early after a single injection revealed a normal thyroid (Fig. 4). The autopsy specimen at 130 days showed areas of intense infiltration and distortion of thyroid follicular structure with other portions of the gland entirely normal in appearance (Fig. 5). No significant decrease in levels of serum iodine were found; as a matter of fact, the serum sample taken at the time of killing had a PBI of 6.4 and a BEI of 4.1, suggesting a small degree of hyperthyroidism.

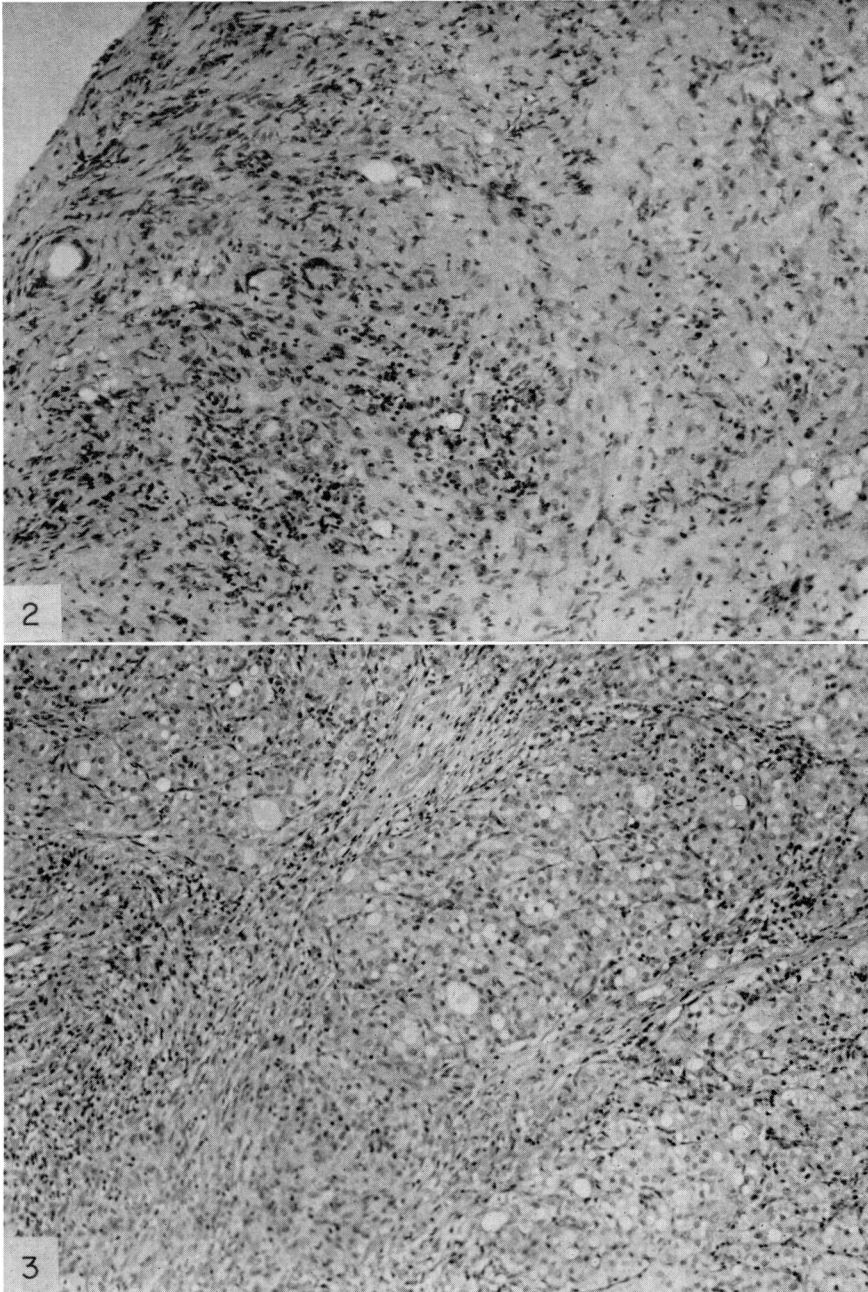


FIG. 2. Biopsy of the thyroid gland of monkey 'Pete' taken 37 days after the first injection. Considerable infiltration of inflammatory cells. Only a few traces of shrunken thyroid follicles are seen. H & E,  $\times 100$ .

FIG. 3. Biopsy of the thyroid gland of monkey 'Pete' taken 108 days after the first injection. A similar histological picture to the earlier biopsy (Fig. 2). Largely unorganized sheets of cuboidal epithelial cells are seen in the background. H & E,  $\times 100$ .

TABLE 2. Serum titres obtained following the injection of monkey 'Pete' (male)

Day	Tanned cell haemagglutination	Complement fixation	Cytotoxic antibody	Complement levels (C <sub>50</sub> units)
0	0	0		36
0	Injected with 1.0 ml monkey thyroid crude extract plus complete Freund's adjuvant			
7	0	0	0	41
14	4	0	0	54
21		0	0	29
28	0	4	0	34
35	0	0		38
37	Biopsy: severe inflammation (Fig. 2)			
48	0	0	0	47
48	Injected with 1.0 ml monkey thyroid crude extract plus complete Freund's adjuvant			
56	64	0	0	40
64	32	0	0	
70	16	0	10	30
78	16	0	10	
87	32		10	17
87	Injected with 1.0 ml monkey thyroid crude extract plus complete Freund's adjuvant			
98	16	0	0	47
108	4			38
108	Autopsy: severe infiltration (Fig. 3)			

TABLE 3. Serum titres obtained following the injection of monkey 'Cathy' (female)

Day	Tanned cell haemagglutination	Complement fixation	Cytotoxic antibody	Complement levels (C <sub>50</sub> units)
0	0	0		34
0	Injected with 1.0 ml monkey thyroid crude extract plus complete Freund's adjuvant			
7	0		0	48
11			10	
13	Biopsy: normal (Fig. 4)			
18	0	16	10	65
28	0			60
31	Injected with 1.0 ml monkey thyroid crude extract plus complete Freund's adjuvant			
39	0	4	0	39
50	0			39
67	2	4	0	33
74	Injected with 1.0 ml monkey thyroid crude extract plus complete Freund's adjuvant			
81	512	4	100	38
102	128		10	24
110			0	
117	Injected with 1.0 ml monkey thyroid crude extract plus complete Freund's adjuvant			
126	256	4	100	18
130	Autopsy: moderate inflammation (Fig. 5)			

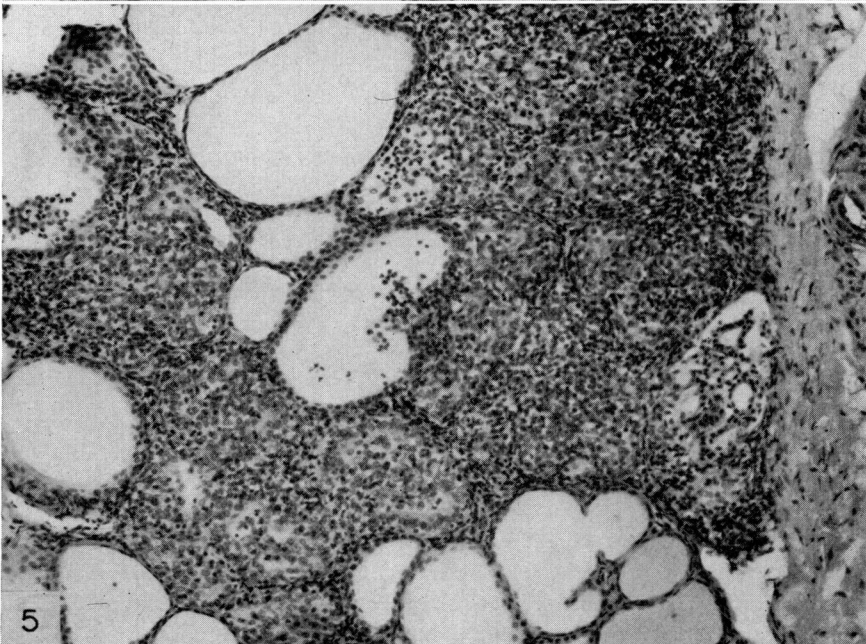
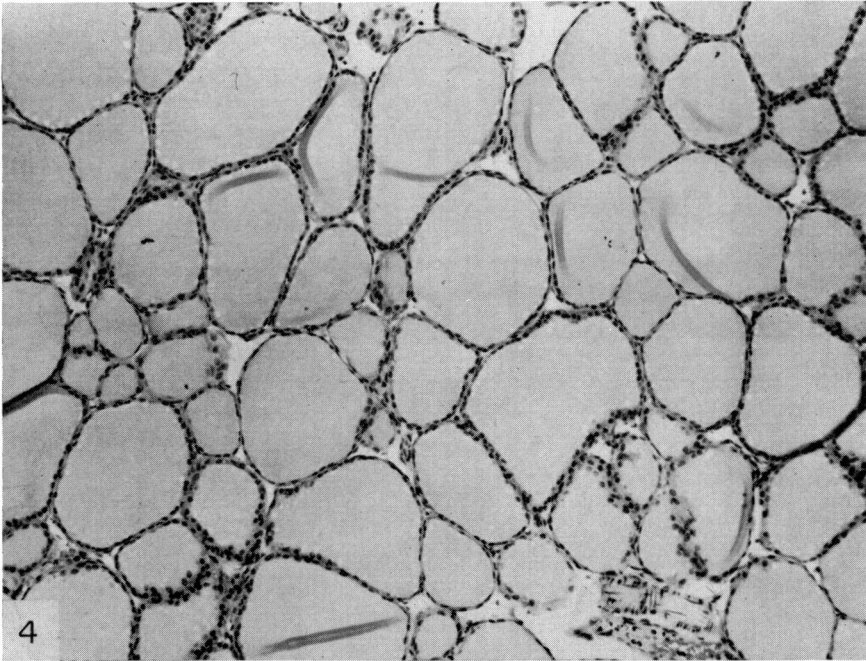


FIG. 4. Biopsy of the thyroid gland of monkey 'Cathy' taken 13 days after the first injection. The thyroid gland appeared normal. H & E,  $\times 100$ .

FIG. 5. Biopsy of the thyroid gland of monkey 'Cathy' taken 130 days after the first injection. There appeared areas of intense infiltration and distortion of thyroid follicular structure with other portions of the gland entirely normal in appearance. H & E,  $\times 100$ .

Monkey 'Pipo' (Table 4) was also injected according to the same schedule. Antibodies to thyroglobulin rose gradually, reaching a titre of 1024 on the final examination. Antibodies to thyroid cytoplasm, as measured by complement fixation, were present only in the last serum sample tested. Cytotoxic antibodies appeared following the first booster injection and remained at a relatively constant level throughout the observation period. Complement levels showed a gradual but steady decrease to a final low value of 23 units. On the first biopsy essentially normal thyroid tissue was seen (Fig. 6). The autopsy specimen revealed a generalized inflammatory process marked by invasion of the interfollicular spaces by mononuclear cells of various types (Fig. 7). The follicles themselves were small and contained only thin colloid. However, the values of PBI and BEI remained essentially constant in this animal.

TABLE 4. Serum titres obtained following the injection of monkey 'Pipo' (male)

Day	Tanned cell haemagglutination	Complement fixation	Cytotoxic antibody	Complement levels (C <sub>50</sub> units)
0	0			46
0	Injected with 1.0 ml monkey thyroid crude extract plus complete Freund's adjuvant			
7	8	0	0	33
13	Biopsy: normal (Fig. 6)			
18	4	0	0	36
29	0		0	23
31	Injected with 1.0 ml monkey thyroid crude extract plus complete Freund's adjuvant			
39	64	0	10	24
49	32	0	10	34
52			10	
67	0	0	10	29
74	Injected with 1.0 ml monkey thyroid crude extract plus complete Freund's adjuvant			
81	8	0	10	33
102	4	0	10	26
116	Injected with 1.0 ml monkey thyroid crude extract plus complete Freund's adjuvant			
126	16		10	
145	Injected with 1.0 ml monkey thyroid crude extract plus complete Freund's adjuvant			
158	1024	4		23
158	Autopsy: moderate inflammation (Fig. 7)			

Two monkeys, 'Claude' and 'Kit', were injected with partially purified rhesus monkey thyroglobulin plus complete Freund's adjuvant. The injection schedules together with serological findings are seen in Tables 5 and 6. Antibodies to thyroglobulin were never detected in the serum of monkey 'Claude' (Table 5). However, complement-fixing antibodies to microsomal antigen were present in several serum samples taken between the 60th and 118th days. Cytotoxic antibodies were detected in low titre only once on the 230th day after injection. Both the biopsy specimen taken on the 243rd day and the autopsy material obtained at the end of the experiment (348th day) showed severe inflammation (Figs. 8 and 9). Serum samples from monkey 'Kit' (Table 6) were positive by tanned cell haemagglutination as early as the 21st day but showed a gradual loss in titre, being negative at the end of the experiment. Complement-fixing antibodies were never found. Cytotoxic anti-



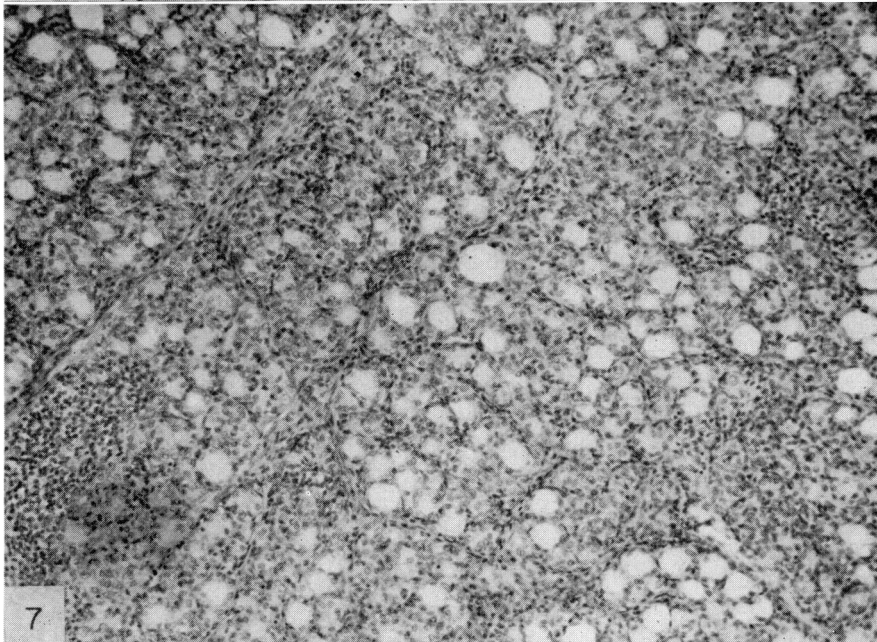
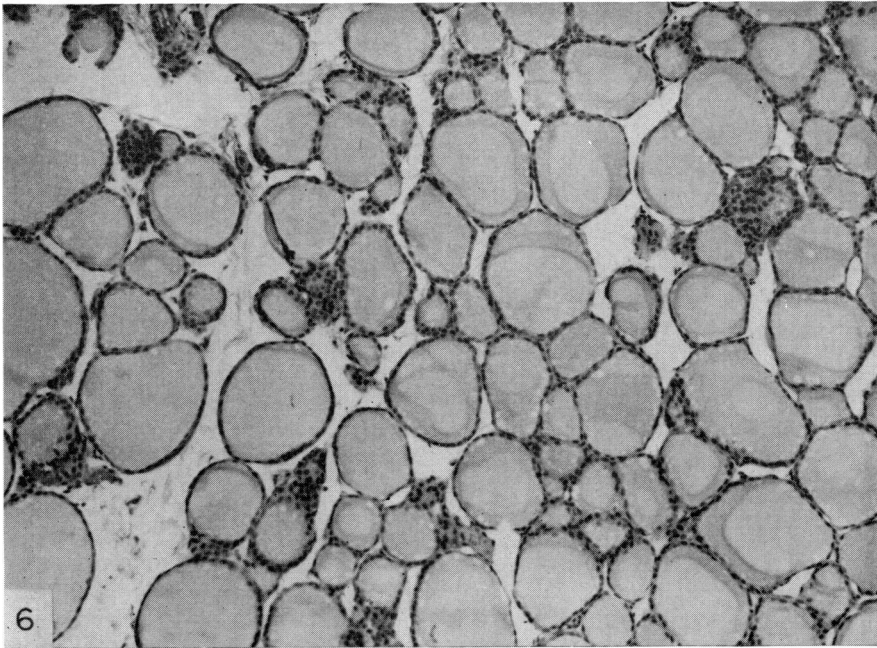


FIG. 6. Biopsy of the thyroid gland of monkey 'Pipo' taken 13 days after the first injection. The thyroid gland appeared normal. H & E,  $\times 100$ .

FIG. 7. Biopsy of the thyroid gland of monkey 'Pipo' taken 158 days after the first injection. There was a generalized inflammatory process marked by invasion of the interfollicular spaces by mononuclear cells of various types. The follicles were small and contained only thin colloid. H & E,  $\times 100$ .

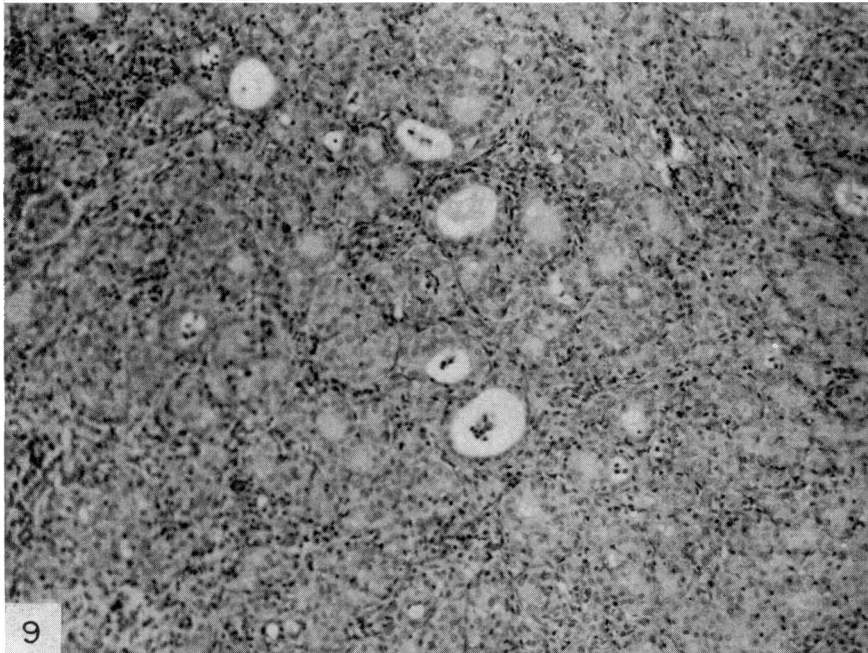


FIG. 8. Biopsy of the thyroid gland of monkey 'Claude' taken 243 days after the first injection. Severe inflammation of the thyroid. H & E,  $\times 100$ .

FIG. 9. Biopsy of the thyroid gland of monkey 'Claude' taken 348 days after the first injection. Severe inflammation. H & E,  $\times 100$ .

bodies in low titre were present in the middle of the observation period and then disappeared despite the application of a booster injection. A biopsy taken on the 135th day showed that the thyroid gland was composed primarily of sheets of epithelial cells with little evidence of follicular organization (Fig. 10). Scattered collections of mononuclear cells and areas of fibrosis were apparent. On autopsy performed 100 days later, the thyroid showed many small follicles filled with colloid, although abundant evidence of chronic inflammation and fibrosis remained (Fig. 11).

TABLE 5. Serum titres obtained following the injection of monkey 'Claude' (male)

Day	Tanned cell haemagglutination	Complement fixation	Cytotoxic antibody
0	Injected with 100 mg monkey thyroglobulin plus complete Freund's adjuvant		
19			0
32			0
39	Injected with 100 mg monkey thyroglobulin plus complete Freund's adjuvant		
47	0		0
60		32	0
68		32	0
71	Injected with 100 mg monkey thyroglobulin plus complete Freund's adjuvant		
112	Injected with 100 mg monkey thyroglobulin plus complete Freund's adjuvant		
118		32	0
133	0	0	0
144	0	0	0
147	Injected with 100 mg monkey thyroglobulin plus complete Freund's adjuvant		
165	0	0	0
174	0	0	0
190	0	0	0
200	Injected with 100 mg monkey thyroglobulin plus complete Freund's adjuvant		
214	0	0	0
230	0	0	10
243	0	0	0
243	Biopsy: severe inflammation (Fig. 8)		
307	0	0	
326	0		
335	0	AC	
348	0	AC	
348	Autopsy: severe inflammation (Fig. 9)		

AC = Anti-complementary.

Two monkeys were injected with a suspension of rhesus monkey thyroid cells freshly prepared from whole tissue by treatment with collagenase and trypsin. The washed cell suspension was mixed with complete Freund's adjuvant for inoculation purposes. The injection schedule was essentially the same as that employed with partially purified thyroglobulin. The results are presented in Tables 7 and 8. Monkey 'Flo' (Table 7) developed significant titres of complement-fixing antibody early in the course of immunization. These antibodies disappeared despite the application of periodic booster injections. Cytotoxic and haemagglutinating antibodies were present in low titre only at the very end of the

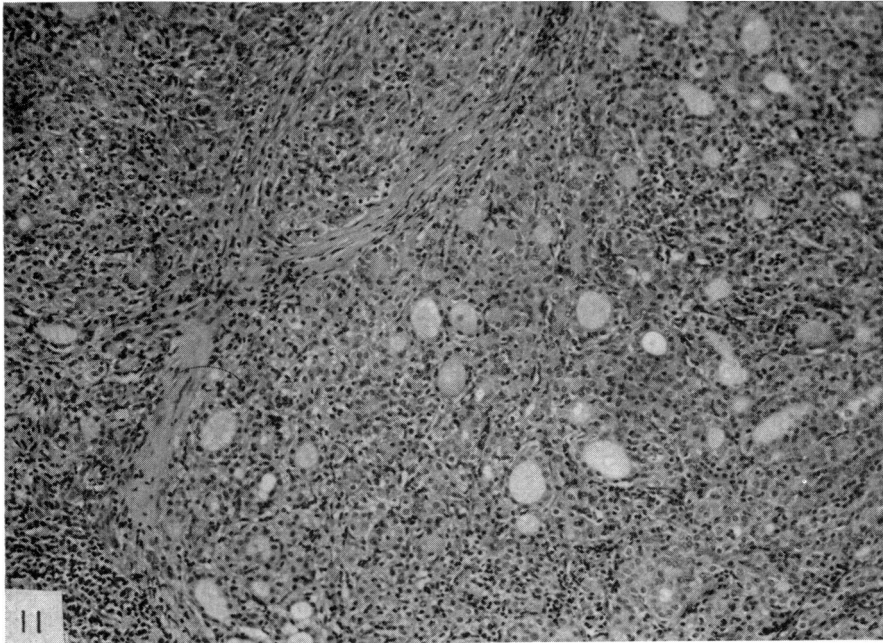
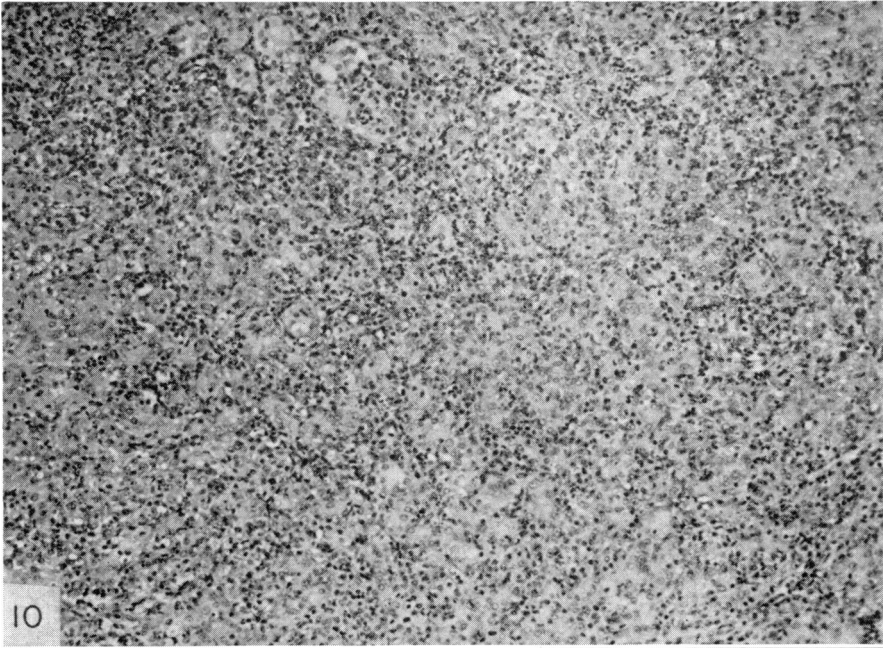


FIG. 10. Biopsy of the thyroid gland of monkey 'Kit' taken 135 days after the first injection. The thyroid gland was composed primarily of sheets of epithelial cells with a little evidence of follicular organization. Scattered collections of mononuclear cells and areas of fibrosis were apparent. H & E,  $\times 100$ .

FIG. 11. Biopsy of the thyroid gland of monkey 'Kit' taken 236 days after the first injection. There were many small follicles filled with colloid, although abundant evidence of chronic inflammation and fibrosis remained. H & E,  $\times 100$ .

TABLE 6. Serum titres obtained following the injection of monkey 'Kit' (female)

Day	Tanned cell haemagglutination	Complement fixation	Cytotoxic antibody
0	Injected with 1.0 ml monkey thyroglobulin plus complete Freund's adjuvant		
4	0		0
21	32	0	0
32	32	0	0
35	Injected with 1.0 ml monkey thyroglobulin plus complete Freund's adjuvant		
54	4	0	0
67	32	0	0
78	16	0	0
89	Injected with 1.0 ml monkey thyroglobulin plus complete Freund's adjuvant		
102	8	0	10
118	2	0	10
134	4	0	10
135	Biopsy: severe fibrosis (Fig. 10)		
196	0	0	0
208	Injected with 1.0 ml monkey thyroglobulin plus complete Freund's adjuvant		
215	8		0
223	0	0	0
236	0	0	0
236	Autopsy: severe inflammation and fibrosis with regenerating follicles (Fig 11)		

TABLE 7. Serum titres obtained following the injection of monkey 'Flo' (female)

Day	Tanned cell haemagglutination	Complement fixation	Cytotoxic antibody
0	Injected with 1.0 ml monkey thyroid cell suspension plus complete Freund's adjuvant		
8		64	0
21			0
21	Injected with 1.0 ml monkey thyroid cell suspension plus complete Freund's adjuvant		
36	0	0	0
49		64	0
57		64	0
63	Injected with 1.0 ml monkey thyroid cell suspension plus complete Freund's adjuvant		
91	Injected with 1.0 ml monkey thyroid cell suspension plus complete Freund's adjuvant		
113	Injected with 1.0 ml monkey thyroid cell suspension plus complete Freund's adjuvant		
122	0	0	0
133	0	AC	0
134	Injected with 1.0 ml monkey thyroid cell suspension plus complete Freund's adjuvant		
154	0	AC	0
163	0	AC	0
179	0	AC	0
183	Injected with 1.0 ml monkey thyroid cell suspension plus complete Freund's adjuvant		
203	4	0	10
211	Injected with 1.0 ml monkey thyroid cell suspension plus complete Freund's adjuvant		
219	8	0	10
248	0	0	0
266	Autopsy: slight focal infiltration (Fig. 12)		

AC = Anti-complementary.

immunization process. The thyroid gland of this animal at autopsy showed scattered areas of round cell infiltration with the rest of the gland entirely normal in appearance (Fig. 12). Monkey 'Gail' (Table 8), which received a similar series of injections, responded in a similar manner. No antibodies were detected in the tanned cell haemagglutination or cytotoxic tests. Complement-fixing antibodies appeared in some early samples but disappeared from the later trial bleedings. A biopsy taken on the 240th day showed fairly general interstitial invasion by mononuclear cells (Fig. 13). Many small follicles filled with colloid

TABLE 8. Serum titres obtained following the injection of monkey 'Gail' (female)

Day	Tanned cell haemagglutination	Complement fixation	Cytotoxic antibody	Complement levels ( $C_{50}$ units)
0	Injected with 1.0 ml monkey thyroid cell suspension plus Freund's adjuvant			
8		64	0	
20			0	
21	Injected with 1.0 ml monkey thyroid cell suspension plus Freund's adjuvant			
35			0	
48		32	100	
56		64	0	
63	Injected with 1.0 ml monkey thyroid cell suspension plus Freund's adjuvant			
91	Injected with 1.0 ml monkey thyroid cell suspension plus Freund's adjuvant			
104		32		
113	Injected with 1.0 ml monkey thyroid cell suspension plus Freund's adjuvant			
121	0	AC	0	
131	0	AC		
134	Injected with 1.0 ml monkey thyroid cell suspension plus Freund's adjuvant			
152	0	AC	0	
162	0	0	0	
183	0	0		
183	Injected with 1.0 ml monkey thyroid cell suspension plus Freund's adjuvant			
203	0	0	0	
211	Injected with 1.0 ml monkey thyroid cell suspension plus Freund's adjuvant			
219	0	AC	100	
240	0		0	
240	Biopsy: moderate generalized infiltration with minimal fibrosis (Fig. 13)			
296	0	0		
323	0	0	10	
323	Injected with 1.0 ml monkey thyroid cell suspension plus Freund's adjuvant			
346	0	0	10	
352	Autopsy: focal interfollicular infiltration (Fig. 14)			

AC = Anti-complementary.

could be seen and in a few areas fibrosis was apparent. The specimen obtained at autopsy showed limited foci of round cell infiltration with the rest of the gland largely normal in appearance (Fig. 14).

Monkey 'Lil' (Table 9) was injected with a microsome fraction prepared from three toxic human thyroids (Drz., Web. and Sel.) removed at surgery. This fraction was incorporated in complete Freund's adjuvant for injection. As demonstrated by the tanned cell haemagglutination test antibodies to monkey thyroglobulin (as well as human thyroglobulin) were

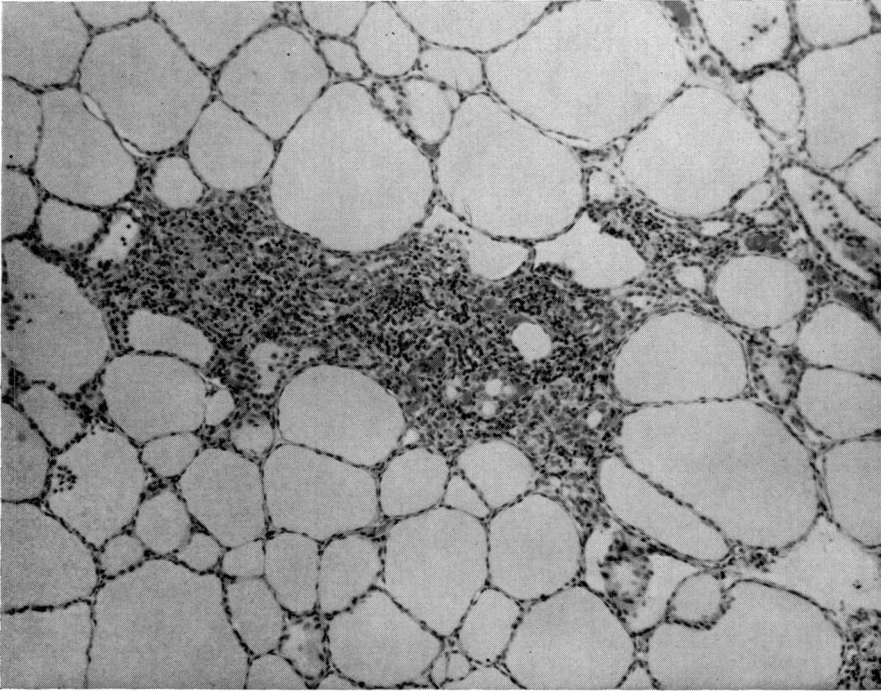


FIG. 12. Biopsy of the thyroid gland of monkey 'Flo' taken 266 days after the first injection. There are scattered areas of round cell infiltration with the remainder of the gland entirely normal in appearance. H & E,  $\times 100$ .

TABLE 9. Serum titres obtained following the injection of monkey 'Lil' (female)

Day	Tanned cell haemagglutination (cells coated with monkey thyroid extract)	Cytotoxic antibody
0	Injected with toxic human thyroid microsomes plus Freund's adjuvant	
10	81	0
21	81	0
24	Injected with toxic human thyroid microsomes plus Freund's adjuvant	
42	729	10
56	2187	0
67	6561	0
77	Injected with toxic human thyroid microsomes plus Freund's adjuvant	
91	19683	100
107	6561	100
134	Biopsy	
184		0
220		0
220	Autopsy: minimal infiltration (Fig. 15)	

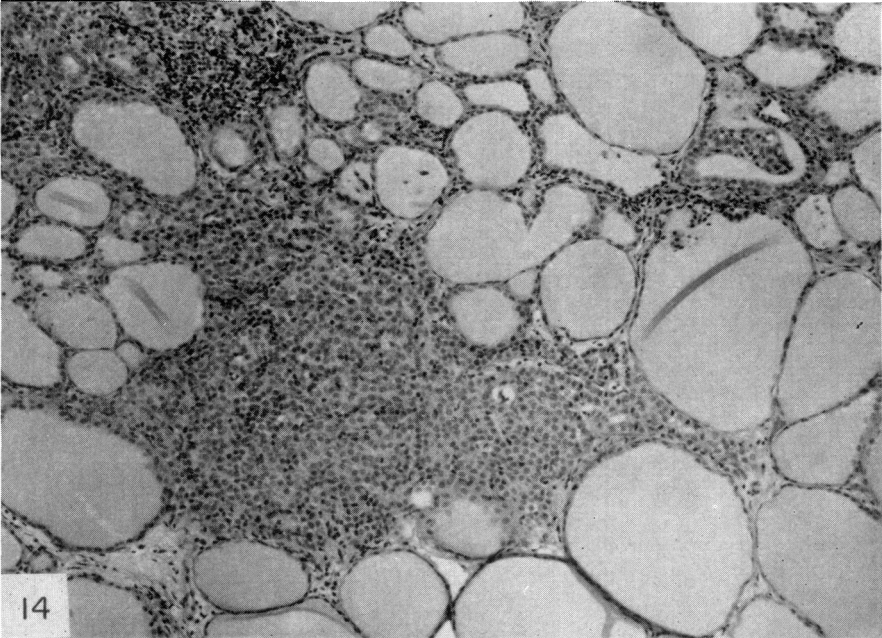
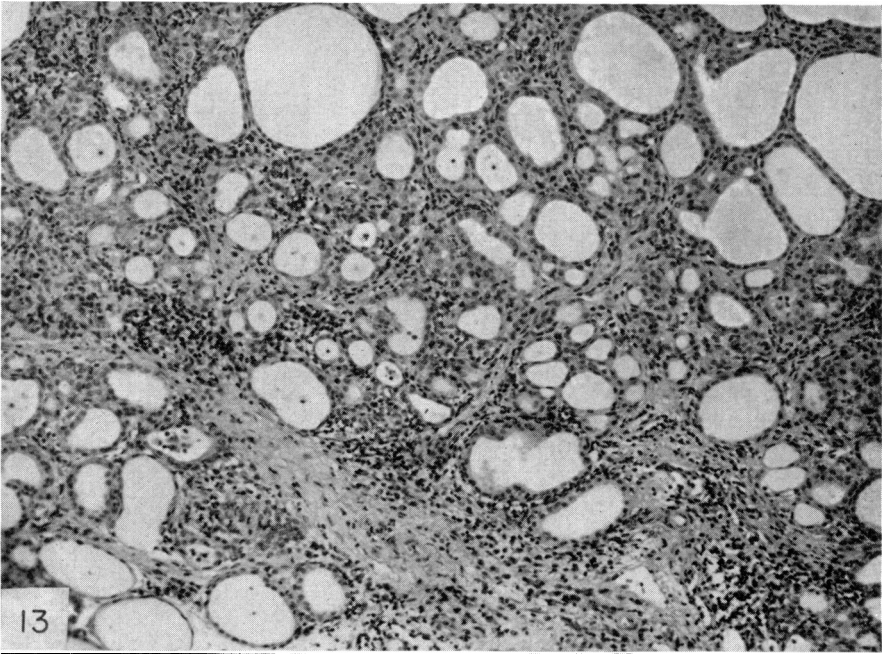


FIG. 13. Biopsy of the thyroid gland of monkey 'Gail' taken 240 days after the first injection. A general interstitial invasion by mononuclear cells. Many small follicles filled with colloid can be seen and in a few areas fibrosis is apparent. H & E,  $\times 100$ .

FIG. 14. Biopsy of the thyroid gland of monkey 'Gail' taken 352 days after the first injection. There are limited foci of round cell infiltration with the rest of the gland normal in appearance. H & E.  $\times 100$ .



present in high titre throughout the course of immunization. Cytotoxic antibodies were also present on at least three occasions, sometimes reaching a titre of 100. Unfortunately it was not possible to carry out complement fixation tests with these particular antisera. Examination of the thyroid gland post-mortem revealed one or two small areas of inflammation characterized by presence of mononuclear cells in the interfollicular spaces and the appearance of macrophages within the colloid (Fig. 15).

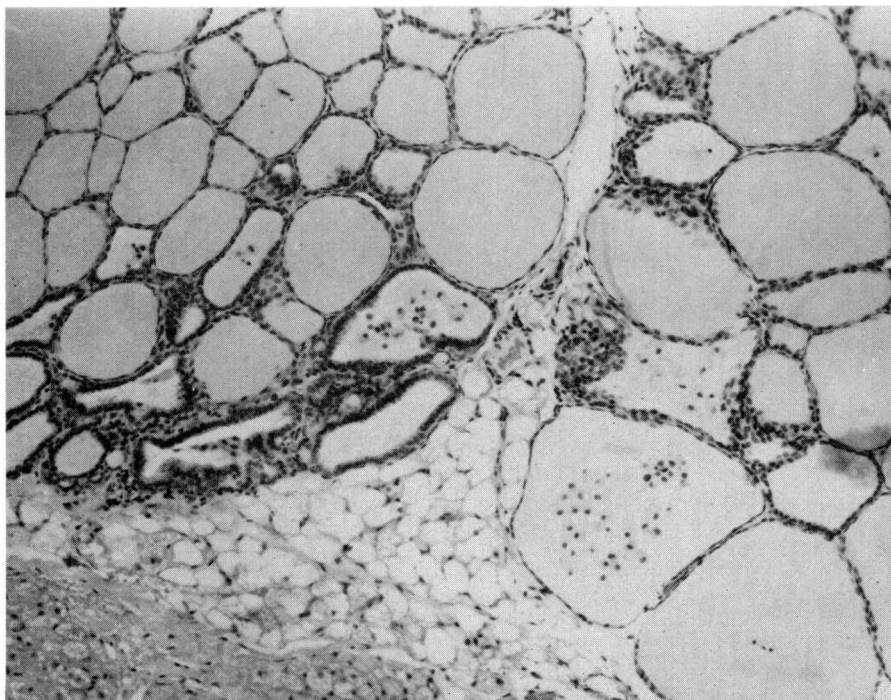


FIG. 15. Biopsy of the thyroid gland of monkey 'Lil' taken 220 days after the first injection. There are one or two small areas of inflammation characterized by presence of mononuclear cells in the interfollicular spaces and the appearance of macrophages within the colloid. H & E,  $\times 100$ .

## DISCUSSION

These investigations emphasize the variability of the experimentally induced autoimmune process in monkeys even when the same or similar antigenic stimulation is applied. While it is not yet possible to assign this fluctuation to particular environmental or genetic causes, it does recall the great variation characteristic of human autoimmune disease. Some monkeys such as 'Olive' responded promptly to a single injection of monkey thyroid crude extract, developing antibodies to both cytoplasmic and thyroglobulin components. The fact that lesions of the magnitude illustrated could develop within such a brief period of time is surprising. It is consistent, however, with the view that subacute thyroiditis may be a sequela of viral or other types of infection.

The data fail to reveal any consistent association between the circulating antibody to thyroglobulin and the circulating antibodies to cytoplasmic antigens, or with the development of pathological changes in the thyroid gland. Levels of serum C' varied throughout the observation period. Some animals showed a gradual but steady decrease reaching in some cases values of 23 and 18 units at the end of the experiment. In most cases low C' levels coincided with histological damage of the thyroid as shown in human chronic thyroiditis (Andrada *et al.*, 1965). In addition to serological tests for circulating antibody, skin tests were performed on the immunized monkeys, using a well centrifuged sample of monkey thyroid extract as antigen. The reactions obtained were irregular and difficult to interpret and, therefore, have been omitted from the tables. In the monkey there appeared to be no greater correlation between delayed hypersensitivity as measured by the skin test and the appearance of lesions than there was between circulating antibody and lesions.

The importance of repeated serological examination is well illustrated by these experiments. Monkey 'Pete' developed severe thyroiditis before antibodies were measurable by the serological techniques employed, except for a single low titred reaction by complement fixation and a similar reaction by haemagglutination. On the other hand, 'Cathy' and 'Pipo' both had significant reactions in one or more serological tests at a time when their thyroid glands were normal histologically. These observations are also relevant to the study of human autoimmune disease in which at any given moment there may be no correspondence between levels of circulating antibody and appearance of lesions in the thyroid.

The pathological changes occurring in these animals seem to be specific for the thyroid gland. A variety of other tissues were examined post-mortem and all appeared to be entirely normal. As a further control two monkeys were injected with a crude extract of monkey gastric mucosa. These animals showed no pathological changes in their thyroid glands and no evidence of circulating antibody to thyroid constituents. However, they did develop an antibody to gastric mucosa. This finding will be described in more detail in future publications.

Despite the impressive changes in the thyroid gland observable by histological examination, there was relatively little change in thyroid function as measured by levels of protein bound iodine and 'thyroxine' iodine. One animal, 'Pete', showed a sufficient decrease in circulating hormone levels to be considered hypothyroid. Another animal, 'Cathy', might actually have been considered hyperthyroid for a period of time. We did not see any consistent evidence of a disparity between protein bound iodine and thyroxine iodine as has been noted previously by Gribetz, Talbot & Crawford (1954) in human chronic thyroiditis. However, this negative finding must be extended by further experimental scrutiny.

The two categories of thyroid antigens with autoantigenic potentiality, thyroglobulin and cytoplasmic antigens, seem to be completely distinct. However, injection of monkey thyroglobulin, as carried out with monkeys 'Kit' and 'Claude', produced a full-blown picture of thyroiditis. It included antibodies to the cytoplasmic antigens as well as to thyroglobulin. As a matter of fact, production of antibody to thyroglobulin seemed to be no greater in these animals than those receiving thyroid crude extract. The question then arises as to the origin of these autoantibodies to cytoplasmic constituents in monkeys injected with thyroglobulin. Although small amounts of cytoplasmic antigen may be present in soluble form as contaminants of the thyroglobulin preparation, this possibility is unlikely. Perhaps thyroglobulin induced an initial process of thyroiditis which was followed later by autosensitization to cytoplasmic antigens.

In the two animals tested, monkey thyroid cells appeared to be a much less potent antigen than thyroglobulin. In one of two animals, they did give rise to significant antibody to thyroglobulin. It is likely that treatment with trypsin coupled with thorough washing removed most of the soluble thyroglobulin from the cell suspension. However, it is also possible that thyroglobulin or some antigenic equivalent of thyroglobulin is present in the cells in a tightly bound form. In earlier experiments we were unable to remove thyroglobulin from thoroughly washed suspensions of thyroid cell microsomes (Kite, Brown & Rose, 1962).

Further evidence that thyroglobulin has remained tightly bound to the microsomal fraction can be obtained from the experiment with monkey 'Lil', injected with human thyroid microsomes. There was a strong response to monkey thyroglobulin and titres reached levels not usually obtained even with homologous monkey thyroglobulin as antigenic stimulus. Cytotoxic antibodies to cytoplasmic antigen appeared rather late. Only minimal evidence of thyroid inflammation was found at autopsy. This effect of injecting human thyroglobulin into the monkey is in accord with previously presented evidence that foreign, cross-reacting thyroglobulins (e.g. hog thyroglobulin injected into the rabbit) are capable of inducing experimental thyroiditis (Witebsky & Rose, 1959). However, cross-reacting thyroglobulin generally seem to be much less effective in provoking pathological alteration than thyroglobulin of the same species despite the fact that high titres of circulating antibodies to homologous thyroglobulin develop.

#### ACKNOWLEDGMENTS

This work was supported in part by a Public Health Service Research Grant CA-05203 from the National Institutes of Health. We would like to thank the following for technical assistance: Dr Enia C. Andrada, Mr Charles Anderson, Mrs Bettina Twarog, and Mrs Audrey Phillips.

#### REFERENCES

- ANDRADA, J.A., SANCHEZ AVALOS, J.C., O'FARRELL, J.J. & COMINI, E. (1965) Study of the complement concentrations and anticoagulant factors in the serum of patients with Hashimoto's thyroiditis. *Excerpta Medica Internat. Congress*, Series No. 99 Mexico.
- DOEBBLER, T.K. & ROSE, N.R. (1966) Experimental thyroiditis in the rhesus monkey. II. Precipitating, haemagglutinating and anaphylactogenic antibodies. *Clin. exp. Immunol.* **1**, 159.
- GRIBETZ, D., TALBOT, N.R. & CRAWFORD, J.D. (1954) Goiter due to lymphocytic thyroiditis (Hashimoto's struma). Its occurrence in preadolescent and adolescent girls. *New Engl. J. Med.* **250**, 555.
- KABAT, E.A. & MAYER, M.M. (1961) *Experimental Immunochemistry*. Thomas, Springfield, Illinois.
- KITE, J.H., ARGUE, H. & ROSE, N.R. (1966) Experimental thyroiditis in the rhesus monkey. I. Cytotoxic, mixed-agglutinating and complement-fixing antibodies. *Clin. exp. Immunol.* **1**, 139.
- KITE, J.H., BROWN, R.C. & ROSE, N.R. (1962) Autoantibodies to thyroid tissue sediment detected by the antiglobulin consumption test. *J. Lab. clin. Med.* **59**, 179.
- KITE, J.H., ROSE, N.R., KANO, K. & WITEBSKY, E. (1965) Cytotoxicity of human thyroid autoantibodies. *Ann. N.Y. Acad. Sci.* **124**, 626.
- ROIT, I.M., LING, N.R., DONIACH, D. & COUCHMAN, K.G. (1964) The cytoplasmic autoantigen of the human thyroid. I. Immunological and biochemical characteristics. *Immunology*, **7**, 375.
- ROSE, N.R., KITE, J.H., DOEBBLER, T.K., SPIER, R., SKELTON, F.R. & WITEBSKY, E. (1965) Studies on experimental thyroiditis. *Ann. N.Y. Acad. Sci.* **124**, 201.
- ROSE, N.R., SKELTON, F.R., KITE, J.H. & WITEBSKY, E. (1966) Experimental thyroiditis in the rhesus monkey. III. Course of the disease. *Clin. exp. Immunol.* **1**, 171.
- WITEBSKY, E. & ROSE, N.R. (1959) Studies on organ specificity. VII. Production of antibodies to rabbit thyroid by injection of foreign thyroid extracts. *J. Immunol.* **83**, 41.