

Serum thyroid stimulating hormone, initially 620 μ U/ml, fell to 20 μ U/ml after one month on thyroxine 0.1 mg daily, and to 2 μ U/ml after a further month on thyroxine 0.2 mg daily. After three months' therapy his weight had fallen by 6 kg and his height had increased by 2.5 cm. He was euthyroid but there were no signs of further sexual development.

Repeat investigations (see Table) showed rapid advance in bone maturity and recovery of human growth hormone and cortisol responses to hypoglycaemic stress. Basal levels of luteinizing hormone remained low, but rose to within the normal adult range in response to luteinizing hormone-releasing hormone.

Comment

The patient presented with features of hypopituitarism but the raised levels of serum thyroid stimulating hormone indicated the true diagnosis of primary hypothyroidism. The aetiology of the hypothyroidism remains obscure, there being no evidence of a previous thyroiditis or of a lingual thyroid.

Varying degrees of partial pituitary failure secondary to primary hypothyroidism have been described. A blunted cortisol response to insulin-induced hypoglycaemia may occur (Lessof *et al.*, 1969), and similarly the growth hormone response may be absent (Najjer and Blizzard, 1966; Root *et al.*, 1967). After replacement therapy with thyroxine these hormone responses usually return to normal and treated cretins have a normal growth hormone response to hypoglycaemia (Harrison *et al.*, 1968). In the present patient normal human growth hormone and cortisol responses were seen after replacement therapy but luteinizing hormone levels remained low and unresponsive to clomiphene. This latter finding was not surprising in that the patients' physical development was that of an 8-year-old, and normal subjects remain unresponsive to clomiphene until stage III-IV of puberty (Anderson *et al.*, 1972).

The partial luteinizing hormone response to the gonadotrophin releasing hormone shows, however, that the pituitary is capable of secreting gonadotrophin and so puberty may develop spontaneously at a later date.

Enlargement of the pituitary fossa may occur in primary hypothyroidism and be persistent after treatment. It may then be difficult to exclude a coexistent chromophobe adenoma of the pituitary. In this patient despite the clinical and biochemical evidence of pituitary failure (thyrotrophin excepted) there was no radiological evidence of pituitary enlargement or an empty sella, and the reversibility of the pituitary disturbances indicates that they were secondary to the thyroid failure. The mechanism whereby the high level of thyroid stimulating hormone is maintained but other pituitary function is impaired remains obscure. Hypertrophy of the thyrotrophin secreting cells may interfere with the production of other pituitary hormones; or, alternatively, the failure of human growth hormone and adrenocorticotrophic hormone release may be due to a direct effect of lack of thyroxine at hypothalamic or pituitary level.

We are grateful to Drs A. Stockell Hartree and W. Butt and to the Medical Research Council for providing reagents for the immunoassay procedures, to Professor Russell Fraser, under whose care the patient was admitted, and to Dr. F. H. Doyle for the radiology. J.C.M. is in receipt of a Medical Research Council Clinical Research Fellowship.

Requests for reprints should be addressed to: Dr. W. M. G. Tunbridge, Department of Medicine, Royal Victoria Infirmary, Newcastle upon Tyne.

References

- Anderson, D. C., Marshall, J. C., Young, J. L., and Fraser, T. R. (1972). *Clinical Endocrinology*, 1, 127.
 Greulich, W. W., and Pyle, S. I. (1950). In *Radiographic Atlas of Skeletal Development of the Hand and Wrist*. Stanford, University Press.
 Harrison, M. R., Fierro-Benitel, R., Ramirez, I., Refetoff, S., and Stanbury, J. S. (1968). *Lancet*, 1, 936.
 Lessof, M. M., Lyne, C., Maisey, M. N., and Sturge, R. A. (1969). *Lancet*, 1, 642.
 Najjer, S., and Blizzard, R. M. (1966). *Pediatric Clinics of North America*, 13, 437.
 Root, A. W., Rosenfield, R. L., Bongiovanni, A. M., and Eberlein, W. R. (1967). *Pediatrics*, 39, 844.

Toxocara Larval Papillitis

C. I. PHILLIPS, A. D. MACKENZIE

British Medical Journal, 1973, 1, 154-155

Adult toxocara worms commonly infest the intestinal tracts of dogs, cats, kittens, and puppies, thus their eggs are frequently excreted. Children and occasionally adults are at risk from accidentally ingesting these eggs. In the human intestinal tract larvae escape from the eggs and pass through the wall of the intestine. Visceral infestation causes pica, cough and wheezing, fever, and sometimes convulsions. Enlarged liver and spleen, with leucocytosis and eosinophilia, are also commonly found. Ocular involvement sometimes occurs with unioocular

poor vision usually due to macular chorioretinal scarring, often with retinal detachment. A convergent squint often follows, and may be the presenting symptom. Involvement of the central nervous system results in acquired epilepsy (and also poliomyelitis), according to evidence presented by Woodruff *et al.* (1966).

The present case is the first to be recorded of an adult presenting with papillitis due to a larva of the nematode worm *Toxocara*. One similar case was recorded in a child (Bird *et al.*, 1970) in whom enucleation allowed histological proof of the presence of a *Toxocara canis* larva in the optic disc. Wilder (1950) identified in sections for the first time nematode larvae embedded in fibrous tissue in enucleated eyes which had been removed usually because of a suspected retinoblastoma. Brown (1970) reported a review of the literature which included accounts of 245 affected patients in the U.S.A., Europe, Australia, and elsewhere. Ashton (1960) and Duguid (1961a, 1961b) described cases in England, and in two of Duguid's cases (1961b) the temporal part of the disc was implicated.

Case Report

A 25-year-old woman had had poor vision in her left eye from childhood attributed to strabismic amblyopia (6/18 with correction for hypermetropia—namely +7.50/+0.50 at 100°. The right eye had good vision (6/6) when corrected for a similar degree of hypermetropia until February 1971, when she noticed a flickering

University of Manchester and Manchester Royal Eye Hospital
 C. I. PHILLIPS M.D., F.R.C.S., Professor of Ophthalmology

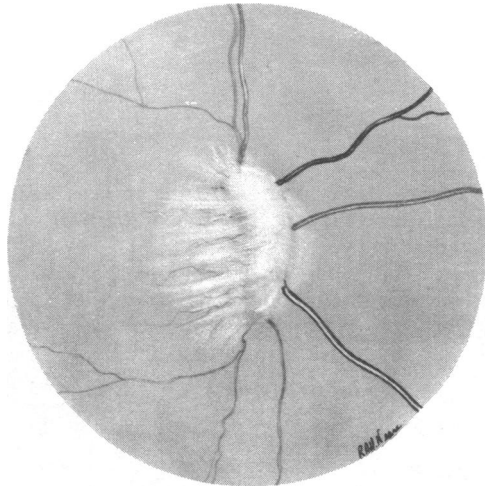
Victoria Hospital, Blackpool, Lancashire
 A. D. MACKENZIE, M.B., F.R.C.S., Consultant Ophthalmic Surgeon

sensation in this eye followed a few days later by reduced visual acuity, which was 6/18 about 10 days after the onset of symptoms. Gross right papilloedema was present but it was not typical because the disc seemed to be covered by translucent "tissue," presumably an early inflammatory exudate. The left disc and fundus were normal. Full general clinical and neurological examination showed no abnormalities except for the poor visual acuity in the right eye and a large central scotoma to a 10-mm white object at 1 m. The toxoplasma dye test was positive at 1/32. The E.S.R. was 5 mm in one hour. She had had a dog for four years and before that a cat. Three months later the acuity was 6/60, and this deteriorated to 3/60 after a further 3 months.

Five months after the onset of symptoms a small white focus of inflammatory or fibrous tissue was visible on the optic disc. On slit-lamp microscopy numerous inflammatory cells were seen in the vitreous and anterior chambers. At this stage the clinical diagnosis of papillitis due to the larva of a nematode worm, probably *T. canis*, was made.

Six months after the onset of symptoms she was referred to Professor A. W. Woodruff and Mr. D. P. Choyce, of the Hospital for Tropical Diseases, London, who agreed with the diagnosis and kindly reported the results of their investigations. Toxocara skin test was negative, toxocara fluorescent antibody test was negative (in the following three months this latter test was positive on two occasions), and eosinophils were 2%. A two to three week course of systemic cortisone and diethylcarbamazine (Banocide) was given.

Eleven months after the onset of symptoms the eye showed a large white sheet of fibrous inflammatory tissue in the posterior



Fibrous inflammatory mass with streamers of fibrous tissue in vitreous anterior to optic disc, produced by toxocara larva. Initially it caused papillitis for about six months before migrating anteriorly.

vitreous anterior to the disc (see Fig.). This final condition of the eye as seen with the ophthalmoscope provided good evidence that the diagnosis was correct. Only slight active inflammation was still present judging by the few cells which could be seen in the vitreous and anterior chambers on slit-lamp microscopy.

Prognosis for vision and even for the eye was poor, a retinal detachment being a likely future complication.

Comment

An important factor in the spread of this disease in our overcrowded towns and cities is the widespread practice of keeping dogs and cats. Unfortunately pets are particularly common in households with young children, who also tend to be at increased risk of infestation because of their unhygienic habits.

A reduction in the population of pet animals would probably improve the situation. Two other measures would also help. (1) Laws to prohibit the deposition of excreta by pets outside their owners' premises or gardens. This might be valuable (though not completely effective, of course) if Henderson Brown's suggestion be true that the reason for the complete absence of *proved* ocular disease from larval infestation by *T. cati* is "the fastidious excreta disposal carried out by cats." The cat's intestinal tract, however, is incriminated in the harbouring of *Toxoplasma gondii*, a coccidial protozoan parasite which causes choroiditis in man. (Hutchison *et al.*, 1971). (2) Dissemination of knowledge about risks of infection from pets in schools, welfare clinics, eye hospitals (especially the orthoptic departments), children's departments, hospitals, etc.

Requests for reprints should be addressed to Professor C. I. Phillips, Department of Ophthalmology, Princess Alexandra Eye Pavilion, Chalmers Street, Edinburgh, EH3 9HA.

References

- Ashton, N. (1960). *British Journal of Ophthalmology*, **44**, 129.
 Bird, A. C., Smith, J. L., and Curtin, V. T. (1970). *American Journal of Ophthalmology*, **69**, 72.
 Brown, D. H. (1970). *Journal of Paediatric Ophthalmology*, **7**, 182.
 Duguid, I. M. (1961a). *British Journal of Ophthalmology*, **45**, 705.
 Duguid, I. M. (1961b). *British Journal of Ophthalmology*, **45**, 789.
 Hutchison, W. M., Dunachie, J. F., Work, K., and Siim, J. Chr. (1971). *Transactions of the Royal Society of Tropical Medicine and Hygiene*, **65**, 380.
 Wilder, H. C. (1950). *Transactions of the American Academy of Ophthalmology and Otolaryngology*, **55**, 99.
 Woodruff, A. W., Bisseru, B., and Bowe, J. C. (1966). *British Medical Journal*, **1**, 1576.