

Gut blood flow velocities in the newborn: effects of patent ductus arteriosus and parenteral indomethacin

R C Coombs, M E I Morgan, G M Durbin, I W Booth, A S McNeish

Abstract

The effects on gut blood flow velocities of parenteral indomethacin (0.2 mg/kg) given either quickly as a bolus or slowly as an infusion were compared in consecutive studies of two groups of infants with symptomatic patent ductus arteriosus. In the presence of patent ductus arteriosus the range of velocities in the superior mesenteric artery before indomethacin was given was characterised by pronounced abnormalities including absent—or in some cases even retrograde—diastolic flow.

In eight subjects the first rapidly given bolus dose of indomethacin (duration 20 seconds or less) caused a pronounced and sustained fall in the velocity of the superior mesenteric artery blood flow (mean peak systolic velocity (cm/second): before 74; after 38; median time to maximum fall 7.4 minutes; median time to recovery 50 minutes). A further 10 subjects received their first dose of indomethacin by slow infusion (duration 30–35 min) and the percentage fall in peak systolic velocity was both substantially less (22% compared with 47%) and later (median time to maximum fall 37.3 minutes) than after rapid infusion. Qualitatively similar but smaller changes were seen in the coeliac axis. Return of antegrade end diastolic flow in the superior mesenteric artery within one hour of the first dose of indomethacin was a good predictor of subsequent closure of the ductus.

These data suggest that there is a profound disturbance in mid gut perfusion in infants with patent ductus, which is exacerbated by indomethacin given rapidly by intravenous bolus. They may also provide a rational explanation for the well recognised association between necrotising enterocolitis and both patent ductus arteriosus and indomethacin administration. The unwanted effects of the indomethacin are abrogated by slow infusion, without loss of efficacy in closure of the ductus.

The role of indomethacin in the management of patent ductus arteriosus in preterm neonates is well established.^{1 2} Its use is associated with unwanted gastrointestinal effects, however, including intestinal haemorrhage, local perforation, and necrotising enterocolitis. The reason for these is not known, and they have been described in association with oral, rectal, intramuscular, or intravenous administration.^{3–7} In addition local ileal perforation in neonates has been described after indomethacin has been

used to inhibit preterm labour in their mothers.⁸

Indomethacin has well recognised effects on the cerebral circulation. Intravenous boluses reduce cerebral blood flow in the adult human,⁹ and cerebral blood flow velocity in the newborn.^{10 11} No deterioration in cerebral function has yet been reported in association with bolus indomethacin, however, although the fall in blood flow velocity has been considered undesirable.

To date there is no direct evidence that intestinal ischaemia plays a part in the pathogenesis of necrotising enterocolitis in man, but Doppler studies in animals^{12 13} and on severely growth retarded human fetuses suggest that this is a possibility.¹⁴ It is therefore possible to hypothesise that the gastrointestinal side effects of indomethacin may be mediated by a disturbance in gut perfusion.

We have previously used Doppler ultrasound to study gut blood flow velocities in human infants born at full term and have described the changes in splanchnic circulation with increasing postnatal age and in response to feeds. (RC Coombs, MEI Morgan, GM Durbin, *et al*; unpublished observations).¹⁵

Before this study it was our practice to give indomethacin as an intravenous bolus. The present studies were designed to determine the effect of a rapidly administered bolus of indomethacin on the splanchnic circulation, and whether such changes could be reduced by slow infusion in infants with symptomatic patent ductus arteriosus.

Subjects and methods

CONTROL SUBJECTS

In a preliminary study, only those subjects with patent ductus arteriosus were shown to have absent end diastolic forward flow. Control subjects covering a wide range of birth weights and gestational ages were therefore chosen to find out whether absent end diastolic forward flow was present in those who did not have clinically apparent patent ductus arteriosus.

Eighteen preterm infants without symptomatic patent ductus arteriosus were studied (table 1). They were not matched with the study subjects for maturity, weight, or postnatal age. They were significantly more mature ($p < 0.003$), heavier ($p < 0.002$), and studied earlier than the study subjects. Each was studied on several occasions (range 1–6) during the first week of life.

STUDY SUBJECTS

Subjects were entered into the study if a clinical

Neonatal Unit,
Birmingham Maternity
Hospital
M E I Morgan
G M Durbin

Institute of Child Health,
Francis Road,
Birmingham B16 8ET
R C Coombs
I W Booth
A S McNeish

Correspondence to:
Dr Coombs.

Accepted 5 June 1990

Table 1 Clinical details of control subjects and those with symptomatic patent ductus arteriosus receiving either an intravenous bolus dose or a slow infusion of indomethacin

	No of control subjects (n=18)	No who received bolus dose (n=9)	No who received slow infusion (n=10)
Mean (range) gestational age (weeks)	31.2 (27-35)	27.3 (23-31)	28.7 (24-35)
Mean (range) birth weight (g)	1460 (950-2890)	1090 (720-1990)	1190 (630-2670)
Mean (range) age at time of study (days)	2.7 (1-6)	12.7* (6-21)	8.5* (3-12)

*p<0.02.

decision was made to give indomethacin (in three doses 12 hours apart) for the treatment of symptomatic patent ductus arteriosus.

STUDY 1: INDOMETHACIN BY BOLUS

Nine preterm neonates (table 1) were studied on 10 occasions (one infant received a second course of indomethacin). One infant was later found to have tetralogy of Fallot, and data from this patient have been analysed separately.

STUDY 2: INDOMETHACIN BY SLOW INFUSION

Ten preterm infants were also studied who received indomethacin by slow intravenous infusion over 30-35 minutes (table 1). There were no significant differences between these subjects and the first group in gestation or birth weight, although they were studied earlier than the first group (mean 4 days).

DOPPLER ULTRASOUND

A Hewlett Packard duplex pulsed Doppler ultrasound system with a 5 MHz short focus probe and high pass filter at 50 Hz was used to visualise the coeliac axis and superior mesenteric artery. Blood flow velocities were measured from a point just distal to the origin of these vessels at the aorta. The range of velocities from each vessel were recorded on videotape for later analysis by the analysis package contained within the Hewlett Packard system. The duplex system allowed measurement of the angle of insonation, which was kept between 0 and 40°. For analysis of the ranges at any time point, the following were measured over six consecutive cardiac cycles: (i) peak systolic velocity; (ii) end diastolic velocity; (iii) time averaged mean velocity; and (iv) the area under the peak velocity envelope. In another study we showed that the measurement with the least variation is the peak systolic velocity (RC Coombs, MEI Morgan, GM Durbin, *et al*; unpublished observations).

We were unable to determine accurately the diameter of the superior mesenteric artery or coeliac axis, and cannot therefore comment on changes in volume flow.

CLINICAL MANAGEMENT

Clinical management of the subjects with patent ductus arteriosus included fluid restriction to 90 ml/kg for 24 hours before the indomethacin was given. Any enteral nutrition was stopped for the hour before the indomethacin was given, and was not restarted until after the study.

ADMINISTRATION OF INDOMETHACIN

Indomethacin trihydrate (Indocid PDA; Thomas Morson) was given in intravenous doses of 0.2 mg/kg on three occasions, with 12 hour intervals between doses. Only velocity data concerning the first dose were used in the analysis.

Indomethacin by bolus

For rapid infusion the indomethacin was diluted to 1 mg/ml with water or 5% dextrose and given as a bolus in 20 seconds or less.

Slow infusion of indomethacin

For slow infusion, the indomethacin was diluted with water or 5% dextrose to a concentration of 0.2 mg/ml and infused over 30-35 minutes with a constant infusion pump.

In each study, baseline velocity measurements were recorded from the coeliac axis and superior mesenteric artery in the fasting state before, and for a period up to two hours after, the indomethacin was given.

After both the bolus dose and the slow infusion of indomethacin we calculated the time taken to reach the maximal change in velocity, and the magnitude of that change.

STATISTICAL ANALYSIS

The significance of differences between the groups was assessed with the Mann-Whitney U test, Student's paired *t* test, or Fisher's exact test.

ETHICAL APPROVAL

Ethical approval for the study was obtained from the Research Ethics Committee of the Central Birmingham Health Authority. Informed consent was obtained from parents before each study.

Results

VELOCITY PROFILES BEFORE INDOMETHACIN WAS GIVEN

Superior mesenteric artery

Controls: none of the control subjects had a clinically suspected patent ductus arteriosus. Three had absent end diastolic forward flow on day 1. Subsequently all control subjects had velocity ranges with forward flow throughout the entire cardiac cycle (fig 1A).

Study subjects: In contrast to the controls, the

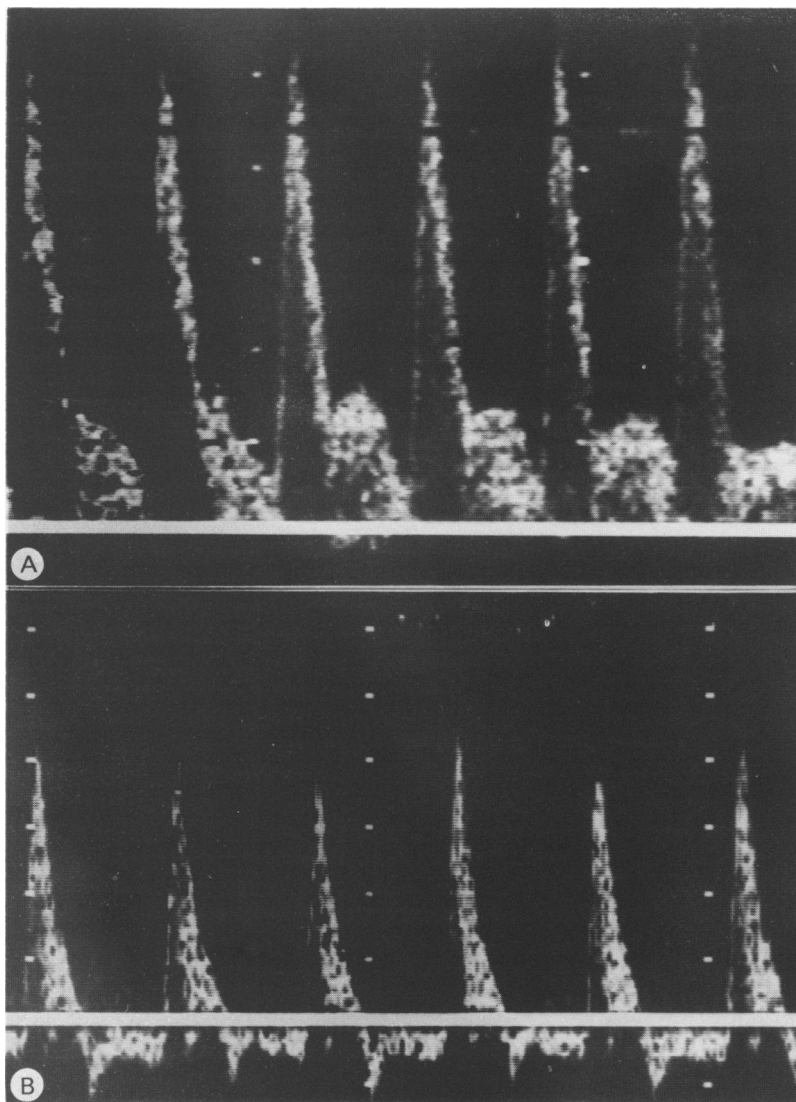


Figure 1 Typical ranges of superior mesenteric artery velocity (A) in a control child, and (B) in an infant with a symptomatic patent ductus arteriosus. Ranges above the line indicate antegrade, and below the line retrograde, flow. Note the retrograde diastolic flow in (B).

velocity ranges in subjects with symptomatic patent ductus arteriosus were characterised by absent end diastolic forward flow, or in some cases retrograde diastolic flow (flow out of the superior mesenteric artery during diastole) (fig 1B).

Coeliac axis

Controls: At no time during the study periods was there absent or retrograde diastolic flow in any of the control subjects.

Study subjects: Retrograde flow was rarely seen in the coeliac axis, and in only eight cases (four in each study group), was there absent end diastolic forward flow.

EFFECTS OF INDOMETHACIN

Indomethacin by bolus

Indomethacin led to a rapid and profound fall in peak systolic velocity, time averaged mean velocity, and area under the peak velocity

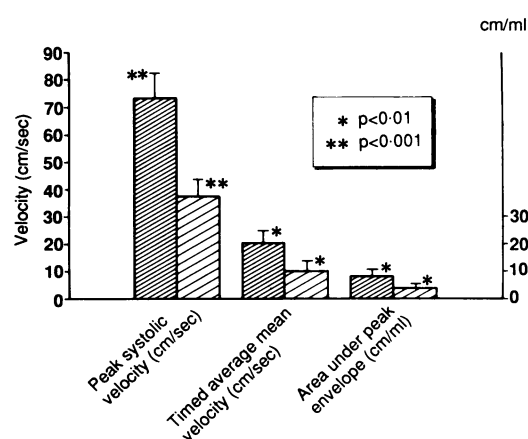


Figure 2 Effects of a bolus dose of indomethacin on peak systolic velocity, time averaged mean velocity, and area under peak velocity envelope in nine infants. Close hatched bars indicate minimum values in the superior mesenteric artery before indomethacin was given, and wide hatched bars indicate the values after administration of indomethacin. Values are mean (SD).

envelope in the superior mesenteric artery (fig 2), such that the mean (SD) peak systolic velocity fell from 74 (30) cm/sec before indomethacin was given, to 38 (13) cm/sec after the bolus ($p < 0.008$).

In the coeliac axis the changes in peak systolic velocity were qualitatively similar but the magnitude of the fall was substantially less, being 63 (19) cm/sec before indomethacin was given and 43 (16) cm/sec after the bolus ($p < 0.03$). The median time to the maximal fall in peak systolic velocity was 7.4 minutes (range 1.4–16) in the superior mesenteric artery and 8.0 minutes (range 3.5–26) in the coeliac axis.

After this profound fall in velocity within the superior mesenteric artery, the median time to recovery was 50 minutes (range 15–191). In the five subjects whose recovery times were longer than 50 minutes closure of the ductus was successful. In contrast, indomethacin did not permanently close the ductus in three of the four subjects whose recovery time for peak systolic velocity was less than 50 minutes.

Slow infusion of indomethacin

After slow infusion of indomethacin, the fall in peak systolic velocity in the superior mesenteric artery was not significant, falling from a mean (SD) of 71 (24) cm/sec to 56 (32) cm/sec at the maximum fall in velocity. Similarly there was no significant change in coeliac artery peak systolic velocity, being 63 (19) cm/sec before indomethacin was given, and 66 (33) cm/sec at the inflection of the velocities.

As the range of velocities before indomethacin was given in both studies was wide we have compared the percentage fall instead of the actual fall in peak systolic velocity between the two studies. The percentage fall of peak systolic velocity in the superior mesenteric artery after the bolus dose of indomethacin was significantly greater than the fall associated with the slow infusion of indomethacin: 47% (range 20 to 63) with the bolus of indomethacin compared with 22% (range -33 to +53) with the slow infusion ($p < 0.02$). The fall in peak systolic velocity was

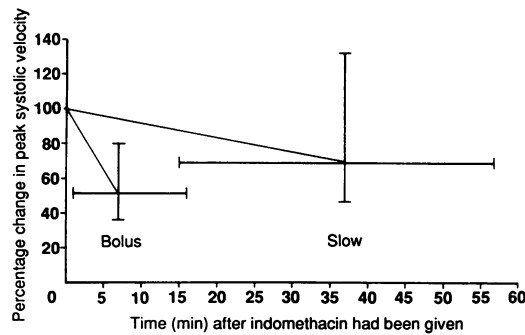


Figure 3 Comparison of magnitude and time course of changes in peak systolic velocity in the superior mesenteric artery after bolus and slowly infused doses of indomethacin.

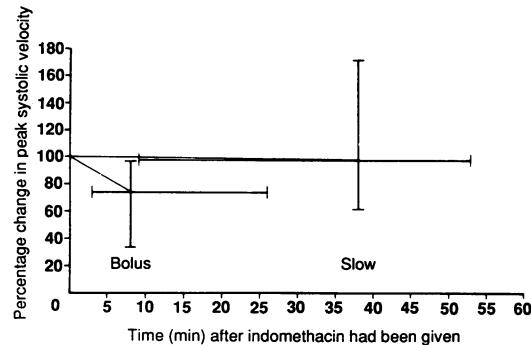


Figure 4 Comparison of magnitude and time course of changes in peak systolic velocity in the coeliac axis after bolus and slowly infused doses of indomethacin.

also greater in the coeliac axis after the bolus dose of indomethacin: (31% (range 3 to 65) after the bolus dose of indomethacin compared with -3% (range -72 to +39) with the slow infusion ($p < 0.04$)).

After the slow infusion of indomethacin the time to the maximal change in velocity was also significantly longer in both the superior mesenteric artery and coeliac axis. In the superior mesenteric artery it was 37 minutes after the slow infusion, compared with 7.4 min after the bolus ($p < 0.003$). At the coeliac axis it was 38 minutes after the slow infusion, compared with 8 minutes after the bolus ($p < 0.0013$) (figs 3 and 4).

Return of antegrade diastolic flow

Return of antegrade diastolic flow after the first dose of indomethacin was the first clinical indication of the likelihood of closure of the ductus. Among the 18 subjects studied on 19 occasions there was a close association between return of antegrade diastolic flow within one hour of the first dose of indomethacin and sub-

Table 2 Association between return of antegrade end diastolic flow in the superior mesenteric artery within one hour of the first dose of indomethacin (bolus or slowly infused) and subsequent ductal closure after 19 courses of indomethacin ($p < 0.002$)

	Ductus closed	Ductus reopened or no change
Return of end diastolic volume within one hour	11	1
No return of end diastolic volume within one hour	2	5

sequent clinical ductal closure ($p < 0.002$; table 2).

Efficacy and side effects

There was no apparent loss of efficacy with the slow infusion of indomethacin. Seven of 10 ducts closed clinically, one reopened and was ligated, and two remained open. Of the eight subjects who received bolus doses of indomethacin, closure of the ductus occurred in five with the first course, in one with the second, and two remained open. No serious gastrointestinal side effects were seen; one subject in the bolus group developed a transient paralytic ileus.

Discussion

Work in experimental animals together with the known clinical risk factors indicate that ischaemia probably plays at least a part in the pathogenesis of necrotising enterocolitis. In newborn piglets, for example, significant falls in blood flow were seen after severe acute asphyxia,¹² as well as after a less severe prolonged period of asphyxia.¹³ On histological examination in each case there was evidence of ischaemia with congestion, haemorrhage,¹² and areas of necrosis.¹³

A patent ductus is a known risk factor for necrotising enterocolitis.¹⁵ Our observations on gut blood flow velocities in preterm infants lead us to believe that the absent or retrograde diastolic flow found in infants with symptomatic patent ductus arteriosus represents a compromised splanchnic circulation, and suggests a possible mechanism whereby a patent ductus may predispose to necrotising enterocolitis.

Absent forward end diastolic flow in the superior mesenteric artery seems to indicate patent ductus arteriosus. It was seen in all subjects with a symptomatic patent ductus arteriosus, and in only three of the control subjects on day 1 only—a time when an asymptomatic patent ductus commonly occurs.

Indomethacin by bolus leads to a profound and sustained fall in splanchnic blood flow velocity, further compromising the vascular bed. The mechanism of the fall in velocity is not known, although similar changes have also been seen in the splanchnic circulation of cats and dogs after they were given indomethacin.^{16 17} In cats the response was dose related and not inhibited by previous exposure to the known cyclooxygenase inhibitor, meclofenamic acid. In dogs profound mesenteric vasoconstriction was seen after indomethacin had been given, but not after ibuprofen, which has a similar inhibitory effect on cyclooxygenase. This supports the view that the vasoconstricting effect of indomethacin on the splanchnic circulation is independent of its actions on prostaglandin metabolism.

In two infants in whom the effects of all three bolus doses of indomethacin were recorded, we noted that the vasoconstricting response became progressively less. The percentage maximum fall in velocity decreasing from 58% to 7% and 50% to 16%. Similar effects have been reported in the cerebral circulation of adult man,⁹ but

have not been examined in the cerebral circulation of neonates.

Necrotising enterocolitis, local intestinal perforation, and haemorrhage have all been documented in neonates receiving both parenteral and enteral indomethacin. Indomethacin given rectally in dogs profoundly reduced mucosal blood flow to the stomach, and the mid and distal ileum, suggesting that changes in blood flow may be just as important after indomethacin has been given enterally.¹⁸

In the infant with tetralogy of Fallot in our study there was good antegrade diastolic flow before indomethacin had been given (7.2 cm/sec). After the indomethacin had been given there was a pronounced fall in peak systolic velocity of 58%, which recovered after one hour. There was no apparent change in the clinical condition. This provides further evidence that indomethacin has effects on the splanchnic vascular bed which are independent of its actions on the ductus.

Our data suggest that the vasoconstricting effects of a bolus dose of indomethacin on a splanchnic vascular bed that is already compromised by a patent ductus arteriosus provide at least one explanation for the gastrointestinal side effects of indomethacin. This effect of a bolus dose of indomethacin can be avoided by giving the drug by slow infusion. No adverse gastrointestinal effects were seen when indomethacin was infused slowly, nor was there any apparent loss of efficacy in closure of the ductus. One infant with abdominal distension and blood and mucus in his stool, but with no intramural gas on abdominal radiograph, was successfully managed with a slow infusion of indomethacin.

We thank the medical and nursing staff of the neonatal unit at the Birmingham Maternity Hospital, and Melvyn Docker and Phil Williams of the department of medical physics for technical help.

- 1 Gersony WM, Peckham GJ, Curtis Ellison R, Miettinen OS, Nadas AS. Effects of indomethacin in premature infants with patent ductus arteriosus: results of a national collaborative study. *J Pediatr* 1983;102:895-906.
- 2 Rudd P, Montanez P, Hallidie-Smith K, Silverman M. Indomethacin treatment for patent ductus arteriosus in very low birthweight infants: double blind trial. *Arch Dis Child* 1983;58:267-70.
- 3 Alpan G, Eyal F, Vinograd I, et al. Localized intestinal perforations after enteral administration of indomethacin in premature infants. *J Pediatr* 1985;106:277-81.
- 4 Kuhl G, Wille L, Bolkenius M, Seyberth HW. Intestinal perforation associated with indomethacin treatment in premature infants. *Eur J Pediatr* 1985;143:213-6.
- 5 Scholz TD, McGuinness GA. Localised intestinal perforation following intravenous indomethacin for patent ductus arteriosus. *J Pediatr Gastroenterol Nutr* 1988;7:773-5.
- 6 Nagaraj HS, Sandhu AS, Cook LN, Buchino JJ, Groff DB. Gastrointestinal perforation following indomethacin therapy in very low birthweight infants. *J Pediatr Surg* 1981;16:1003-7.
- 7 Walters M. Tolerance of intravenous indomethacin treatment for premature infants with patent ductus arteriosus. *Br Med J* 1988;297:773-4.
- 8 Vanhaesebrouck P, Thiery M, Leroy JG, et al. Oligohydramnios, renal insufficiency, and ileal perforation in preterm infants after intrauterine exposure to indomethacin. *J Pediatr* 1988;113:738-43.
- 9 Eriksson S, Hagenfeldt L, Law D, Patrono C, Pinca E, Wennalm A. Effect of prostaglandin synthesis inhibitors on basal and carbon dioxide stimulated cerebral blood flow in man. *Acta Physiol Scand* 1983;117:203-11.
- 10 Cowan F. Indomethacin, patent ductus, and cerebral blood flow. *J Pediatr* 1986;109:341-4.
- 11 Lundell BPW, Sonesson S-E, Cotton RB. Ductus closure in preterm infants. *Acta Paediatr Scand* 1986;329(suppl):140-7.
- 12 Touloukian RJ, Posch JN, Spencer R. The pathogenesis of ischemic gastroenterocolitis of the neonate; selective gut mucosal ischemia in asphyxiated neonatal piglets. *J Pediatr Surg* 1972;7:194-205.
- 13 Alward CT, Hook JB, Helmtrath TA, Mattson JC, Baillie MD. Effects of asphyxia on cardiac output and organ blood flow in the newborn piglet. *Pediatr Res* 1978;12:824-7.
- 14 Hackett GA, Campbell S, Gamsu H, Cohen-Overbeek T, Pearce JM. Doppler studies in the growth retarded fetus and prediction of necrotising enterocolitis, haemorrhage and neonatal morbidity. *Br Med J* 1987;294:13-6.
- 15 Ryder RW, Shelton JD, Quinan D. Necrotising enterocolitis: A prospective multicenter investigation. *Am J Epidemiol* 1980;112:113-23.
- 16 Lippton HL, Armstead WM, Hyman AL, Kadowitz PJ. Characterization of the vasoconstrictor activity of indomethacin in the mesenteric vascular bed of the cat. *Prostaglandins Leukotrienes Med* 1987;27:81-91.
- 17 Feigen LP, King LW, Ray J, Beckett W, Kadowitz PJ. Differential effects of ibuprofen and indomethacin in the regional circulation of the dog. *J Pharmacol Exp Ther* 1981;219:679-84.
- 18 Cronen PW, Najjar HS, Janik JS, Groff DB, Passmore JC, Hock CE. Effect of indomethacin on mesenteric circulation in mongrel dogs. *J Pediatr Surg* 1982;17:474-8.