

Neonatal diaphragmatic paralysis caused by chest drains

H Arya, J Williams, S N Ponsford, J G Bissenden

Abstract

A boy delivered at 32 weeks' gestation developed bilateral pneumothoraces that required multiple chest drains. He was dependent on the ventilator for 52 days because of bilateral diaphragmatic paralysis. Electrophysiological studies confirmed phrenic nerve damage. He eventually made a full recovery. It is likely that this damage was caused by the insertion of the chest drains.

The problem of the baby who refuses to breathe effectively after ventilation is one familiar to neonatologists. When the problem is not one of prematurity, the difficulty is deciding whether the cause of underbreathing is central or neuromuscular. We present a case of paralysed diaphragms where the cause was iatrogenic.

Case report

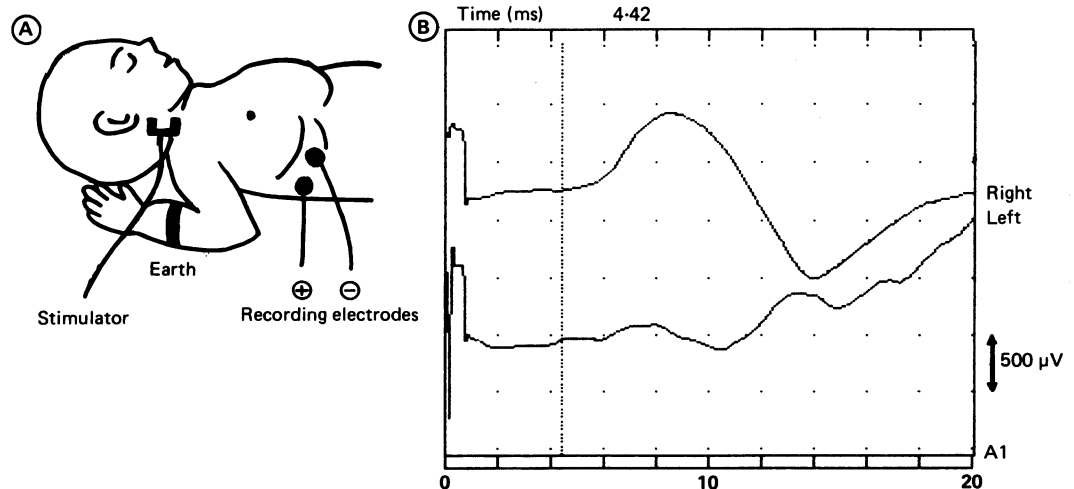
A boy was delivered at 32 weeks' gestation by caesarean section because of maternal pre-eclamptic toxemia. He weighed 1810 g, and his Apgar scores were 8 at 1 minute and 9 at 5 minutes. He rapidly became tachypnoeic and by 4 hours of age had been intubated and was requiring full ventilation. Chest radiography confirmed moderate respiratory distress syndrome. Poor synchrony with the ventilator necessitated paralysis with atracurium for 48 hours. When the paralysis was stopped he developed pneumothoraces, first on the left and then on the right. Over the next four days three chest drains were put in the right and two in the left pleural cavities. The air leaks sealed

and by day 7 he required only minimal ventilation. Any attempt at weaning from the ventilator, however, resulted in profound hypoxia. Although his limb movements were normal, it was clear that his respiratory excursion was poor.

The differential diagnosis lay between an acquired bilateral diaphragmatic paralysis or a congenital neuromuscular condition. Although the latter seemed unlikely in view of the generalised adequacy of movement and tone, edrophonium was given as a test for myasthenia gravis. After the edrophonium had been given his condition deteriorated and temporarily he needed more respiratory support. Ultrasonography of the diaphragms during spontaneous breathing showed poor diaphragmatic excursion, which was confirmed on fluoroscopy.

In view of this, phrenic nerve conduction was carried out by stimulating each side of the neck using a stimulation of 0.1 milliseconds duration at 1 Hz. Recording was performed with silver/silver chloride disc electrodes over the sixth intercostal spaces in the anterior axillary line. (figure). This was carried out on day 19, and there was no recordable potential on either side. The right median nerve action potentials were normal.¹ This excluded generalised neuropathy and localised the lesion at the phrenic nerve bilaterally.

He was ventilated for a total of 52 days with frequent episodes of bradycardia and anoxia. These episodes became less frequent, and when he was eventually extubated fluoroscopy showed normal diaphragmatic movement on the right but diminished movement on the left.



Department of
Neonatal Paediatrics,
Dudley Road Hospital,
Birmingham B18 7QH
H Arya
J Williams
S N Ponsford
J G Bissenden

Correspondence to:
Dr Bissenden.

Accepted 31 October 1990

(Arch Dis Child 1991;66:441-2) Phrenic nerve conduction studies showing (A) technique and (B) the recording at the age of 3 months.

Phrenic nerve studies showed that the right phrenic nerve was excitable with a latency of 3.3 milliseconds but the evoked muscle action potentials were small (100 microvolts). The left side remained unexcitable. The baby was discharged home before diaphragmatic movement had returned to normal. Three months later he was thriving without respiratory problems. The phrenic nerve studies showed a normal diaphragmatic response on the right (4.4 milliseconds, 1.5 microvolts). The left phrenic nerve was excitable even though the response was small (4.4 milliseconds, 200 microvolts) (figure).

Discussion

The phrenic nerve studies on this neonate were of great help. The median mixed nerve action potentials and edrophonium (Tensilon) test excluded generalised neuropathy and myasthenia gravis, and serial phrenic nerve studies confirmed that the bilateral diaphragmatic paralysis was the result of phrenic nerve dysfunction. Of the cases of paralysed diaphragms in the newborn period, 80–90% are the result of brachial plexus injury and 5% of all brachial plexus injuries have associated diaphragmatic paralysis.² Of traumatic causes, damage during cardiac surgery is a well recognised problem.³ The treatment of a pneumothorax by insertion of a chest drain is an all too common experience in a neonatal unit. Complications of this procedure include perforation of the lung parenchyma,⁴ but surprisingly, phrenic nerve

injury secondary to insertion of a chest drain has been reported only twice to our knowledge, and on both occasions the paralysis was unilateral.^{5,6}

Drainage tubes placed deep in the chest carry a risk of injury to the phrenic nerve.⁶ It was clear from reviewing the series of radiographs that two basal and two apical chest drains had impinged on the baby's mediastinum. The phrenic nerves run down in the mediastinum over the pericardium, and theoretically any of the four drains could have caused nerve damage.

The message is that diaphragmatic paralysis may be a cause of failure to wean a baby from the ventilator who has had bilateral chest drains inserted. If the chest drains are reaching the mediastinum, they should be withdrawn fractionally, even if they are functioning well. When the cause of underbreathing is not clear, phrenic nerve conduction studies are helpful.

- 1 Russell RI, Logan-Sinclair R, Shinebourne EA, Green M. Measurement of phrenic nerve latency in children undergoing cardiac surgery. *Electroencephalography and clinical neurophysiology* 1988;70:131P.
- 2 Volpe JJ. Injuries of extracranial, cranial, intracranial, spinal cord and peripheral nervous system structures. In: Volpe JJ, ed. *Neurology of the newborn*. 2nd Ed. Philadelphia: WB Saunders, 1987:638–61.
- 3 Smith CD, Sade RM, Crawford FA, Othersen HB. Diaphragmatic paralysis and eventration in infants. *J Thorac Cardiovasc Surg* 1986;91:490–7.
- 4 Moessinger AC, Driscoll JM Jr, Wigger HJ. High incidence of lung perforation by chest tube in neonatal pneumothorax. *J Pediatr* 1978;92:635–7.
- 5 Ayalon A, Anner H, Moghilner M, Schiller M. Eventration of the diaphragm due to phrenic nerve injury caused by intercostal drainage. *J Pediatr Surg* 1979;14:473–4.
- 6 Marinelli PV, Ortiz A, Alden ER. Acquired eventration of the diaphragm: a complication of chest tube placement in neonatal pneumothorax. *Pediatrics* 1981;67:552–4.