

Symmetrical thalamic lesions in infants

M Eicke, J Briner, U Willi, J Uehlinger, E Boltshauser

Abstract

Clinical observations and findings on imaging are reported in six newborns with symmetrical thalamic lesions (STL). In three cases the diagnosis was confirmed by postmortem examination. Characteristic observations in this series and 17 previously reported cases include no evidence of perinatal asphyxia, high incidence of polyhydramnios, absent suck and swallow, absent primitive reflexes, appreciable spasticity at or within days of birth, lack of psychomotor development, and death within days or months. Characteristic pathological findings include loss of neurons, astrogliosis, and 'incrusted' neurons particularly in the thalamus. In two thirds of cases the basal ganglia and brain stem are involved as well. A hypoxic-ischaemic event occurring two to four weeks before birth is most likely responsible for STL. Bilateral thalamic calcification can often, but not always, be demonstrated in the newborn period by computed tomography and/or cranial ultrasound. The presence of these calcifications and the observation of spasticity at birth imply that the responsible insult occurred at least two to four weeks earlier. The small number of published cases with STL suggest that it may be easily missed.

The first cases of symmetrical thalamic lesions in infants (STL) were reported in 1962 by Rosales and Riggs.¹ In the subsequent 28 years only 14 additional cases have been reported.²⁻⁹ Six cases of STL were seen at our hospital between 1982 and 1991. We would like to draw attention to this condition with particular emphasis on neonatal clinical presentation and findings on imaging. In this context we have preferred the term thalamic lesions, instead of the initial designation of thalamic degeneration used by Rosales and Riggs, to avoid the assumption of a progressive system degeneration.

Case reports

Relevant data of the published cases and our own observations are summarised in the table. The diagnosis was confirmed by postmortem examination in three of our cases; in the other three the diagnosis was based on typical clinical presentation and neuroradiological findings.

CASE 1

The mother was a 29 year old primigravida. The girl was born at 35 weeks' gestation by emer-

gency caesarean section due to breech presentation and maternal haemorrhage. The pregnancy had been uncomplicated except for an upper respiratory tract infection with fever in the last four weeks. The amniotic fluid was stained with meconium. The umbilical cord arterial pH was 7.29 and venous pH was 7.31. Apgar scores were 5, 9, and 9 at 1, 5, and 10 minutes. The infant was intubated due to increasing respiratory distress. The chest radiograph showed a totally opaque left lung, presumably due to atelectasis.

Clinical findings

The birth weight was 1820 g (10th centile) and the head circumference was 30.5 cm (10th-50th centile). The infant made no spontaneous movements, there was pronounced spasticity with leg abduction, exaggerated tendon reflexes, and absent suck and swallow (fig 1). Upon establishing the diagnosis of bilateral thalamic lesions it was decided, in view of the poor prognosis, to withdraw aggressive support. She died some hours later at 4 days of age.

Additional investigations

Cranial ultrasound on the second day of life showed mild irregular periventricular hyper-echogenicity and narrow lateral ventricles. Magnetic resonance imaging on the fourth day of life gave normal results. An electroencephalogram (EEG) at 3 days was within normal limits. A metabolic screen (amino acids and organic acids) and TORCH serology (toxoplasma, rubella, cytomegalovirus, and herpes virus) were negative.

Summary of relevant data in all published cases of STL including the present series

	Previously published cases (n=17)*	Present series (n=6)
Mean duration of pregnancy (weeks)	37	38.5
Range	32-42	35-40.5
Polyhydramnios	5/10	3/6
Apgar score at 1 minute ≤ 4	2/10	1/6
Apgar score at 5 minutes ≤ 6	6/9	3/6
No spontaneous motor activity	6/9	4/6
Spasticity:		
From birth	5/16	3/6
Within days of birth	6/16	3/6
Absent primitive reflexes	8/8	5/6
Absent swallow	15/15	5/6
Neonatal convulsions	8/14	1/6
Postmortem examination:		
Thalamic lesions	14/14	3/3
Basal ganglia affected	4/14	2/3
Brain stem involved	9/14	1/3

*Information not complete for all cases.

University of Zurich,
Switzerland,
Department of
Paediatrics

M Eicke
U Willi
J Uehlinger
E Boltshauser

Institute of Pathology,
Division of
Paediatric Pathology
J Briner

Correspondence to:
Professor E Boltshauser,
Children's University
Hospital,
Steinwiesstrasse 75,
CH-8032 Zurich,
Switzerland.

Accepted 14 July 1991

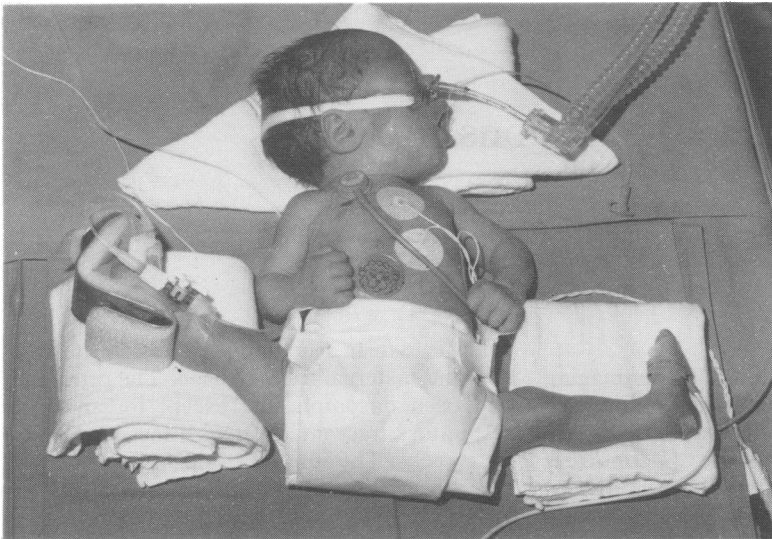

Figure 1 Case 1 at 3 days showing appreciable spasticity with abduction of lower limbs.

Findings on postmortem examination

Severe gliosis with mineralised neurons and neuronal loss in both thalami, hypothalamus, corpus geniculatum mediale, dorsal pons, and medulla oblongata were found. There was mild oedema and interstitial emphysema of the lungs.

CASE 2

The mother was 28 years old and gravida two, para two. The pregnancy had been complicated by polyhydramnios (time of onset not documented). At 35 weeks' gestation an abnormal external fetal heart rate trace was noted but a repeat on the next day was normal. An amniocentesis was normal. The girl was born by spontaneous vaginal delivery at 37 weeks' gestation. The amniotic fluid was stained with meconium. The umbilical cord arterial pH was 7.26 and venous pH was 7.48. Apgar scores were 6, 8 and 9, at 1, 5, and 10 minutes.

Clinical findings

The birth weight was 3220 g (90th centile) and the head circumference was 35.2 cm (greater than 90th centile). Decreased spontaneous activity, hypotonia with hyperreflexia, and absent suck and swallow were noted. Gavage feeding was necessary. She had symmetrical but reduced facial movements, incomplete closure of the eyes, and an absent corneal reflex. She made no psychomotor progress and died unexpectedly after a respiratory arrest at 6 weeks of age.

Additional investigations

Cranial ultrasound on the second day of life demonstrated increased echogenicity in the region of the thalamus that was more distinct on the left side. Computed tomography on the sixth day showed diffuse subcortical hypodensities and irregular density of the thalami (fig 2). An EEG on the third day showed

multifocal discharges but no seizures were observed. A metabolic screen (amino acids and organic acids) and TORCH serology were negative.

Findings on postmortem examination

Mineralised neuronal necrosis bilaterally in the lateral thalamus, diffuse gliosis of the cortex, and severe aspiration pneumonia were found.

CASE 3

The mother was 41 years old and gravida three, para one. She had had two previous spontaneous first trimester abortions. Because of maternal age, the boy was born by elective caesarean section at 39 weeks' gestation after an uncomplicated pregnancy. The Apgar scores were 9, 9, and 9 at 1, 5, and 10 minutes. At 24 hours of life severe hypoglycaemia occurred and was treated with glucose infusion.

Clinical findings

The birth weight was 3430 g (50th–90th centile) and the head circumference was 36 cm (50th–90th centile). At birth the infant was apathetic, spontaneous movements were clearly diminished, and muscle tone was generally increased. He was a poor feeder, there was repeated vomiting, and difficulty maintaining body temperature. He did not fix with his eyes. There was pendular horizontal and vertical nystagmus. The pupils did not react to light. The optic discs appeared hypoplastic. Laboratory examinations showed hypothalamic panhypopituitarism. (Thyroid stimulating hormone 4.6 mU/l (normal range 1–3.7), thyroxine 60 nmol/l (65–145), cortisol 28 nmol/l (200–500), luteinising hormone 36 µg/l (low), follicle

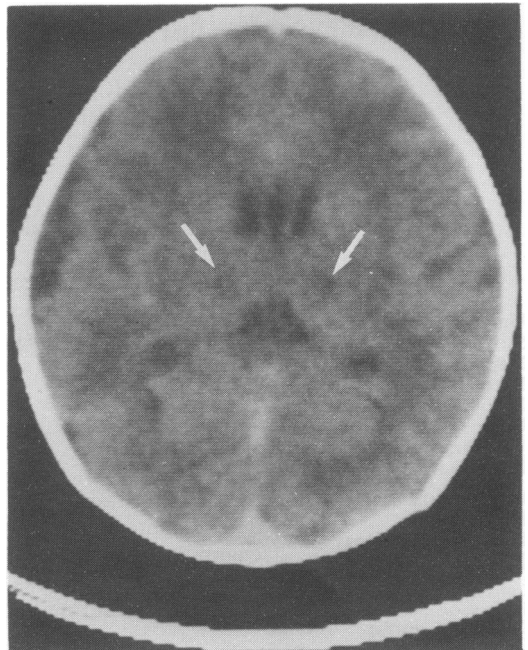


Figure 2 Computed tomogram of case 2 at 6 days showing diffuse irregular hypodensities of the white matter, thalamic hypodense (arrows). Thalamic lesions were confirmed at postmortem examination.

stimulating hormone 7 µg/l (low), and basal prolactin 2073 mU/l (≤ 500 .) After hormonal substitution with thyroxine (at 4 weeks), corticosteroids (at 4 weeks), and vasopressin (at 7 weeks) the infant's general condition improved: his vomiting stopped and he was able to drink. At 8 weeks of age, during a discharge examination, he appeared well and his muscle tone and reflexes were normal. He had persistent vertical and horizontal nystagmus and absent pupillary reaction to light. At 8.5 months he died unexpectedly at home.

Additional investigations

Cranial ultrasound on the sixth day showed mild dilatations of the lateral ventricles. At 4 weeks a distinct hyperechogenic lesion was seen in the thalamus bilaterally (fig 3). In retrospect this was also visible on a prior, technically suboptimal study. At 8 weeks there was mild increase in size of the lesions with increasing width of the lateral ventricles. Computed tomography on the 26th day confirmed the ultrasound findings (fig 4).

Findings at postmortem examination

There were symmetric calcifications in the lateral thalamus, globus pallidus, and capsula interna with hypoplastic corticospinal tracts, with incrustated neurons, axonal swelling, and neuroaxonal dystrophy. A von Kossa stain was positive. Diffuse gliosis and decreased myelination of the white matter was found as well as septo-optic dysplasia with hypoplastic nerves and tracts. Additional findings included hypoplasia of the nerve fibre and ganglion layer in the retina, cataract, hypoplasia of anterior and posterior pituitary lobes, appreciable hypoplasia of both adrenal glands and testes, and micro-penis.

CASE 4

The mother was 31 years old and gravida four, para four. She had Hodgkin's disease and had been treated with chemotherapy and radiotherapy five years before this pregnancy. She

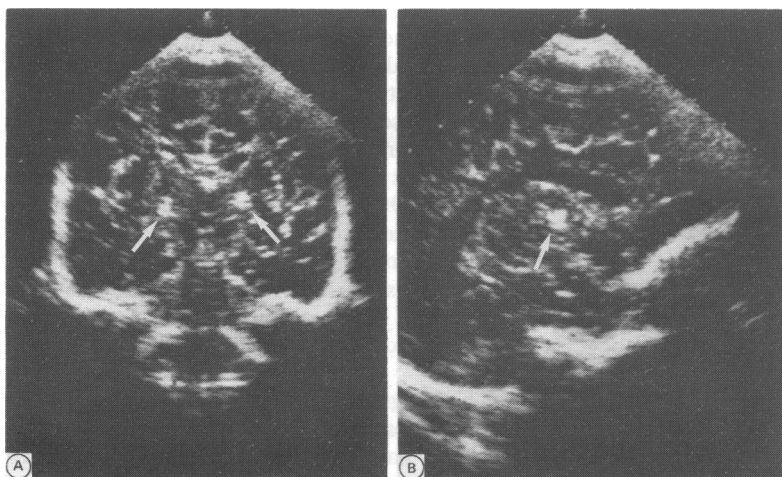


Figure 3 Case 3: (A) coronal and (B) sagittal sonograms at 4 weeks of age with a distinct hyperechogenic lesion of the thalamic region bilaterally (arrows).

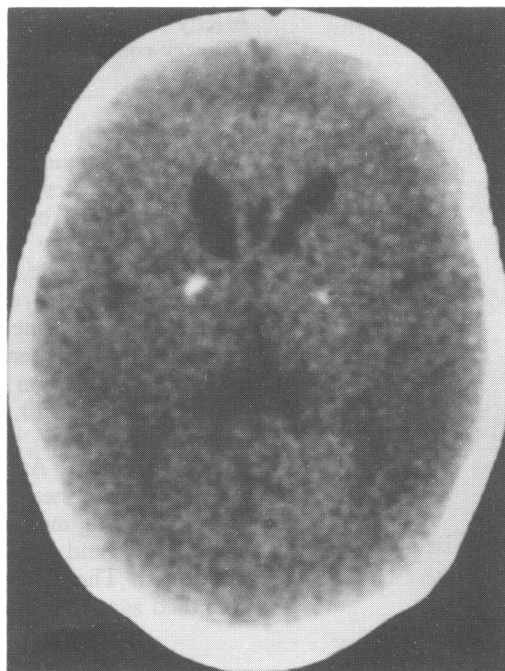


Figure 4 Case 3: Computed tomogram at 26 days with bilateral hyperdensities in the thalamic region.

had three healthy children. The pregnancy was complicated by polyhydramnios. Amnioscopy and external heart rate monitoring five days before birth were normal. The girl was born by uneventful spontaneous vaginal delivery at 39 weeks' gestation. Seven litres of clear amniotic fluid were noted. Apgar scores were 5, 5, and 7 at 1, 5, and 10 minutes. The infant required oxygen by mask and some hours later had to be intubated because of respiratory acidosis (pH 7.18, carbon dioxide tension 8.3 kPa).

Clinical findings

The birth weight was 3240 g (50th–90th centile) and the head circumference was 32 cm (slightly less than 3rd centile). She showed no spontaneous activity, suck, or swallow. Appreciable spasticity with bilateral subluxation of the hips was observed in the delivery room. Deep tendon reflexes were brisk with bilateral ankle clonus. A diagnosis of STL was very likely in our view, therefore on the third day the infant was extubated and died 12 hours later.

Additional investigations

Cranial ultrasound on the first day showed a large third ventricle. Permission for post-mortem examination was refused.

CASE 5

The mother was a 22 year old primigravida. After an uncomplicated pregnancy the girl was born at 40 weeks' gestation by a caesarean section because of abnormal external heart rate monitoring and failure to progress. Umbilical cord arterial pH was 7.29. Apgar scores were 1, 6, and 9 at 1, 5, and 10 minutes. The infant

briefly required bag and mask ventilation in the delivery room.

Clinical findings

The infant weighed 3280 g (50th centile) and her head circumference was 37 cm (greater than 90th centile). At birth she was hypotonic but after several days the upper limbs became increasingly spastic. Primitive reflexes were absent. Because of absent suck and swallow gavage feeding was necessary. Nursing care was complicated by hypersalivation. Severe apnoea prompted intubation and mechanical ventilation from day 7 to 10. Mild seizures occurred at 5 days and were successfully treated with phenobarbitone. At 7 months the clinical findings were nearly identical: pronounced spasticity with increased tendon reflexes and absent suck and swallow. Gavage feeding was continued. There was no motor development. She died age 8.5 months at home.

Additional investigations

Cranial ultrasound on the fifth day of life showed hyperechogenic areas in the region of the lateral thalamus. Computed tomography on the ninth day showed a distinct bilateral hyperdensity in the lateral thalamic/putaminal area (fig 5). Magnetic resonance imaging was tried on two occasions but was not possible because of considerable breathing difficulties after head positioning; imaging with intubation and anaesthesia was not felt justified. Permission for postmortem examination was refused.

CASE 6

The mother was 31 years old and gravida five,

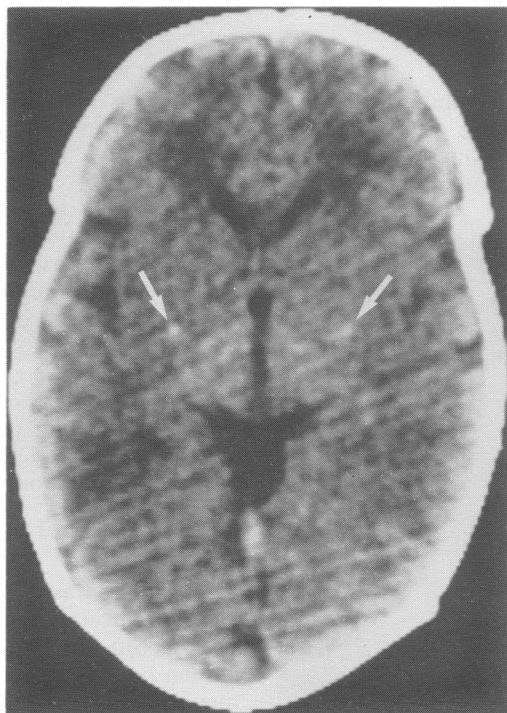


Figure 5 Case 5: Computed tomogram at 9 days showing small hyperdensities in the putaminal region.

para four. At 35 weeks' gestation she noted absent fetal movements and feared that the fetus was dead. Auscultation of fetal heart rate was normal; fetal heart rate monitoring and sonography were not done. An ultrasound investigation at 38 weeks showed polyhydramnios, which had not been present at 33 weeks. The boy was born by uncomplicated spontaneous delivery at 38 weeks' gestation. Amniotic fluid was clear. Umbilical cord arterial pH was 7.24 and venous pH was 7.30. Apgar scores were 5, 6, and 8 at 1, 5, and 10 minutes.

Clinical findings

The birth weight was 3490 g (50th–90th centile) and the head circumference was 34 cm (10th–50th centile). In the delivery room the neurological examination was striking: the infant was hypotonic and could not suck or swallow. A few hours later deep tendon reflexes were exaggerated, primitive reflexes were absent, and motor activity was diminished. Twenty two hours after birth spasticity of the legs was noted. Because of repetitive apnoea and carbon dioxide retention the child was intubated and transferred to our hospital. In our view the history and findings were typical for STL. On the sixth day of life the child was extubated; he died 30 minutes later.

Additional investigations

Cranial ultrasound on the sixth day of life was normal. Computed tomography on the fifth day showed diffuse subcortical hypodensities that were similar to case 2 (and had been proved at postmortem examination). An EEG on day 4 showed immature cerebral background activity with multifocal paroxysmal discharges without obvious seizures. A metabolic screen (amino acids, lactate, and pyruvate) was normal. Permission for postmortem examination was refused.

Discussion

STL appears to have a characteristic constellation of findings (table). Polyhydramnios is common and is likely to be caused by impaired intrauterine swallowing of amniotic fluid. This supports the idea of a prenatal origin for STL, which is also suggested by the presence of spasticity at or within days of birth. In almost all cases absence of suck, swallow, and primitive reflexes were observed. In our series neonatal convulsions were seen in only one patient (case 5). Other cranial nerve signs (pupillary abnormalities, disturbed ocular motility, and facial weakness) were occasionally noted in our patients (cases 2 and 3). Only in case 5 was there evidence of perinatal hypoxia; the Apgar scores and umbilical cord pH in all other cases were normal.

The prognosis of STL seems very poor. The reported patients have died within days to weeks or have survived, severely damaged, for only a few months. In view of this experience artificial ventilation was withdrawn in our cases 1, 4, and 6.

If STL is considered on clinical grounds we recommend a neuroradiological work up repeated as necessary. Ultrasonography is a useful tool in this work up: in our series thalamic hyperechogenicity was seen in three out of five cases.^{10 11} Computed tomography was performed in four patients. There was evidence of thalamic hyperdensity in two infants but not in the other two (one proved at postmortem examination). Our experience with magnetic resonance imaging is limited but it gave normal results in case 1 (STL proved at postmortem examination). These observations confirm the findings of Roland *et al*⁸ and DiMario and Clancy⁹ that neuroimaging may be normal at an initial stage and has to be repeated subsequently in surviving patients who have a clinical diagnosis of STL.

Neuropathological examination commonly demonstrates a thalamic lesion with additional and variable involvement of basal ganglia and brain stem. The typical histological findings consist of neuronal loss, astrogliosis, and 'incrusted' neurons. It is of interest that the astrogliosis often has a different topographic distribution and is not limited to the thalamus. The clinical signs are not easily explained by the neuropathological lesions. Case 3 is unusual in that he had in addition to STL, findings compatible with septo-optic dysplasia and panhypopituitarism.

Because the time interval required before appreciable tissue calcification becomes visible is two or more weeks,¹² it is likely that an event leading to STL occurs at least two weeks before birth. It is of great interest that in this time period significant events have been noted in many cases: abnormal cardiocotography 11 days before birth in case 2 and sudden loss of fetal movements three weeks before birth in case 6. Also reported are maternal trauma with subsequent labour four weeks before birth,⁶ salicylate intoxication three weeks before birth² and reduced fetal movements in last few weeks of pregnancy.⁷ Therefore an acute hypoxic-ischaemic event occurring two to four weeks before birth is considered a likely possible explanation for STL. Myers¹³ and Ranck *et al*¹⁴ found similar histological changes in the thalamus and brain stem after a single episode of total anoxia in monkey fetuses.

So far published cases of STL have been sporadic with the exception of two siblings reported by Abuelo *et al*.⁴ The empiric recurrence risk for further similarly affected children appears to be very low.

STL of prenatal onset has to be separated from postnatal spontaneous intrathalamic haemorrhage (which has a comparatively favourable outcome¹⁵) as well as from thalamic haemorrhages observed after severe perinatal asphyxia.^{16 17}

As we have been able to collect six cases within eight years, and the total number of previously reported cases is only 17, we feel that STL may be more common than previously thought. The diagnosis may be missed if the clinical signs are not recognised. Normal neuroimaging in the newborn period does not exclude the diagnosis and repeated investigations may be needed.

We are grateful to Dr E Martin, Dr D Mieth, and Dr U Hunziker for additional information.

- 1 Rosales RK, Riggs HE. Symmetrical thalamic degeneration in infants. *J Neuropathol Exp Neurol* 1962;21:372-6.
- 2 Norman MG. Antenatal neuronal loss and gliosis of the reticular formation, thalamus, and hypothalamus. *Neurology* 1972;22:910-6.
- 3 Ambler M, O'Neill W. Symmetrical infantile thalamic degeneration with focal cytoplasmic calcification. *Acta Neuropathol (Berl)* 1975;33:1-8.
- 4 Abuelo DN, Barsel-Bowers G, Tutschka BG, Ambler M, Singer DB. Symmetrical infantile thalamic degeneration in two sibs. *J Med Genet* 1981;18:448-50.
- 5 Wilson ER, Mirra SS, Schwartz JF. Congenital diencephalic and brain stem damage: neuropathologic study of three cases. *Acta Neuropathol (Berl)* 1982;57:70-4.
- 6 Parisi JE, Collins GH, Kim RC, Crosley CJ. Prenatal symmetrical thalamic degeneration with flexion spasticity at birth. *Ann Neurol* 1983;13:94-7.
- 7 Jennekens FGI, Barth PG, Fleury P, Veldman H, Keuning JF, Westdorp J. Axonal dystrophy in a case of congenital thalamic and brain stem degeneration. *Acta Neuropathol (Berl)* 1984;64:68-71.
- 8 Roland EH, Hill A, Norman MG, Flodmark O, MacNab AJ. Selective brainstem injury in an asphyxiated newborn. *Ann Neurol* 1988;23:89-92.
- 9 DiMario FJ, Clancy R. Symmetrical thalamic degeneration with calcifications of infancy. *Am J Dis Child* 1989;143:1056-60.
- 10 Babcock DS, Ball W. Postasphyxial encephalopathy in full-term infants: ultrasound diagnosis. *Radiology* 1983;148:417-23.
- 11 Shen EY, Lin JCT, Shih CC. Pathological echogenicity of the thalamus in newborn and young infants. *Journal of the Formosan Medical Association* 1988;87:891-7.
- 12 Ellis WG, Goetzman BW, Lindenberg JA. Neuropathologic documentation of prenatal brain damage. *Am J Dis Child* 1988;142:858-66.
- 13 Myers RE. Brain damage induced by umbilical cord compression at different gestational ages in monkeys. *Medical Primatology* 1970:394-425.
- 14 Ranck JB, Windle JR, Windle WF. Brain damage in the monkey, macaca mulatta, by asphyxia neonatorum. *Exp Neurol* 1959;1:130-54.
- 15 Trounce JQ, Fawer CL, Punt J, Dodd KL, Fielder AR, Levene MI. Primary thalamic haemorrhage in the newborn: a new clinical entity. *Lancet* 1985;i:190-2.
- 16 Kotagal S, Toce SS, Kotagal P, Archer CR. Symmetric bithalamic and striatal hemorrhage following perinatal hypoxia in a term infant. *J Comput Assist Tomogr* 1983;7:353-5.
- 17 Donn SM. Possible mechanisms of primary thalamic haemorrhage in newborn. *Lancet* 1985;i:823.