

time, the previous form of delayed acting insulin is resumed in single daily dosages reduced in corresponding amounts ( $\frac{1}{4}$ ,  $\frac{1}{2}$  or  $\frac{3}{4}$  of original dose) to the percentage reduction in diet.

#### SUMMARY

The plan described demonstrates the feasibility of a uniform, balanced, liberal basic diet in the commencement of the regulation ordeal in the treatment of diabetes. The ingredients of the menu are computed on the basis of edible portions. The portions of equivalent values serve as units for replacements, additions or deductions. A minor discrepancy enters into the matter of mathematical precision in the calculations because the exact percentage composition of the various elements of nutrition are not wholly standardized. There is an uncritical margin of error in servings which rates up to 15% according to dietitians' estimates.

A guide in prescribing insulin is outlined. Also a conversion scheme is mentioned when it is necessary to withhold food from a diabetic person on account of a surgical operation or for other reasons.

In review 200 records of patients were examined. Of this number 129 began with the basic diet plan. Before this procedure was adopted 71 were started on the traditional basal calorie induction method. The net result was: 16 did not require insulin; 9 used two kinds of insulin; 143 used a single daily dose; and in 33 the treatment was delegated to others. It is of interest to have found the total caloric requirements fell short of the amounts customarily advocated as necessary for maintenance at work.

---

If a sulfonamide must be prescribed for a second time, a different compound should be used, especially if reactions appeared during the original sulfonamide treatment. After 78 patients had fever, dermatitis, or conjunctivitis during sulfonamide therapy, 33, or 69%, of 48 subsequently given the same drug were similarly affected. Harry F. Dowling, M.D., and associates of George Washington University, Washington, D.C., observed that only 5, or 17%, of 30 patients from the original group had harmful reactions to a different sulfonamide. Of 9 patients reacting adversely to both of two courses of treatment, 5 had toxic manifestations when the same drug was given a third time. Toxic response on retreatment bore no relation to the original number of reactions.—*Ann. Int. Med.*, 24: 629, 1946.

## CASE REPORTS

### MUCINOUS ADENOCARCINOMA OF URACHUS, INVADING THE URINARY BLADDER\*

C. Agnew Cawker, B.A., M.D.

*Urologist to Shaughnessy Hospital,  
Vancouver, B.C.*

Like the urachal cyst, the mucinous carcinoma of the urachus is relatively rare, but it does occur, with extension to the urinary bladder, often enough for the urologist to be on the alert for its detection. Hayes and Segal, in 1945, reviewed 44 cases from the literature and added a case of their own (*Journal of Urology*, 53: 5, 1945).

The anlage of the urachus is the primitive hind gut of the early fetus. The type of development of the cells is decided by the proximity to the site of the urorectal septum formation and that the cells retain totipotent germinal powers with a tendency to develop along their respective three primitive layers. In one-third of the anatomical dissections the urachus communicated with the bladder cavity; however, a transverse fold of the mucosa acts as a valve and only with great increase of intravesical pressure will urine escape past this barrier. The lining of the urachus usually consists of one to three layers of epithelium without a basement membrane.

In their review of the reported cases, Hayes and Segal found that, as with urachal cysts, males predominate in the proportion of about two to one. The majority of these tumours occurred in males in the middle and latter age groups. The youngest case on record was a twenty-six year old male. Of all the cases reported, only one did not show the neoplasm completely eroded through the bladder mucosa. On cystoscopy, these cases showed either a fungating ulceration or a papillary mass of varying size at the vault of the bladder.

J.S., a 73-year old male, was first seen in the Urologic Clinic at Shaughnessy Hospital on May 5, 1944, complaining of frequency days 6 to 10, nights 3 to 4 for the past  $1\frac{1}{2}$  to 2 years, much worse for the past week, and pain in the left loin and groin of several days' duration. He had passed no sand or gravel in his urine. There had been no weight loss that he had noted. His general health was otherwise good. His bowels were regular and his appetite good. Physical examination

\* From the Department of Urology, Shaughnessy Hospital, Vancouver.

was essentially negative. Kidneys not palpable, but slight left costovertebral angle tenderness was present. The abdominal examination was negative. External genitalia were normal on palpation. Rectal examination showed good sphincter tone; hæmorrhoids present; no abnormality in the rectum noted on palpation. Prostate enlarged grade 1 plus, glandular, smooth, not tender, and not fixed. Residual urine 3 ounces. Excretory urogram showed apparently normal appearance and function of upper urinary tract. Marked osteoarthritis present. Cystogram was unfortunately cut off on all the films. Admission for prostatectomy was advised. Shortly after admission the patient developed an acute left epididymitis. Urine, dark amber, nsq., acid/leucocytes 4 plus, red blood cells rare to occasional albumen 3+, non-protein nitrogen 36 mgm. %, hæmoglobin 85%.

On June 1, a suprapubic cystostomy for drainage was done. A tumour the size of a golf ball was found in the wall of the vault of the bladder protruding into the bladder. This was widely excised. The prostate was noted as being moderately enlarged. A bilateral vasectomy was done.

*Pathological report.*—"A small sac-like structure the size of an almond nut from which protrudes a large papillary growth, 4 x 3 cm., which on section shows colloid appearance with fair circumscription of basal portion. The microscopic examination shows many tortuous, enlarged, aborted, frequently inter-communicating acinar formations lined by one or more layers of atypical columnar epithelium and in some areas there is a marked degree of mucoid or so-called 'colloid' change producing a typical picture of a colloid carcinoma. This does not suggest an origin from the bladder and more likely is either an extension or a metastasis of a colloid carcinoma of the gastro-intestinal tract. Sections through the wall of the sac show loss of lining epithelium and diffuse lymphocytic and plasma cell infiltration throughout the wall and there is no suggestion of any malignant process. Pathological

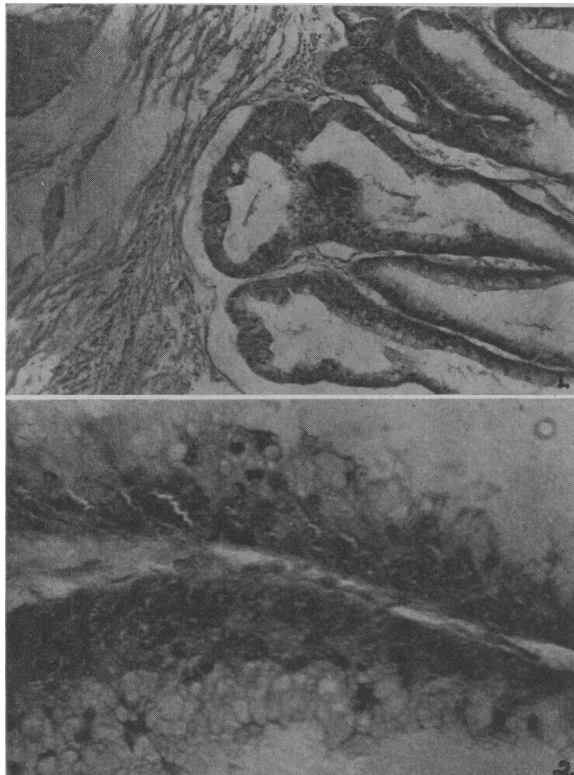


Fig. 1.—Magnification 10 x 6.  
 Fig. 2.—Magnification 45 x 6.

diagnosis is metastasis or extension of colloid carcinoma of the gastro-intestinal tract, probably rectum, colon, or cæcum to the urinary bladder."

A barium series and barium enema were done but showed no apparent abnormality of the gastro-intestinal tract. Proctoscopic examination revealed no abnormality of the rectum or sigmoid.

*Consultation report of the surgical specialist.*—"The tumour is secondary to growth of the cæcum most probably, but a laparotomy is not advised due to the age of the patient and the presence of metastasis."

Accordingly, he was discharged from hospital. He was advised to return in four months for re-examination.

However, this patient did not return for follow-up examination until January 28, 1946, when I first saw him. He was complaining of frequency days 7 to 10, nights 3 to 4 of four years' duration, also marked difficulty in starting the urinary stream, and slowness in emptying his bladder, with a weak, dribbling stream. All these symptoms had become progressively more severe since his discharge from hospital in 1944. He had lost no weight and had not passed blood either in his urine or in his stool. His bowel habits were regular. His physical examination on admission was essentially negative except for a blood pressure of 180/90. No costovertebral angle tenderness and his kidneys were not palpable. The suprapubic incision was well healed and there was no evidence of local recurrence of tumour in the scar. No mass could be palpated on bimanual examination. The prostate was enlarged grade 1 plus, glandular, smooth, not tender and mobile. Rectal sphincter tone was normal, hæmorrhoids were present but nothing abnormal could be palpated in the rectum.

The urine was amber, cloudy; 1.027; acid; occasional red cells; 3 plus white cells; albumen 3+. Culture showed *B. coli*. Excretory urogram showed apparently normal appearance and function of the upper urinary tract. Cystogram showed gross irregularity of the bladder contour and the floor of the bladder was elevated ½ inch above the symphysis pubis and a filling defect at the base was suggestive of shadow of prostatic intrusion. Marked osteoarthritis of lower dorsal and lumbar spine. No evidence of any metastatic lesion. X-ray of chest was negative. The cardio-thoracic ratio was 14.7 to 31 cm. Barium series and barium enema were normal and a proctoscopic examination revealed no abnormality of rectum or sigmoid. Cystoscopic examination of February 5, showed marked bladder trabeculation due to median bar type prostatic enlargement with grade 2 or 3 intra-urethral lateral lobe intrusion. Ureters were visualized but not catheterized. No evidence of tumour seen, although the site of the scar of the previous operation could be seen at the apex of the bladder.

I questioned the surgeon who performed the original suprapubic operation about the site of the tumour and sent a summary of the clinical findings to the pathologist who then kindly reviewed the microscopic slides of the growth with me. The pathological diagnosis was then changed to "Mucinous carcinoma of the urachus, invading the urinary bladder".

A per urethral prostatectomy was performed, and 18 gm. of tissue removed. Pathology report: "Benign prostatic hypertrophy".

The patient was discharged from hospital with a good postoperative functional result. He was instructed to report for cystoscopic examination in three months. He has been re-checked twice since then, the last examination being on November 12, 1946. There was no evidence of bladder tumour.

It is now almost three years since the bladder tumour was removed. There has been no sign of a recurrence of tumour. A review of the microscopic sections on January 2, 1947, leaves the pathological as well as the clinical diagnosis

unchanged. He is a three-year cure. It has been impressed upon the patient that he must return for re-examination every four months for the next two years and then once or twice a year.

This patient's only presenting symptoms were those of prostatism. The initial pain in the left loin and groin and burning on voiding were undoubtedly due to a prostatitis, vasitis and culminating in an acute epididymitis. It was probably for this reason that he was not cystoscoped prior to his operation. Undoubtedly cystoscopy would have revealed the tumour at the apex of the bladder. The patient at no time noticed blood in his urine. It was indeed unfortunate that the cystogram was cut off the films in the excretory urogram as they probably would have revealed a filling defect in the bladder vault that would have made the examiner suspicious of a tumour of the bladder before operation.

925 West Georgia.

### A CASE OF SCHISTOSOMIASIS IN MANITOBA

T. H. Williams, M.D., C. M., D.T.M.&H. (Eng.)\*

Winnipeg, Man.

Until recent years so-called tropical diseases have received far too little consideration in Canada. A rude and costly awakening occurred when the South West Pacific campaign bogged down at first for lack of knowledge of malariology and other parasitic diseases. A belated correction of the deficiency of training in recognition and treatment of tropical diseases was then made in most of our medical colleges. Such special knowledge is still necessary because many ex-service men who served in endemic areas of these diseases will present themselves with late results of such infection. Enquiry into the geographical travels and sojourns of such patients will often indicate the true diagnosis.

However, this fortunate solution of the case will only be so if the medical profession here are tropically conscious. The present cases being encountered of recurrent malaria will taper off and cease.<sup>1</sup> Amœbiasis has received considerable notice recently and its late results will continue

\* Pathologist, Deer Lodge Hospital, D.V.A., Winnipeg. Assistant Professor of Pathology, University of Manitoba.

to be important.<sup>2, 3, 4, 5</sup> In addition the possibility of such diseases as schistosomiasis, clonorchiasis, filariasis, giardiasis, etc., and the residual effects of other tropical diseases must be remembered and understood.

The following is a case in point:

J.L., a white male, aged 68, a veteran of the Boer War, was admitted to hospital complaining of hæmaturia; burning sensation on micturition; suprapubic pain; pain in the right loin; frequency by day 1½ hours, by night 2 hours; loss of weight 15 lb. over a period of years.

*History.*—In 1903 in Northern Transvaal during the Boer war he developed hæmaturia and dysuria and was told by the M.O. that he had "bilharzia" (schistosomiasis). He gave an indefinite history of intermittent hæmaturia every fortnight or so ever since but did not consider it important enough to consult a physician. Recently increasing suprapubic and right loin pain led him to consult a physician and he was then admitted to hospital for investigation April 6, 1946.

*Physical findings.*—Examination showed a thin old man not obviously anæmic. No skin lesions. Head and neck negative. Thorax, no evident disease. Electrocardiograph "probably normal". Pain in right loin; pain and tenderness over pubes. No palpable masses. Urinalysis during hospitalization showed gross blood and pus. Never any casts. Blood urea nitrogen on admission 15.8 mgm. %; before death 91.6 mgm. %.

Cystoscopy after admission revealed a "dirty bladder" with much phosphatic encrustation near the right ureteral orifice, which orifice could not be found. Subsequent repeated cystoscopy still showed no trace of the right ureteral orifice and intravenous pyelogram showed no sign of right kidney or dye excretion. The left kidney however was well visualized. Left retrograde urogram normal. Cystogram showed a double shadow resembling a diverticulum.

Digital rectal examination disclosed a flat firm mass above the prostate. Accordingly sigmoidoscopic examination was done and the condition was considered to be seminal vesiculitis. Further examination to rule out tumour was done. Barium enema was reported on as follows: Colon is negative. Cæcum not tender. Appendix is visualized. Barium series was done, with negative results.

Cystoscopy was then repeated before considering a right nephrectomy. Some of the encrusted material was scraped away from the region of the right ureteral orifice. Tissue from this area was sent to the pathologist and was reported as "papillary carcinoma". It was considered that further operation was inadvisable.

Patient steadily became more cachectic with frequency by day and night with some dysuria and gross hæmaturia at times. Transplantation of ureters to the exterior was considered inadvisable. After being semi-comatose for a week, he died October 12, 1946.

*Autopsy findings, gross.*—Externally, emaciation, cachexia, senility beyond age. The pertinent findings were as follows: Consolidation of lower lobes of both lungs with commencing abscess formation. Heart showed minimal arteriosclerotic changes in the coronaries.

The abdominal viscera were fixed by recent adhesions and there was thick yellow-green pus in the cavity which appeared to come from the pelvic retroperitoneal area. The liver showed metastatic white tumour nodules 2 cm. in diameter. Kidneys were both hydronephrotic, with ureters dilated irregularly in places to 3 to 4 cm. in diameter.

The bladder was filled with cloudy urine and firmly adherent on all surfaces. The lining was dark, roughened, thickened and encrusted and much of it was involved by diffuse infiltrating tumour growth. This tumour growth invaded surrounding structures and penetrates deeply into the rectal wall.