

at the rate of 1/3 gr. per lb. of body weight per day in divided doses every three hours for 6 doses daily. The above dosage should be continued for 10 days, then the dosage reduced to 1/4 grain per lb. for 14 days. During the administration of sulfadiazine the white cell count should be done daily. The administration of penicillin drops in a strength of 500 units per c.c. is recommended concurrent with the sulfadiazine. It may be argued that this is unnecessary, which may be true, but making use of the proved synergistic action of the two agents it is thought wise to use the full armamentarium.

For out-patients treatment is limited to medication the patient is likely to take when on his own responsibility and also by the lack of opportunity to check the white blood cells. It is probably best not to exceed the quantity of 1/4 gr. of sulfadiazine per lb. of weight for 14 days, then a rest period of one week and repeat this schedule twice. Some patients are impressed by local treatment and to such penicillin eye drops may be given. If signs of activity persist after the 8 weeks' course of treatment outlined and it can be established that the patient has followed instructions the diagnosis should be reviewed and the patient kept under control for a further course of treatment.

#### SUMMARY

Old and recent writings on trachoma have been reviewed bringing the outstanding data on the disease together in a single article. An outline of treatment with sulfadiazine and penicillin is recommended, thus applying the newest drugs to a problem that is over 5,000 years old.

A plea is made particularly to general practitioners to be on the watch for trachoma, as early treatment will prevent the catastrophic end results of the disease and lessen dissemination. Constant watch needs to be kept as reinfection is possible.

#### REFERENCES

1. LOE, F.: *Sight Saving Review*, 17: 16, 25, 1947.
2. MITERSTEIN, B. AND STERN, H. J.: *The Lancet*, May 19, 1945.
3. WILSON, R. P.: 14th Rep. Memorial Ophthalmic Laboratory, Giza, Cairo for 1939-44, p. 13.
4. BLAND, J. O. W.: 14th Rep. Memorial Ophthalmic Laboratory, Giza, Cairo for 1939-44, p. 89.
5. BLAND, J. O. W. AND WILSON, R. P.: 14th Rep. Memorial Ophthalmic Laboratory, Giza, Cairo for 1939-44, p. 49.
6. DARIUS, D. J.: *Am. J. Ophthalm.*, 28: 1007, 1945.
7. MACCALLUM, A. F.: *Trachoma*, Butterworth & Co., London, 1936.
8. BODIAN, M.: *Am. J. Ophthalm.*, 30: 758, 1947.
9. KOSEBAY, B.: *Dirim* (in Turkish) 1-2, 15-16, January and February, 1947.

1311-12th St. West.

## CONGENITAL BLINDNESS (PSEUDOGLIOMA) OCCURRING AS A SEX-LINKED DEVELOPMENTAL ANOMALY\*

W. M. G. Wilson, M.D.

Vancouver, B.C.

THIS study deals with the findings in a family of Indians from Manitoulin Island, Ontario, in which several of the males over three generations were blind at birth. Ten members of this family have been examined at the Hospital for Sick Children, Toronto, and others seen elsewhere. These ten cases include five of the blind males, all brothers or half brothers, from three of whom an eye was enucleated for diagnostic purposes. Sections of these eyes, and the pedigree, are pictured and will be discussed. All five of these boys showed evidence of gross bilateral ocular anomalies of the pseudoglioma group.

Among the causes of blindness occurring in infancy and early childhood, pseudoglioma forms a significant percentage. The term is inclusive and applies to several disease conditions of childhood which, together with true glioma or retinoblastoma have in common a single clinical feature. This is the reflection of light from a sightless eye, known as the amaurotic cat's eye, first described by Beer<sup>1</sup> in 1817. For the production of this phenomenon two factors are necessary, (a) transparency of cornea, aqueous and lens, and (b) the presence in the vitreous chamber, close behind the lens, of a white or clear-coloured surface capable of reflecting light entering through the pupil.

Both acquired and congenital conditions are included in the group, classified clinically as pseudoglioma. Since it is clear from the history in the cases here presented that the blindness was congenital, the acquired group will not be considered. In the truly congenital type, which means those showing pathological changes at birth which have originated *in utero*, are included inflammatory conditions, hæmorrhage, phthisis bulbi, tumours and, most numerous, embryological arrests and anomalies of development causing gross ocular malformations. These anomalies, according to Ridley and Soresby,<sup>2</sup>

\* Read at the Academy of Medicine, Toronto, Section of Ophthalmology, on January 26, 1948.

From the Department of Ophthalmology, University of Toronto, and the Hospital for Sick Children.

may be either one of or a combination of the following: (a) persistence of the posterior vascular lens capsule; (b) persistent hyaloid artery with proliferation of its sheath; (c) failure of complete involution of the primary optic vesicle (detached retina) and (d) congenital retinal septum or fold. In these four types the eye is usually microphthalmic. It is of interest here to note that Duke-Elder<sup>3</sup> and Mayou<sup>4</sup> draw a distinction between congenital detachment of the retina and congenital non-attachment, the former being a pathological accident occurring before birth and the latter a true developmental anomaly. Indeed, most writers, in discussing pseudoglioma, point out that retinal detachment is a frequent finding in these eyes, regardless of other disease. The explanation for this, as Ida Mann<sup>5</sup> shows, is that during a large part of intrauterine life the connection of inner and outer layers of the optic cup is very indefinite. This potential cavity, of course, persists through adult life, and an anatomical continuity is never established.

quarter-breed and two whites respectively; all of them are reported to have had normal eyes.

In generation V all the blind males except V 11 who died in infancy, have been examined at the Hospital for Sick Children, as well as the mother IV 5 had several daughters. Ocular examination of the mother and of V, 9, 14, 15 and 16 revealed normal vision (except for small refractive errors), normal fundi and no evidence of ocular congenital anomalies. The normal male, V 13 was examined by the doctor on the Reserve and reported as having normal vision. Many others, male and female, have been reported by him and other doctors as having normal eyes.

In the blind males in generation V the defect was noted by the mother shortly after birth in all except V 3. This boy, being illegitimate, was taken from her for adoption the first day after birth, and returned to her when the blindness was obvious. She states that the pregnancies were normal, but with the males except two, V 13 and 17, labour was prolonged and difficult. On the other hand, with the females she had short easy labours except with V 7 and 14. She had not connected these facts with the incidence of blindness and one hesitates to ascribe any significance to this history.

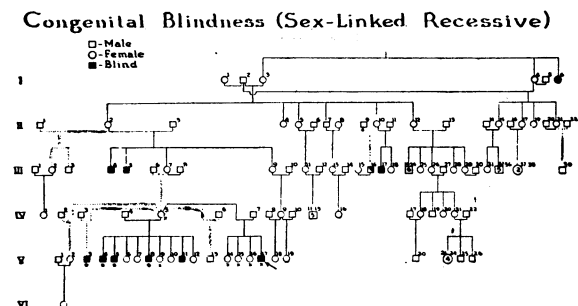


Fig. 1.—Chart showing pedigree of family.

Fig. 1 shows the pedigree of the family, constructed and verified from church and Indian agency records. It reveals that (a) the defect is limited to the males, with one exception, and is transmitted through the females; (b) in generation V the six blind males have in some cases different fathers but the same mother; (c) normal males occur in each generation and (d) the fathers of the blind males had, in each case, normal eyes.

The blindness of I 6, which was possibly acquired in childhood, will be discussed later. In generation III, 2, 3 and 4 died while young, cause of death unknown. Reports, not verified by records, indicate that there may have been other blind siblings. III 17 died in a mental hospital, cause unknown, in middle age. The mother, IV 5 in generation IV had five fathers for her children who were two Indians, a

CASE 1

This study was initiated by the admission to the Hospital for Sick Children, of V 17, aged 18 days, on September 25, 1947. The mother had noticed a pale greenish-yellow reflex in each eye shortly after birth. On examination both eyes presented much the same appearance, the lids being normal, the globes normal in size with clear cornea, shallow anterior chambers, dilated fixed pupils and normal tension. There was no apparent light perception in the right eye, but in the left the infant blinked and withdrew when a bright light was suddenly presented. Behind the clear lens, with oblique illumination was a greenish-gray, brightly reflecting smooth surface with some ill-defined dark red areas and new blood vessels upon it. An irregular ring of small blood vessels was present at the border of the pupil, anterior and posterior to the lens. No reflex was seen on transillumination of the globe. The x-ray examination showed no abnormalities of the orbits and no psammoma bodies were evident either before or after enucleation. Apart from the eyes the infant appeared to be normal, and no abnormalities were found on general physical examination. The blood Wassermann was negative.

Enucleation O.D. was done on October 2, 1947 under general anaesthesia and a plastic ball implant inserted. Except for a mild upper respiratory infection recovery was uneventful.

Fig. 2 shows a section of the eye which measured 17 x 16 x 15 mm. The cornea and lens are clear and it is considered that the appearance of adhesions between iris and cornea are artefacts. The pars plana shows increased fibrous tissue and the ciliary processes are hypertrophied. Behind the umbrella detachment of retina there is a sub-retinal mass of pink-staining, albuminous exudate and a thick fibrous stalk, evidently

long present. The retina is thickened and thrown into folds and made up largely of embryonic cells with no normal retinal structure. Behind the lens there is a mass of fibrous tissue and a large cystic space containing old hæmorrhagic material and debris. There is no evidence of any marked inflammatory process. These observations suggest a developmental anomaly, present for some time. It is obviously not a simple retinal detachment, but a non-attachment, with retro-lental hyperplasia and persistence and proliferation of the hyaloid artery and its sheath.

#### CASE 2

This boy V 8, aged 2½ months, was admitted to the Hospital for Sick Children on July 9, 1935, with lobar pneumonia and a history of blindness since birth. The mother stated that for ten days after birth the eyes appeared normal but then became "smoky". The clinical notes are brief, and summarized, state that both eyes had much the same appearance, with blindness, large iris coloboma and ectropion of the uveal pigment. Each fundus showed, behind the clear lens, a yellowish mass

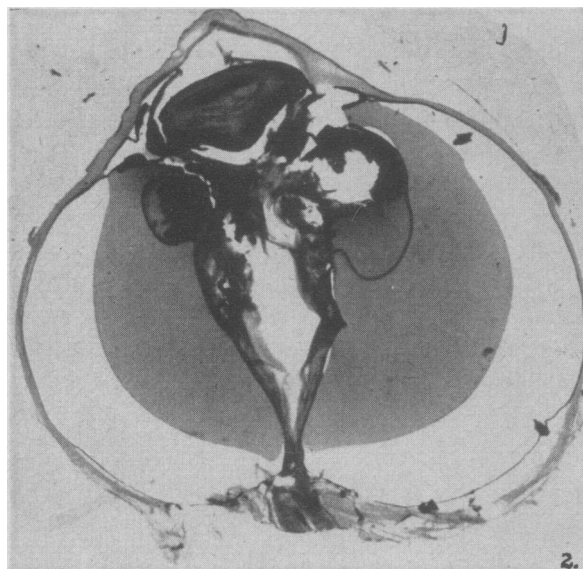


Fig. 2. (Case 1).—Section of enucleated eye.

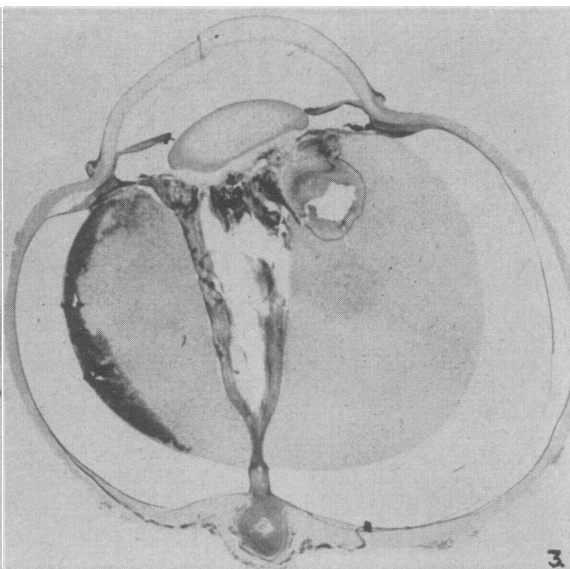


Fig. 3. (Case 2).—Section of enucleated eye.

partly covered by pinkish-looking vessels. The tension was elevated in each eye and, apart from the eyes, no other anomalies were found on general physical examination. The blood Wassermann was negative. Enucleation O.S. was done on July 24, 1935, with an uneventful recovery. The infant is said to have died two months later during an epidemic of measles.

Fig. 3 shows a section of the eye and its similarity to that in Fig. 2 is very obvious. The eye measured 21.5 x 21 x 20.3 mm. Briefly, the findings include a clear cornea and lens, deep anterior chamber with wide anterior synechiæ at the filtration angle and a rudimentary iris with ectropion of pigment, with extensive disorganization in the posterior segment. Masses of partly absorbed hæmorrhage underlie the umbrella detachment of the retina, with much fibrous tissue in the stalk and retro-lental space. The retinal layers are greatly distorted by hæmorrhage, connective tissue and scattered pigment, and very little normal retinal architecture remains. This eye, while not showing such marked disorganization as in Case 1, shows obviously more than a simple detached retina. The presence of congenital glaucoma, rudimentary iris with ectropion of uveal pigment, primitive retinal structure with non-attachment of retina, with extensive fibrosis, indicates an embryological arrest occurring fairly late in fetal life.

#### CASE 3

This boy, V 4, aged 5 years, was one of three brothers, V 3, 4 and 5, admitted to the Hospital for Sick Children on August 21, 1928. In all three apparently, blindness was present from birth, with what was described as a greyish pupil appearing at about two months of age. The brief clinical notes in this case may be summarized as follows; the shrunken right eye showed a dilated pupil with a small atrophic lens floating far back in a deep anterior chamber. In the posterior chamber there was a mass which was probably inflammatory but may have been new growth. The soft shrunken left eye showed degeneration of the cornea with heavy deposits and an opaque lens. The iris was atrophic and the pupil widely dilated. Both eyes were obviously blind and no record was made of other abnormalities on general physical examination. Enucleation O.D. was done on August 22, 1928.

Figure 4 shows a section of the eye which measured 18½ x 18 x 18 mm. In addition to the very deep anterior chamber and firm anterior synechiæ at the angles, a Morgagnian cataract and an anterior polar

cataract are present. Extensive disorganization of retinal structure is apparent with many clefts and areas of embryonic structure, and much fibrous tissue formed behind it and near the nerve head. This latter may have originally been the stalk of an umbrella detachment as was present in the other cases. Lying sub-retinal to one side is a mass of partly organized hæmorrhage. The effects of five years of compression on the whole posterior compartment are clearly seen, and it is interesting to speculate that the eye may have resembled the other two rather closely at a similar age. There is sufficient evidence of developmental abnormalities in this specimen to indicate that an arrest in development, rather than an inflammatory process, was the original pathogenic feature. The lens opacity, apart from an anterior polar cataract, could be the result of nutritional changes due to the abnormal physiology which must have been present in such an eye, and therefore one can assume that originally this eye could also have been included in the pseudoglioma group.

#### CASES 4 AND 5

These brothers V 3 and 5, aged 7 and 2½ years respectively, were admitted with the previous case. The histories given are identical in that the eyes were said to appear normal at birth and for two months after, but then the pupils appeared greyish. Both boys were

blind from birth. The clinical notes are brief and in summary are as follows:

Case 4 (V 3). The right eye showed posterior synechiæ and a soft greyish-yellow lens. In the left eye there was iris atrophy with some uveal ectropion and a dilated pupil. The lens was small and opaque and the vitreous filled with a pinkish mass either due to inflammation or new growth.

Case 5 (V 5). Both eyes showed partly dilated pupils posterior synechiæ and lens opacities. In this case an opinion was recorded that an inflammatory disturbance had caused the synechiæ and lens opacities. No further observations regarding other abnormalities are recorded. Both boys were examined under general anæsthesia. V 3 is still living and is now well known among his tribe as a witch doctor or "bear-walker". V 5 died three years later, cause unknown, at an institution for the blind.

The presence of posterior synechiæ in three of these four eyes is difficult to explain on a primarily embryological basis. In one eye, however, a mass in the

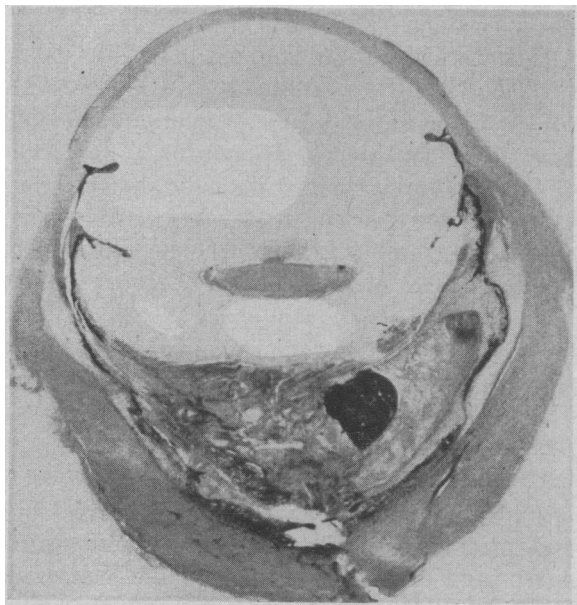


Fig. 4. (Case 3).—Section of enucleated eye.

posterior segment was present, and the opaque lenses prevented a clear examination of the retro-lental area in the others. These cataracts may have been congenital, but on the other hand they may have been the result of nutritional changes as was assumed in Case 3. In both instances, therefore, proof of embryological arrest having occurred is not definite, but at least the inference of some congenital anomalies being present is clear for two reasons; (a) from the absence in the history of any suggestion of inflammatory disease, and (b) the presence of definite fetal abnormalities in the siblings with a similar history. Statements of the mother regarding the appearance of the eyes in early infancy were inconclusive.

#### GENETIC STUDY

Reference to Fig. 1 shows the pedigree beginning with the families of an Indian I 2, who married three times, and died in 1881. There were no children by the first wife. The second and third wives were sisters and another sister of theirs was blind.

By the third wife there were born four daughters, one of whom died. The other three married and had seven sons and three normal daughters. By the second wife there were five daughters and one son, all normal. One daughter died and the other four married. One of these gave birth to a blind son, and a son who was found to be blind in one eye at the age of six years. Another daughter gave birth to at least two blind sons and a carrier daughter. This woman had an only child, a carrier daughter who had six blind sons, one son with normal vision and nine normal daughters.

The genetic factor for this defect (congenital blindness) is evidently sex-linked, females being carriers and males showing the defect, and therefore it is on the X-chromosomes. Thus the males are of two genotypes; (a) those having normal eyes (XY) and (b) those blind (XY), and the females of three genotypes; (a) those having normal sight (XX), (b) carriers, having normal sight (XX), and (c) blind women having two defective X-chromosomes (XX).

Regarding the blind sister (I 6) in generation I, there are three possible explanations for the condition. (1) The blindness may have been due to another acquired condition. (2) If the blindness were sex-linked, then she must have been homozygous for the genetic factor (with two defective X-chromosomes) and inherited one from each parent. In this case the father would be blind (XY) and the mother a carrier (XX). Also since the defective gene would have a low frequency of occurrence as shown in the pedigree, one would expect that the marriage was consanguineous. Unfortunately no information is available regarding either parent. (3) She may have been a carrier (XX) in whom the recessive gene penetrated.

#### SUMMARY

The pedigree of an Indian family, covering six generations, in which several of the males have been born blind, has been shown. Pathological studies of eyes enucleated from three of these males show the presence of gross developmental anomalies. Clinical examination of two other blind siblings, as well as the genetical evidence, suggests the presence here also of ocular developmental anomalies. Five female members of the family showed no ocular anomalies of any kind on examination, and reliable documentary evidence shows that with

one exception, no females were blind. The two males seen in early infancy were proved to be cases of pseudoglioma due to extensive congenital detachment of the retina, and there is evidence that the others may also have shown the clinical phenomena of this condition.

#### CONCLUSION

In this family, therefore, there exists a gene causing a developmental ocular arrest, occurring bilaterally in some of the males. This has been traced through six generations and appears as a sex-linked recessive characteristic.

The author wishes to acknowledge the valuable assistance of Dr. N. Ford Walker, Dr. T. H. Hodgson, Dr. A. L. Morgan and Dr. R. N. Simpson of Manitowaning in the preparation of this paper.

#### REFERENCES

1. BEER: Cited by Wetzel, J. O.: Pseudoglioma of the retina, *Am. J. Ophthalm.*, 24: 164, 1941.
2. RIDLEY, F. AND SORESBY, A.: Modern Trends in Ophthalmology, Butterworth & Co., London, 1st ed., p. 398, 1940.
3. DUKE-ELDER, SIR W. S.: Textbook of Ophthalmology, C. V. Mosby Co., St. Louis, 1st ed., p. 1338, 1946.
4. MAYOU, M. S.: Microphthalmos, *T. O. S.*, 24: 340, 1904.
5. MANN, I. C.: Developmental Abnormalities of the Eye, Cambridge University Press, London, 1st ed., p. 206, 1937.

### PRIMARY RESECTION OF THE COLON IN ULCERATIVE COLITIS\*

G. Gavin Miller, M.D., F.R.C.S.[C.],  
Campbell McG. Gardner, M.D.,  
F.R.C.S.[Eng. & C.] and  
Charles B. Ripstein, M.D., F.R.C.S.[C.]

Montreal, Que.

THE surgical treatment of ulcerative colitis has never been wholly satisfactory. Earlier conservative operations such as appendicectomy have been abandoned in recent years, and it has been the practice of most surgeons to perform an initial ileostomy and follow this later with a staged resection of the colon. Ileostomy alone is seldom adequate and few cases are reported in which intestinal continuity has been restored without recurrence of the disease. When extensive pathological changes have occurred, the bowel wall never reverts to normal, and the dangers of hæmorrhage and polyposis with malignant degeneration always exist. It has been the universal experience that resection of the colon is neces-

sary to cure the disease; and the policy of staged resection has become accepted.

In most cases a permanent ileostomy is necessary. With the development of the Koenig-Rutzen bag this has ceased to be an intolerable disability. Ravitch has recently recommended a pull-through operation which results in a continent anal stoma. This approach is promising but it is still too early to evaluate the end results.

Many surgeons have emphasized the idea that resection of the colon in ulcerative colitis should be a carefully staged procedure and have warned against radical initial operation. Despite the fact that preliminary ileostomy carries a high mortality it has been adopted as the procedure of choice.

In a recent publication we have advocated that ileostomy be combined with right hemicolectomy as an initial operation, and that this be followed in three to six months by resection of the remaining colon. We have since carried out primary resection in 24 cases of ulcerative colitis with no mortality. The procedure has become more radical in successive patients until at present we perform a one stage subtotal colectomy to the level of the lower sigmoid.

Seven years ago, one of us (G.G.M.) was forced to do a primary resection of the right colon in a very sick girl with multiple impending perforations. The result was surprising and spectacular. The patient, who had previously been extremely toxic and ill, responded in a dramatic fashion. Her temperature dropped to almost normal, she gained weight and her symptoms subsided to a considerable extent. It was not until the advent of the sulfonamide drugs and streptomycin that we felt justified in recommending primary resection as a routine procedure. We now feel that with proper pre- and post-operative care this operation can be done with a lower mortality and less morbidity than ileostomy and staged resection.

The right colon is the absorptive part of the large bowel and its removal at once eliminates the absorption of bacterial toxins. Furthermore, the diseased bowel represents an extensive source of protein and blood loss. The amount of protein excreted into the colon may be 100 to 200 gm. daily and it is difficult to maintain the nitrogen balance in the face of

\* From the Departments of Surgery, Royal Victoria Hospital, Queen Mary Veterans' Hospital and McGill University, Montreal, Que.