

## *Original articles*

# The changing pattern of chronic lung disease of prematurity

I HYDE,\* R E ENGLISH,\* AND J D WILLIAMS†

*\*Wessex Department of Paediatric Radiology and the †University Department of Medical Statistics and Computing, Southampton General Hospital*

**SUMMARY** Thirty four infants with chronic lung disease of prematurity were reviewed and divided into two groups on the appearance of the chest radiograph. Type 1 disease (n=19) was defined as homogeneous or patchy ill defined opacification in the lungs without coarse reticulation, and type 2 disease (n=11) had the classical appearance of bronchopulmonary dysplasia. Four patients could not be classified. We conclude that type 1 disease represents typical chronic lung disease of premature infants, and type 2 is usually complicated by pulmonary interstitial emphysema. As no infant with type 1 disease died, its histopathological basis is unknown.

Improvements in the care of premature infants, particularly sophisticated ventilation and monitoring techniques, has lead to increasing numbers of babies surviving, even as young as 24 weeks' gestation. Many of these premature infants develop hyaline membrane disease within the first few hours of birth with the associated range of symptoms and signs of the respiratory distress syndrome. Uncomplicated hyaline membrane disease is self limiting and resolves in seven to 10 days; the lungs of the infants who die of other causes after that time show either no membranes or only fragments.<sup>1</sup> Most infants with the respiratory distress syndrome require supplemental oxygen and mechanical ventilation.

Northway *et al* described a chronic lung disease in premature infants that was superimposed on the healing phase of hyaline membrane disease,<sup>2</sup> which they called bronchopulmonary dysplasia, and in the definition of this disease an abnormal chest radiograph was a crucial component. The abnormalities in established bronchopulmonary dysplasia consisted of overexpanded lungs with a coarse reticulation of air cysts and intervening septa.

It is well known that the classical description of bronchopulmonary dysplasia is not standard, and other authors have described a different radiographic pattern of more homogeneous lung opacities.<sup>3,4</sup> As these seem to be milder forms of chronic pulmonary disease opportunities for histopathological confirmation that it is a type of bron-

chopulmonary dysplasia are infrequent, but Edwards confirmed the diagnosis in two such cases.<sup>5</sup> Tooley diagnosed bronchopulmonary dysplasia in any premature infant who at the age of 30 days still required supplemental oxygen and who also had a pulmonary parenchymal radiographic abnormality.<sup>6</sup> We too have noticed these two distinct types of bronchopulmonary dysplasia, and therefore undertook a review of a cohort of infants born during a three year period to see if our diagnosis was confirmed.

## **Patients and methods**

All cases of chronic lung disease of prematurity in the special care baby unit from 1983 to 1985 inclusive were reviewed. The criteria for inclusion (similar to those of Tooley<sup>6</sup>) were as follows: any premature infant who required mechanical ventilation soon after birth, required supplemental oxygen for at least 28 days, had an abnormal chest radiograph on the 28th day of life, and had no other severe congenital abnormality.

We also recorded birth weight, length of gestation, indications for mechanical ventilation, number of days that intubation and supplemental oxygen were required, the presence of patency of the ductus arteriosus and whether there was evidence of air leaks. Other clinical events that might have affected the radiographic appearances were also noted.

We attempted to divide the radiographic pattern into two types; type 1 consisted of bilateral, ill defined pulmonary opacities that were predominantly perihilar and homogeneous but sometimes patchy. Often these were no more than a haze of density that was fixed and persistent, unchanged by treatment with antibiotics or diuretics, and lacking any coarse reticulation (fig 1).

Type 2 consisted of a coarse reticulation characterised by streaky densities interspersed with small cystic translucencies (fig 2). The translucencies were sometimes, but not always, clearly due to air cysts with well defined walls. We did not consider that transient patchy opacities caused by atelectasis, infection, or haemorrhage that were superimposed on this pattern altered the definition of type 2 (fig 3).

The clinical features of infants with the two types

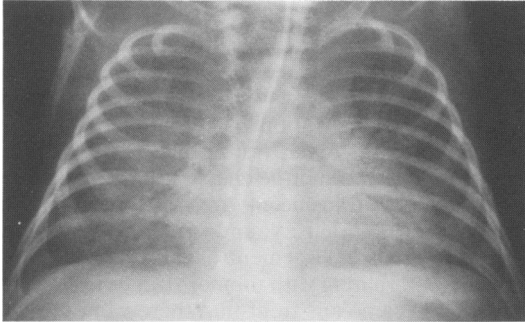


Fig 1 Type 1 chronic lung disease in an infant aged 37 days. Note bilateral hazy perihilar opacities with no coarse reticulation.

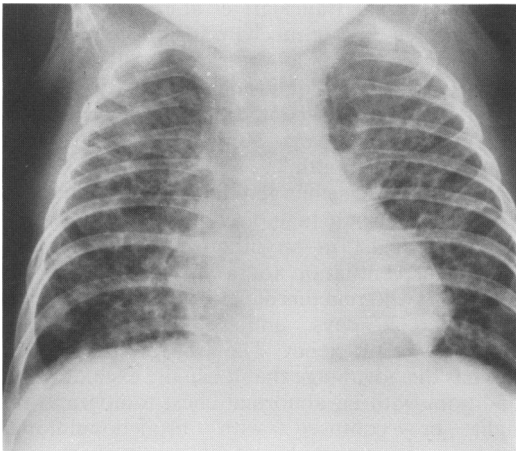


Fig 2 Type 2 chronic lung disease in an infant aged 88 days. Note generalised coarse reticulation.

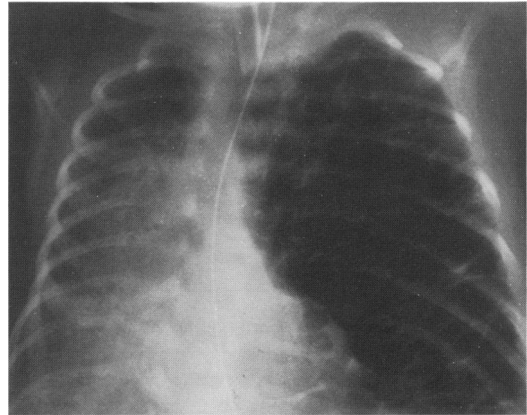


Fig 3 Type 2 chronic lung disease in an infant aged 23 days. Note transient homogeneous opacity of the right lung due to compression collapse from the contralateral air cysts.

of pattern were compared by the Mann-Whitney U test, which was used to obtain estimates and 95% confidence intervals (CI) for differences between the medians in the two groups; a confidence interval that includes zero indicates that the difference is not significant at the 5% level.

### Results

Thirty four infants were included in the study, of whom 33 met all the criteria described. The exception was an infant who died at 21 days of age and in whom bronchopulmonary dysplasia was found at necropsy. Thirty one were ventilated for hyaline membrane disease; three had normal chest radiographs at birth and were presumably ventilated because of apnoea.

There were 19 patients with type 1 and 11 with type 2 disease. Four infants could not be classified; of these, three started as type 1 but became type 2, and in one a type 2 pattern became type 1.

Table 1 shows the birth weights and gestation periods of the infants for each type. The median birth weight for type 2 infants was estimated to be 100 g higher than for type 1 (95% CI of the

Table 1 Details of patients

Median range	Type 1 chronic lung disease of prematurity (n=19)	Type 2 chronic lung disease of prematurity (n=11)
Body weight (g)	980 (660-1520)	1080 (800-1600)
Gestation (weeks)	27 (25-30)	28 (25-31)

Table 2 Complications

	Type 1 chronic lung disease of prematurity No (%)	Type 2 chronic lung disease of prematurity No (%)
Pulmonary interstitial emphysema	7 (37)	11 (100)
Pneumothorax	5 (26)	9 (82)
Patent ductus arteriosus:		
Total	13 (68)	8 (73)
No requiring ligation (% of total)	5 (26)	4 (36)
Total	19 (100)	11 (100)

Table 3 Details of ventilation regimens

	Type 1 chronic lung disease of prematurity	Type 2 chronic lung disease of prematurity
Median (range) period of ventilation (days)	30 (6-99)	40 (21-109)
Median (range) period of oxygen dependence (days)	54 (32-113)	48 (21-169)
Median (range) maximum % inspired oxygen	80 (35-100)	100 (25-100)
Minimum and maximum ventilation pressures (cm H <sub>2</sub> O)	16/2 to 36/5	20/3 to 38/6

difference -90 to 360 g). For gestation periods the difference was one day (95% CI -1 to 2). All patients with the type 2 pattern had had an episode of pulmonary interstitial emphysema, usually during the first few days of life (table 2). Pulmonary interstitial emphysema usually developed gradually into bronchopulmonary dysplasia, but this was not invariably the case. Patency of the ductus arteriosus was diagnosed in a large proportion of both types and ligation was carried out in about half (table 2).

Both groups required prolonged ventilation (table 3); the median for type 2 was estimated to be 10 days longer than for type 1 (95% CI -5 to 23 days). By definition both groups were dependent on oxygen for some time, the median period being six days longer for type 1 than for type 2 (95% CI -31 to 16 days). Type 2 patients required a significantly higher median maximum percentage concentration of inspired oxygen ( $p=0.03$ ); the estimated difference in medians was 15% (95% CI 0 to 30%).

There were four deaths, all of type 2 disease. The age at death ranged from 21-169 days.

## Discussion

When bronchopulmonary dysplasia was first described it was attributed to the adverse effects of oxygen on the immature lungs of premature infants who were being kept alive by mechanical ventilation.<sup>2</sup> Four stages were identified: (1) two to three days, with the classical radiographic picture of hyaline membrane disease; (2) four to 10 days with

almost total opacification of the lungs; (3) 10-20 days, during which the transition to chronic lung disease took place and the chest radiograph showed small rounded translucent areas alternating with areas of irregular density; and (4) after one month, when there was enlargement of the rounded translucencies alternating with thinner strands of density.

It soon became apparent that there were difficulties in staging by radiographic pattern; in particular stage 2 occurred rarely and stage 4 was often atypical.<sup>5</sup> This led to other criteria being used to define the disease based more on functional and clinical features. Bancalari *et al* required a minimum of three days of mechanical ventilation and 28 days dependence on oxygen, but still included a radiographic pattern of strands of density.<sup>7</sup> Tooley, on the other hand, accepted among the criteria any pulmonary parenchymal abnormality on the chest radiograph at 1 month.<sup>6</sup>

A consensus has emerged that bronchopulmonary dysplasia or chronic lung disease of prematurity can be said to exist in an infant who has required mechanical ventilation for a variable period soon after birth, who remains dependent on supplemental oxygen at 28 days, and still has evidence of pulmonary insufficiency. The arbitrary period of 28 days has the advantage that it usually excludes other conditions with an abnormal chest radiograph that might be confused with bronchopulmonary dysplasia—for example, resolving hyaline membrane disease, patent ductus arteriosus with heart failure, pulmonary haemorrhage, and infection.

The justification for the assumption that both the radiological patterns that we have described are caused by bronchopulmonary dysplasia is that they fulfill the accepted criteria of predisposing cause, chronic pulmonary disease, and long term dependence on supplemental oxygen. The occasional transition from one type to the other strengthens that assumption.

The respiratory insufficiency syndrome,<sup>8</sup> chronic pulmonary insufficiency of prematurity,<sup>9</sup> and Wilson-Mikity syndrome (pulmonary dysmaturity),<sup>10</sup> are diseases that characteristically develop after an initial period free of respiratory problems. Of these, only the Wilson-Mikity syndrome has any radiographic similarity to bronchopulmonary dysplasia. Edwards *et al* reported a group of premature infants with lung disease that they called the 'immature lung',<sup>11</sup> with radiographic appearances corresponding closely to what we would call type 2 bronchopulmonary dysplasia; the main difference was the length of time on supplemental oxygen, a factor that was built into our case selection. They believed that these infants had not had respiratory distress syndrome partly because the biochemical profile of pulmonary surfactant was normal.

In the theories of the aetiology of bronchopulmonary dysplasia the role of oxygen toxicity has been downgraded and that of mechanical ventilation promoted, to the extent that the term 'barotrauma' is now sometimes used. Type 1 bronchopulmonary dysplasia as defined by Henghan *et al*,<sup>4</sup> and in the present series, is less serious than type 2, having no mortality and less morbidity, and a lower incidence of air leaks. These are also features of the immature lung. In the absence of histological confirmation the diagnosis of bronchopulmonary dysplasia is imprecise and it is probable that there is overlap with immature lung, respiratory insufficiency syndrome, chronic pulmonary insufficiency of prematurity, and the Wilson-Mikity syndrome.

Pulmonary interstitial emphysema arising in the course of respiratory distress syndrome is a bad prognostic sign and is associated with a higher incidence of bronchopulmonary dysplasia.<sup>12</sup> In the present series all the cases that developed the classical radiographic pattern of bronchopulmonary dysplasia—that is type 2 disease—had this complication. Its appearance is sudden and dramatic and its resolution is usually also rapid, but a persistent form has been described,<sup>13</sup> which (if bilateral and generalised) is readily confused with bronchopulmonary dysplasia stages 3 and 4 as described by Northway *et al*.<sup>2</sup>

If it is accepted that the homogeneous opacity with a predominantly perihilar distribution truly reflects bronchopulmonary dysplasia then it follows

that there are two distinct radiographic patterns of the disease. This study has provided no evidence of a significant difference between the two types with respect to birth weight or period of gestation. We suggest that type 1 represents the basic or pure form, and that the coarse reticular type 2 is a complicated form usually attributable to pulmonary interstitial emphysema.

The pathological basis of the type 1 change is unknown. Alveolar oedema usually shows short term changes in intensity and distribution either spontaneously or as a result of treatment with diuretics. Pulmonary fibrosis should be permanent whereas the type 1 change eventually resolves. For these reasons neither pulmonary oedema nor fibrosis are likely causes; a cellular infiltration seems the most likely explanation. It may be relevant that in the series of immature lung four of those who died had thickened hypercellular alveolar walls, and one also had a chronic interstitial infiltrate that suggested bronchopulmonary dysplasia.<sup>11</sup>

#### References

- 1 Avery ME, Fletcher BD, Williams RG. *The lung and its disorders in the newborn infant*. 4th ed. Philadelphia: WB Saunders, 1981:225.
- 2 Northway WH, Rosan RC, Porter DY. Pulmonary disease following respirator therapy of hyaline-membrane disease. *N Engl J Med* 1967;**276**:357-68.
- 3 Cleveland RH, Todres ID. Patterns of evolution of x-ray changes in respiratory distress syndrome. *Helv Paediatr Acta* 1981;**36**:43-53.
- 4 Henghan MA, Sosulski R, Baquero JM. Persistent pulmonary abnormalities in newborns: the changing picture of bronchopulmonary dysplasia. *Pediatr Radiol* 1986;**16**:180-4.
- 5 Edwards DK. Radiographic aspects of bronchopulmonary dysplasia. *J Pediatr* 1979;**95**:823-9.
- 6 Tooley WH. Epidemiology of bronchopulmonary dysplasia. *J Pediatr* 1979;**95**:851-5.
- 7 Bancalari E, Abdenour GE, Feller R, Gannon J. Bronchopulmonary dysplasia: clinical presentation. *J Pediatr* 1979; **95**: 819-23.
- 8 Carlsson J, Svenningsen NW. Respiratory insufficiency syndrome (RIS) in preterm infants with gestational age of 32 weeks and less. *Acta Paediatr Scand* 1975;**64**:813-21.
- 9 Krauss AN, Klain DB, Auld PAM. Chronic pulmonary insufficiency of prematurity (CPIP). *Pediatrics* 1975;**55**:55-8.
- 10 Wilson MG, Mikity VG. A new form of respiratory disease in premature infants. *AMA Journal of Diseases of Children* 1960;**99**:489-99.
- 11 Edwards DK, Jacob J, Gluck L. The immature lung: radiographic appearance, course and complications. *AJR* 1980;**135**: 659-66.
- 12 Moylan FMB, Walker AM, Kramer SS, Todres ID, Shannon DC. Alveolar rupture as an independent predictor of bronchopulmonary dysplasia. *Crit Care Med* 1978;**6**:10-3.
- 13 Stocker JT, Madewell JE. Persistent interstitial pulmonary emphysema: another complication of the respiratory distress syndrome. *Pediatrics* 1977;**59**:847-57.

Correspondence to Dr I Hyde, Paediatric X Ray Department, Southampton General Hospital, Shirley, Southampton SO9 4XY.

Accepted 23 November 1988