

sleeve at the catheter tip increases the likelihood of bacterial colonisation. Once such colonisation has occurred the catheter may act as a nidus for further blood-borne infection.

## References

- <sup>1</sup> Blackett, R L, *et al*, *British Journal of Surgery*, 1978, **65**, 393.  
<sup>2</sup> Wilmore, D W, and Dudrick, S J, *Archives of Surgery*, 1969, **98**, 256.

- <sup>3</sup> Durskin, M S, and Seigal, P D, *Journal of the American Medical Association*, 1963, **185**, 966.  
<sup>4</sup> Copeland, F M, *et al*, *Surgery, Gynecology, and Obstetrics*, 1974, **138**, 377.  
<sup>5</sup> Horshel, V L, Ause, R G, and Hoskins, P A, *Archives of Surgery*, 1971, **102**, 353.  
<sup>6</sup> Tanner, W A, Delaney, T P, and Hennessy, T P, *British Journal of Surgery*, 1978, **65**, 355.  
<sup>7</sup> Ellis, B W, *et al*, *British Medical Journal*, 1976, **1**, 1389.

(Accepted 2 May 1979)

# Drug-induced oesophageal injury

F J COLLINS, H R MATTHEWS, S E BAKER, J M STRAKOVA

*British Medical Journal*, 1979, **1**, 1673-1676

## Introduction

Oesophageal injury due to accidental or suicidal ingestion of corrosives has long been recognised. Since 1970, however, it has become evident that certain therapeutic agents may also cause similar damage.<sup>1</sup> A recent case of oesophageal ulceration caused by emepronium bromide (Cet:prin) at this hospital caused us to review reports of oesophageal injury from this and other drugs. Forty-one cases of oesophageal damage caused by eight different drugs were found with nine drug-related deaths. We review their clinical and pathological features in the hope of avoiding further instances of yet another iatrogenic disease.

## Case report

In May 1977 a 15-year-old schoolgirl attended the medical out-patient clinic complaining of pain behind the sternum on swallowing. This had started suddenly about one month previously and had been very severe at first, so that even eating jelly had brought tears to her eyes. There had then been an improvement, but some pain still persisted. After the onset of symptoms she had been treated for one week with tetracycline but denied taking any other medications. At the age of 5 she had been investigated for mild unsteadiness on walking and early morning incontinence, but no neurological diagnosis had been reached and no treatment advised. There were no abnormal physical signs.

Investigations showed haemoglobin 13.6 g/dl, white cell count  $6 \times 10^9/l$ , and ESR 15 mm in one hour. Chest radiograph was normal. Barium swallow showed no abnormality. In view of her symptoms rigid endoscopy was performed on 12 July under general anaesthesia. Severe circumferential mucosal ulceration was present with slough formation between 23 and 27 cm from the incisor teeth. The oesophagoscope could be passed through the area, and the distal oesophageal mucosa was found to be squamous and normal. Biopsy specimens from the ulcerated area showed non-specific acute and chronic inflammatory infiltrate with basal cell hyperplasia. In view of this unusual pathological appearance in the mid-oesophagus, she was questioned more carefully about drugs. It then emerged that since March 1977 she had been taking emepronium bromide, 200 mg twice daily, prescribed by her doctor for her mild urinary incontinence. To investigate a possible connection between this drug and the oesophagitis, certain specific studies were performed.

On 27 July, while taking the drug treatment, the patient was screened radiologically after swallowing a tablet of emepronium bromide (200 mg) that had been rendered radio-opaque by drilling the surface and filling the hole with barium sulphate. This was swallowed dry, as was her normal practice, and was seen to pass to the level of the aortic arch, where it became impacted (fig 1). Twenty minutes later the tablet was still at the same level, and it did not move until liquid barium was administered. Later, oesophageal manometry studies were undertaken with the patient off the drug and then again two days

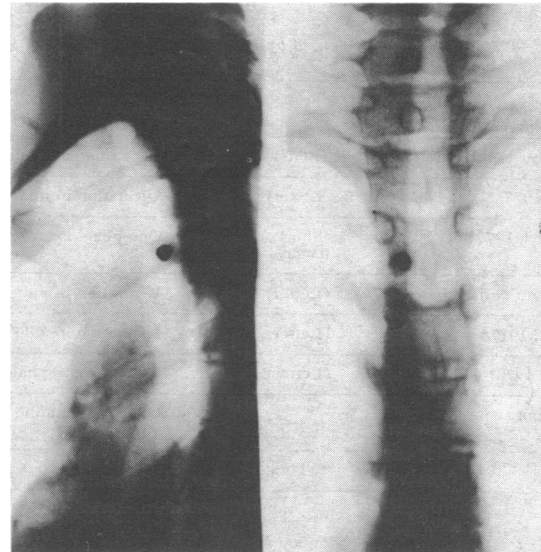


FIG 1—Tablet of emepronium bromide impacted in oesophagus just above aortic arch.

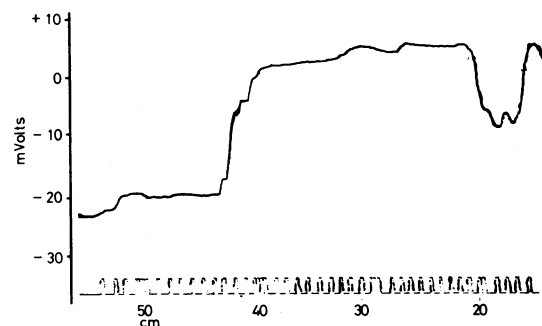


FIG 2—Mucosal potential difference while not taking drug; withdrawal from stomach to pharynx (left to right). Trace shows a stable level throughout body of oesophagus.

Queen Elizabeth Hospital, Edgbaston, Birmingham B15 2TH, UK

F J COLLINS, MB, FRCSI, registrar in thoracic surgery  
 H R MATTHEWS, MB, FRCS, consultant thoracic surgeon  
 S E BAKER, BPHARM, MPS, staff pharmacist  
 J M STRAKOVA, MD, clinical assistant in thoracic surgery

after she had begun taking the drug again. No significant difference in pressures either in upper or lower sphincter or body of the oesophagus was found between the two sets of recordings, but the swallowing pattern showed synchronous rather than peristaltic contractions on both occasions. The record of mucosal potential difference, however, showed a pronounced change on the two occasions. A normal trace was obtained when the drug was withheld, with an abrupt rise at the level of the oesophagogastric junction and a stable trace throughout the rest of the oesophagus (fig 2). With the patient taking the drug a pronounced dip in the trace was seen in the upper reaches of the oesophagus, which would correspond to the area of oesophagitis seen at endoscopy, and is strongly suggestive of mucosal injury (fig 3).

On the basis of these findings the patient was advised to take no further tablets. Her symptoms then progressively disappeared, and repeat endoscopy on 14 October showed the oesophageal mucosa to be fully healed.

## Drugs causing oesophageal injury

### EMEPRONIUM BROMIDE

Emepronium bromide is a quaternary ammonium anticholinergic drug that blocks peripheral cholinergic nerves and ganglionic transmission. It increases bladder capacity, delays the first desire to void, and decreases voiding pressure. It is used in urinary frequency and after bladder surgery, prostatectomy, or bladder radiotherapy.

The first indication of injury to the alimentary tract by this agent appeared in 1972, when oral ulceration was noted in elderly patients who had failed to swallow the tablets.<sup>2</sup> This was subsequently corroborated in 1973 by Hale and Bernardo.<sup>3</sup> Oesophageal injury was first recognised by Habershaw and Bennett,<sup>4</sup> also in 1972, and later by others (table I). Most of these reports, however, were in the form of correspondence to the editors of various journals, and no compre-

hensive account of the condition has yet appeared. Including our patient, 16 cases of oesophageal ulceration caused by emepronium bromide have now been reported, although one of the patients was also taking doxycycline and an injurious effect from that drug cannot be excluded.<sup>5</sup> The ages of the patients ranged from 15 to 56, and the patients were mostly women. Symptoms were usually that of the

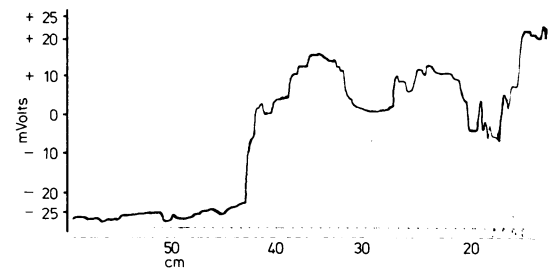


FIG 3—Mucosal potential difference while taking emepronium bromide; trace from body of oesophagus shows dip in middle one-third, suggestive of mucosal injury at site of impaction of tablet.

tablet "sticking" followed by severe retrosternal pain and developed at varying intervals after starting treatment. In one patient they occurred after a single tablet, while in others they did not appear for days or weeks. The oesophageal lesion was that of an isolated ulcer or ulcers usually in the mid-oesophagus, the organ being otherwise normal. In all cases symptoms disappeared shortly after cessation of treatment. When repeat endoscopy was performed, complete or practically complete healing had occurred. No case progressed to stricture of the oesophagus.

TABLE I—Oesophageal injury caused by emepronium bromide

Author	No of cases	Oesophageal pathology	Comments
Habershaw and Bennett, 1972 <sup>4</sup>	(Letter) 1	Ulceration at 22 and 36 cm	Tablet swallowed dry. Local irritation suggested as cause of ulceration.
Kavin, 1977 <sup>5</sup>	(Letter) 3	Ulceration in mid-oesophagus in two cases	One patient also taking doxycycline (qv).
Sheppard, 1977 <sup>6</sup>	(Short paper) 2	Oesophagitis lower half in one case	Barium meal showed gastro-oesophageal reflux without hiatus hernia in other case. Gastro-oesophageal reflux suggested as cause
Kenwright and Norris, 1977 <sup>7</sup>	(Letter) 1	Ulceration in mid-oesophagus	Tablet taken immediately on retiring and without water
Bennett, 1977 <sup>8</sup>	(Letter) 3	Ulceration in all 3 cases	
Higson, 1978 <sup>9</sup>	(Letter) 5	Two had oesophagitis and one an ulcer	Direct irritation suggested as cause of injury
This report	1	Ulceration middle third	Tablet observed to stick at level of injury. Changes in mucosal potential difference while on drug
Total	16		

TABLE II—Oesophageal injury caused by potassium

Drug	Author	No of cases	Oesophageal pathology	Comments
Slow-K	Pemberton, 1970 <sup>1</sup>	1	Ulceration	Cardiomegaly thought to cause oesophageal stasis. Tablet impacted in lower third oesophagus
Slow-K	Whitney and Croxon, 1972 <sup>10</sup>	5	4—Stricture. 1—Ulcer	All had cardiomegaly. Three died: haemorrhage (1) and stricture (2)
Non-coated potassium chloride tablets	Rosenthal, 1974 <sup>11</sup>	1	Ulcer	Cardiomegaly. Died—mediastinitis
Slow-K	Lowry, 1975 <sup>12</sup>	2	Ulceration and stricture	Cardiomegaly
Slow-K	Howie and Strachan, 1975 <sup>13</sup>	1	Stricture mid-oesophagus	Cardiomegaly
Slow-K	McCall, 1975 <sup>14</sup>	1	Penetrating ulcer lower third	Cardiomegaly. Died—haemorrhage
Slow-K	Peters, 1978 <sup>15</sup>	1	Tight stricture mid-oesophagus	
Total		12		

TABLE III—Oesophageal injury caused by antibiotics

Drug	Author	No of cases	Oesophageal pathology	Comments
Doxycycline hydrochloride (Vibramycin)	Bokey and Hugh, 1975 <sup>16</sup>	1	Ulcer lower third	Very low pH of an aqueous solution of this compound was suggested as cause
Tetracycline hydrochloride (Sumycin)	Crowson <i>et al</i> , 1976 <sup>17</sup>	1	Ulcer mid-oesophagus	Small hiatus hernia with no reflux oesophagitis
Tetracycline	Crowson <i>et al</i> , 1976 <sup>17</sup>	1	Three ulcers mid-oesophagus	Small hiatus hernia with no reflux oesophagitis
Doxycycline hyclate (Doxy 11)	Crowson <i>et al</i> , 1976 <sup>17</sup>	1	Large ulcer lower third	
Doxycycline hyclate (Doxy 11)	Schneider, 1977 <sup>18</sup>	2	Several ulcers mid-oesophagus—both cases	Local irritation suggested as cause. Motility disorder suggested as an aggravating factor
Clindamycin (Dalacin C)	Sutton and Gosnold, 1977 <sup>19</sup>	1	Two ulcers mid-oesophagus	
	Total	7		

TABLE IV—Oesophageal injury caused by other drugs

Drug	Author	No of cases	Oesophageal pathology	Comments
Phenylbutazone prednisone	Juncosa, 1970 <sup>22</sup>	1	Ulcer lower third	
Fluouracil	Pannuti, 1973 <sup>21</sup>	5	Necrotising oesophagitis lower third in three patients	17 patients treated: 5 developed symptoms, 3 died—oesophageal necrosis
Carbachol	Cochrane, 1973 <sup>22</sup>	1	3 cm tear in posterior surface of lower third	Died—oesophageal leak
	Total	7		

## POTASSIUM

Potassium chloride has long been recognised as causing small bowel ulceration. The production of slow-release tablets was supposed to overcome this complication, but in 1970 Pemberton<sup>1</sup> reported a case of oesophageal ulceration caused by Slow-K. Since then 10 other cases of oesophageal injury caused by slow-release potassium preparations have been reported, together with one caused by non-coated potassium chloride tablets (table II). The pathological findings included oesophagitis, ulceration, and stricture formation. In five patients death occurred from drug-related causes. Two died from haemorrhage, one from a septic mediastinitis, and two from the long-term effects of stricture, both having needed jejunostomy. A contributing factor in all these cases was the presence of an enlarged heart which was thought to delay swallowing through extraneous oesophageal pressure from left atrial enlargement.

## ANTIBIOTICS

Oesophageal injury has been described in association with doxycycline (four cases), tetracycline (two cases), and clindamycin (one case) (table III). These drugs caused localised discrete ulcers that healed on withdrawal of the drug and were not associated with stricture formation or perforation.

## MISCELLANEOUS

Table IV lists other drugs that have caused oesophageal injury. In 1970 Juncosa<sup>20</sup> reported one case of oesophageal ulceration associated with taking a phenylbutazone-prednisone preparation prescribed for arthritis. Which component was responsible and the subsequent fate of the patient are unknown.

In 1973 Pannuti<sup>21</sup> described a series of 17 patients with carcinoma of the alimentary tract who were taking fluouracil by mouth as recommended by the manufacturers. Five developed oesophageal symptoms including heartburn, retrosternal pressure, and dysphagia. Three of the patients died between the 15th and 30th day after treatment began. At necropsy, necrotising oesophagitis was found in the lower oesophagus in each case.

Cochrane 1973<sup>22</sup> reported a patient who developed vomiting and oesophageal rupture after the administration of subcutaneous carbachol, given for urinary retention. The interval between the administration of the drug and the development of the symptoms was not stated, but the oesophagus was grossly normal at operation, and it was postulated that the drug had induced vomiting, which then caused the rupture. Death eventually resulted from continued oesophageal leakage.

## Discussion

In prescribing oral drug treatment it is usually assumed that ingested drugs reach the stomach rapidly and without hindrance. This, however, is a fallacy.<sup>23</sup> Delayed passage of aspirin-sized tablets through the oesophagus was observed in many subjects with normal gullets and was even more likely to occur in subjects with hiatus hernia and disorders of peristalsis. Clearly when tablets are held up, injury is likely to result. Mechanisms of injury are as yet poorly understood, and may indeed vary from one drug to another. Doxycycline and tetracycline form highly acid solutions in water,<sup>16 17</sup> which could damage the oesophagus. This is not so with emepronium bromide, which was thought to have a local irritant effect by Strouthidis,<sup>3</sup> but Sheppard<sup>6</sup> suggested that its anticholinergic effect predisposed to gastro-oesophageal reflux with resultant oesophagitis. This is contradicted, however, by ulceration occurring in the mouth when the tablets were not swallowed and by the frequent finding of ulceration confined to the mid-oesophagus.

In the cases reviewed here injury has been observed at the anatomical sites of narrowing—for instance, aortic arch and sites of pathological narrowing, such as an enlarged left atrium. Theoretically, tumours and motility disorders might also be expected to predispose to these complications. In addition the tendency of a tablet to adhere to the oesophageal mucosa and its properties of disintegration and dissolution<sup>24</sup> may be a factor.

From the number of cases collected clearly the hazard of oesophageal injury from therapeutic agents in normal doses is

commoner than generally supposed. With the multiplication of these agents, no doubt further cases will emerge. From the practical point of view particular care must be exercised in using these preparations, especially in patients with pre-existing oesophageal obstruction, and, in general, tablets should be swallowed with water or dissolved first. We hope that increased awareness of the possibility of oesophageal injury will lead to greater care in the use of these drugs and to the formulation of safer preparations.

We thank Professor J M Bishop who referred the case, Dr F Howarth for radiological studies, Mr T Dee for photographic prints, and Mrs M Scott for secretarial work.

Requests for reprints to Mr H R Matthews.

## References

- <sup>1</sup> Pemberton, J, *British Heart Journal*, 1970, **32**, 267.
- <sup>2</sup> Strouthidis, T M, Mankikar, G D, and Irvine, R E, *Lancet*, 1972, **1**, 72.
- <sup>3</sup> Hale, J E, and Bernardo, D E, *Lancet*, 1973, **1**, 493.

- <sup>4</sup> Habeshaw, T, and Bennett, J R, *Lancet*, 1972, **2**, 1422.
- <sup>5</sup> Kavin, H, *Lancet*, 1977, **1**, 424.
- <sup>6</sup> Sheppard, H W H, *Journal of Laryngology and Otolaryngology*, 1977, **41**, No 2.
- <sup>7</sup> Kenwright, S, and Norris, A D C, *Lancet*, 1977, **1**, 548.
- <sup>8</sup> Bennett, J R, *Lancet*, 1977, **1**, 810.
- <sup>9</sup> Higson, R H, *British Medical Journal*, 1978, **2**, 201.
- <sup>10</sup> Whitney, B, and Croxon, R, *Clinical Radiology*, 1972, **23**, 147.
- <sup>11</sup> Rosenthal, T, et al, *Chest*, 1974, **65**, 4.
- <sup>12</sup> Lowry, N, *Irish Journal of Medical Science*, 1975, **144**, 366.
- <sup>13</sup> Howie, A D, and Strachan, R W, *British Medical Journal*, 1975, **1**, 176.
- <sup>14</sup> McCall, A J, *British Medical Journal*, 1975, **2**, 230.
- <sup>15</sup> Peters, J L, *British Journal of Surgery*, 1976, **63**, 698.
- <sup>16</sup> Bokey, L, and Hugh, T B, *Medical Journal of Australia*, 1975, **1**, 236.
- <sup>17</sup> Crowson, T D, Head, L H, and Ferrante, W A, *Journal of the American Medical Association*, 1976, **235**, 25.
- <sup>18</sup> Schneider, R, *American Journal of Digestive Diseases*, 1977, **22**, 805.
- <sup>19</sup> Sutton, D R, and Gosnold, J K, *British Medical Journal*, 1977, **1**, 1598.
- <sup>20</sup> Juncosa, L, *Revista Espanola de las Enfermedades del Aparato Digestivo*, 1970, **30**, 457.
- <sup>21</sup> Pannuti, F, *Gazzeta Medica Italiana*, 1973, **132**, 303.
- <sup>22</sup> Cochrane, P, *British Medical Journal*, 1973, **1**, 463.
- <sup>23</sup> Evans, K T, and Roberts, G M, *Lancet*, 1976, **2**, 1237.
- <sup>24</sup> Pilbrant, A K E, *Lancet*, 1977, **1**, 749.

(Accepted 6 April 1979)

# Sudden death during ambulatory monitoring

A LAHIRI, V BALASUBRAMANIAN, E B RAFTERY

*British Medical Journal*, 1979, **1**, 1676-1678

## Summary

**Three patients with ischaemic heart disease died suddenly while being monitored with an ambulatory tape recorder. Two had terminal ventricular fibrillation initiated by paired bidirectional ventricular ectopic beats against a background of scattered ectopic activity; both had had ventricular tachycardia during routine treadmill exercise testing in the week before death. The third patient developed bizarre ventricular complexes followed by asystole.**

**Sudden death may be due to ventricular fibrillation initiated by paired ventricular ectopic beats with changing morphology, or asystole following bizarre ventricular complexes. Exercise testing may have an important predictive value.**

## Introduction

The electrocardiographic antecedents of sudden death outside hospital and the changes taking place during this event are not clearly understood because death seldom occurs during ambulatory monitoring. In 1978 three patients, out of 346 assessed for ischaemic heart disease, died suddenly while being monitored with an ambulatory tape recorder. All three were on long-term treatment for arrhythmias and two had had exercise tests in the two weeks before death. We report the findings in these three cases in the hope that they will help to elucidate possible predictors of sudden death.

Department of Cardiology, Northwick Park Hospital and Clinical Research Centre, Harrow, Middx HA1 3UJ

A LAHIRI, MB, BS, research fellow  
V BALASUBRAMANIAN, MD, FACC, honorary senior registrar  
E B RAFTERY, MD, FRCP, consultant physician

## Case reports

**Case 1**—A 59-year-old television executive came under our care in 1974 for angina. An exercise electrocardiogram showed a 4 mm down-sloping ST depression in lead V5 and a 2 mm depression in leads V4 and V6. He was treated with propranolol, 80 mg thrice daily, and glyceryl trinitrate. His exercise tolerance improved and he was reviewed regularly in the outpatient clinic. Routine investigations revealed no biochemical risk factors. He was not obese and did not smoke. Three years after the first episode he was admitted into the coronary care unit with an acute inferior myocardial infarction. He had a very stormy stay, with primary ventricular fibrillation and multiple multifocal ventricular ectopic beats, which responded to an intravenous lignocaine infusion. He was discharged taking propranolol, 80 mg thrice daily; frusemide, 80 mg a day; and potassium supplements. In the course of 11 months his angina gradually increased and he complained of palpitations. A graded treadmill exercise test (fig 1) showed significant ST segment depression during exercise; it was stopped when he developed ventricular tachycardia at a rate of 250 beats/min. He rapidly returned to sinus rhythm. The total ventricular ectopic count in the exercise period was 18, and a short run of supra-ventricular tachycardia also occurred. Another notable feature was considerable tachycardia during minor grades of exercise despite

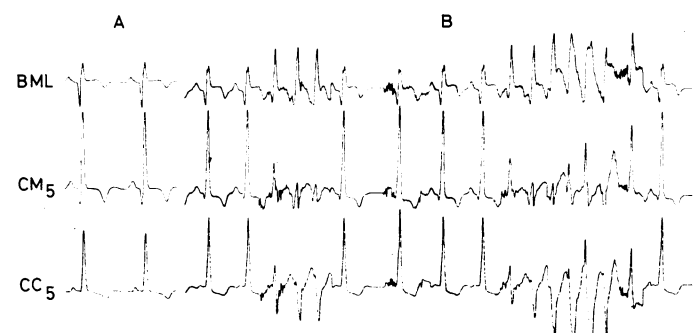


FIG 1—Case 1: ECGs before exercise (A) and during exercise (B), the latter showing ST-segment depression in CM<sub>5</sub> and CC<sub>5</sub> and runs of ventricular tachycardia (CASE, Marquette Electronics). BML—bipolar monitoring lead; CM<sub>5</sub> and CC<sub>5</sub>—bipolar leads.