

changes of pregnancy produced a reversible increase in the fat content of the cells of pre-existing tumours, and (b) that increased peripheral blood flow in pregnancy caused an alteration in the water content of already existent though impalpable tumours.

We thank Dr P Hutchinson, consultant dermatologist, Leicester Royal Infirmary, for help in preparing this case.

<sup>1</sup> Shanks, J A, *et al*, *Canadian Medical Association Journal*, 1957, 77, 881.

<sup>2</sup> Cairns, R J, in *Textbook of Dermatology*, ed A Rook *et al*, 2nd edn, p 1510. Oxford, Blackwell Scientific, 1972.

<sup>3</sup> Caro, W A, in *Dermatology*, ed S L Moschella *et al*, 2nd edn, p 1399. Philadelphia, Saunders, 1975.

(Accepted 4 May 1979)

Department of Obstetrics and Gynaecology, University of Leicester, Leicester Royal Infirmary Maternity Hospital, Leicester LE2 7LX

PETER S BENNY, MB, CHB, registrar

JOHN MACVICAR, MD, FRCOG, professor

## Reversible renal failure during treatment with captopril

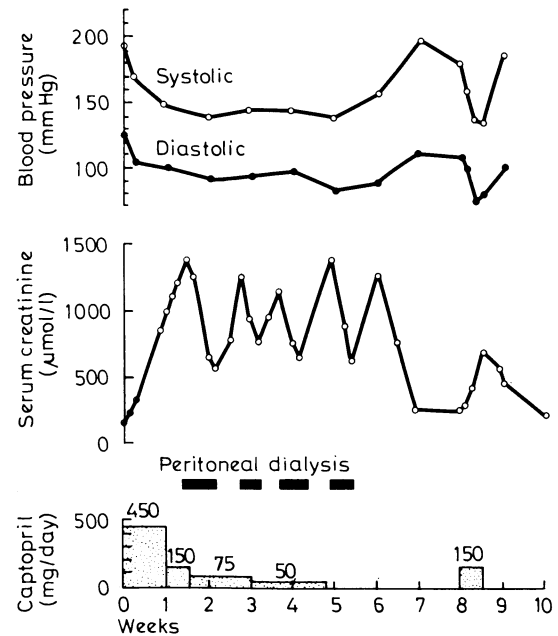
The new orally active angiotensin-converting enzyme inhibitor captopril (Squibb, SQ 14225) is effective in hypertension whether or not of renal origin.<sup>1</sup> Rashes may occur but resolve when the dose is reduced. Other side effects are minor, and nephrotoxicity has not been reported, although transient slight increases in serum creatinine concentrations were observed in two patients.<sup>1</sup> We report a case of acute renal failure in a young woman with transplant artery stenosis and severe hypertension resistant to conventional treatment that occurred during administration of captopril. Renal failure recurred on reintroducing the drug.

### Case history

The patient was found to be hypertensive in 1973, when she was aged 22. Full investigation including renal arteriography failed to disclose a cause for her severe hypertension, which was resistant to large doses of standard drugs. Neither minoxidil nor diazoxide were used because of the risk of hirsuties. She progressed to end-stage renal failure and began regular haemodialysis in 1975. With dialysis, blood pressure was controlled satisfactorily (150/90 mm Hg) while taking propranolol 120 mg daily. She was transplanted with a well-matched (two HLA-B and one HLA-A) cadaver kidney in 1976. There were two renal arteries, one of which was anastomosed end-to-end to the left internal iliac artery and the other end-to-side to the common iliac artery. Two months later severe hypertension recurred, and a systolic bruit was heard over the transplant.

The inferior vena cava (IVC) was cannulated via the right femoral vein and plasma samples collected from the left common iliac vein and IVC below and above the renal veins. Plasma renin activities at the three sites were 69, 56, and 59 pmol/l/min (8.8, 7.2, and 7.6 ng/100 ml/min), suggesting that the graft was the probable cause of her hypertension. Arteriography showed tight stenosis at the anastomosis with the internal iliac artery. At surgical exploration correction of the stenosis could not be attempted without risk of losing the kidney because of dense fibrosis around the anastomosis. Blood pressure remained poorly controlled (190/130 mm Hg lying, 180/130 mm Hg standing) despite methyldopa 3 g, propranolol 1280 mg, frusemide 1 g, and hydralazine 200 mg daily, though standing pressures down to 130/90 mm Hg were recorded at times. Furthermore, she was severely incapacitated by side effects of the drugs, mainly drowsiness and depression. We therefore decided to use captopril, which was approved by the hospital's ethical committee.

All other treatment was stopped the evening before according to the trial protocol under which captopril was being used and the drug given by mouth at an initial dose of 25 mg. This was doubled eight-hourly until 150 mg eight-hourly was reached after 24 hours. Hydrochlorothiazide 50 mg daily was added. The figure shows the blood-pressure response and changes in serum creatinine concentration. The initial fall in blood pressure may have been in part a carryover effect from the previous treatment, but this would not explain control at one week. An erythematous, macular itchy rash appeared after five days but cleared on reducing the dose of captopril to 25 mg eight-hourly. Renal function began to deteriorate on the second day, the lowest recorded blood pressure during captopril treatment before this being 120/80 mm Hg standing. It seemed likely that the renal failure was due to acute tubular necrosis resulting from ischaemia beyond the renal artery stenosis consequent on the reduction in blood pressure, and captopril was continued



Effect of captopril on supine blood pressure and serum creatinine concentration ( $1 \mu\text{mol/l} \approx 0.01 \text{ mg/100 ml}$ ).

at 25 mg eight-hourly. After three weeks of renal failure renal biopsy showed patchy atrophy and inflammation suggesting localised scarring but no evidence of rejection or tubular necrosis.

After five weeks captopril was withdrawn and replaced with methyldopa 500 mg twice daily. During the sixth week renal function recovered, serum creatinine finally reaching pre-captopril values. Hypertension recurred (180/120 mm Hg), and 10 days after recovery methyldopa was withdrawn and captopril reintroduced at a dose of 50 mg eight-hourly. Renal function immediately deteriorated (figure), though blood pressure did not fall below 140/80 mm Hg. Captopril was withdrawn and renal function returned to pretreatment values in eight days.

### Comment

Captopril was most effective in controlling hypertension resistant to conventional agents in the maximum doses that could be tolerated. Although we considered renal ischaemia to be the probable cause of renal failure on the first occasion, the time course of recovery and the recurrence on reintroducing captopril without documented hypotension strongly suggested drug nephrotoxicity. Renal biopsy appearances were compatible with this diagnosis and showed none of the changes of tubular necrosis.

We are grateful to Squibb (Europe) for supplying captopril. We thank Dr A R Morley for the renal histological report, and Mrs R Grieveson for secretarial help.

<sup>1</sup> Gavras, H, *et al*, *New England Journal of Medicine*, 1978, 298, 991.

(Accepted 2 May 1979)

Department of Nephrology, Freeman Hospital, Newcastle upon Tyne NE7 7DN

P R FARROW, BSC, MB, senior house officer

R WILKINSON, MD, FRCP, consultant physician

### Correction

#### Postcards or outpatients: an alternative method of follow-up

We regret that owing to a printer's error Mr David J Varnam's name was spelt incorrectly in the list of authors of the above article (19 May, p 1321). Bristol Myers in his address should have been hyphenated.