

properties and is thought to increase the analgesic effect of peripherally acting drugs. Concern has been growing about the dangers of dextropropoxyphene as a cause of death in acute overdosage, particularly when it is taken with alcohol and other centrally acting drugs.¹ Its potential for producing dependence has been widely reported in the United States. Recently addiction to Distalgesic has been reported in Britain.² We report a further case here where withdrawal was successfully effected.

Case report

A 41-year-old woman with a history of multiple drug abuse in her teens began taking Distalgesic in 1976 to relieve pain after a hysterectomy. She continued to take it regularly since it relieved the chronic back pain and headache from which she also suffered. After several months of uninterrupted consumption she had developed tolerance to its effects. During three years she had gradually increased her consumption to 32 tablets daily. While taking Distalgesic she felt well, confident, and better able to cope with life. When she attempted to stop taking it she had withdrawal symptoms consisting of severe headache, nausea, tremulousness, drowsiness, shivering, and watering eyes. She was also bad tempered, irritable, and subject to overwhelming misery and a severe craving for the drug. She made many importunate demands for prescriptions from her general practitioner. This culminated in her forging a prescription in June 1978, for which she received two years' probation.

Haematological testing gave normal results except for a raised cell volume (110 fl). γ -Glutamyltransferase activity was also raised at 139 IU/l and the calcium concentration slightly depressed (1.95 mmol/l (7.8 mg/100 ml)). A liver biopsy performed shortly after admission showed some cloudy swelling of the hepatocytes and an increased amount of "wear and tear" pigment. The patient denied alcohol abuse. Treatment consisted in withdrawing Distalgesic and giving methadone on a reducing scale, starting with 5 mg four times a day. Methadone was withdrawn completely within 10 days. While on it she had no withdrawal symptoms. But on complete withdrawal of methadone she had low-grade symptoms of misery, nausea, headache, and slight tremulousness. When followed up as an outpatient she had not returned to taking Distalgesic and her symptoms were slowly abating.

Comment

Dextropropoxyphene is the psychoactive ingredient of several widely used analgesics (table). National Health Service prescriptions for these in 1975 totalled 74 383 and had risen by about 20% a year

Formulae of proprietary drugs containing dextropropoxyphene

	Dextropropoxyphene	Paracetamol	Aspirin
Depron SA	150 mg	—	—
Distalgesic	32.5 mg	325 mg	—
Dolasan	100 mg	—	325 mg
Doloxene	65 mg	—	—
Napsalgesic	50 mg	—	500 mg
SK-65	65 mg	—	—

over the preceding three years. A survey of patients discharged from hospitals in a health district showed that 1 in every 38 patients was receiving the drug (AC Bower, unpublished communication, 1979). It is rapidly absorbed from the gastrointestinal tract and passes readily from the blood into body tissues. Dextropropoxyphene is structurally related to methadone and is similar in its onset and duration of action to codeine. It produces dependence of the morphine type. Initially it was thought to be a drug of low potential for abuse and relatively safe, and was introduced to compete with codeine as the analgesic of choice for chronic or recurrent mild-to-moderate pain. Dependence was first reported in 1963 in a 28-year-old man who consumed 960 mg of dextropropoxyphene daily.³ Two further cases of dependence were reported in 1966 and another in 1969.

Seemingly, prolonged administration of medications containing dextropropoxyphene leads to tolerance and dependence. Another danger is its ability to produce respiratory depression in relatively low doses. Controlled studies have failed to show that dextropropoxyphene is any more efficacious than paracetamol or aspirin alone.⁴ The use of drugs containing it should be reappraised in view of the hazards.

¹ Whittington RM. Dextropropoxyphene (Distalgesic) overdosage in the West Midlands. *Br Med J* 1977;ii:172-3.

² Whittington RM. Dextropropoxyphene addiction. *Lancet* 1979;ii:743-4.

³ Elson A, Domino EF. Dextropropoxyphene addiction: observations of a case. *JAMA* 1963;183:482-5.

⁴ Hopkinson JH, Blatt G, Cooper M, *et al.* Effective pain relief: comparative results with acetaminophen in a new formulation, propoxyphene, napsylate-acetaminophen combination, and placebo. *Current Therapeutic Research* 1976;19:622-30.

(Accepted 8 February 1980)

Regional Addiction Treatment Unit, All Saints' Hospital, Birmingham B18 5SD

ROBERT WALL, MB, MRCPsych, senior registrar

SUSAN M J LINFORD, MB, registrar

M IFTIKHAR AKHTER, MB, MRCPsych, consultant psychiatrist

Megaloblastic anaemia due to vitamin B₁₂ malabsorption associated with long-term metformin treatment

Metformin has been used extensively in treating maturity-onset diabetes. It has few side effects, but it inhibits active vitamin B₁₂ absorption in the distal ileum. Annual serum vitamin B₁₂ measurements are therefore advisable in patients on long-term treatment.^{1,2} So far no other case of vitamin B₁₂-deficient megaloblastic anaemia due to metformin therapy has been reported.

Case report

In 1960 a 47-year-old woman gradually developed polyuria and polydipsia. Her height was 1.57 m and weight 88 kg. Her initial 2½-hour postprandial venous blood glucose was 10.1 mmol/l (182 mg/100 ml). She was put on a 4.18 MJ (1000 kcal) diet containing 100 g carbohydrate. Chlorpropamide 250 mg daily was started after one year and within three years metformin 0.5 g twice daily was added because of persistent hyperglycaemia. She was not careful with her diet. When she was 54 her haemoglobin was 13.7 g/dl with normal indices. One year later serum vitamin B₁₂ and serum folate concentrations were normal. When aged 58, after eight years of metformin therapy, she became clinically anaemic with lassitude and general debility. There were no neurological signs of posterior column disease or peripheral neuropathy. Her haemoglobin was 8.9 g/dl, her mean corpuscular volume (MCV) 106 fl (normal 84-99), and her mean cell haemoglobin (MCH) 36 pg (normal 30-35 pg). Serum concentrations were: bilirubin 164 µmol/l (9.8 mg/100 ml) (normal 3.0-21.0 µmol/l), lactate dehydrogenase 680 WL units (normal 220-440), alkaline phosphatase 4.0 KA units (normal), calcium 2.4 mmol/l (9.6 mg/100 ml), and phosphorus 1.2 mmol/l (3.7 mg/100 ml). Serum vitamin B₁₂ was 60 ng/l (normal range 150-900) and serum folate 3.1 µg/l (normal range 3.5-24.0). Blood urea was normal.

A bone marrow aspirate showed a highly cellular pattern with all three cell lines present. The red and white cells were notably megaloblastic with predominance of the erythroid series. A modified combined Schilling test showed 6.2% of a test dose of ⁵⁸Co-labelled vitamin B₁₂ excreted in 24 hours (normal range 10.1-32.1%) and 4.8% of a test dose of ⁵⁷Co-labelled vitamin B₁₂ gastric juice complex (normal range 10.1-30.1%). There was evidence of gastric secretion of free hydrochloric acid (azuresin (Diagnex Blue) test). Concentration of serum gastrin was 65 ng/l (normal 9-150), serum iron 10 µmol/l (55.9 µg/100 ml) (normal 14-25 µmol/l), total iron-binding capacity 65 µmol/l (363 µg/100 ml) (normal 45-72 µmol/l), and serum carotene 1 µmol/l (53.7 µg/100 ml) (normal). Barium studies showed some flocculation and clumping in the proximal ileum but insufficient to suggest a major malabsorption syndrome. There were no local lesions and the terminal ileum was normal. The fat content of a three-day collection of faeces was normal. Intrinsic factor antibody was absent. Treatment was with cyanocobalamin 1000 µg by injection daily at first and subsequently monthly. Serum vitamin B₁₂ rose to over 1000 ng/l and haemoglobin to 13.9 g/dl, and MCV fell to 81 fl, and MCH to 28 pg. She died suddenly when aged 63, probably from myocardial infarction.

Comment

Side effects of metformin, apart from occasional initial nausea, are rare. Lactic acidosis is very unusual in correct clinical usage.³ We found that vitamin B₁₂ malabsorption as shown by a Schilling test was abnormal in 30% of patients who had been on the drug for a mean of four to five years.¹ No patient in that series had actually become anaemic, although three patients had pathologically low serum vitamin B₁₂ concentrations and a fourth had a low normal concentration with macrocytosis. The patient reported here developed

megaloblastic anaemia after taking metformin for eight years. True pernicious anaemia was excluded. There was no evidence of a lesion in the distal ileum and generalised malabsorption was excluded. We presumed that the vitamin B₁₂ malabsorption was related to the effect of metformin on active absorption in the distal ileum but we could not prove that. The anaemia was cured, and treatment with chlorpropamide, metformin, and cyanocobalamin was continued.

Although vitamin B₁₂ malabsorption is relatively common with long-term metformin treatment, we think this is the first reported case of megaloblastic anaemia. The rarity of this complication might be expected since the malabsorption is not complete and the normal body stores contain more than a year's supply of vitamin B₁₂. We advise annual screening for megaloblastic anaemia in patients on long-term metformin treatment, as it is an easily remediable complication and does not necessitate withdrawal of the drug.

¹ Tomkin G, Hadden D, Weaver J, Montgomery D. Vitamin B₁₂ status of patients on long-term metformin therapy. *Br Med J* 1971;iii:685-7.

² Tomkin G. Malabsorption of vitamin B₁₂ in diabetic patients treated with phenformin: a comparison with metformin. *Br Med J* 1973;iii:673-5.

³ Natrass M, Alberti KGMM. Biguanides. *Diabetologia* 1978;14:71-4.

(Accepted 12 February 1980)

Metabolic Unit, Royal Victoria Hospital, Belfast, BT12 6BA

T S CALLAGHAN, MRCP, registrar

D R HADDEN, MD, FRCPED, consultant physician

Metabolic Unit, The Adelaide Hospital, Dublin 8

G H TOMKIN, MD, FRCP, consultant physician

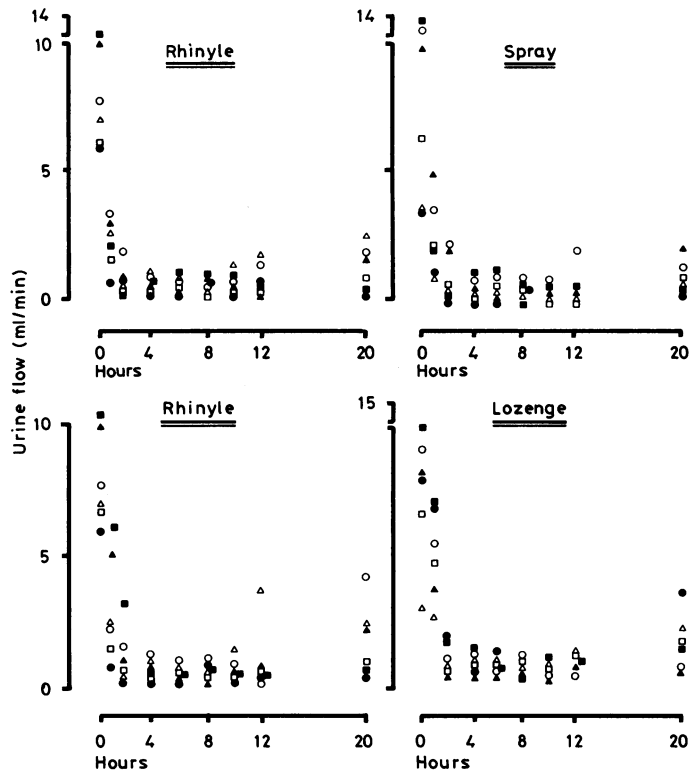
Two new modes of desmopressin (DDAVP) administration

The standard form of replacement treatment for diabetes insipidus in recent years has been the vasopressin analogue desmopressin (DDAVP). This produces a prolonged antidiuresis, lasting up to 20 hours, after intranasal or parenteral administration without the side effects associated with pitressin, such as vascular constriction or smooth muscle spasm.¹ A major problem, however, is the difficulty in administering desmopressin intranasally in the commonly used rhinyle. The technique is rapidly learnt by some patients and gradually by most, but some never manage it. The control of diabetes insipidus, therefore, may be variable. We describe two new modes of administering desmopressin and compare them with rhinyle administration.

Methods and results

(1) A metered-dose nasal spray was used that delivered desmopressin as a fine spray. The spray was inserted into the entrance to one nostril and the patient was required to sniff as the spray was activated. (2) Desmopressin was included in a gelatin-based lozenge, which was placed under the tongue and allowed to dissolve. Two puffs of the spray or one lozenge were taken to be equivalent to 10 µg of desmopressin given by the rhinyle. We administered the spray and lozenges to two groups of six patients with confirmed cranial diabetes insipidus and compared their use with administration of desmopressin by rhinyle. All six patients were tested with two lozenges, and two of them also had a single sublingual lozenge on a separate occasion. In all, there were eight patients with cranial diabetes insipidus established on the basis of water deprivation tests—three males and five females, with an age range of 11-64 years.

The method used for assessing antidiuresis was that described by Edwards *et al.*¹ At 8.30 am the patient was given a one-litre oral water load (500 ml in the case of the 11-year-old patient), and the urine flow rate was subsequently stabilised by giving oral fluids in a volume equivalent to that of the urine passed. When the flow rate was stable desmopressin was given by either the rhinyle or one of the new modes of administration. All the patients normally took 20 µg desmopressin daily but had been off treatment for 24 hours. The volume of urine passed at each time interval was noted and its osmolality measured. The results were analysed by the non-parametric Walsh test.² There was no significant difference between rhinyle and spray or rhinyle and lozenges in terms of urine flow or osmolality at any time up to 20 hours (figure). The responses of two patients to one and to two lozenges were also compared. The speed of onset and maximal effect of the single lozenge were similar to those of two lozenges, but the effect wore off more quickly. Every patient preferred the spray to the rhinyle, while there was a marginal preference for the rhinyle rather than the lozenges.



Changes in urine osmolality after DDAVP. Comparisons between rhinyle and spray (above) and between rhinyle and two lozenges (below). Symbols refer to responses in same subjects.

Comment

Desmopressin given by nasal spray or sublingual lozenge was at least as potent as by rhinyle, in the doses used, in terms of maximal antidiuresis and duration of action. Each produced a potent antidiuresis of rapid onset lasting 10-12 hours followed by a gradual loss of control over the next 12 hours. The nasal spray is simple and efficient, was generally preferred by our patients, and was better than the rhinyle for giving desmopressin, particularly when starting new patients on treatment. This is particularly important in the very young, the very old, and the partially sighted—groups that tend to have special problems using the rhinyle. On the other hand, the advantages of the sublingual lozenges seem fewer. Although obviously effective, at present they should probably be used only when intranasal administration is impossible, as during severe attacks of rhinitis or coryza.

The DDAVP nasal spray and sublingual lozenges were provided by Dr B Donovan, Ferring Pharmaceuticals, Malmö, Sweden. The rhinyle spray and lozenges are not yet commercially available in the United Kingdom.

¹ Edwards CRW, Kitau MJ, Chard T, Besser GM. Vasopressin analogue DDAVP in diabetes insipidus: clinical and laboratory studies. *Br Med J* 1973;iii:375-8.

² Siegel S. *Non-parametric statistics*. New York: McGraw Hill, 1956.

(Accepted 5 February 1980)

Department of Endocrinology, St Bartholomew's Hospital, London EC1A 7BE

ASHLEY GROSSMAN, BA, MRCP, MRC training fellow

A FABBRI, medical student

P L GOLDBERG, BA, medical student

G M BESSER, MD, FRCP, professor of endocrinology

Correction

Gall-bladder sensitivity to cholecystokinin in patients with gall stones

An error occurred in this paper by Dr T C Northfield and others (19 January, p 143). Cholecystokinin values are expressed throughout in mU(Ivy dog)/kg/min. They should have been expressed in Ivy dog units/kg/min.