

Case report

Open Access

Breast carcinoma and malignant melanoma metastasis within a single axillary lymph node

Kirstin A Carswell¹, Kasim A Behranwala¹, Ashutosh Nerurkar A² and Gerald PH Gui*^{1,3}

Address: ¹Breast Surgery Department, Royal Marsden Hospital, London, UK, ²Pathology Department, Royal Marsden Hospital, London, UK and ³Academic Surgery (Breast Unit), Royal Marsden Hospital, London SW3 6JJ, UK

Email: Kirstin A Carswell - kirstincarswell@hotmail.com; Kasim A Behranwala - kbehranwala@hotmail.com; Ashutosh Nerurkar A - Ashutosh.Nerurkar@rmh.nhs.uk; Gerald PH Gui* - Gerald.Gui@rmh.nhs.uk

* Corresponding author

Published: 06 October 2006

Received: 16 September 2006

International Seminars in Surgical Oncology 2006, **3**:32 doi:10.1186/1477-7800-3-32

Accepted: 06 October 2006

This article is available from: <http://www.issoonline.com/content/3/1/32>

© 2006 Carswell et al; licensee BioMed Central Ltd.

This is an Open Access article distributed under the terms of the Creative Commons Attribution License (<http://creativecommons.org/licenses/by/2.0>), which permits unrestricted use, distribution, and reproduction in any medium, provided the original work is properly cited.

Abstract

A 58 year old lady presented with a right breast cancer and a prior history of malignant melanoma excised from the right chest wall eight years previously. An abnormal axillary lymph node resected contained features of both metastatic breast carcinoma and malignant melanoma. Following oncologic breast cancer management, the patient is well with no evidence of recurrence at three years.

Background

There is an increased incidence of breast cancer as a second primary tumour in women previously diagnosed with a malignant melanoma [1]. Any direct association is at best controversial [2] and common aetiological factors remain elusive. One plausible link may be hormonal in origin as oestrogen receptors are expressed in up to half of malignant melanomas [3] and at least two-thirds of breast cancers.

There are isolated case reports of melanoma and carcinoma found together in the primary tumour mass in breast [4], lung [5], oral cavity [6,7]. Cancer-to-cancer metastasis with evidence of melanoma metastases to primary renal cell carcinoma [8] is also documented. There is only one report of synchronous involvement in the metastatic axillary lymph node retaining the dual histology of the breast tumour exhibiting melanoma and carcinoma components [4]. We report on a lymph node containing two different primary cancer types that may result in dis-

tinct clinical management and have different prognostic implications for the patient.

Case report

A 58 year old lady presented with a 2.5 cm right breast lump inferior to the nipple with skin tethering and a palpable malignant right axillary lymph node. She had excision of a right chest wall malignant melanoma Clark's level IV (1.18 mm maximum thickness) eight years prior. There were no palpable axillary nodes at that time. Mammogram, ultrasound and fine needle aspiration cytology of the breast lump confirmed breast cancer. Core biopsy of the right axillary lymph node showed high grade malignancy including pigmented cells, possibly originating from the malignant melanoma. She underwent right wide local excision and axillary nodal clearance. Histopathology revealed a 19 mm, grade 3 infiltrating ductal carcinoma of the breast of medullary phenotype with no lymphovascular invasion that was ER, PgR and HER-2 negative. Breast tumour cells in the primary cancer were

positive for CAM 5.2, AE1, AE3 and EMA and negative for S100 and HMB45. Right axillary nodal clearance showed one out of nine lymph nodes contained metastatic cancer with a large area of necrosis and 2 distinct tumour types (Figure 1). One morphological type was of epithelial origin with cells arranged in cohesive sheets. These areas were positive for CAM 5.2, AE1, AE3 and EMA (Figure 2). Other areas were highly pleomorphic containing cells with prominent nucleoli arranged in loose dissociate clusters that were strongly positive for S100 protein and focally for HMB45; negative for EMA and CAM 5.2 (Figure 3). The lymph node metastases therefore contained features of metastatic breast carcinoma and malignant melanoma in the same metastatic focus. Staging CT of her thorax, abdomen and pelvis as well as a bone scan were negative for distant spread. The patient was treated with adjuvant chemotherapy for breast cancer with 5 fluorouracil, epirubicin and cyclophosphamide for six cycles fol-

lowed by radiotherapy to the breast. She remains well with no evidence of breast cancer or melanoma recurrence three years later.

Discussion

Early diagnosis and better treatment protocols have led to significant improvements in disease free and overall survival following a diagnosis of cancer. It is therefore becoming increasingly common for patients to be diagnosed with a second primary tumour in their lifetime, particularly in patients with primary malignant melanoma [1,2]. The possible explanations include familial factors, the increasing natural lifespan of patients, and improved outcome following previous cancer treatment.

The primary breast cancer in our case did not contain melanoma cells that might have arisen through collision between two histologically different primary tumours,

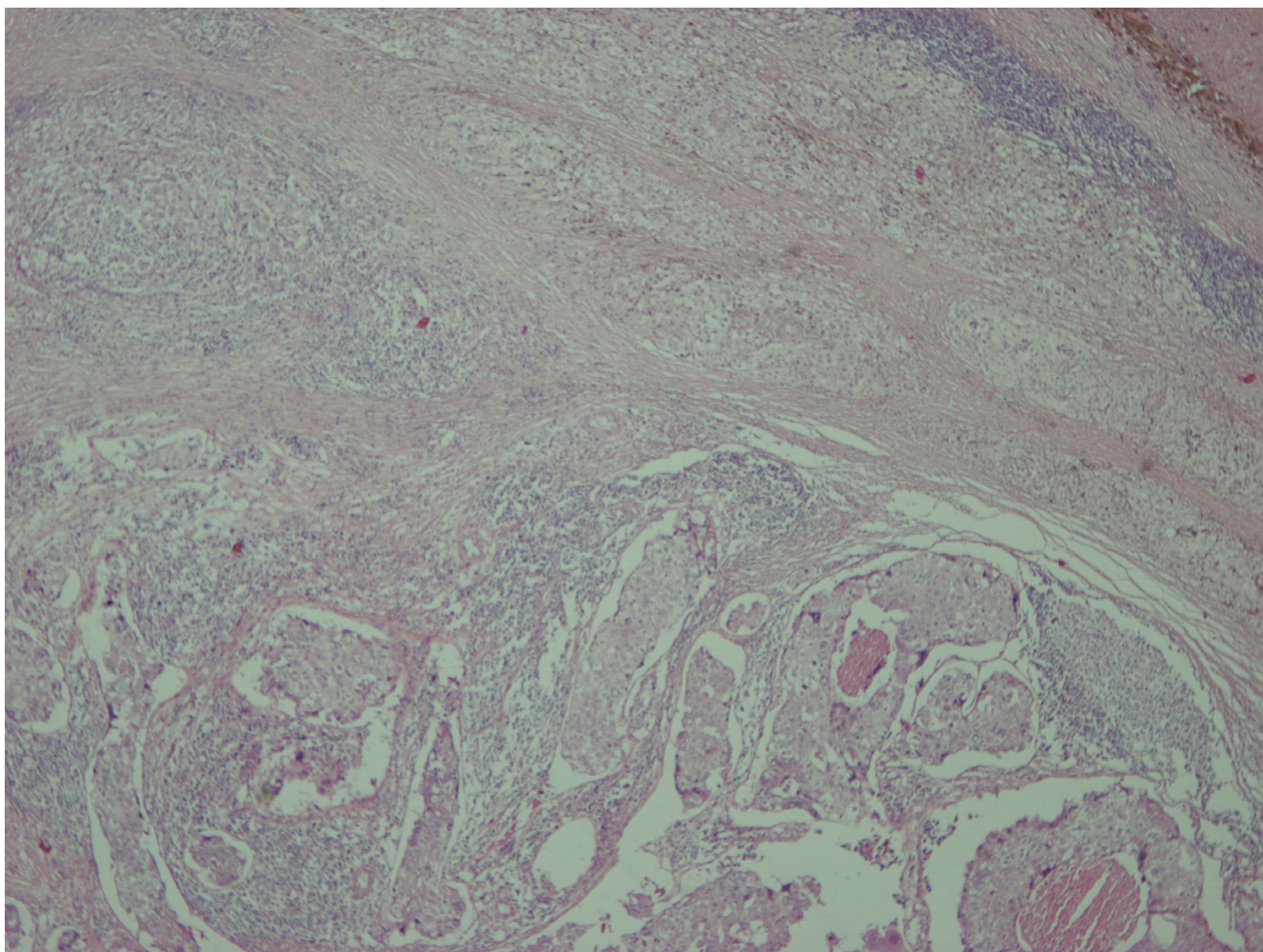


Figure 1

Metastasis of melanoma and carcinoma to a single regional lymph node, the upper part shows melanoma while lower part of photo shows carcinoma (40 \times).

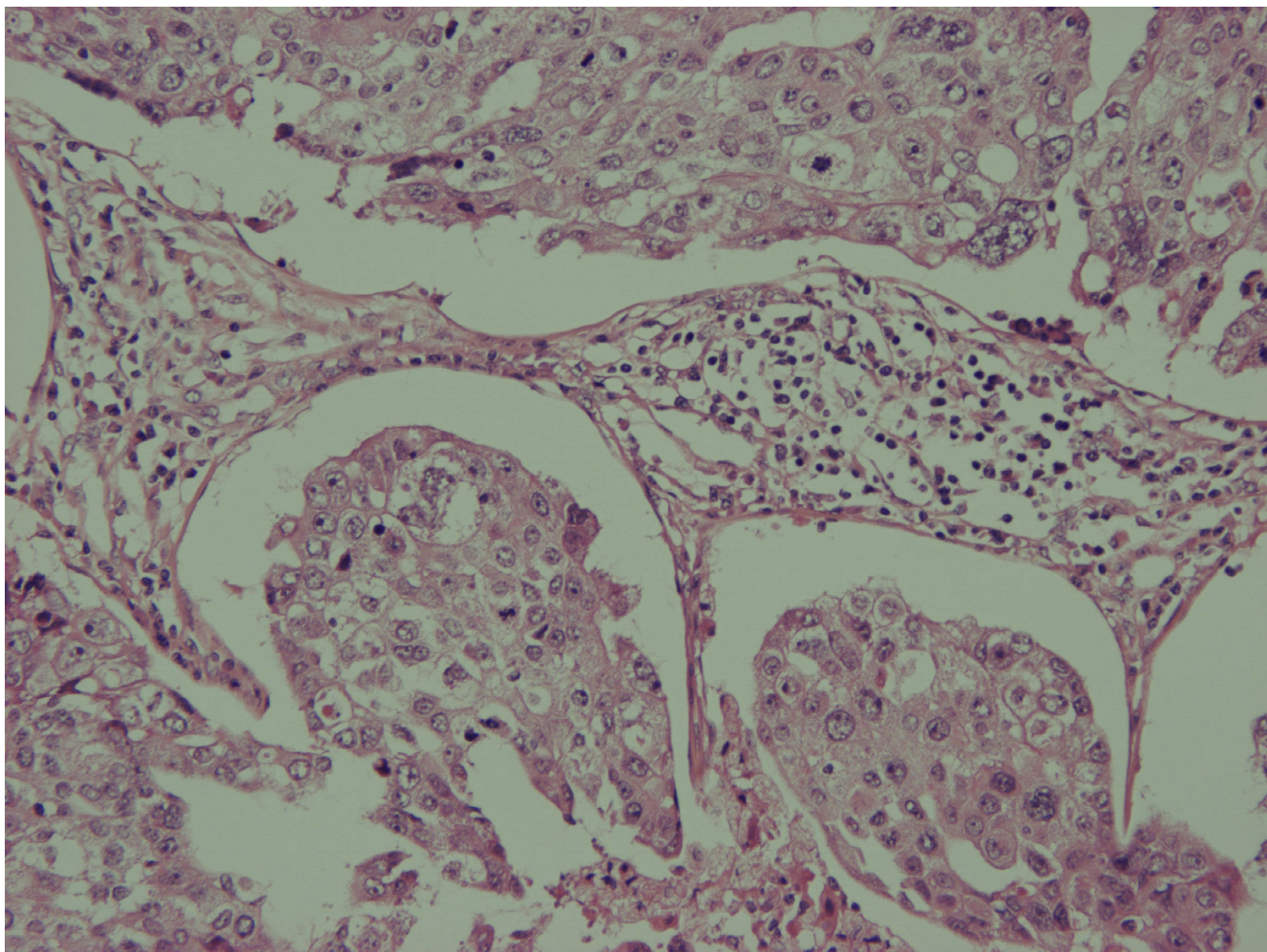


Figure 2
Carcinoma component (200×).

nor was there any pathological evidence of metaplasia, neuroendocrine differentiation or cancer to cancer metastases. The presence of two metastatic cell phenotypes in the axillary lymph node with different immunohistochemistry profiles is likely to have occurred in a metachronous fashion with the melanoma metastasis being detected incidentally during axillary dissection for breast carcinoma. The involved lymph node in probability represented the true sentinel node draining the skin of the chest wall and the breast. It is possible that melanoma micrometastases was dormant in the axillary lymph node and did not progress to clinical significance following the melanoma diagnosis. Melanoma micrometastases may therefore not be prognostically equivalent to overt nodal metastases and may reflect the natural history of melanoma micrometastases in the sentinel lymph node [9]. Barnhill et al [10] demonstrated that melanoma micrometastases lack significant rates of proliferation,

apoptosis and neo-vascularisation when compared with macrometastases as the angiogenic and lymphangiogenic factors may be suppressed by host immune responses.

Subsequent management and follow-up of patients such as ours depend on the competing risks and natural history of the two separate primary cancers. In this case, adjuvant breast cancer treatment was of priority with continued surveillance of the melanoma.

The common sentinel node draining the breast and the trunk skin probably reflects the dominant lymphatic pattern of ectodermal structures and adds to the anatomical evidence to support the concept of the first draining node to a regional basin. The application of new technologies to cancer staging has to be guided by the natural history of the various cancer types. Detection of regional metastases has different prognostic implications for breast cancer and

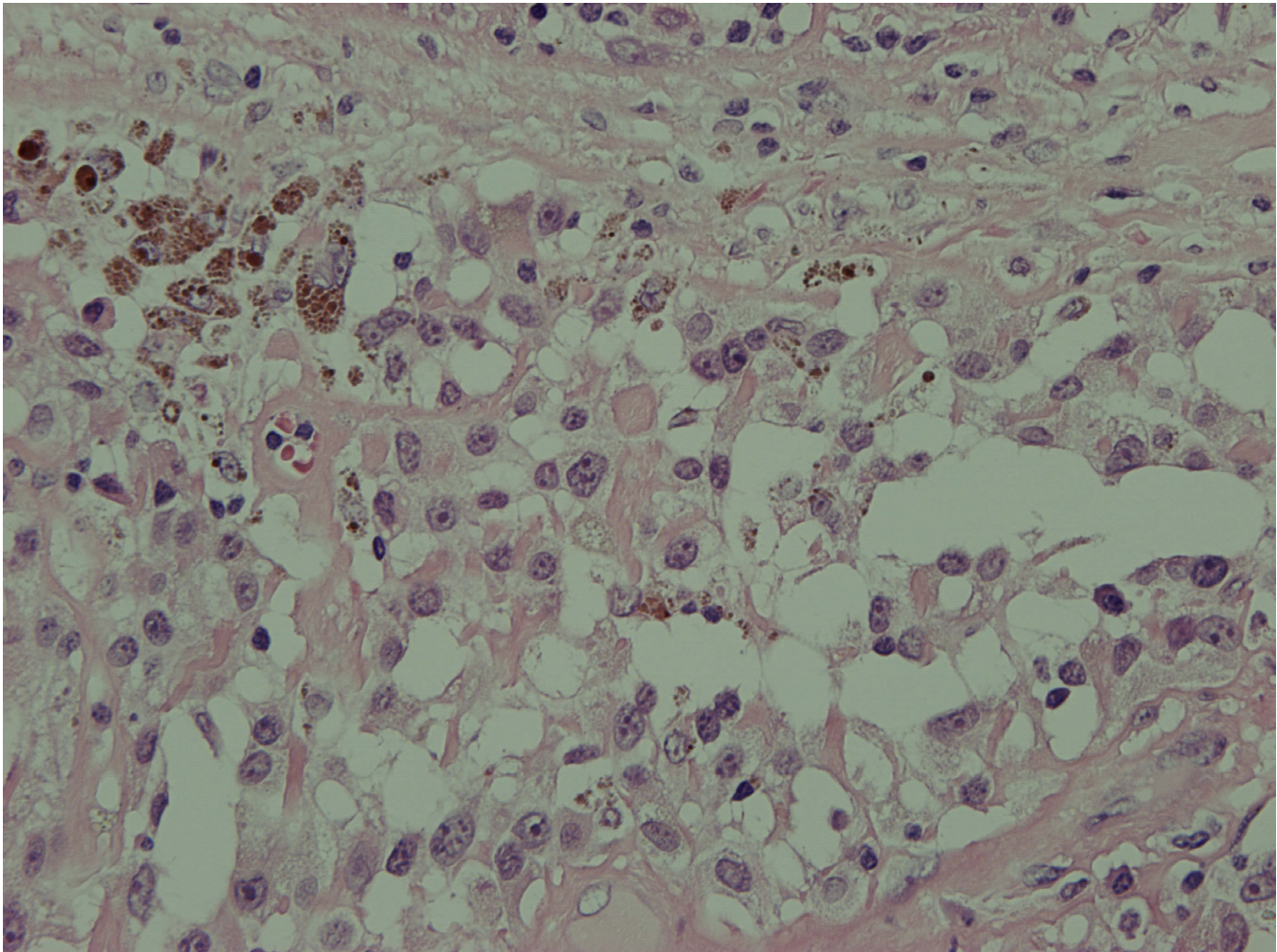


Figure 3
Melanoma component (400×).

melanoma and management decisions need to be made on evidence based clinical criteria rather than any incidental findings.

References

- Gutman M, Cnaan A, Inbar M, Shafir R, Chaitchik S, Rozin RR, Klausner JM: **Are malignant melanoma patients at higher risk for a second cancer?** *Cancer* 1991, **68(3)**:660-5.
- Wassberg C, Thorn M, Yuen J, Ringborg U, Hakulinen T: **Second primary cancers in patients with cutaneous malignant melanoma: a population-based study in Sweden.** *Br J Cancer* 1996, **73(2)**:255-9.
- Walker MJ, Beattie CW, Patel MK, Ronan SM, Das Gupta TK: **Estrogen receptor in malignant melanoma.** *Journal of Clinical Oncology* 1987, **5(8)**:1256-1261.
- Padmore RF, Lara JF, Ackerman DJ, Gales T, Sigurdson ER, Ehya H, Cooper HS, Patchefsky AS: **Primary combined malignant melanoma and ductal carcinoma of the breast.** *Cancer* 1996, **78(12)**:2515-2525.
- Ueyama T, Tsuru T, Tsuneyoshi M, Suelshi K, Sibuya T, Fukuda T: **Primary collision neoplasm of malignant melanoma and adenocarcinoma in the lung. A case report.** *Pathol Res Pract* 1993, **189**:178-83.
- Sirsat MV, Shrikhande SS: **Collision tumour in the oral cavity.** *Indian J Pathol Bacteriol* 1996, **9(4)**:340-3.
- Davis JP, MacLennan KA, Schofield JB, Watkinson JC, Gluckman P: **Synchronous primary mucosal melanoma and mucoepidermoid carcinoma of the maxillary antrum.** *J Laryngology and Otolology* 1991, **105**:370-2.
- Singh EO, Benson RC, Wold LE: **Cancer-to-cancer metastases.** *J Urol* 1984, **132**:340-2.

Publish with **BioMed Central** and every scientist can read your work free of charge

"BioMed Central will be the most significant development for disseminating the results of biomedical research in our lifetime."

Sir Paul Nurse, Cancer Research UK

Your research papers will be:

- available free of charge to the entire biomedical community
- peer reviewed and published immediately upon acceptance
- cited in PubMed and archived on PubMed Central
- yours — you keep the copyright

Submit your manuscript here:
http://www.biomedcentral.com/info/publishing_adv.asp



9. Giblin AV, Hayes AJ, Thomas JM: **The significance of melanoma micrometastases in the sentinel lymph node.** *Eur J Surg Oncol* 2005, **31(10)**:1103-4.
10. Barnhill RL: **The biology of melanoma micrometastases.** *Recent Results Cancer Res* 2001, **158**:3-13.

Publish with **BioMed Central** and every scientist can read your work free of charge

"BioMed Central will be the most significant development for disseminating the results of biomedical research in our lifetime."

Sir Paul Nurse, Cancer Research UK

Your research papers will be:

- available free of charge to the entire biomedical community
- peer reviewed and published immediately upon acceptance
- cited in PubMed and archived on PubMed Central
- yours — you keep the copyright

Submit your manuscript here:
http://www.biomedcentral.com/info/publishing_adv.asp

